



E-ISSN: 2395-1958
P-ISSN: 2706-6630
IJOS 2023; 9(4): 161-165
© 2023 IJOS
<https://www.orthopaper.com>
Received: 04-07-2023
Accepted: 05-08-2023

Md. Tofiqul Hasan Bhuiyan
Medical Officer, Department of
Orthopaedic Surgery, National
Institute of Traumatology and
Orthopaedic Rehabilitation
(NITOR), DHAKA, Bangladesh

Md. Mohoshin Sarker
Jr. Consultant, Department of
Orthopaedic Surgery, Upazila
Health Complex, Chatkhil,
Noakhali, Bangladesh

Md. Sarwar Rahman
Jr. Consultant, Department of
Orthopaedic Surgery, Upazila
Health Complex, Ranisankoil,
Thakurgaon, Bangladesh

Md. Abubaker Siddique
Junior consultant, MS,
Department of Orthopaedic, 250
Bedded General Hospital
Thakurgaon, Thakurgaon,
Bangladesh

Corresponding Author:
Md. Tofiqul Hasan Bhuiyan
Medical Office, Department of
Orthopaedic Surgery, National
Institute of Traumatology and
Orthopaedic Rehabilitation
(NITOR), DHAKA, Bangladesh

Short term functional outcome of arthroscopic partial meniscectomy in isolated un-repairable bucket handle tear of medial meniscus

Md. Tofiqul Hasan Bhuiyan, Md. Mohoshin Sarker, Md. Sarwar Rahman and Md. Abubaker Siddique

DOI: <https://doi.org/10.22271/ortho.2023.v9.i4c.3481>

Abstract

Background: Meniscal tears are common orthopaedic injuries, affecting patients of various ages and activity levels. Bucket-handle meniscal tears (BHMTs) are vertical longitudinal tears of the meniscus with displacement of the torn inner free fragment toward the inter-condylar notch region of the femur. Traumatic tear is very common in young age group due to twisting force on weight loaded flexed knee. Degenerative tear is more common in adult group, but can occur at early age especially in obese patient. Arthroscopic Partial Meniscectomy is a surgical procedure where there is a removal of portion of the torn meniscus.

Objectives: The purpose of this study is to evaluate short term functional outcome of Arthroscopic Partial Meniscectomy for isolated bucket handle tear of medial meniscus.

Methods: This Prospective interventional study was conducted in the Department of Orthopaedic surgery, BSMMU, Shahbag, Dhaka from September 2019 to March 2022. Within this period, a total number of 30 cases of bucket handle tear of the medial meniscus of knee that required surgery were selected as study sample. Visual analogue scale (VAS), WOMET score and Lysholm scores were used to assess the outcome of Arthroscopic Partial Meniscectomy. All the data were analyzed statistically by using statistical package for social science (SPSS-25).

Results: The results of present study demonstrate that the preoperative means (\pm SD) VAS, WOMET and Lysholm scores were respectively 7.153 \pm 0.437, 753.666 \pm 88.336, 50.8 \pm 9.105 and postoperative VAS, WOMET and Lysholm scores were 0.369 \pm 0.242, 141.0 \pm 36.332, and 87.838 \pm 4.204 respectively. Statistically significant differences were observed between the groups. Excellent result was found in 56.6%, good 26.7%, fair 10.0% and poor 6.7% cases. A total number of 25 (83.3%) patients were in the satisfactory group and only 5 (16.7%) patients were in the unsatisfactory group.

Conclusion: It can be concluded that arthroscopic partial meniscectomy showed satisfactory short term functional outcome for the treatment of isolated bucket handle tear of medial meniscus.

Keywords: Bucket handle tear of MM, arthroscopic partial meniscectomy

Introduction

Meniscal lesions are the most common intra-articular knee injury. Arthroscopic partial meniscectomy is the most frequent surgical procedures performed by orthopaedic surgeons [1]. The mean annual prevalence of meniscal lesions has been reported to be 66 per 100,000 inhabitants, 61 of which result in meniscectomy [2, 3] with a male to female prevalence ratio between 2.5:1 and 4:1 [2]. Meniscal lesions occur in all age groups, with the main etiological and pathophysiological factors varying and being highly dependent upon the patient's [4, 5]. The medial and lateral menisci are two fibro-cartilaginous structures attached anteriorly and posteriorly to the tibial plateau. It is relatively less vascular, only peripheral part is vascular and called red zone. The tear in the red zone has healing potential, The anatomy of the menisci has been studied for over 100 years; historically, the meniscus was thought to be a vestigial tissue, and was first described by Bland-Sutton in 1897 as "the functionless remnants of intra-articular leg muscles" [6]. However, now it is known that the menisci provide mechanical support, secondary stabilization, lubrication and localized stress distribution. Load sharing is the main function of the meniscus [7, 8].

The menisci transmit at least 50%-75% of the axial load in knee extension, and up to 85% with the knee in ninety degrees of flexion [9]. Due to removal of meniscal tissue in partial or total meniscectomy, the contact area of the knee joints decreases thereby increasing localized pressure on the surface of the articular cartilage [10]. Increased pressure on the articular surface causes local cartilage damage, leading to accelerated osteoarthritis. That is why, it necessary to remove meniscal tissue as little as possible. The aim of the partial meniscectomy is to preserve all the healthy tissue with a stable meniscal rim, so that it can bear the load at the knee. Bucket-handle meniscal tears (BHMTs) are vertical longitudinal tears of the meniscus with displacement of the torn inner free fragment toward the inter-condylar notch region of the femur. Nearly 10% of all meniscus tears are bucket-handle tears [11]. As displacement of the free segment can lead to significant knee pain, disability and mechanical problems like clicking and locking, most of the cases with BHMTs require surgical treatment. Operative management of meniscal tears typically provides improved function and pain relief [12]. The management decision to use non-operative or operative methods should take into consideration factors related to patients (age, expectations, activity level, lifestyle, duration of injury, general health status, etc.) and the location, duration, type, etiology and tissue quality of the meniscal lesion [13]. Repair is indicated in certain types of meniscal tear in red-red zone and who present early preferably before 3 months. However, most of the patients in our country present late where repair is not possible. Short term results following partial meniscectomy are encouraging with around 90% showing satisfactory clinical results. Several long term studies show that partial meniscectomy may delay degeneration but not prevent it [14]. The aim of this study was to observe the short term functional outcome after Arthroscopic partial meniscectomy for isolated bucket handle tear of medial meniscus. Compared to Arthroscopic meniscal repair, Arthroscopic partial meniscectomy is a technically easy, cost effective and effective method for non-repairable BHMTs of medial meniscus

Materials and Methods

Study design: Prospective study

Types of study: Interventional study

Study period: September 2019 to march 2022

Place of study: This study was carried out in the department of Orthopaedic Surgery, BSMMU, Shahbag, Dhaka

Sample: Isolated Bucket handle tear of medial meniscus patient who need operative treatment

Sample size: Sample size determination depends on time and resources. Estimated population will be calculated by using the following statistical formula [15].

$$n = \frac{(Z\alpha + Z\beta)^2 \times (\sigma_1^2 + \sigma_2^2)}{(\mu_1 - \mu_2)^2}$$

Follow-up of 4 cases were discontinued at 3rd month and 6th month.

So, finally sample size was 30

Study population: Patients attending at the department of Orthopaedic Surgery, BSMMU, Shahbag, Dhaka from all corners of the country for comprehensive management for medial meniscus tear of knee within the defined period.

Inclusion criteria

- Age ->30 years, <50 years
- Late Presentation, after 3 months
- Patients with definite history of trauma followed by symptoms like effusion, locking, joint pain, giving away, quadriceps wasting etc.
- Arthroscopically documented bucket handle tear of MM without ACL injury.
- Patient with arthroscopically diagnosed MM tears not amenable to repair
- Only bucket handle type tear of MM

Exclusion criteria

- a) Menisci tears involving in the red- red zone
- b) Professional athlete
- c) Age< 30 years, >50 years
- d) Others tear of medial meniscus without bucket handle tear
- e) Patient with ACL, PCL injury
- f) Patient with previous history of surgery for knee injuries
- g) Knee sepsis and loss of knee motion due to acute injury
- h) Presence of fractures around the knee (femoral condyle, tibia plateau, patella)

All the data were compiled and sorted properly and the quantitative data were analyzed statistically by using Statistical Package for Social Science (SPSS-25). Level of significance was calculated at 95% CI and p <0.05.

Results

Table 1: Demographic characteristics of the study population (n=30)

Age	Frequency	Percentage
30-35 years	17	(56.66%)
36-40 years	10	(33.33%)
41-46 years	3	(10%)
Sex		
Male	27	(90%)
Female	3	(10%)
Site of Involvement		
Right knee	23	(76.66%)
Left knee	7	(23.33%)
Mechanism of injury		
sports injury	16	(53.33%)
fall from height	5	(16.66%)
RTC	4	(13.33%)
domestic injury	3	(10%)
others injury	2	(6.66%)
Injury and operation		
Within 6 month	5	(16.67%)
>6 month	25	(83.33%)

In this study, out of 30 patients 17 (56.66%) were 30-35 years of age, 10 (33.33%) were 36-40 years and only 3 (10%) were 41-46 years old. The youngest and the oldest patients were 30 and 45 years respectively. The mean age was 35.5±4.50. Majority 27(90%) of the study subjects were male and only 3(10%) were female, so male patient were common in this study. 23 (76.66%) had right knee affected and the rest 7 (23.33%) had left knee affected. So right sided patient were common in this study. Sports injury of 16 (53.33%) patients had history, 5 (16.66%) patients had history of fall from height, 4 (13.33%) patients had history of RTC, 3 (10%) patients had history of domestic injury and 2 (6.66%) others injury. So sports injury was most common cause of medial

meniscus tear in this study. 5 (16.67%) cases arthroscopic partial meniscectomy was performed within 6 months of occurrence of lateral meniscus tear of knee and 25 (83.33%) cases arthroscopic partial meniscectomy was performed after 6 months of occurrence of medial meniscus tear of knee.

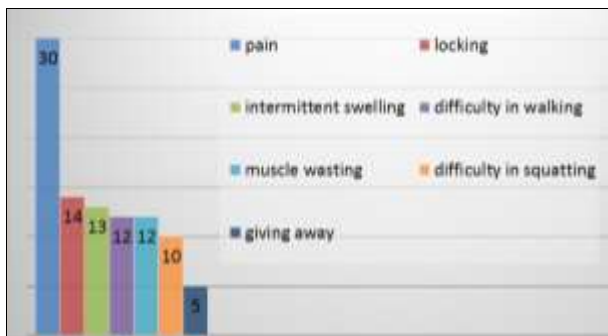

Fig 1: Distribution of study population according to clinical features (n=30)

Figure 1 showing, Preoperative clinical findings show that pain (100%), locking (46.66%), intermittent swelling (43.33%) and difficulty in walking (40%) were the predominant complaints followed by muscle wasting (40%), difficulty in squatting (33.33%), and giving away also present in (16.66%) cases.

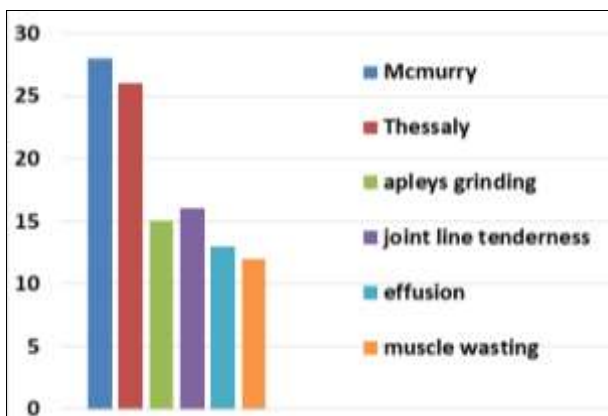


Fig 2: Distribution of study population according to positive clinical examination (n=30)

Figure 2 showing, out of 30 patient, McMurray test was positive 93.3% (28) and the Thessaly test positive 86.7% (26), 53.33% (16) of the patients had joint line tenderness, Apley’s grinding test positive 50% (15), effusion present in 43.33% (13), muscle wasting present in 40% (12) patient

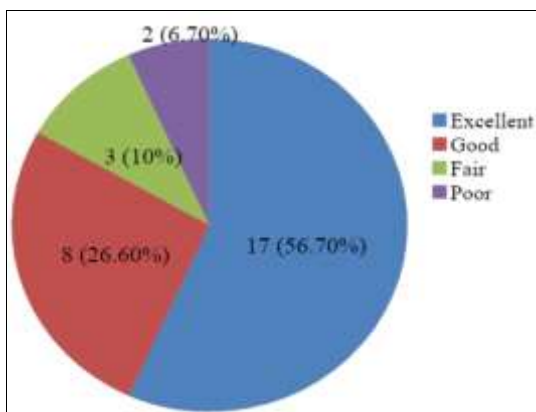


Fig 3: Distribution of study population according to Tapper-Hoover grading (n=30).

Figure 3 showing: According to Tapper-Hooper grading system result was excellent 56.70%, good 26.60%, fair 10.0%, and poor 6.7%.

Table 2: Distribution of study population according to surgical outcome (n=30)

Outcome	Tapper-Hoover Grading	Frequency	Percentage
Satisfactory	Excellent + Good	25	83.3
Un- satisfactory	Fair + Poor	05	16.7
Total		30	100.0

To determine the final outcome of the study, excellent and good grades was treated as satisfactory, fair and poor grade was treated as unsatisfactory according to Tapper-Hoover grading Score. So, a total number of 25 (83.3%) patients were in the satisfactory group and only 5 (16.7%) patients were in the unsatisfactory group.

Table 3: Assessment of the study population according to different Score scale (n=30)

Visual analogue score (VAS)	Preoperative n=30	Postoperative (09 months) n=30	Mean difference	P value*
Mean±SD	7.153±0.437	0.369±0.242	6.784	<0.001

Preoperative means (±SD) VAS, WOMET and Lysholm scores were respectively 7.153±0.437, 753.666±88.336, 50.8±9.105 and postoperative VAS, WOMET and Lysholm scores were 0.369±0.242, 141.0±36.332, and 87.838±4.204 respectively. Statistically significant differences were observed between the groups (Table-3)

Table 4: Distribution of study population according to Scale (n=30)

Scale	Preoperative	Postoperative	Mean difference	p value
WOMET	753.666±88.336	141.0±36.327	612.666	p<0.001***

Table 5: Distribution of study population according to lysholm knee score (n=30)

Lysholm knee score	Preoperative n=30	Postoperative (09 months) n=30	Mean difference	p value*
Mean±SD	50.8±9.105	87.838±4.204	37.038	<0.001
Interpretation				
Poor (<65)	26 (86.66)	0(0)		
Fair (65-83)	04 (13.33)	3 (10.0)		
Good (84-90)	0(0)	5 (16.66)		
Excellent (>90)	0(0)	22 (73.33)		

* Paired Students ‘t’ test was performed

Preoperative Lysholm knee score (Appendix VII) was poor in majority of cases (86.66%), while 09 months postoperative functional outcome of the subjects were good or excellent in most of the cases (89.99%). Besides, significant improvement was found in this study when comparing the preoperative and 09 months postoperative Lysholm knee score (p<0.001) Results were expressed as mean± SD. Paired Student’s ‘t’ test was performed to compare pre and final postoperative follow-up. Level of significance was calculated at confidence interval of 95% and p value <0.05. The preoperative means (±SD) VAS, WOMET and Lysholm scores were 8.63±1.26, 10.50±3.57 and 7.40±10.13 respectively and postoperative VAS, WOMET and Lysholm scores were 0.53±0.71, 83.70±4.30 and 84.70±12.73 respectively. Statistically significant differences were observed between the groups.

Discussion

The present single centered, prospective interventional study was conducted between the periods of September 2019 to March 2022 for the duration of two years in the Department of Orthopaedic Surgery, BSMMU, Dhaka. The present study assesses the short term functional outcome of arthroscopic partial meniscectomy for isolated bucket handle tear of medial meniscus of knee. Total 30 patients of both sexes with bucket handle meniscal tear were included in the study. The analysis of age distribution in this study showed that age range was 30-46 years and mean age was 35.5 years. Nearly similar result was shown by Munshiet al ^[16]. In their study the age range was 15-45 years. In another study of showed the mean age was 27.9 years ^[17]. The majority of patients of our study were male 90% and female were 10%. Similar result was shown by Rayan et al. ^[18]. In their study 88% patients were male and 12% were female. The reason of male predominance may be due to their more involvement in manual activities, sports and random mobility for work. Out of 30 patients 76.66% had injury at right knee and 23.33% had injury at left knee. Similar result was shown by Butt et al. ^[19]. In their study they got predominant right knee injury (63.6%) but dissimilar result was shown by Jha et al. ^[17]. They got predominantly left knee injury (57.1%). This dissimilarity may be due to variation in patient selection. Causes of injury are important and vital factors for meniscal tear. In our study it was found that sports injury were the major cause of apart from other activities. Similar result was showed by Sharma et al; Jha et al. ^[17, 20]. In their study sports injury was the major cause. In present study, arthroscopic partial meniscectomy was performed within 6 to 12 months of occurrence of isolated medial meniscus tear of knee. This result was nearly similar to Butt et al. ^[19]. Clinical findings showed that pain, locking, difficulty in squatting, intermittent swelling were the predominant complaints. Karachalios et al. ^[21] reported that pain and locking were the major complaints. Maximum patients had McMurray test and Thessaly test positive followed by joint line tenderness, Apley's Grinding test are also positive. Varyani et al. ^[22] showed that maximum patient had joint line tenderness. This signifies that findings of clinical examination may vary in different subjects. During operation strict asepsis was followed in every step and broad spectrum intravenous antibiotic was given for three days. Initial recovery was uneventful in the cases. In present study, the postoperative means (\pm SD) VAS was significantly decreased than preoperative VAS. The postoperative means (\pm SD) WOMET and Lysholm scores were significantly improved then preoperative scores. This finding was similar with previous study Sihvonen et al; Varyani et al and Sihvonen et al. ^[22-24]. According to Tapper-Hooper grading system result was excellent 56.70%, good 26.60%, fair 10.0%, and poor 6.7%. We used Hoover classification to evaluate the result postoperatively because it's simple and easy to apply on our patients. Tapper E.M and Hoover N.W ^[25] reported excellent results in 45%, good results in 23%, fair results in 21% and poor results in 11%, after partial meniscectomy. Briol Gulman, et al. ^[26] reported excellent-good result in 73.8% after partial meniscectomy done in 128 patients operated by him. Camanho et al. ^[27] reported excellent-good result in 179 patients out of 194 patients (92.2%), with traumatic meniscus injury, poor result in 7.73% patients (14). Martin MA et al. ^[28] reported excellent results in 41.5%, good results in 43%, fair results in 12% and poor results in 3.5%, on short term after partial arthroscopic meniscectomy done in 116 patients. BK

Tay et al. ^[29] reported excellent-good result in 39 patients out of 51 patients operated by arthroscopic partial meniscectomy (76.5%). Fair results found in 19.6% patients. Poor result in 3.9% patients only. We found that, our results are comparable with those results, although our sample of patients was smaller than there study. To determine the final outcome of the study, excellent and good grades was treated as satisfactory, fair and poor grade was treated as unsatisfactory according to Tapper-Hoover grading Score. In present study, majority of the patients were in the satisfactory group and only 5 (16.7%) patients were in the unsatisfactory group. Almost similar to the findings observed by the various researchers of different countries ^[22-24].

Conclusions

After analyzing the results of the present study, it can be concluded that arthroscopic partial meniscectomy showed satisfactory functional outcome for the treatment of isolated unrepairable BHT of medial meniscus of knee and all the functions of knee were improved in compared with their pre-operative status.

Limitations

Although optimal care had been tried by the researcher in every steps of the study, but there were some limitations:

- Study was conducted in a single hospital. So, the study population might not represent the whole community
- The sample was taken purposively. So, there may be chance of bias which can influence the results
- The study and follow-up period was short in comparison to other studies.
- Small sample size

Recommendations

To make more conclusive results the following recommendations are proposed for further studies:

- Similar type of study can be done with large sample size
- A randomized clinical trial study can be done to evaluates surgical outcome of arthroscopic partial meniscectomy for lateral meniscus tear of knee
- Sample can be collected from different parts of country
- Study must be longer period. So that we find out the effect of treatment in maximum outcome

Conflict of Interest

Not available

Financial Support

Not available

References

1. Englund M, Roos EM, Roos HP, Lohmander LS. Patient-relevant outcomes fourteen years after meniscectomy: Influence of type of meniscal tear and size of resection. *Rheumatology (Oxford)*. 2001;40(6):631-9.
2. Baker BE, Peckham AC, Puppato F, Sanborn JC. Review of meniscal injury and associated sports. *Am. J. Sports Med.* 1985;13(1):1-4. PMID: 3838420, DOI: 10.1177/036354658501300101.
3. Hede A, Jensen DB, Blyme P, Sonne-Holm S. Epidemiology of meniscal lesions in the knee. 1,215 open operations in Copenhagen 1982-84. *Acta Orthop Scand.* 1990;61(5):435-7. PMID: 2239168, DOI: 10.3109/17453679008993557.
4. Makris EA, Hadidi P, Athanasiou KA. The knee

- meniscus: Structure-function, pathophysiology, current repair techniques, and prospects for regeneration. *Biomaterials*. 2011;32(30):7411-31. PMID: 21764438, DOI: 10.1016/j.biomaterials.2011.06.037.
5. Noble J. Congenital absence of the anterior cruciate ligament associated with a ring meniscus. *JBJS*. 1975;57(8):1165-1166.
 6. Bland-Sutton J. *Ligaments: Their Nature and Morphology*. London, UK: JK Lewis; c1897.
 7. Greis PE, Bardana DD, Holmstrom MC, Burks RT. Meniscal injury: I. Basic science and evaluation. *JAAOS-Journal of the American Academy of Orthopaedic Surgeons*. 2002;10(3):168-176.
 8. McDermott ID, Amis AA. The consequences of meniscectomy. *Journal of Bone and Joint Surgery. British volume*. 2006;88(12):1549-1556.
 9. Ahmed AM, Burke DL. *In-vitro* measurement of static pressure distribution in synovial joints—Part I: Tibial surface of the knee. *Journal of biomechanical engineering*. 1983;105(3):216-225.
 10. Ihn JC, Kim SJ, Park IH. *In vitro* study of contact area and pressure distribution in the human knee after partial and total meniscectomy. *International Orthopaedics*. 1993;17(4):214-218.
 11. Metcalf MH, Barrett GR. Prospective evaluation of 1485 meniscal tear patterns in patients with stable knees. *Am J Sports Med*. 2004;32:675-80.
 12. Easley D, O'hara M, Srinivas PS. Option volume and stock prices: Evidence on where informed traders trade. *The Journal of Finance*. 1998;53(2):431-465.
 13. Di Matteo T, et al. The origin of the most massive black holes at high-z: BlueTides and the next quasar frontier. *Monthly Notices of the Royal Astronomical Society*. 2017;467(4):4243-4251.
 14. Jorgensen JD. Oxygen ordering and the orthorhombic-to-tetragonal phase transition in Y Ba 2 Cu 3 O 7- x. *Physical Review B*. 1987;36(7):3608.
 15. Hoque MM. *ABC of research methodology & biostatistics*. Dhaka: Asian color printing; c2014.
 16. Munshi M, Davidson M, MacDonald PB, Froese W, Sutherland K. The efficacy of magnetic resonance imaging in acute knee injuries. *Clin. J Sport Med*. 2000;10(1):34-39.
 17. Jha AAE, Keyhani S, Zarei R, Moghaddam AK. Accuracy of MRI in comparison with clinical and arthroscopic findings in ligamentous and meniscal injuries of the knee. *Acta Orthop Belg*. 2005;71(2):189-196.
 18. Rayan F, Bhonsle S, Shukla D. Clinical, MRI, and arthroscopic correlation in meniscal and anterior cruciate ligament injuries. *Int. Orthop*. 2009;33(1):129-32.
 19. Butt M, Farooq M, Dhar SA, Gani N, Hussain A, Mumtaz I. Clinical Evaluation Of The Knee For Medial Meniscal Lesion And Anterior Cruciate Ligament Tears: An Assessment Of Clinical Reliability. *J Orthopaedics*. 2007, 4(4).
 20. Sharma UK, Shrestha BK, Rijal S, Bijukachhe B, Barakoti R, Banskota B, et al. Clinical, MRI and arthroscopic correlation in internal derangement of knee. *Kathmandu Univ Med J*. 2011;35(3):174-8.
 21. Karachalios T, Hantes M, Zibis AH, Zachos V, Karantanas AH, Malizos KN. Diagnostic accuracy of a new clinical test (The Thessaly test) for early detection of meniscal tears. *J. Bone Joint Surg. Am*. 2005;87:955-62.
 22. Varyani A, Vithal S, Juyal A, Sharma S, Chauhan V. Evaluation of clinical diagnosis by knee arthroscopy. *J.E. of Medical and Dental sciences*. 2013;2(7):772-77.
 23. Sihvonen R, Paavola M, Malmivaara A, Itälä A, Joukainen A, Nurmi H, et al. Arthroscopic Partial Meniscectomy versus Sham Surgery for a Degenerative Meniscal Tear. *N Engl J Med*, 2013, 369(26).
 24. Sihvonen M, Paavola A, Malmivaara A, Itälä A, Joukainen A, Nurmi H, et al. The FIDELITY (Finnish Degenerative Meniscal Lesion Study) Investigators. Arthroscopic partial meniscectomy versus placebo surgery for a degenerative meniscus tear: A 2-year follow-up of the randomised controlled trial Raine. *Ann Rheum Dis*. 2017;0:1–9.
 25. Tapper EM, Hoover NW. Late results after meniscectomy. *J Bone Joint Sur*. 1969;51A:517-26.
 26. Gulman B. *Acta orthopdica et traumatologica turcica*. 1992; ISSN26:1017.
 27. Camnaho GL, Hernandez AJ, Bitar AC. Results of Meniscectomy for treatment of isolated meniscus injuries, correlation between results and etiology of injury. *Clinics*. 2006;61(2):133-8.
 28. Martin MA, Backaert M, Heyman E, Muller JC. Partial arthroscopic meniscectomy versus open meniscectomy. *Acech. Orthop. Trauma surgery*. 1986;108(1):31-5.
 29. Tay BK, Sofyanuddin MD. Early results of arthroscopic partial meniscectomy in Singapore general hospital. *Online Journal*; c2008.

How to Cite This Article

Md. Bhuiyan TH, Md. Sarker M, Md. Rahman S, Md. Siddique A. Short term functional outcome of arthroscopic partial meniscectomy in isolated un-repairable bucket handle tear of medial meniscus. *International Journal of Orthopaedics Sciences*. 2023;9(4):161-165.

Creative Commons (CC) License

This is an open access journal, and articles are distributed under the terms of the Creative Commons Attribution-NonCommercial-ShareAlike 4.0 International (CC BY-NC-SA 4.0) License, which allows others to remix, tweak, and build upon the work non-commercially, as long as appropriate credit is given and the new creations are licensed under the identical terms.