



International Journal of Orthopaedics Sciences

E-ISSN: 2395-1958
P-ISSN: 2706-6630
IJOS 2023; 9(3): 278-284
© 2023 IJOS
<https://www.orthopaper.com>
Received: 05-04-2023
Accepted: 03-05-2023

Dr. AK Prabhakaran
Department of Orthopaedics,
Saveetha Medical College and
Hospital, Thandalam, Chennai,
Tamil Nadu, India

Dr. Akshay J Kumar
Department of Orthopaedics,
Saveetha Medical College and
Hospital, Thandalam, Chennai,
Tamil Nadu, India

Dr. Abin Mahmood Nizar
Department of Orthopaedics,
Saveetha Medical College and
Hospital, Thandalam, Chennai,
Tamil Nadu, India

Dr. R Aswin Sundar
Department of Orthopaedics,
Saveetha Medical College and
Hospital, Thandalam, Chennai,
Tamil Nadu, India

Dr. Yeshwanth Subash
Department of Orthopaedics,
Saveetha Medical College and
Hospital, Thandalam, Chennai,
Tamil Nadu, India

Corresponding Author:
Dr. Yeshwanth Subash
Department of Orthopaedics,
Saveetha Medical College and
Hospital, Thandalam, Chennai,
Tamil Nadu, India

Functional and radiological outcome of retrograde ILIM nailing for distal femur fracture

**Dr. AK Prabhakaran, Dr. Akshay J Kumar, Dr. Abin Mahmood Nizar,
Dr. R Aswin Sundar and Dr. Yeshwanth Subash**

DOI: <https://doi.org/10.22271/ortho.2023.v9.i3d.3437>

Abstract

Aim: To assess functional and radiological outcome of retrograde IMIL nailing for distal femur fracture

Background: Distal femur fractures pose challenges in Orthopaedic treatment, affecting both young and elderly patients. Retrograde intramedullary nailing has emerged as a preferred technique due to its minimally invasive approach and preservation of soft tissue. This study aimed to evaluate the effectiveness of retrograde intramedullary nailing in distal femur fractures and its impact on surgical technique, outcomes, complications, and union rates. Findings will enhance fracture management and inform treatment decisions for orthopedic surgeons.

Materials and Methods: A prospective study was conducted on 28 patients with distal femur fractures who underwent retrograde intramedullary interlocking nailing. Patient selection criteria included age between 18 and 80 years and the presence of simple and complex supracondylar femur fractures. Exclusion criteria comprised severe osteoarthritis of the knee, associated patella fractures, and certain fracture types. Detailed preoperative examinations and imaging were performed, and the surgical procedure involved retrograde nail insertion, fracture reduction, and fixation. Postoperative rehabilitation and follow-up visits were conducted to assess functional outcomes and complications.

Results: Among the 28 patients treated with retrograde intramedullary nailing, the average union time was 10.5 weeks. The surgery duration ranged from 70 to 180 minutes, with an average of 89.64 minutes. The average blood loss was 224.29 ml. Knee range of motion varied from 0 to 81 degrees, with an average American Knee Society Score of 70.36%. Complications included knee pain (14.3%), knee stiffness (7.1%), shortening (14.3%), and infection (7.1%). The majority of patients achieved good outcomes, with 57.2% experiencing no complications. Shortening less than 1 cm was observed in 8 cases, while shortening of 2 cm or more was recorded in 4 cases.

Conclusion: Retrograde intramedullary nailing demonstrated favourable outcomes in the treatment of distal femur fractures. The procedure offered advantages such as shorter operating times and reduced blood loss compared to other methods. Fracture union occurred within a reasonable time frame, and complications were relatively low. However, careful attention should be given to nail insertion depth and adequate proximal locking. Retrograde nailing is considered a reliable alternative for the treatment of extra-articular distal femur fractures, providing successful osseous healing, and facilitating early mobilization.

Keywords: Distal femur fracture, Muller classification type A, retrograde intramedullary nailing, American knee society score

Introduction

Distal femur fractures present a complex challenge for orthopaedic surgeons. They account for approximately 1% of all fractures and 6-7% of femur fractures [1]. The incidence of supracondylar femur fractures is around 37 cases per 100,000 patients per year [2]. These fractures typically occur through two distinct mechanisms. In younger individuals, they result from high-velocity trauma and are often accompanied by severe soft tissue injuries and open fractures. Elderly patients with pre-existing osteopenia can sustain isolated distal femur fractures from low-energy trauma, such as a simple accidental fall [3-5]. Non-operative treatment of these fractures is no longer in favour due to the higher chance of complications like malunion, non-union, and joint stiffness [6].

Treating distal femur fractures is complicated due to their proximity to neurovascular structures, making them more susceptible to vessel injuries. Furthermore, these fractures are located near the knee joint's articular surface, which can lead to early impairment of joint movement, necessitating appropriate physiotherapy for optimal functional recovery.

Regardless of the chosen fixation method, certain principles of internal fixation must be followed. These include achieving anatomical reduction of the articular surface, providing stable internal fixation, minimizing soft tissue damage, and promoting early active mobilization. Intramedullary implants offer potential biomechanical advantages compared to plates [7, 10]. Their placement within the medullary canal reduces stress on the implant, allows load sharing, and enables a closed, minimally invasive insertion without disrupting the fracture hematoma [8-11]. However, antegrade intramedullary nails have been associated with angular deformities due to difficulties in achieving control of the small distal fracture fragment with distal interlocking. The aim of this study was to assess functional and radiological outcome of retrograde IMIL nailing for distal femur fracture.

Materials and Methods

A prospective study involved 30 patients with extra-articular supracondylar femur fractures who were treated with retrograde intramedullary interlocking nails. Patients were selected from admissions to the trauma ward in the Department of Orthopaedics at Saveetha Medical College, Chennai, based on specific criteria. Prior to the investigation, approval from the hospital ethics committee was obtained, and the informed consent was obtained. Patient of age between 18 and 80 years, Cases of simple and complex supracondylar femur fractures (Grades I, II, IIIA), Muller classification: A1, A2, A3 were included in the study. Patients with Complex fractures (Grades IIIB, IIIC), fracture with associated patella fractures, severe osteoarthritis of the knee, Age below 18 years, Muller classification: B, C types were excluded in the study. A total of 30 patients with extra-articular supracondylar femur fractures were included in the study. All patients were initially evaluated either at the outpatient department or the emergency department. Upon admission, a detailed history was taken, including information about the time elapsed since the injury, mode of injury, and a physical examination was conducted. Local examination of the affected limb was performed. A standardized management protocol was followed for all patients. Upon admission, resuscitation and patient assessment were prioritized in accordance with advanced trauma life support guidelines. After admission and stabilization, a detailed examination was conducted, followed by standard Antero-Posterior and Lateral X-ray views to assess the fracture configuration. The fractures were classified according to the Muller classification system. Routine blood investigations were performed. After obtaining informed consent and ensuring anaesthesia fitness for surgery, the patients underwent surgery. The operative technique for retrograde nailing [13] is as follows,

Under spinal anaesthesia the patient is placed supine position, parts painted and draped. With knee should flexed 45 degrees to 55 degrees with a leg roll? Knee flexion allows proper access to the entry portal, as well as reduction and fixation of inter condylar fractures. An infrapatellar incision 4 to 5 cm long is made either directly over the patellar tendon or at its medial edge. The patellar tendon is correspondingly then either split longitudinally or retracted laterally. The entry point is located 5mm in front of the posterior cruciate

ligament attachment, slightly toward the inner side of the distal femoral condyles. The fat pad is removed to directly visualize the entry site in the intercondylar notch. C-arm imaging is used to confirm that the entry site is aligned with the axis of the distal fragment in both the anteroposterior and lateral planes. If necessary, either of the two infrapatellar incisions can be extended to a formal medial parapatellar arthrotomy. The femur is reamed by using hand-held reamers. The reduction is confirmed to be in perfect alignment along the longitudinal axis of the distal fragment, as the varus/valgus and sagittal alignment of the fracture are determined by this. A guide wire is then passed into the distal fragment, and the fracture is reduced through manual traction. The guide wire is subsequently passed into the proximal canal. Length and alignment are maintained manually or with a femoral distractor while the canal is gradually reamed to be at least 1 mm larger than the expected nail diameter. Over reaming by up to 2 mm may be necessary when using a 250 mm length nail to minimize distortion within the canal, which can complicate proximal interlocking. The reamers must be passed sufficiently proximally to accommodate the length of the nail being used. The distal end of the nail should be positioned at least 1 mm below the subchondral bone. Length and alignment are confirmed using an image intensifier before proceeding with interlocking. Traction or manual manipulation is used to achieve proper alignment and reduction of the fracture. The primary goal is to restore the anatomical alignment between the condyles and the structural integrity of the shaft. Intraoperative anteroposterior and lateral radiographs are taken to confirm the proper reduction and alignment. Then nail is advanced through the intercondylar notch into the medullary canal. Typically, the apex of the angle is directed anteriorly. The distal tip of the nail should be counter sunk 1-2 mm below the surface of the intercondylar notch. Then nail is fixed with two proximal and two distal screw. Thorough wound wash given. Wound closed in layer sterile dressing applied.

Postoperative rehabilitation played a significant role in the recovery process, focusing on range of motion and quadriceps strength. Rehabilitation exercises were initiated early if fracture fixation was stable. The rehabilitation program included static and dynamic quadriceps strengthening, hamstring stretching, hip and ankle mobilization exercises. Partial weight bearing was gradually allowed, and full weight bearing was permitted after radiological evidence of healing. Patients were advised to attend regular follow-up appointments at specified intervals. Functional outcomes were assessed using the American Knee Society Score (AKSS), and digital X-rays were taken to monitor fracture union. Follow-up visits occurred every two weeks for the first six weeks, monthly for the next three months, and every three months for two years. The final one-year follow-up results were analysed and compared. Statistical analysis was done with SPSS software. Mann-Whitney test was used to assess continuous variables and Chi square test was used in the comparison of categorical variables. A P value < 0.05 was taken to be statistically significant.

Results

In this prospective study conducted on 28 cases of distal femur fractures, were treated with retrograde intramedullary interlocking nailing were studied between April 2022 to December 2022. Most patients sought medical attention within the first 7-10 days following the injury. The age range of the participants varied from 18 to 80 years, with an average

age of 48.7 years. Fracture incidence was highest among individuals aged 40 to 60 years. Males accounted for 78.6% (21) of the cases, while females accounted for 21.4% (7). Fractures were more commonly observed on the right side. The causes of fractures included road traffic accidents (21 cases), accidental falls (6 cases), and 1 case resulting from an assault injury [Figure 1]. Among the 28 cases studied, the most frequent subtype of extra-articular distal femur fracture was subtype A1 with 14 out of 28 cases (50%). Some polytrauma patients had additional injuries in the same limb, primarily due to motor vehicle accidents, such as multiple rib fractures, haemothorax, and head injuries. Other fracture types observed in the study included distal radius fractures (2 cases), fractures of both leg bones (2 cases), pubic rami fracture (1 case), clavicle fractures (4 cases), and opposite femur fractures (3 cases). Closed fractures were more prevalent in the studied cases, representing the majority. In the subgroup of supracondylar fractures, patients treated with retrograde intramedullary interlocking nailing achieved an average union time of 10.50 weeks. The average surgery duration for this treatment method was 89.64 minutes with maximum of 180 mins for a case but that case had ipsilateral tibial plateau time was also included and minimum of 70 mins in a case, and the average blood loss was 224.29 ml. The patients achieved knee flexion, with an average range of 0 to 81 degrees. Overall, knee flexion ranged from 15° to 105° among all patients, with varying degrees based on the fracture subtype. The average American Knee Society Score at 3 months for these patients was 70.36% [FIG 3]. Among the 28 patients treated with retrograde intramedullary interlocking nailing, 16 patients (57.2%) had no complications. Knee pain was reported by 4 patients (14.3%), stiff knee by 2 patients (7.1%), shortening by 4 patients (14.3%), and infection by 2 patients (7.1%) (Fig 2). Results of our study was shown in [Table 1]. Shortening less than 1 cm was recorded in 8 cases, while shortening of 2 cm or more was recorded in 4 cases. Most patients were able to discard walking aids within 16 weeks, except for two patient who required heel and sole rise. None of our patients were lost to follow up.

Discussion

Distal femur fractures commonly occur in young patients due to high-energy impacts, often resulting in comminuted and open fractures. In contrast, elderly patients with osteopenic or osteoporotic bones can experience distal femoral fractures from low-energy injuries. Over the years, the treatment of distal femur fractures has undergone significant changes. Initially, condylar screws and angled blade plates were used, but now the focus has shifted towards less invasive stabilization systems and retrograde intramedullary nailing^[10, 14, 15]. There are two primary treatment options for distal femur fractures: retrograde intramedullary (IM) nailing and locking plate osteosynthesis. Retrograde IM nailing is preferred for its minimally invasive approach, closed reduction techniques, and better preservation of the soft tissue envelope.

Early surgical stabilization is beneficial as it aids in soft tissue care, allows early mobility, and reduces complexity. Open reduction and internal fixation techniques involve the use of implants such as angled blade plates, fixation devices, Rush rods, Ender nails, dynamic condylar screws, condylar buttress plates, interlocking nails, and locking compression plates. Locking plates provide more rigid fixation by reducing screw-plate motion and toggle at the bone-screw interface. Rigid fixation is crucial for successful treatment. However,

conventional plates have their limitations, including screw pullout, implant failure, and unstable fixation requiring postoperative immobilization.

Nailing offers favourable stability and can be used for bilateral or multisegmented fractures of the lower extremity. It can stabilize various types of distal femur fractures, including extra-articular metaphyseal and supracondylar fractures. Retrograde IM nailing allows for closed indirect fracture reduction, preserving the soft tissue envelope. The distal interlocking screws of the retrograde nail are inserted at a valgus angle of approximately 7 degrees to respect the physiological valgus angle of the femoral condyle and shaft. In SCN IM fixation systems, such as retrograde femoral nails or short condylar nails (SCNs), offer advantages such as smaller incisions, reduced blood loss due to limited exposure, percutaneous joint fixation, increased stability, load-sharing, and support from a long nail. Biomechanical studies have shown that long nails reaching the intertrochanteric region provide greater stability in distal supracondylar femur fractures compared to short retrograde nails. The nail insertion depth is critical, as excessive insertion impairs condylar fixation and complicates removal, while insufficient insertion may lead to the implant protruding into the joint space, risking damage to the medial meniscus, anterior cruciate ligament, and patellar cartilage. Proximal locking can be challenging with short nails, posing a risk of nail fracture during drilling. A snug fit between the nail and bone enhances mechanical interaction.

Indications for retrograde IM nailing include distal femur fractures classified as type A according to the Müller classification, open wounds around the knee, injuries requiring a supine position with elevated thorax and head, bilateral femur fractures, ipsilateral multilevel fractures (e.g., additional proximal femur or combined femur and tibia fractures), periprosthetic fractures around total knee arthroplasty, and severe obesity.

Handolin L, *et al.* studied Retrograde intramedullary nailing in distal femoral fractures-results in a series of 46 cases in that study operational data, per- and post-operative complications and the outcome were studied retrospectively after a mean follow-up of 9 months. The final union rate was 95%, with a mean union time of 17.5 (8-68) weeks. Restoration of the limb axial alignment and length was inadequate in two cases, whereas three losses of reduction and one non-union were observed. Two cases of distal locking screw breakage were also observed. Moreover, one patient suffered from an iatrogenic lesion of the branch of the deep femoral artery. No deep, but three superficial infections were observed. In conclusion, they suggest that retrograde nailing is a reliable alternative in distal femoral fracture treatment with a low complication rate^[9].

Hierholzer, *et al.* studied we analysed 115 patients with distal femur fracture both extra and intraarticular fractures who had been treated by retrograde IM nailing (59 patients) or LISS plating (56 patients), have found no difference between the groups with respect to non-union and infection and they stated that Clinical outcome largely depends on surgical technique rather than on the choice of implant^[10].

Demirtas, *et al.* studied Comparison of retrograde intramedullary nailing and bridge plating in the treatment of extra-articular fractures of the distal femur did not find any significant difference with respect to implant failure, malunion, non-union, knee pain, or union time in extra articular distal femur fractures. Both Gao, *et al.* and Gill *et al.*^[17, 18] who have studied Retrograde nailing versus locked

plating of extra-articular distal femoral fractures: comparison of 36 cases have found similar findings in extra articular distal femur fractures [20]. They have found significant difference between nailing group and plating in terms of blood loss and surgical time favouring the plating group. As the nailing patients required extra procedure of sequential reaming, increased blood loss as well as surgical time was seen in nailing. However, these findings did not translate into any long-term effects as there was no significant difference between the two groups with respect to deep infection, implant failure, knee pain or knee range of motion. Gao, *et al.* also reported more union disturbances, namely both non-union and delayed union combined in the plating group, when compared to the nailing group [17].

Markmiller, *et al.* studied distal Femur treated using LISS and Distal Femoral Nail for Fixation of Distal Femoral Fractures also did not find any significant between the two groups nailing and plating with respect to infection, malunion or non-union [19].

Contraindications for retrograde IM nailing include open epiphyseal cartilages, bone infection, pathologic fractures, total hip arthroplasty, and lung contusions. IM reaming and nail insertion may spread bacteria in cases of infection, making IM nailing unsuitable. Disadvantages of nailing include a lack of alignment control, retro curvature, intra-articular insertion, joint cartilage perforation, and intraarticular distribution of reaming debris. Although angular

malunion is a known complication of retrograde medullary nailing, the use of longer and broader nails and the use of poller screws whenever necessary can reduce its occurrence [24, 25]. Inserting small diameter and short nails can limit stability [22, 23]. Our results showed retrograde nails have advantages such as shorter operating times and reduced blood loss compared to other methods [27-32]. Union of the fracture occurs earlier, while complications such as infection, stiff knee, knee pain, and shortening [24, 25] can occur with the SCN technique. Excellent outcomes were observed in 21.9% of SCN patients, fair results in 21.9%, good outcomes averaged at 42.9%, and poor outcomes in 14.9%.

Despite the advanced age of patients, reduced activity levels, and various comorbidities, retrograde nailing resulted in reliable osseous healing in most cases. This allowed for painless fracture sites and stable knee joints, facilitating early mobilization even in challenging cases. Fracture union was achieved within a reasonable time, and the complication rate was relatively low. However, the long-term effects of trans-articularly inserted retrograde femur implants remain unknown. Bone debris from the nail insertion canal may pose a risk to the knee joint, making thorough irrigation before wound closure vital. Retrograde nailing proves to be a reliable alternative for the treatment of extra-articular distal femur fractures when considering options for supracondylar femoral fractures.

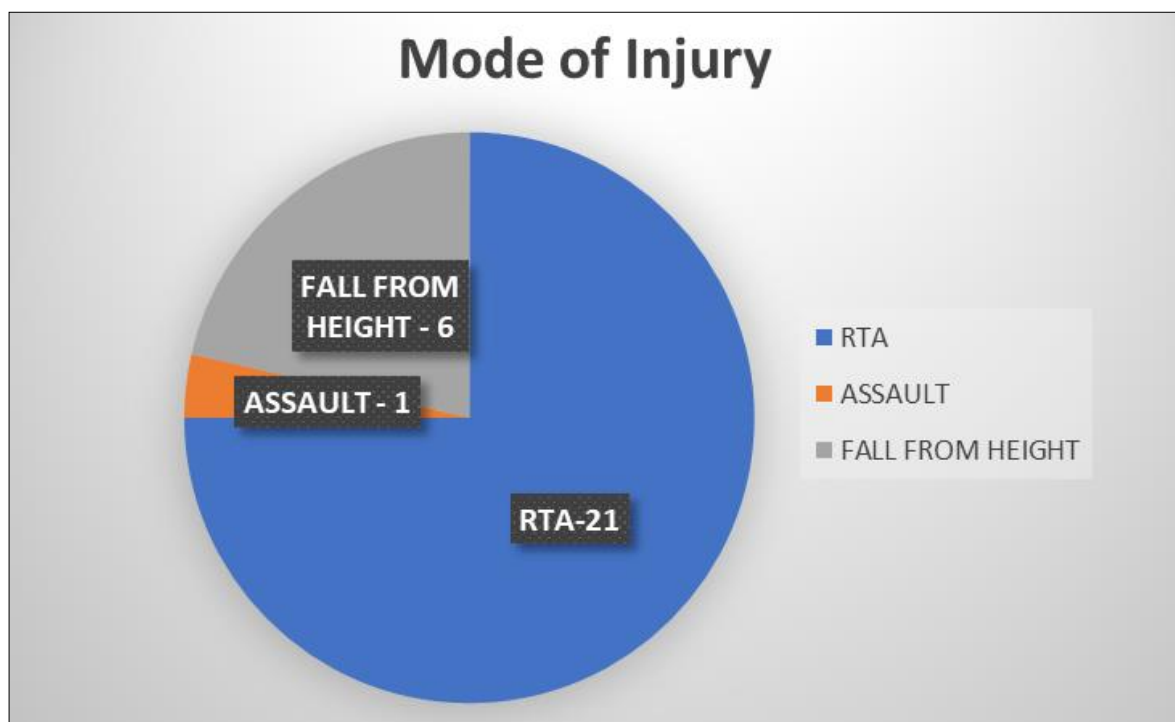


Fig 1: Distribution of mode of injury among the patients

Table 1: Results of the study

Procedure	Age (Mean)	Sex		Mode of injury			Fracture type			Side	Duration of surgery (mean)	Union (mean)	Blood Loss (mean)	Knee Rom	AKSS Score (mean)	Complication
		M	F	RTA	Self-fall	Assault	A1	A2	A3							
Retrograde nailing (N=28)	48.7 years	21	7	21	6	1	15	9	3	R	89.64 MIN	10.5 Weeks	224.2 ML	0-81 Degree	70.36%	Shortening – 4 Knee pain – 4 Knee stiffness – 2 Infection - 2

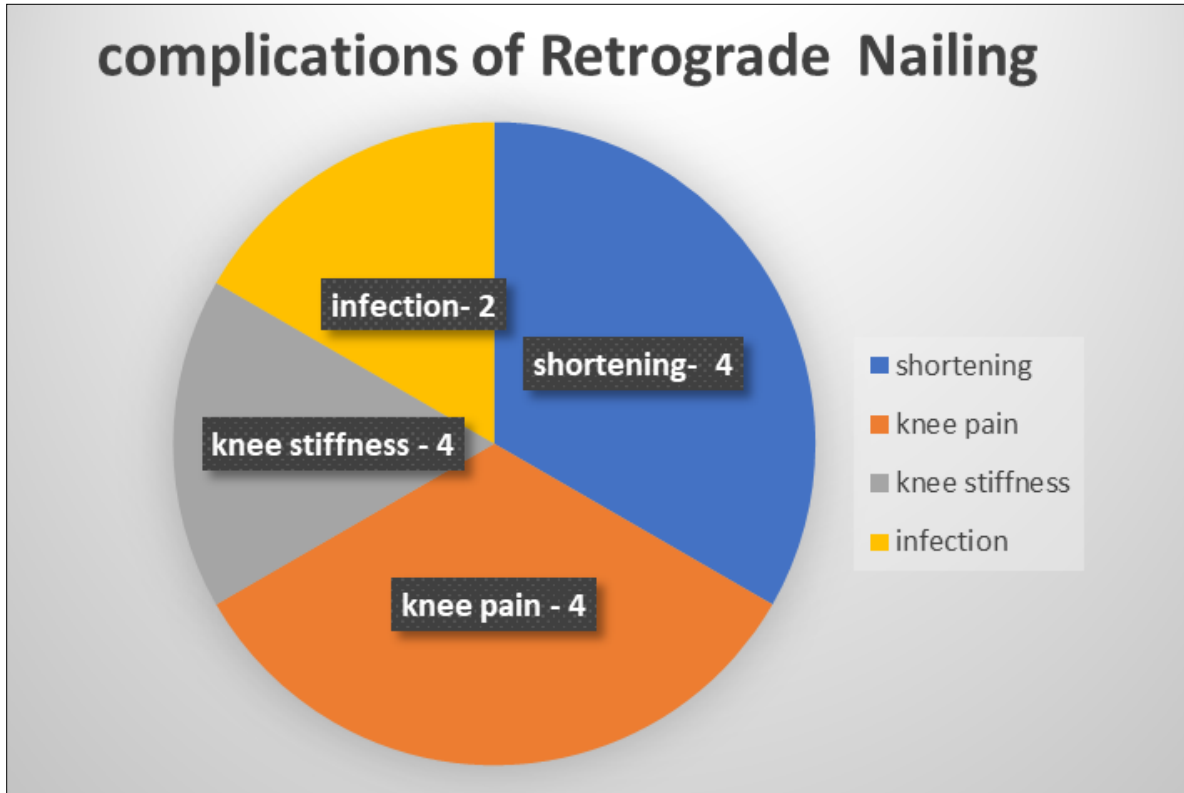


Fig 2: Distribution of complication of retrograde nailing

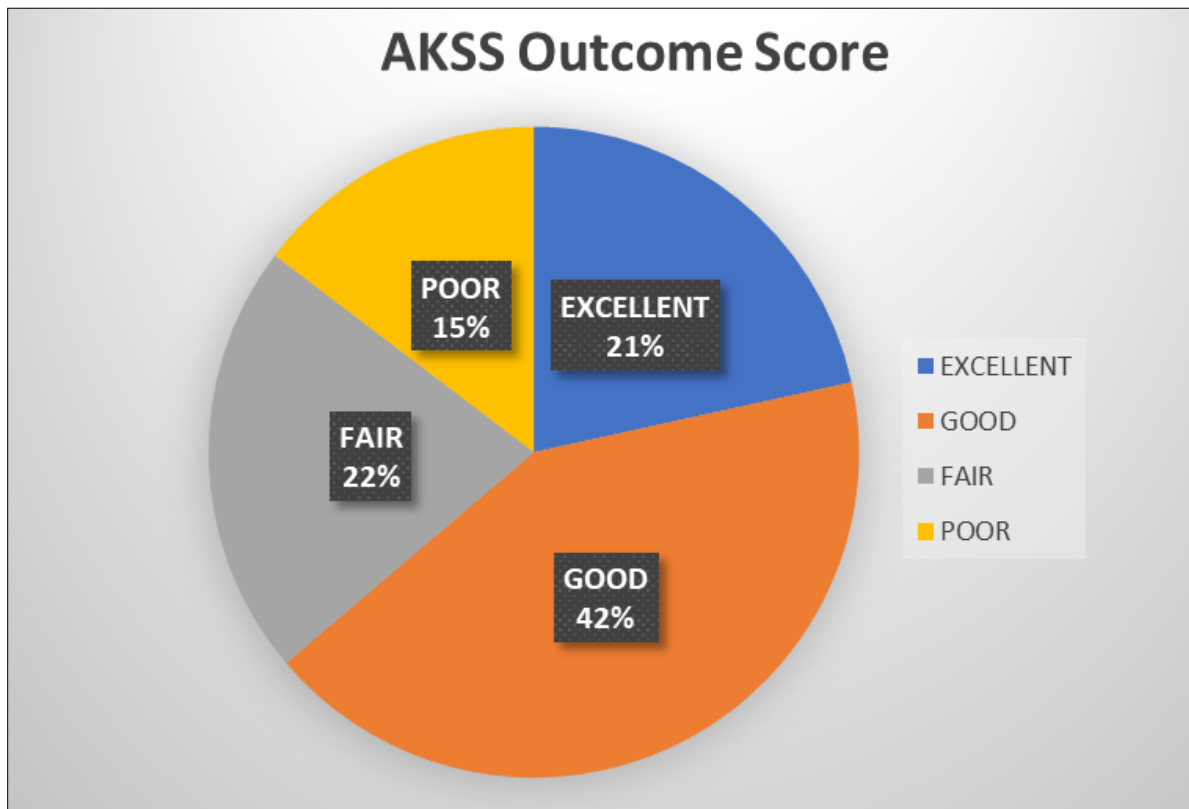


Fig 3: AKSS outcome score at 3 months

Table 2: Patients demographics and data

S.no	Age	Sex	Mode of Injury	Type	Open Closed Injury	Affected Side	Operative time (min)	Union in weeks	Blood Loss	KNEE Rom Flexion	AKSS	AKSS	Complication	Outcome
									(ML)		At 3 month	At 6 Months		
1	56	M	RTA	A2	closed	Lt	125	10	320	10°-110°	82	86	Knee pain	Excellent
2	45	M	RTA	A1	Open Gr II	Rt	115	12	350	10°-95°	75	79	Shortening	Good
3	62	M	Fall	A1	closed	Rt	95	13	380	10°-60°	65	72	no	Fair
4	58	F	Fall	A2	closed	Lt	100	11	400	10°-105°	80	87	no	Excellent
5	48	M	RTA	A2	closed	Rt	105	12	370	10°-110°	83	90	no	Excellent
6	62	F	Fall	A1	closed	Lt	120	13	330	10°-50°	62	69	Stiff knee	Fair
7	32	M	RTA	A3	closed	Lt	135	10	360	10°-85°	72	77	no	Good
8	44	M	RTA	A1	Open gr IIIA	Rt	110	15	350	30°-50°	37	52	Infection	Poor
9	47	M	RTA	A1	closed	Rt	95	16	330	20°-40°	36	48	Infection	Poor
10	52	M	RTA	A2	closed	Lt	100	10	380	10°-80°	74	82	no	Good
11	50	M	RTA	A1	closed	Rt	125	13	320	10°-60°	61	68	Stiff knee	Fair
12	45	F	RTA	A2	closed	Lt	110	10	375	10°-80°	71	77	no	Good
13	40	M	RTA	A1	closed	Rt	105	14	350	10°-95°	77	75	no	Good
14	53	M	RTA	A2	closed	Rt	100	11	390	10°-85°	72	83	Stiff knee	Good
15	41	M	RTA	A1	closed	Rt	90	10	250	10°-95°	70	75	Knee pain	Good
16	43	M	RTA	A1	Open grII	Lt	85	8	220	10°-105°	83	92	Shortening	Excellent
17	35	M	Assault	A1	IIIA	Lt	85	10	230	10°-90°	82	88	no	Excellent
18	59	F	Fall	A1	closed	Rt	95	9	200	10°-100°	80	85	no	Excellent
19	42	M	RTA	A2	closed	Rt	70	10	200	10°-95°	71	77	no	Good
20	62	F	Fall	A3	closed	Rt	80	12	250	10°-105°	72	79	no	Good
21	62	F	RTA	A2	closed	Lt	75	10	220	10°-100°	74	81	no	Good
22	32	M	RTA	A3	OPEN Gr II	Rt	180	12	200	20°-30°	57	72	Shortening	Poor
23	44	M	RTA	A1	closed	Rt	80	8	220	20°-50°	57	65	Infection	Poor
24	47	M	RTA	A2	Open Gr I	Lt	85	14	240	20°-40°	62	68	Stiff knee	Fair
25	54	M	RTA	A3	closed	Rt	80	12	230	10°-70°	65	71	no	Fair
26	50	F	RTA	A2	closed	Rt	90	11	210	10°-60°	66	75	Knee pain	Fair
27	64	M	Fall	A1	closed	Lt	85	10	250	10°-105°	72	79	no	Good
28	35	M	RTA	A1	closed	Rt	75	11	220	10°-100°	74	84	no	Good

Conclusion

In conclusion, retrograde intramedullary nailing has emerged as a reliable and effective treatment option for distal femur fractures, both extra-articular and intra-articular. The technique offers several advantages, including a minimally invasive approach, closed reduction techniques, and preservation of the soft tissue envelope. The use of retrograde nails allows for indirect fracture reduction, maintaining the physiological valgus angle of the femoral condyle and shaft. Biomechanical studies have demonstrated the stability provided by long nails reaching the intertrochanteric region. Clinical studies have shown high union rates, shorter operating times, and reduced blood loss with retrograde nailing. Complication rates, including infection, implant failure, and knee-related issues, have generally been low. However, careful attention should be paid to proper nail insertion depth, avoiding joint space intrusion and ensuring adequate proximal locking. While long-term effects of trans-articular nail insertion remain uncertain, retrograde nailing is considered a reliable alternative for the treatment of distal femur fractures, particularly in extra-articular cases.

Declarations

Funding

None

Conflict of Interest

The authors declare that they have no known competing financial interests or personal relationships that could have appeared to influence the work reported in this paper.

Ethical Approval

Not required

References

- Arneson TJ, Melton LJ, Lewallen DG. Epidemiology of diaphyseal and distal femoral fractures in Rochester, Minnesota, 1965- 1984. *Clin Orthop*. 1988;234:188-94.
- Court-Brown CM, Caesar B. Epidemiology of adult fractures: a review. *Injury*. 2006;37(8):691-7.
- Charles S Neer. Supracondylar fracture of adult femur. *JBJS American volume*, 1967 Jun;49-A:4.
- Schatzker J, Home G, Waddell J. The Toronto experience with the supracondylar fracture of the femur, 1966-72. *Injury*. 1974;6(2):113-128.
- Albert MJ. Supracondylar Fractures of the Femur. *J Am Acad Orthop Surg*. 1997;5(3):163-171.
- Jahangir AA, Cross WW, Schmidt AH. Current management of distal femoral fractures. *Current Orthopaedic Practice*. 2010;21(2):193-7.
- Kregor PJ, Stannard JA, Zlowodzki M, Cole PA. Treatment of distal femoral fractures using the less invasive stabilization system: Surgical experience and early clinical results in 103 fractures. *J Orthop Trauma*. 2004;18(8):509-20
- Gurkan V, Orhun H, Doganay M, Salioglu F, Ercan T, Dursun M, *et al*. Retrograde intramedullary interlocking nailing in fractures of the distal femur. *Acta Orthop Traumatol Turc*. 2009;43(3):199-205.
- Handolin L, Pajarinen J, Lindahl J, Hirvensalo E. Retrograde intramedullary nailing in distal femoral fractures--results in a series of 46 consecutive operations. *Injury*. 2004;35(5):517-22.
- Hierholzer C, von Rueden C, Pötzel T, Woltmann A, Bühren V. Outcome analysis of retrograde nailing and less invasive stabilization system in distal femoral fractures: A retrospective analysis. *Indian J Orthop*.

- 2011;45(3):243-50.
11. Neubauer T, Ritter E, Potschka T, Karlbauer A, Wagner M. Retrograde nailing of femoral fractures. *Acta Chir Orthop Traumatol Cech.* 2008;75(3):158-166.
 12. Shin YS, Kim HJ, Lee DH. Similar outcomes of locking compression plating and retrograde intramedullary nailing for periprosthetic supracondylar femoral fractures following total knee arthroplasty: a meta-analysis. *Knee Surg Sports Traumatol Arthrosc.* 2017;25(9):2921-2928.
 13. Warner SJ, Achor TS. Intramedullary Nailing of Complete Articular Distal Femur Fractures. *Operative techniques in orthopaedics.* 2018;28(3):112-7
 14. Hoskins W, Sheehy R, Edwards ER, Hau RC, Bucknill A, Parsons N, *et al.* Nails or plates for fracture of the distal femur? Data from the Victoria Orthopaedic Trauma Outcomes Registry. *The bone & Joint Journal.* 2016;98(6):846-50.
 15. Rossas C, Nikolopoulos D, Liarokapis S, Platanitis I, Karatzas G, Aggelidis C, *et al.* Retrograde intramedullary nailing vs. plating in treatment of extrarticular distal femoral fractures: A comparative study. *Injury.* 2011;42(3):S20-S1.
 16. Pean CA, Konda SR, Fields AC, Christiano A, Egol KA. Perioperative adverse events in distal femur fractures treated with intramedullary nail versus plate and screw fixation. *Journal of orthopaedics.* 2015;12(2):S195-S9.
 17. Gao K, Gao W, Huang J, Li H, Li F, Tao J, *et al.* Retrograde nailing versus locked plating of extra-articular distal femoral fractures: comparison of 36 cases. *Med Princ Pract.* 2013;22(2):161-6.
 18. Gill S, Mittal A, Raj M, Singh P, Singh J, Kumar S. Extra Articular Supracondylar Femur Fractures Managed with Locked Distal Femoral Plate or Supracondylar Nailing: A Comparative Outcome Study. *J Clin Diagn Res.* 2017;11(5):19-23.
 19. Markmiller M, Konrad G, Südkamp N. Femur–LISS and Distal Femoral Nail for Fixation of Distal Femoral Fractures: Are There Differences in Outcome and Complications? *Clinical Orthopaedics and Related*
 20. Ricci WM, Streubel PN, Morshed S, Collinge CA, Nork SE, Gardner MJ. Risk factors for failure of locked plate fixation of distal femur fractures: an analysis of 335 cases. *J Orthop Trauma.* 2014;28(2):83-9.
 21. Henderson CE, Kuhl LL, Fitzpatrick DC, Marsh JL. Locking plates for distal femur fractures: is there a problem with fracture healing? *J Orthop Trauma* 2011;25(1):8-14.
 22. Acharya KN, Rao MR: Retrograde nailing for distal third femoral shaft fractures: a prospective study. *J Orthop Surg.* 2006;14(3):253-8
 23. Ostrum RF, Maurer JP: Distal third femur fractures treated with retrograde femoral nailing and blocking screws. *J Orthop Trauma.* 2009;23(9):681-4.
 24. Wenda K, Runkel M. Systemic complications in intramedullary nailing. [Article in German] *Orthopade* 1996;25(3):292-9.
 25. Leggon RE, Feldmann DD. Retrograde femoral nailing: a focus on the knee. *Am J Knee Surg.* 2001;14(2):109-18.
 26. Henderson CE, Lujan TJ, Kuhl LL, Bottlang M, Fitzpatrick DC, Marsh JL. Mid-America orthopaedic association physician in training award: healing complications are common after locked plating for distal femur fractures. *Clin Orthop Relat Res.* 2011;469(6):1757-65.
 27. Kregor PJ, Stannard J, Zlowodzki M, Cole PA, Alonso J. Distal femoral fracture fixation utilizing the Less Invasive Stabilization System (L.I.S.S.): The technique and early results. *Injury.* 2001;32(3):32-47. DOI: 10.1016/S0020-1383(01)00182-6
 28. Heiney JP, Barnett MD, Vrabec GA, Schoenfeld AJ, Bajj A, Njus GO. Distal Femoral Fixation: A Biomechanical Comparison of Trigen Retrograde Intramedullary (I.M.) Nail, Dynamic Condylar Screw (DCS), and Locking Compression Plate (LCP) Condylar Plate. *J Trauma.* 2009;66(2):443-9. DOI: 10.1097/TA.0b013e31815edeb8
 29. Putineanu D, Com S, Ciobota N-D. Comparative study of mechanical fixation of extreme distal femur fractures with plates and condylar intramedullary nails. *UPB Scientific Bulletin, Series D: Mechanical Engineering.* 2011;73(2):59-70.
 30. Wähnert D, Hoffmeier K, Fröber R, Hofmann GO, Mückley T. Distal femur fractures of the elderly-Different treatment options in a biomechanical comparison. *Injury.* 2011;42(7):655-9. DOI: 10.1016/j.injury.2010.09.009
 31. Zlowodzki M, Williamson S, Cole P, Zardiackas L, Kregor P. Biomechanical Evaluation of the Less Invasive Stabilization System, Angled Blade Plate, and Retrograde Intramedullary Nail for the Internal Fixation of Distal Femur Fractures. *Journal of Orthopaedic Trauma*
 32. Agarwal S, Udapudi S, Gupta S. To Assess Functional Outcome for Intra-Articular and Extra-Articular Distal Femur Fracture in Patients using Retrograde Nailing or Locked Compression Plating. *Journal of Clinical and Diagnostic Research.* 2018;12(3):21-4.

How to Cite This Article

Prabhakaran AK, Kumar AJ, Nizar AM, Sundar RA, Subash Y. Functional and radiological outcome of retrograde ILM nailing for distal femur fracture. *International Journal of Orthopaedics Sciences.* 2023;9(3):278-284.

Creative Commons (CC) License

This is an open-access journal, and articles are distributed under the terms of the Creative Commons Attribution-Non Commercial-Share Alike 4.0 International (CC BY-NC-SA 4.0) License, which allows others to remix, tweak, and build upon the work non-commercially, as long as appropriate credit is given and the new creations are licensed under the identical terms.