



International Journal of Orthopaedics Sciences

E-ISSN: 2395-1958
P-ISSN: 2706-6630
IJOS 2023; 9(1): 465-474
© 2023 IJOS
<https://www.orthopaper.com>
Received: 07-11-2022
Accepted: 13-01-2023

Somnath Ghosh
Senior resident, Department of
Orthopaedics, Peerless Hospitex
Hospital & BK Roy Research
Centre, Kolkata, West Bengal,
India

Buddhadeb Nayak
Senior Resident, Department of
Orthopaedics, Peerless Hospitex
Hospital & BK Roy Research
Centre, Kolkata, West Bengal,
India

Dhananjoy Bera
Consultant, Department of
Orthopaedics, Peerless Hospitex
Hospital & BK Roy Research
Centre, Kolkata, West Bengal,
India

Swarnendu Samanta
Senior consultant, Department
of Orthopaedics, Peerless
Hospitex Hospital & BK Roy
Research Centre, Kolkata, West
Bengal, India

Corresponding Author:
Somnath Ghosh
Senior resident, Department of
Orthopaedics, Peerless Hospitex
Hospital & BK Roy Research
Centre, Kolkata, West Bengal,
India

Functional outcome of diaphyseal fractures of humerus in adults treated with closed interlocking nails: A prospective study

Somnath Ghosh, Buddhadeb Nayak, Dhananjoy Bera and Swarnendu Samanta

DOI: <https://doi.org/10.22271/ortho.2023.v9.i1g.3328>

Abstract

Background: Diaphyseal fractures of humerus are common, representing 3% of all fractures and 20% of all humerus fractures. Though compression plate osteosynthesis is the gold standard, interlocking intramedullary nailing is also a reliable option. In this present study we evaluated the functional outcome of diaphyseal fractures of humerus treated with interlocking nails.

Materials and Methods: A total of 36 patients with diaphyseal fractures of humerus, selected between October 2020 to May 2021 were managed by closed interlocking nail of humerus. This was a prospective study and all patients were followed up to a minimum of 6 months. The primary outcome measures were functional outcome assessed using DASH Score (The Disabilities of the Arm, Shoulder & Hand Score) & Constant-Murley scoring system respectively. Secondary outcomes were intra-operative conditions such as operative time and blood loss and post-operative complications.

Results: The mean time of radiological union was 15.7 weeks ranging from 14-26 weeks. All 36 fractures were united including one delayed union which united at 26 weeks. In our series, 4 patients had post-operative shoulder stiffness including one prominent nail, 1 patient developed radial nerve neuropraxia which recovered in 8 weeks. All patients were evaluated on the basis of Constant Murley score for shoulder function and DASH score. In our study of 36 patients 69.4% got excellent results, 19.4% got good results, 8.3% got moderate/fair results and 2.8% got poor results.

Conclusion: Interlocking nailing is a relatively quick, minimally invasive, and biomechanically sound, cosmetically better method of internal stabilization of shaft humerus fractures with less union time, less infection and lesser threat to radial nerve and other complications. Besides it allows early mobilization. With correct anatomical knowledge, preoperative planning, good surgical techniques and postoperative rehabilitation interlocking humeral nailing is a viable option in the management of fracture shaft humerus promising excellent outcome.

Keywords: Diaphyseal fractures, humerus, closed interlocking nails, a prospective study

Introduction

Humerus is a long tubular bone connecting scapula in the shoulder and radius and ulna in the elbow. The diaphysis is the expanse distal to surgical neck and proximal to supracondylar ridge^[1].

Diaphyseal fractures of humerus are common, representing 3% of all fractures and 20% of all humerus fractures^[2, 3]. Age distribution is bimodal, first peak in 21 to 30 years age group, mostly young males due to high velocity trauma, and the second peak in 60 to 80 years age group, mostly older females due to trivial trauma^[4]. Most diaphyseal fractures are closed and simple, 3% to 5% presenting as open and 8% as pathological^[5].

Various modalities of conservative treatment such as hanging arm cast, velpau dressing, coaptation splint or U slab, shoulder spica cast, and most importantly functional bracing continues to be the mainstay for treatment with acceptable healing in more than 90% patients. But nowadays, due to immense improvement in surgical techniques and implants, together with increased demand of patients and treating surgeons on fast restoration of function with less pain, trend is shifting towards operative management^[6]. Though compression plate osteosynthesis is the gold standard in fracture fixation of shaft humerus, interlocking

intramedullary nailing is also a reliable option [7]. Plate fixation though offers higher union rate, involves extensive soft tissue stripping, interlocking nails on the other hand is advantageous as it involves minimal surgical exposure and soft tissue handling, good biomechanical fixation, lesser operating time, lesser infection rate (0.7%) and allows earlier mobilization [8].

In this present study we intent to evaluate the functional outcome of diaphyseal fractures of humerus treated with interlocking nails.

Applied surgical anatomy

- The entry point for humeral interlocking nailing is very close to the passage of bicipital tendon, which may be irritated if, the nail projects out.
- While exposing the entry point, we have to dissect the rotator cuff, which has to be carefully repaired.
- The entry point is intraarticular and hence may be associated with shoulder stiffness. The axillary nerve runs at a distance of 4.56 cms from the tip of the acromion. It may be injured while applying the lower of the proximal screws.
- The radial nerve runs very close to the middle two thirds of the bone in the radial groove. It may be injured by the fracture, or during reduction.

Aims and Objective

Aim

The aim of this study is to bring out certain facts which will help in assessing the functional outcome of interlocking nail osteosynthesis for diaphyseal fractures of humerus in adults.

Objectives

Primary

To study the functional outcome of diaphyseal fracture of humerus treated by closed interlocking nails in skeletally mature patients.

Secondary

1. To assess advantages and disadvantages of this procedure.
2. To assess the time of union of diaphyseal fractures of humerus treated with interlocking nails.
3. To assess the complication associated with this modality.
4. Assessment of results based on subjective parameters, objective parameters and clinical finding.

Secondary procedures performed (if any).

Materials and Method

Study Area

Department of Orthopaedics, Peerless Hospital and B. K. Roy Research Centre, Kolkata - 94, West Bengal.

Study Period

October 2020 to May 2021

Sample Size

This is a prospective clinical study done in the Department of Orthopaedics and traumatology, Peerless Hospital and B.K.Roy Research Centre, Kolkata, from OCTOBER 2020 to MAY 2021 on a sample size of 36.

Study Population

Adults with diaphyseal fracture of humerus who fulfill the following inclusion criteria were included in the study.

Sample Design

1) Patient selection

The study was conducted among the adult patients attending Orthopaedics out-patient department and emergency of Department of Orthopaedics, Peerless Hospital and B. K. Roy Research Centre, Kolkata - 94, West Bengal with primary isolated fracture of shaft of humerus.

2) Inclusion criteria

- Adult patients equal or more than 18 years of age with primary fracture shaft of humerus and history of trauma.
- Noncompliant patient for conservative treatment.
- Segmental fracture.
- Failed or unacceptable reduction for conservative treatment.
- Obesity / Pendular breast.

3) Exclusion criteria

- Age below 18 years of age.
- Patients who are medically unfit.
- Patients with local tissue condition making the surgery inadvisable.
- Associated previous surgery of humerus.
- Pathological fractures.
- Ipsilateral other bone fracture in the affected limb.
- Preexisting Shoulder and elbow pathology.
- Very narrow medullary canal.
- Those who are not willing to participate in the study through written consent.

Study Design

Institution based prospective study.

Study tools

- Roentgenogram
- General internal fixation instruments for fixation of fracture shaft of humerus
- Constant-Murley scoring system
- DASH Score

Parameters to study

Primary outcome

- a. Fracture union.

Operative details

- a. Duration of operation.
- b. Amount of blood loss.

Perioperative complications

- a. Iatrogenic neurological injury.
- b. Iatrogenic fracture site comminution.

Postoperative complications

- a. Infection.
- b. Shoulder impingement.
- c. Elbow impingement.
- d. Restriction of range of movement at shoulder and elbow.

Final outcome

- a. Need for metal work removal.
- b. Fracture healing time.
- c. Return to preinjury occupation.

History taking

A detailed and careful history was taken from each patient

and their relatives particularly emphasizing on the mode of injury. All the details were documented properly in respective case sheets.

Clinical examination

All patients were thoroughly examined clinically starting from the standard General Survey, Systemic and Local Examination. Methodical examination was done to rule out other fractures and other injuries.

Initial treatment

In all patients fracture was temporarily stabilized with Plaster of Paris U-Slab and arm pouch sling. It was made sure to stabilize the patient optimally and adequate pain management was undertaken. Medications for their existing comorbidities were continued.

Pre-operative evaluation

Standard radiographs (Digital) of the humerus including the shoulder and elbow joint i.e., anteroposterior and lateral views were done. Every patient underwent a standard set of investigations including blood for Hb%, TC, DC, ESR, sugar, urea, creatinine, Coagulation profile, Serum sodium and potassium, pre-op serology, chest x-ray (PA view) and ECG. Other essential investigations depending on the medical condition of the patient were also done.

Anaesthetic and medical clearance

All the surgeries were done after appropriate cardiological and medical evaluation and optimization. Proper pre anaesthetic checkup were done in every patients before posting for surgery.

Counselling and consent

All patients and their relatives were counselled to their satisfaction in their own language about the aim of this study, surgery, advantages and disadvantages, alternatives, possible complications and outcome of various procedures and informed consent were taken. After due consent and medical or anaesthetic clearance, the patients were posted for surgery.

Anaesthesia

General anaesthesia with endotracheal intubation

Patient positioning and draping

All patients were positioned supine on radiolucent table with shoulder at the edge of bed and C-arm was brought in from foot end

Nail length and diameter assessment

The length of nail taken 1 cm below the articular margin of humeral head to 2.5 cm above olecranon fossa. Diameter of the narrowest part of medullary canal was estimated with radiographic canal width estimator.

Approach

About 3 cm incision were made at the anterolateral margin of acromion. Subcutaneous tissue incised to expose deltoid fibres which was split to expose supraspinatus. Supraspinatus was sharply incised along the line of fibres and retracted gently to expose head of humerus.

Entry point and guide wire insertion

The guide wire is inserted through the opening in the supraspinatus tendon and entry point is confirmed under image intensifier in 2 planes. The ideal entry point is situated medial to the greater tuberosity, which is lateral to the axis of the medullary canal in the AP view and in line with the axis in the lateral view.

Approach

About 3 cm incision were made at the anterolateral margin of acromion. Subcutaneous tissue incised to expose deltoid fibres which was split to expose supraspinatus. Supraspinatus was sharply incised along the line of fibres and retracted gently to expose head of humerus.

Entry point and guide wire insertion

The guide wire is inserted through the opening in the supraspinatus tendon and entry point is confirmed under image intensifier in 2 planes. The ideal entry point is situated medial to the greater tuberosity, which is lateral to the axis of the medullary canal in the AP view and in line with the axis in the lateral view.

Opening entry portal

The entry portal is opened with cannulated AWL over the guide wire.

Nail assembly and insertion

The nail is mounted to insertion handle and Closed reduction done and nail passed through fracture site into the distal fragment, confirming the humeral shaft alignment, rotation and length, taking care that it is not proud proximally. When the medullary canal is too narrow we reamed the canal sequentially before nail insertion. We also used poller screws to aid in reduction.

Interlocking

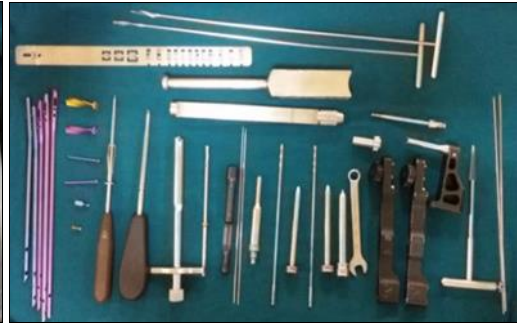Proximal interlocking is performed through the insertion handle from lateral to medial. Malrotation and/or distraction at the fracture site were corrected, prior to distal interlocking. Distal interlocking was done by freehand technique from anterior to posterior after splitting biceps and brachialis.

Closure

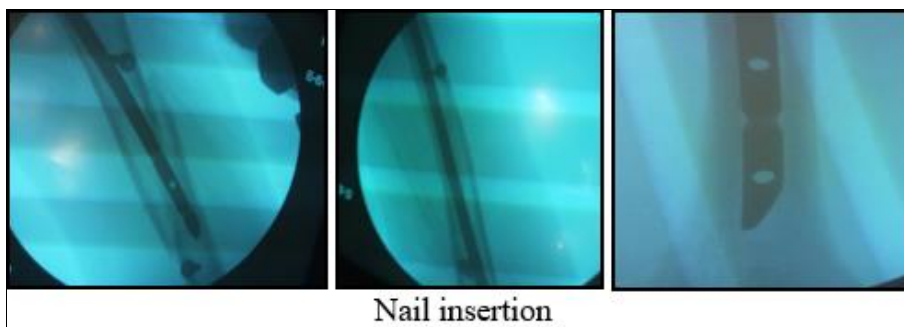
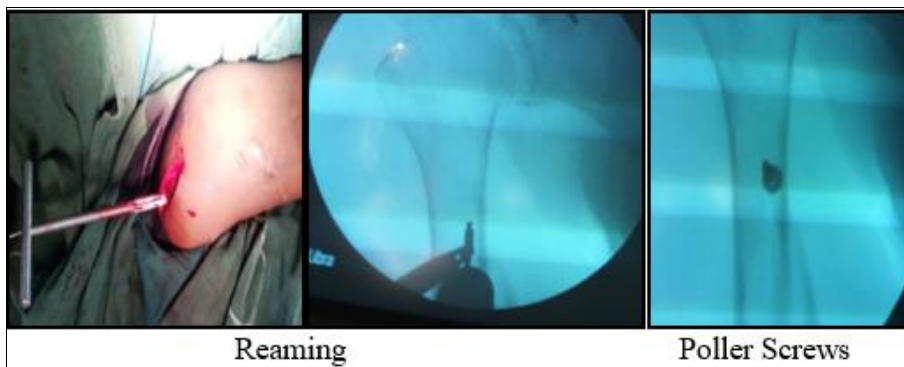

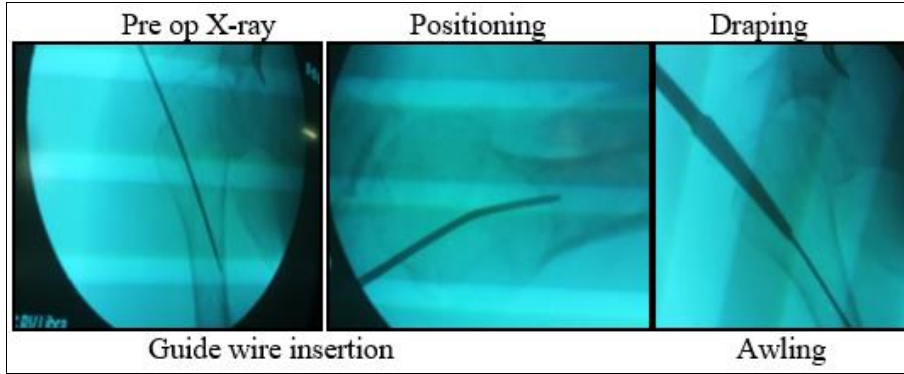
Supraspinatus tendon was repaired carefully with interrupted absorbable sutures. The deltoid, subcutaneous tissue, and skin are closed in layers separately

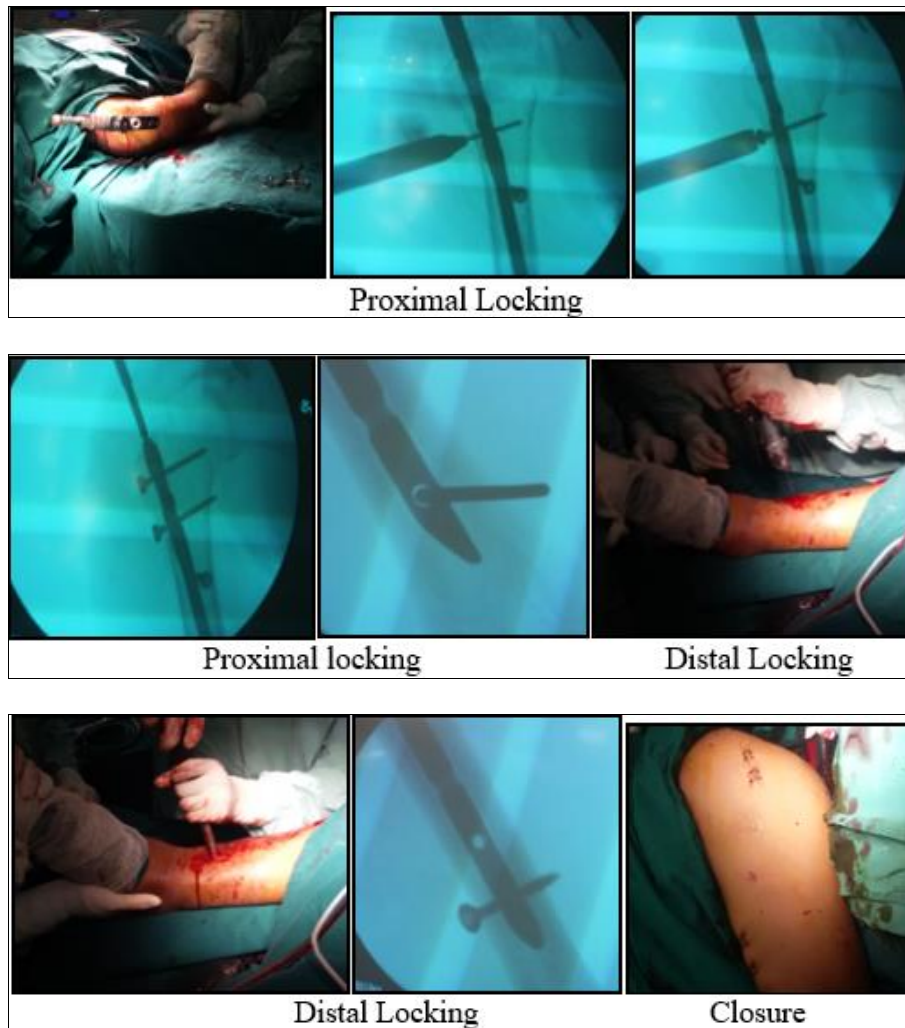


Instruments in tray



Instruments in trolley





After treatment

Postoperatively the patients were asked to move their fingers and wrist joint. Pendular exercises and elbow range of movement exercises to be started from the next day of surgery. Check dressing was done on 3rd postoperative day. They were prohibited from lifting weight or putting additional stresses on the affected limb. Patients were discharged usually on the 4th post-operative day with the arm in an arm pouch sling and advised to come for sutures removal on 14th post-operative day.

Follow up

All the patients were followed up at 2 weeks from date of surgery for removal of sutures. Subsequent follow ups were done at 6th week and then at 6 weeks interval till 6 months, then 3 monthly for next 6 months with a minimum period of 6 months follow up. On the follow up of 6th week, another X ray of whole length humerus including shoulder and elbow joint – AP & Lateral view was done to assess the process of union.

Statistical Analysis

All data were captured and analysed properly by using appropriate statistical tools. Then the functional outcome were assessed using DASH Score (The Disabilities of the Arm, Shoulder & Hand Score) & Constant-Murley scoring system.

Observations and Results

Our present study was conducted over 36 adult patients with fracture shaft humerus treated by closed reduction and internal fixation with intramedullary interlocking nail

(antegrade) between October 2020 to May 2021 at Peerless Hospital and B.K. Roy research centre. Fortunately no patients were lost in follow up.

Following observations were made in our study:

1. Age Distribution

Majority of humerus shaft fractures occurred in age group 21 to 40 years (55.6%). Age is significant in our study and outcome is worse in older age group.

2. Sex Distribution

In our study there were 23 males (63.9%) and 13 females (36.1%) showing male preponderance, but it was statistically not significant in terms of final outcome.

3. Injury Mechanism

In our series the most common mechanism of injury is direct trauma occurring in 25 cases out of 36 (69.4%).

4. Injury Mode

Out of 36 humerus fractures in our study, 21 cases (58.3%) were due to Road traffic accidents followed by domestic fall (19.4%). 5 cases were due to fall from height, while rest 3 cases were due to physical assault.

5. Fracture Site

Middle third fracture was most common (55.6%) in our series.

6. Fracture side

In our study left sided fractures are more common comprising

about 52.8% of total, but is insignificant statistically in final outcome.

7. Fracture Pattern

Majority of humerus shaft fractures in this study were tranverse fractures (61.1%), followed by oblique pattern (25%). However fracture pattern was not significant to functional outcome.

8. Associated Injuries

Mostly isolated humerus fractures, comprising 38.9% of 36 cases occurred in our study. Head injury was the most commonly associated injury (19.4%)

9. Associated Comorbidities

Though hypertension, diabetes mellitus, hypothyroidism and dyslipidaemia are major associated comorbidities they are not significant to our final outcome.

10. Constant murley components

Pain

32 patients (88.9%) did not experience pain during follow up. 3 patient's experienced mild pain, while only 1 patient developed moderate pain. Thus this finding was significant to outcome of our study.

11. Constant murley score

		Final Outcome		Total	P Value	Significance
		Moderate/ Poor	Good/Excellent			
Constant Murley Score	0-55	1(100)	0(0)	1(100)	<0.001	Significant
	56-70	3(100)	0(0)	3(100)		
	71-85	0(0)	7(100)	7(100)		
	86-100	0(0)	25(100)	25(100)		
Total		4(11.11)	32(88.89)	36(100)		

In our study 69.4% scored 86 or more in Constant Murley scoring system. 2.8% were below 55.

12. DASH SCORE (The disabilities of the arm, shoulder & hand score)

		Final Outcome		Total	P Value	Significance
		Poor/ Fair	Good/Excellent			
DASH SCORE	≥61	1(100)	0(0)	1(100)	<0.001	Significant
	41-60	3(100)	0(0)	3(100)		
	21-40	0(0)	7(100)	7(100)		
	0-20	0(0)	25(100)	25(100)		
Total		4(11.11)	32(88.89)	36(100)		

In our study 69.4% scored 20 or less in DASH scoring system. 2.8% were above 61.

13. Radiological union

		Final Outcome		Total	P Value	Significance
		Moderate/ Poor	Good/Excellent			
Radiological Union(weeks)	14 to 18 weeks	2(6.25)	30(93.75)	32(100)	0.006	Significant
	19 to 22 weeks	2(66.67)	1(33.33)	3(100)		
	> 22 weeks	0(0)	1(100)	1(100)		
Total		4(11.11)	32(88.89)	36(100)		

88.9% fractures in our study united between 14 to 18 weeks. Only one fracture took more than 22 weeks to unite.

14. Complications

Intraoperative complications

Bleeding: There was minimal bleeding as in all cases closed reduction was done.

Recreation

31 patients (86.1%) were able to enjoy recreational activities.

Sleep

Sleep was not affected in any patients due to humeral nailing in our study.

Work

33 patients (91.7%) were able to return to there pre trauma employment after humeral nailing

Arm Position

Most of the patients (88.9%) could position their arm upto head and above in our study. 8.3% cases could only position arm upto xiphoid process.

Internal Rotation

Internal rotation till twelfth thoracic vertebrae and beyond was possible in 22 cases (61.1%), but was not possible beyond Lumbo Sacral junction in 19.4% cases.

External Rotation

External rotation upto hand on top of head with elbow behind and above was possible in 22 patients in our study.

Postoperative complications

(a) Radial Nerve Palsy

There was one case of iatrogenic radial nerve palsy post operatively. In postoperative period, the cock up splint was used along with physiotherapy, passive exercises by patient himself was encouraged. This radial nerve palsy was

recovered in 8 weeks.

(b) Infection

There were no cases of wound infection.

(c) Stiffness

There were four cases of shoulder stiffness. One of them had prominent hardware (nail).

(d) Delayed union

There was one case of delayed union, which eventually united in 26 wks.

(e) Non-union

There was no case of nonunion and all fractures united.

15. Functional outcome

Constant murley score

Final functional outcome based on Constant Murley Scoring system in our study shows good to excellent results in 32 patients (88.8%) and poor to moderate results in 4 patients (11.1%).

DASH score

Final functional outcome based on DASH scoring system in our study shows good to excellent results in 32 patients (88.8%) and poor to moderate results in 4 patients (11.1%).

	Final Outcome		P Value	Significance
	Moderate/ Poor	Good/Excellent		
	Mean \pm Std. Deviation	Mean \pm Std. Deviation		
Age(years)	56 \pm 12.83	37 \pm 10.04	0.001	Significant
Interval between injury & surgery	4.5 \pm 1.73	3.13 \pm 1.26	0.056	Not Significant
Duration of hospital stay	6.5 \pm 2.38	5.34 \pm 2.89	0.450	Not Significant
Pain Score	8.75 \pm 2.5	15 \pm 0	<0.001	Significant
Unaffected Sleep Score	2 \pm 0	2 \pm 0		Significant
Full Recreation Score	0 \pm 0	3.88 \pm 0.71	<0.001	Significant
Full Work Score	1 \pm 2	4 \pm 0	<0.001	Significant
Strength of Abduction(pounds)	21 \pm 3.46	23.5 \pm 1.78	0.023	Significant
Abduction(degrees)	82.5 \pm 12.58	145.31 \pm 17.96	<0.001	Significant
Abduction	4.5 \pm 1	8.44 \pm 1.41	<0.001	Significant
Forward flexion(degrees)	87.5 \pm 17.08	148.44 \pm 14.83	<0.001	Significant
Forward flexion	4.5 \pm 1	8.69 \pm 1.09	<0.001	Significant
Constant Murley score	54.75 \pm 7.09	90 \pm 6.85	<0.001	Significant
Final DASH score	50.4 \pm 13.14	17.00 \pm 7.52	<0.001	Significant
Radiological Union(weeks)	18 \pm 4.62	15.5 \pm 2.83	0.129	Not Significant

Discussion

Our present study was conducted over 36 adult patients with fracture shaft humerus treated by closed reduction and internal fixation with intramedullary interlocking nail (antegrade) between October 2020 to May 2021 at Peerless Hospital and B.K. Roy research centre with the purpose of evaluating the functional outcome.

The data collected in this study is assessed, analyzed, compared with other series and the results are evaluated.

1. Age Incidence

Our results are comparable to studies of Sam G Hunter *et al.* [22], Griend RV *et al.* [18], Changulani M *et al.* [16]. So as humerus fracture affects the young and most active age group (20 to 40 years) it is quite justified to return them to their pretrauma status as early as possible through surgical intervention.

3. Mode of Injury

Series	Year	Total no. patients	Commonest mode of injury
McCormack RG <i>et al.</i> [15]	2000	44	MVA/RTA
Changulani M <i>et al.</i> [16]	2007	24	RTA
Fardeen sheriff <i>et al.</i> [17]	2018	30	RTA (60%)
C Current Study	2021	36	R RTA(58.3)

In this study the most common mode of injury is the road traffic accident which is similar to other studies. This implies that humerus fracture usually occurs due to high velocity trauma and indirectly implies that most of them are often associated with other injuries or polytrauma.

5. Fracture Pattern

Sex Incidence

In our study out of 36 patients, 23 were male (63.9%), showing male preponderance in humerus shaft fractures, which is consistent with other studies. The male predominance in the series can be attributed to the fact that most of the traumas were as a result of motor vehicular accidents and fall from height and males are more likely to be involved in such activities.

2. Side of Fracture

As compared to other studies mentioned, left sided humerus fractures appeared to be commoner than the right side. This may be due to human nature of protecting the dominant hand when possible or purely accidental.

4. Level of fracture

Like all the above mentioned studies, in our study also middle third fracture of humerus is most common. In our study 55.6% fractures were in middle third as compared to 60% and 63.9% by H T Tee *et al.* and Griend RV *et al.* respectively.

Series	Year	Total No. of Patients	Maximum fracture type	No. of cases	Percentage
Griend RV <i>et al.</i> [18]	1986	36	Transverse and short oblique	20	55.6
H T Tee <i>et al.</i> [20]	1998	35	Transverse	27	77.1
Tingstad EM <i>et al.</i> [14]	2000	83	Transverse and short oblique	53	64
Fardeen sheriff <i>et al.</i> [17]	2018	30	Oblique & Transverse	20	66.6
Current Study	2021	36	Transverse	22	61.1

6. Union Time

Series	Year	Average union time(weeks)
Demirel M <i>et al.</i> [21]	2005	13
Sahu RL <i>et al.</i> [23]	2015	15.7
Fardeen sheriff <i>et al.</i> [17]	2018	13
Current Study	2021	15.7

In our study union occurred between 14 to 26 weeks, with a mean union time of 15.7 weeks. Results matches exactly with series of Sahu RL *et al.* and are comparable with series of

Rodriguez-Merchan EC [13] and Demirel M *et al.* [20].

7. Union Rate

In our series out of 36 patients, there was only one delayed union and no nonunion, thus making the rate of union as 100% with similar results of Klenerman *et al.* [12] and Rodriguez- Merchan EC [13]. The delayed union in our study was possibly due to distraction at fracture site, however it united without any intervention.

8. Shoulder and elbow movement

Series	Year	No. of Patients	Full or Good mobility	Percentage
Changulani M <i>et al.</i> [16]	2007	24	24	100%
Khan AS <i>et al.</i> [24]	2010	30	19	63.3%
Fardeen sheriff <i>et al.</i> [17]	2018	30	29	96.6%
Current Study	2021	36	32	88.8%

In our study 88.8% (32 out of 36) had full or good shoulder and elbow movements which can be compared with study of Griend RV *et al.*

9. Constant Murley Score

Series	Year	Excellent/Good	Mean Score
Park JY <i>et al.</i> [10]	2008	-	84
Verdano MA <i>et al.</i> [9]	2013	79%	78.2
Baltov A <i>et al.</i> [11]	2014	83.7%	-
Current Study	2021	88.8%	86

In our study 88.8% has well to excellent shoulder function with a mean Constant Murley Score of 86. Park JY *et al.* also had similar shoulder outcome.

10. Results of IM Nailing in follow-up Studies

Authors	N	Method	Joint impairment* (%of cases)	Non-union (%)	Radial nerve # (%)	Infection (%)	Iatrogenic commination (%)
Sasahu RL <i>et al.</i> [23]	78	UHN(A)	0	4	-	0	-
Fffardeen sheriff <i>et al.</i> [17]	30	Interlocking nail (antegrade)	1	1	0	1	0
Current Study	36	UHN(A)	4	0	1	0	0

11. Clinical Results from Randomized Trials

Trial	Sample	Shoulder problems	Nonunion	Radial nv. Palsy	Infection	Reoperation
Chapman <i>et al.</i> 2000 [7]	38	6	2	1	0	0
McCormack <i>et al.</i> 2000 [15]	21	3	2	3	1	1
Putti <i>et al.</i> 2009 [19]	16	3	0	2	0	0
Fardeen sheriff <i>et al.</i> [17]	30	1	1	0	1	1
Current Study	36	4	0	1	0	1

The primary concern in antegrade humeral nailing beside fracture union is shoulder dysfunction. The reasons of the stiffness are protrusion of nail at the entry point, damage to the rotator cuff at the time of nail insertion, inadequate removal of bone debris after nailing and lack of patient's cooperation with the postoperative rehabilitative regimen. In the present series, out of the 4 patients having shoulder

stiffness one patient had protrusion of nail at entry point. Shoulder function improved after removal of nail. The other three were probably due to rotator cuff injury and lack of proper rehabilitation. The average time of return of full shoulder function was six weeks with adequate compliance to the rehabilitation.

Elbow function were excellent in all patients except minimal

restriction in 2 patients in our series, which improved with prolonged rehabilitative regime implying that antegrade nailing do not affect elbow function and do not violate normal elbow anatomy.

Our series has 100% union rate with average union time of 15.7 weeks. Only one case of delayed union was found, probably due to mild distraction at fracture site, secondary to larger diameter nail. Eventually it united at 26 weeks of

follow up with no intervention.

No cases of infection, superficial or deep, was recorded in our study.

One case of post-operative iatrogenic radial nerve neuropraxia occurred in our study, probably due to traction injury. It recovered fully at 8 weeks with postoperative cock up splint, passive exercises and supervised rehabilitation.

12. Final Outcome

Series	Year	Treatment Method	Excellent/Good Result
Tingstad EM <i>et al.</i> [14]	2000	DCP	94%
Changulani M <i>et al.</i> [16]	2007	DCP and I.M.Nail	87.5%
Verdano MA <i>et al.</i> [9]	2013	I.M. Nail	79%
Baltov A <i>et al.</i> [11]	2014	I.M. Nail	83.7%
Fardeen sheriff <i>et al.</i> [17]	2018	I.M.Nail	96.6%
Current Study	2021	I.M. Nail (UHN)	88.8%

In our study, 88.8% (69.4% excellent and 19.4% good) patients had good to excellent results. This is comparable to most previous studies. Thus though with limitations antegrade humeral nailing shows overall favourable outcome.

Conclusion

Our present study was aimed at evaluating the functional outcome of diaphyseal fractures of humerus in adults treated with closed interlocking nails. All data collected were assessed, analyzed, evaluated and following conclusion was made.

Humerus shaft fracture mostly affects the male population in the fourth decade of life occurring mainly due to direct trauma or road traffic accidents, thus often associated with polytrauma. They are usually transverse fractures, through the middle third with predominance of left side.

Though conservative treatment has been successful in the past and still holds good, operative management also delivers good outcome and early mobility. Plate osteosynthesis, regarded as the gold standard in operative management, are nowadays losing popularity to interlocking nails. The better designed interlocking nails with improved surgical techniques have promising results with several advantages. Interlocking nailing is a relatively quick, minimally invasive, and biomechanically sound, cosmetically better method of internal stabilization of shaft humerus fractures with less union time, less infection and lesser threat to radial nerve and other complications. Besides it allows early mobilization and early return to pre-fracture state. However, shoulder dysfunction is the primary limitation, which prevents its widespread use. Fortunately, with certain precautions such as proper rotator cuff dissection, countersinking of proximal nail tip, irrigation of debris from entry portal and early mobilization, together with appropriate rehabilitation, drastically decreases the insertion site morbidity, improving shoulder outcome significantly.

With correct anatomical knowledge, preoperative planning, good surgical techniques and postoperative rehabilitation antegrade interlocking humeral nailing is a viable option in the management of fracture shaft humerus promising excellent outcome. We hope that in days to come, through continued medical research further refinement in nail designs and surgical technique is possible, offering mankind a better quality of life.

Source of funding

None.

Conflict of interest

The authors declare no conflict of interest.

References

1. Mckee MD, Larsson S. Fractures of the shaft of humerus. In: Bucholz RW, Heckman JD, Court-Brown C M, Tornetta P. editors. Rockwood & Green's Fractures in Adults, 7th edition Philadelphia. Lippincott Williams & Wilkins. 2010. p. 1000.
2. Houwelingen AV, McKee MD. Management and complications of humeral shaft fractures. University of Toronto Medical Journal. 2004;81:96-102.
3. Igbigbi PS, Manda K, Epidemiology of humeral fractures in Malawi. Int Orthop. 2004;28:338-41.
4. Tytherleigh-Strong G, Walls N, McQueen MM. The epidemiology of humeral shaft fractures. J Bone Joint Surg Br. 1998;80:249-53.
5. Ekholm R, Adami J, Tidermark J, Tornkvist H, Ponzer S. Fractures of the shaft of the humerus: an epidemiological study of 401 fractures. J Bone Joint Surg Br. 2006;88- B:1469-73.
6. Strohm PC, Reising K, Hammer T, SÜdkamp NP, Jaeger M, Schmal H. Humerus shaft fractures – where are we today? Acta Orthopaedicae. 2011;78:185-189.
7. Chapman JR, Henley MB, Agel J, Benca PJ. Randomized prospective study of humeral shaft fracture fixation: Intramedullary nails versus plates. J Orthop Trauma. 2000;14:162-6.
8. Bhat SN, Rao SK. The functional outcome of antegrade unreamed humeral interlocking nailing in adults. J Orthopaedics 2005;2(1)e2.
9. Kurup H, Hossain M, Andrew JG. Dynamic compression plating versus locked intramedullary nailing for humeral shaft fractures in adults. Cochrane database syst rev. 2011 Jun, 15(6).
10. Verdano MA, Pellegrini A, Schiavi P, Somenzi L, Concar G, Ceccarelli F. Humeral shaft fractures treated with antegrade intramedullary nailing: What are the consequences for the rotator cuff? Int Orthop. 2013 Oct;37(10):2001-2007.
11. Park JY, Pandher DS, Chun JY, Md ST. Antegrade humeral nailing through the rotator cuff interval: A new entry portal. J Orthop Trauma. 2008 Jul;22(6):419-25.
12. Baltov A, Mihail R, Dian E. Complications after interlocking intramedullary nailing of humeral shaft fractures. Injury. 2014 Jan;45(1):S9-S15.

13. Klenerman L. Fractures of the shaft humerus. *Joint Bone Joint Surg Br.* 1966;48:105-111.
14. Tingstad EM, Wolinsky PR, Shyr Y, *et al.* Effect of immediate weight-bearing on plated fractures of the humeral shaft. *J Trauma.* 2000;49(2):278-280.
15. McCormack RG, Brien D, Buckley RE, McKee MD, Powell J. Fixation of fractures of the shaft of the humerus by dynamic compression plate or intramedullary nail. *J Bone Joint Surg Br.* 2000;82(3):336-9.
16. Changulani M, Jain UK, Keswani T. Comparison of the use of the humerus intramedullary nail and dynamic compression plate for the management of diaphyseal fractures of the humerus. A randomized controlled study. *Int Orthop.* 2007;31(3):391- 395.
17. Dr. Fardeen Sheriff, Dr. Shashikumar, Dr. Hareesha YS, Dr. Vikrant Kulkarni, Dr. Bhimanagouda Biradar, Dr. Ravishankar. The outcome of interlocking nailing of humeral shaft fractures, a one year hospital based study. *International Journal of Orthopaedics Sciences.* 2018;4(2):95-99. DOI: 10.22271/ortho.2018.v4 i2b.15
18. Van der Griend RA, Tomasin J, Ward EF. Open reduction and internal fixation of humeral shaft fractures. *J Bone Joint Surg Am.* 1986;68:430-433.
19. Putti AB, Uppin RB, Putti BB. Locked intramedullary nailing versus dynamic compression plating for humeral shaft fractures. *J Orthop Surg (Hong Kong).* 2009;17:139-41.
20. Hee HT, Low BY, See HF. Surgical results of open reduction and plating of humeral shaft fractures. *Ann Acad Med Singapore.* 1998 Nov;27(6):772-5.
21. Demirel M, Turhan E, Dereboy F, Ozturk A. Interlocking nailing of humeral shaft fractures. A retrospective study of 114 patients. *Indian J Med Sci.* 2005 Oct;59(10):436- 42.
22. Hunter SG. The Closed Treatment of Fractures of the Humeral Shaft. *Clin Orthop Relat Res.* 1982;164:192-98.
23. Sahu RL, Ranjan R, Lal A. Fracture Union in Closed Interlocking Nail in Humeral Shaft Fractures. *Chin Med J (Engl).* 5th. 2015 Jun;128(11):1428-1432.
24. Khan AS, Afzal W, Anwar A. Comparison of shoulder function, radial nerve palsy and infection after nailing versus plating in humeral shaft fractures. *J Coll Physicians Surg Pak.* 2010 Apr;20(4):253-7.

How to Cite This Article

Somnath G, Buddhadeb N, Dhananjay B, Swarnendu S. Functional outcome of diaphyseal fractures of humerus in adults treated with closed interlocking nails: A prospective study. *International Journal of Orthopaedics Sciences* 2023; 9(1): 465-474

Creative Commons (CC) License

This is an open access journal, and articles are distributed under the terms of the Creative Commons Attribution-NonCommercial-ShareAlike 4.0 International (CC BY-NC-SA 4.0) License, which allows others to remix, tweak, and build upon the work non-commercially, as long as appropriate credit is given and the new creations are licensed under the identical terms.