



# International Journal of Orthopaedics Sciences

E-ISSN: 2395-1958  
P-ISSN: 2706-6630  
IJOS 2023; 9(1): 392-395  
© 2023 IJOS  
<https://www.orthopaper.com>  
Received: 15-11-2022  
Accepted: 25-12-2022

**Govind Kumar Bhagat**  
Associate Professor,  
Department of Orthopedics,  
MPT Medical College,  
Siddharthnagar, Uttar Pradesh,  
India

**Vimal Dwivedi**  
Senior Consultant,  
Department of Orthopedics,  
District Hospital,  
Siddharthnagar, Uttar Pradesh,  
India

**Akash Kumar**  
Senior Resident,  
Department of Orthopedics,  
MPT Medical College,  
Siddharthnagar, Uttar Pradesh,  
India

## Functional result of diaphyseal fractures of femur managed by closed Intramedullary interlocking nailing in adults

Govind Kumar Bhagat, Vimal Dwivedi and Akash Kumar

DOI: <https://doi.org/10.22271/ortho.2023.v9.i1f.3321>

### Abstract

**Introduction:** Fractures of shaft of femur are among the most common fracture encountered in orthopedic practice in the road traffic accident.

The femur is the largest and strongest bone in the body articulating with hip joint proximally forming knee joint with tibia at its distal end. As industrialization and urbanization are progressing year to year with rapid increase in traffic. Incidence of high energy trauma increasing with same speed. Hence, the aim of the present study was to assess the treatment of unstable diaphyseal fracture femur with femur intramedullary interlocking nailing.

**Material and methods:** The present study was done among 15 patients where boot and bar traction in emergency was given. All routine investigation and surgical fitness were asked for intramedullary nailing was chosen for fracture shaft femur.

**Results:** About 73.3% fractures of the mid shaft femur was present. The pattern of fracture was found to be comminuted which was around 33.3%. The oblique pattern was around 26.6% and transverse pattern of fracture was observed to be 40%. The complications included were implant bending and breaking, infection, delayed and nonunion, rotational deformity.

**Conclusion:** Unstable diaphyseal fractures with femur intramedullary interlocking nailing gives excellent result with this system there are minimal complications which help early return of patients to activity and work.

**Keywords:** Closed interlocking nailing, femoral diaphyseal fractures, nails

### Introduction

Intramedullary nailing is one of the greatest advancement of the century in the treatment of femur fractures. Most of the development has come in last 25 years. Prior to these the use of intramedullary fixation was sporadic. The first instance was reported in the 16th century. It was observed that Aztecs and Incas used resinous wooden pegs in the intramedullary canal of the long bones in the treatment of non-unions. Ivory pegs were used by Bucher in 1886 and again in 1913 as reported by King of Germany. Haugland reported the use of bone rather than ivory pegs in 1917.

The spectrum of injury is so great that no single method of treatment is relevant to all diaphyseal fracture of femur because it is impossible to intervene surgically without further soft tissue damage, the technique chosen should have minimum soft tissue and bone damage. Out of the fracture of the lower extremities causing a lot of morbidity and mortality, most of these are a result of violent force and can be life threatening due to extensive haemorrhage in the thigh, open wounds, fat embolism, ARDS, or multi-organ failure. Most common are due to vehicular accidents. Many modalities of treatment have evolved over the years for these fractures.

A variety of intramedullary devices have been made including the Kuntscher and Ender nails to stabilize the femoral fractures however they are contraindicated for comminuted fracture as these tend to shorten, rotational instability or mal-alignment. In such fractures the recent introduction of intramedullary interlocking nails has greatly increased the scope of technique of intramedullary nailing. Excellent results have been obtained by using intramedullary interlocking nails.

**Corresponding Author:**  
**Govind Kumar Bhagat**  
Associate Professor,  
Department of Orthopedics,  
MPT Medical College,  
Siddharthnagar, Uttar Pradesh,  
India

Fracture is fixed with an intramedullary nails displayed higher values for blood flow in the whole bone and at the fracture site remained elevated for a longer time than those managed through rigid plate fixation. This finding correlates with increased peripheral callous with nail group but a delay in maturation of the fracture was noted in fracture treated with plating. It is postulated that even the reamed dust may have osteo-inductive properties causing endosteal callous formation.

Interlocking nails act as internal splint serving as load sharing device, stabilizing fracture fragments and maintaining alignment. Interlocking nail designed for static maintenance of the length also provides rotational stability by rigidity locking the nail to the bone both proximally and distally by use of bolts.

Mortality is infrequent but can result from open fractures, fat embolism, adult respiratory distress or multi organ failure especially in polytrauma patients. Both morbidity and mortality can be reduced by prompt reduction and internal fixation of fracture. Restoration of alignment, length and rotation, restoration of blood supply to aid union and rehabilitation are the objectives of the treatment. There are various options available for treatment of diaphyseal fractures of femur. The type and location of fracture, degree of comminution, age of the patient, patient's social and economic demands and other factors play a role in deciding the modality of treatment. Various treatment modalities includes closed reduction and spica cast immobilization, skeletal traction, femoral cast bracing, internal fixation with plates and screws, interlocked intramedullary nails."

The art and science of fracture management has tremendously advanced over the years. From use of external splints in Hippocratic age to recent sophisticated instrumentation, treatment of fracture has made an impact in surgical field.

With tubular anatomy of femur intramedullary nailing appears better than plating. Nailing can tolerate more torsional and bending forces better than plates. Being load sharing devices intramedullary nails cause less cortical osteopenia. Currently interlocked intramedullary nailing is considered to be most choice of treatment for femoral diaphyseal fractures. ! The goal of any fracture treatment is to obtain union of fracture in the most anatomical position compatible with maximum functional return of the extremity to the pre-injury state. Therefore, the aim of the present study was to assess the treatment of unstable diaphyseal fracture femur with femur intramedullary interlocking nailing.

## Materials and Methods

### Pre-Operative Management-

The present study was an experimental study done among 15 patients. After admission X-rays were taken in two planes AP and LAT views, including x-rays of ipsi-lateral hip joint and knee joint. Most of the patients were operated after fitness in all aspects with hb% 9gm%. Emergency treatment included, Inj. Fortwin IM to relieve pain. IV fluids and blood transfusion was given to combat any blood loss.

Associated injuries also adequately attended too.

Skin traction or upper tibial traction for skeletal traction was given with the link supported in a Bohler Braun splint.


All routine investigation and surgical fitness were asked for intramedullary nailing was chosen for fracture below the lesser trochanter and distally fracture within 8 cm from the femoral articular surface were chosen. For the shaft femur fracture following a trivial injury, pathological fracture were suspected and conditions like Pagel's disease, Fibrous

dysplasia, tumours were ruled out. Osteomalacia and osteoporosis are not contraindicated for intramedullary nailing, infact it was preferred to plating.

### Selection of Implants

The length of the nail was measured on the femur from the tip of the greater trochanter to the lateral joint line minus 2.5 cm. A preferable way of judging the length of the implant was by strapping the nail of appropriate size to the normal thigh and confirming the length by x-ray. The diameter is to be used was judged by the diameter of the medullary canal was measured from the x-ray and reducing 10% from it minus the magnification.

### Operative Technique



### Closed interlocking nailing showing good reduction and process of digital interlocking

Duly informed, valid consent was taken. General Epidural spinal was given at the discretion of the anaesthetist.

Extreme attention about maintaining the sepsis was taken preoperatively and intra-operatively. Shaving operative parts and private parts were done in evening before surgery. IV antibiotics were given a few hours before surgery.

The patient was given a lateral position and the operative parts were scrubbed with betascrub and Cetavalone for 10 minutes. Iliac crest of the same side was also prepared.

Painting followed by draping was done in such a way that only areas of skin incision were open. The help of stockinet, opsite and plastic drapes were also taken for the same the procedure used for the interlocking nailing was as follows;

Incision for the nailing starts at the greater trochanter and was carried 10cm proximally. Superficial and deep fascias were incised and the gluteus medius muscle was split. The pyriform fossa is identified as it gives a direct access to the femoral canal with the help of curved Awl a defect in the cortex was made flush to the greater trochanter in the posterior aspect of the pyriformis fossa, with care not to perforate the medial cortex. Reaming was done upto one size greater to the size of the nail to be inserted. A Steinman pin was passed through the lateral femoral condyle to assist traction.

Traction was given and at the same time an attempt to insert a guide wire mounted on "T" handle from the pyriformis fossa through the fracture site is made. Several attempts were made get a close reduction including using a thin Kuntscher nail or a thin interlocking in proximal fragment and confirm on an IITV or an x-ray. If close reduction was not possible an open reduction was using a lateral approach by reflecting vastus lateralis anteriorly to reach the fracture site. Reduction was achieved through minimal stripping of periosteum and the guide was passed through the fracture.

Modified AO nail, was used. The appropriate size of the nail

was attached to the jig and was introduced in to the medullary canal through the pyriform fossa over the guide wire, care was taken to ensure that the bowing of nail was maintained anteriorly, the nail was then hammered in the femur till it is flush to the greater trochanter. Initially it should be introduced so that the tip is just over the fracture site. For the shaft femur fracture following a trivial injury, pathological fracture were suspected and conditions like Paget's disease, Fibrous dysplasia, tumours were ruled out.

Osteomalacia and osteoporosis were not contraindicated for intramedullary nailing, infact it was preferred to plating.

Insertion of the interlocking screws -distal interlocking Distal locking was done with a distal aiming localizer, with holes that are exactly matching those of the nail. It can be fixed to the upper end of the nail lying in femur, now its length is adjusted according to the length of the nail used of sliding the knob that locks at a fixed length.

Proximal locking

The proximal cross screw was inserted in the standard manner. First a drill sleeve was inserted into the proximal and a 3.2 mm drill bit was passed down the drill sleeve into the bone, the length of the hole was measured with a special depth gauge and an appropriate sized screw (4.5) was passed after the cortices were tapped. The second interlocking was inserted in the same manner.

#### Post operative management

- Ceftriaxone and amikacin were given for 5days along with other medications. IV fluids, blood transfusion was done according to the blood loss during surgery.

- A. Patient already has 90 degree of flexion if the range cannot be achieved further.
  - B. Quadriceps was stretched eliminating the dead space anterior to the femoral shaft.
  - C. Static quadriceps and static glutei exercises were given.
- Bedside mobilization with quadriceps, strengthening was done after 48 hrs.
  - Suture removal was done after 12 days.
  - Toe touch immobilization on axillary crutches was begun after 3 weeks and full weight bearing mobilization once the fracture starts consolidating in about 6 to 8 weeks.

#### Statistical Analysis

- The data was entered into the Microsoft excel sheet and was analyzed with the help of SPSS software version 21. The descriptive statistics was applied in the form of percentages and was presented in the form of tables.

#### Results

The present study included 15 cases of interlocking for unstable diaphyseal fracture femur which was done using

- AO type nail with proximal locking jig and 2 proximal and 2 distal holes with a localizer. It was found that majority of the patients about 53.33% were from 31-40 years of age followed by 26.66% were from 41-50 years of age. The least age group involved were 61 years and above. Above 73.33% were males and 26.66% were females. The majority i.e. about 66.66% of the accidents were road traffic accidents followed by 33.33% direct injury due to fall.
- About 73.33% fractures involved middle 1/3 rd as the site of fracture. The pattern of fracture was found to be comminuted which was around 33.33%. The oblique pattern was around

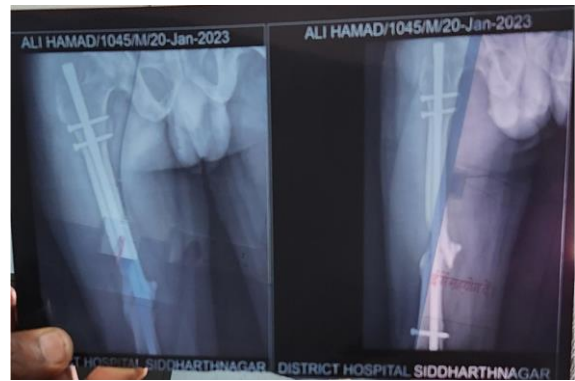Age in years	No. of patients	percentage
31-40 years	8	53.33%
41-50 years	4	26.66%
51-60 years	2	13.34%

Gender	No. of patient	percentage
Male	11	73.33%
Female	4	26.67%
Total	15	100%

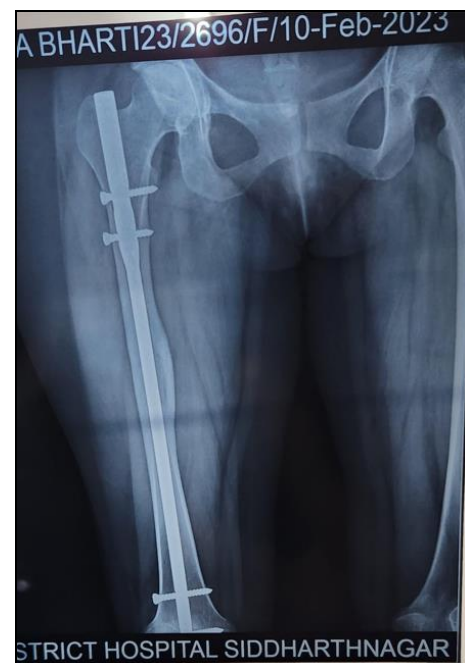Mode of injury	No. of patient	percentage
Road traffic accident	10	66.66%
Direct injury due to fall	5	33.33%

Site	No. of patients	percentage
Middle 1/3 shaft	11	73.33%
Lower middle 1/3	4	26.67%

Pattern of fracture	No. of patient	Percentage
Transverse	6	40%
Oblique	4	26.66%
Comminuted	5	33.33%



Comminuted fracture shaft femur showing excellent callus formation after close interlocking nailing



Excellent union after closed interlocking nailing after 4 months 26.66% and transverse pattern of fracture was observed to be 40%. The complications included were open reduction with bone grafting which was found to be 3 who developed non-union. The late complications breakage of

screws was present in 2 patients and non-union was present in 3 patients.

### Discussion

Close nailing can be achieved by manual traction given by the flexed knee with slight manipulation distal or at the site of fracture. Care must be taken in attempting a close nailing in comminuted fracture as the chances of rotational mal-alignment were high. While hammering the jig has tendency to loosen from the conical bolt leading damage to the bone as well as disturbing the rotations of the nail thus the nut of the bolt has to be regularly checked for loosening and tightening if necessary.

The intermedullary nail, with its location close to center of femur, can tolerate bending and torsional loads better than plates and the locking mechanism provides less tensile and shear stress than plates. The intra-medullary interlocking nail is a load –sharing device. It is less loaded than plates causing less cortical osteopenia of stress shielding, which is a feature of the load – bearing plates. Closed nailing technique is preferred because no damage to extra –periosteal soft tissue occurs and the biological environment around the fracture is minimally disturbed. Another important feature of the ambulation of the patient which reduces the complications of prolonged bed confinement.

The increase in popularity was due to locked intramedullary nails which allowed for improved rotational control, better maintenance of femoral length, early mobilization with weight bearing, and improved control of comminuted and segmental fractures. With closed techniques of nailing it also ensured the biological advantage of not opening the fracture site and hence helps in greater rates of fractures union.

The positive effects of reaming on fracture healing are thought to be from a combination of altered blood flow to the bone and the local muscles, and the deposition of marrow and cortical elements at the site of the fracture locking compression plates offer an alternative form of treatment. It has the advantage of avoidance of complications related to reaming, fat embolism. However plate fixation entails extensive surgical dissection with associated complications including blood loss, infections and soft tissue insult. Also, because the plate is a load bearing implant, implant failure is expected if union does not occur. Although implant failure will ultimately occur with any orthopedic device in the case of non-union, a load sharing implant will have increased longevity compared with a plate.

It was found from the study done by Arun Kumar *et al.* that there were 28 males and 12 females, showing male preponderance and this finding is similar to the finding of the present study where male ratio was found to be 73%. In the present study, common mode of injury was road traffic accidents. In the series of RC Meena *et al.*, showed that out of 108 cases, RTA was the mode of injury in 91 cases. In this study, transverse fracture pattern was predominant in 6 (40%) cases, followed by comminuted 5 (33%).

Fracture characteristics noted to have increased frequency of angular mal –alignment included fractures in the proximal or distal diaphysis, of increased degree of comminution, and those of the sub-acute treatment group who were treated greater than 4 weeks from their date injury. In a study done by Ricci *et al.* Found similar results, with proximal and distal fracture location and comminution being risk factors for mal –alignment.

The increased frequency of mal-alignment in patient treated more than 4 weeks from the date of injury is potentially indicative of operative issue associated with waiting for treatment. There is limited literature on risk of mal-alignment in this patient group, but the increased complexity and challenges involved in surgery for delayed union and aseptic

non-union in the femur is well documented.

### Conclusion

The intramedullary interlocking nailing of femur is a mode of definitive primary management of all diaphyseal fracture of femur. It does not allow collaps in severely comminuted fracture so that the length of the bone is restored and gives good results in severely comminuted fracture of femur.

### References

1. Whittle AP. Fracture of the lower extremity in: Canale ST, Beatty JH, editors. Campbell's operative orthopaedics. 11<sup>th</sup> ed. Philadelphia; Mosby publishers, 2008, 3190-217.
2. Nork SE. Fractures of shaft of the femur. Text book of fractures in adults, Rockwood and Green's, 6<sup>th</sup> ed, Philadelphia, USA: Lippincott Williams and Wilkins. 2006;1:1845-914
3. Johnson KD, Greenberg M. Comminuted femoral shaft fractures. Orthop Clin North Am. 1987;18:133-47.
4. Allen WC, Heiple KG, Burstein AH. Afluted intramedullary rod. Biochemical analysis and preliminary clinical results, J Bone and Joint Surgery. 1978;60:506-515.
5. Bankstone A, Keating M, Saha S. The Biomechanical evaluation of intramedullary nails in distal femoral shaft fracture. Clin Ortho. 1992;276:277-282.
6. Blumberg KD, Foster WC, Blumberg JF. A comparison of Brooker Wills & Russel Taylor nails for treatment of fracture femoral shaft J.B.J.S 1990;72:1019-1024.
7. Bone LB, Johnson KD, Weightelt Schienber J. Early versus delayed stabilization of femoral fractures –a prospective study. J.B.J.S, 1989, 336-340.
8. Bose W, Cores Anderson. A preliminary experience with Russel Taylor reconstruction nail for complex femoral fractures. J Trauma. 1992;32:7176.
9. Wolinsky PR, *et al.* Reamed intramedullary nailing of the femur; 551 cases. J Trauma. 1999;32:7176.
10. Hupel TM, Aksenov SA, Schemitsch EH. Cortical bone blood flow in loose and tight fitting locked unreamed intramedullary nailing : a canine segmental tibia fracture model. J Orthop Trauma. 1998;12:127-135.
11. Schemitsch EH, Turchin DC, Kowalski MJ, *et al.* Quantitative assessment of bone injury and repair after reamed and unreamed locked intramedullary nailing. J Trauma. 1998;45:250-255.
12. Aginsk J, Reais ND. The present state of medullary nailing of the femur: Biomechanical limitations and problems of blood supply to the fracture due to remaining injury. 1990;11:190-6.
13. Charles M, Brown C. An atlas of closed nailing of tibia and femur. Martin Dunitz Ltd. London, 1991.
14. Kenneth D, Johnson MD. Comminuted femoral shaft fractures. Orth clin North Am. 1987;1:112-6.
15. Thoresen BO. Interlocking intramedullary nailing in femoral shaft fractures. JBJS. 1985;67:655-69.

#### How to Cite This Article

Govind KB, Vimal D, Akash M. Functional result of diaphyseal fractures of femur managed by closed Intramedullary interlocking nailing in adults. International Journal of Orthopaedics Sciences 2023; 9(1): 392-395.

#### Creative Commons (CC) License

This is an open access journal, and articles are distributed under the terms of the Creative Commons Attribution-NonCommercial-ShareAlike 4.0 International (CC BY-NC-SA 4.0) License, which allows others to remix, tweak, and build upon the work non-commercially, as long as appropriate credit is given and the new creations are licensed under the identical terms.