



International Journal of Orthopaedics Sciences

E-ISSN: 2395-1958
P-ISSN: 2706-6630
IJOS 2023; 9(1): 71-75
© 2023 IJOS
<https://www.orthopaper.com>
Received: 01-10-2022
Accepted: 06-11-2022

Dr. PS Arun Vignesh
M.S (Ortho), Department of
Orthopaedics, Saveetha Medical
College & Hospital, Thandalam,
Kancheepuram, Tamil Nadu,
India

Dr. V Aakash
M.S (Ortho), Department of
Orthopaedics, Saveetha Medical
College & Hospital, Thandalam,
Kancheepuram, Tamil Nadu,
India

Dr. Adhishwaran Kumaran
M.S (Ortho), Department of
Orthopaedics, Saveetha Medical
College & Hospital, Thandalam,
Kancheepuram, Tamil Nadu,
India

Dr. G Vignesh
M.S (Ortho), Department of
Orthopaedics, Saveetha Medical
College & Hospital, Thandalam,
Kancheepuram, Tamil Nadu,
India

Dr. Yeshwanth Subash
Professor, Department of
Orthopaedics, Saveetha Medical
College & Hospital, Tamil Nadu,
India

Corresponding Author:
Dr. Yeshwanth Subash
Professor, Department of
Orthopaedics, Saveetha Medical
College & Hospital, Tamil Nadu,
India

Comparison of functional outcome between the SHS and CC screws for fixation of fracture involving neck of femur in young adults: A prospective study

Dr. PS Arun Vignesh, Dr. V Aakash, Dr. Adhishwaran Kumaran, Dr. G Vignesh and Dr. Yeshwanth Subash

DOI: <https://doi.org/10.22271/ortho.2023.v9.i1b.3273>

Abstract

Background: Management of intracapsular fractures involving the neck region of femur in a young population should be done as an emergency to prevent avascular necrosis due to its precarious blood supply. This type of fracture can be fixed with either a CC screw or a SHS. The study aimed to evaluate and compare the functional outcome between the CC screw and a SHS after the fixation of these fractures.

Method: This was a prospective study of 30 patients who had traumatic neck of femur fractures conducted between January 2020 to December 2021. Patients were allotted into 2 groups. Group A was treated with cannulated cancellous screw fixation, Group B was treated with sliding hip screw fixation. Post-operatively, patients were under review for 1 year.

Results: This study had 13 males and 17 females with the left side commonly involved. The mean patient's age was 34.7 ranging from 22 to 46 years. RTA was a more common injury mode. The average surgery time for group A patients was 72.9 minutes and was 117.5 for group B. The average time for clinical union of fracture was 13 weeks for group A and 11.5 weeks for group B. The average postoperative Harris hip score was 86.5 for group A and was 84.5 for group B which is not statistically significant. Patients in the study were happy with the treatment and the outcome.

Conclusion: The fixation of fracture involving neck region of femur in younger patients using both the CC screws and a SHS showed no statistically better functional score or hip ROM with no significant complications but cannulated cancellous screw group was better in terms of average surgical duration and hospital stay.

Keywords: Neck of femur; CC screws; DHS; AVN

Introduction

A fracture in the proximal femur is more common reason for an Orthopaedic admission^[1]. The treatment for intracapsular neck fracture remains controversial^[2]. Fracture involving neck region of femur is less commonly seen in the young population since it requires considerable force to overcome the strength of the bone to cause a fracture which is commonly seen with causes like road traffic accidents & a fall from height. This type of fracture in young individuals is considered a surgical emergency due to the potential complications. The femoral head has a precarious blood supply that may be disrupted due to neck fracture. If it is not fixed adequately, chances of getting AVN of head of femur are high. Another problem is non-union of the fracture which may cause further morbidity and disability to the patient. To overcome these complications, the neck of femur fractures should be fixed adequately. The fracture fixation can be done using either cannulated cancellous screws or sliding hip screws. CC screw fixation is found to be less traumatic while SHS fixation is superior biomechanically^[3]. Cannulated cancellous screw's principle is interfragmentary fracture compression, while sliding hip screw's principle is controlled collapse of the fracture^[4]. In a case of non-union of fracture, there is no role for cannulated cancellous screw, but treatment with valgus osteotomy with sliding hip screw is highly beneficial for the outcome of the fracture. Hip replacement is the last resort for this fracture in a young patient^[5]. The purpose of the study is to compare the functional outcomes in the neck of femur fracture patients operated with cannulated

cancellous screw and those operated with SHS using visual analogue scale and Harris's hip score.

Methodology

Source of data

The data was collected from the patients visiting the Emergency Department & Department of Orthopaedics.

Study Period: The study was conducted from January 2020 to December 2021.

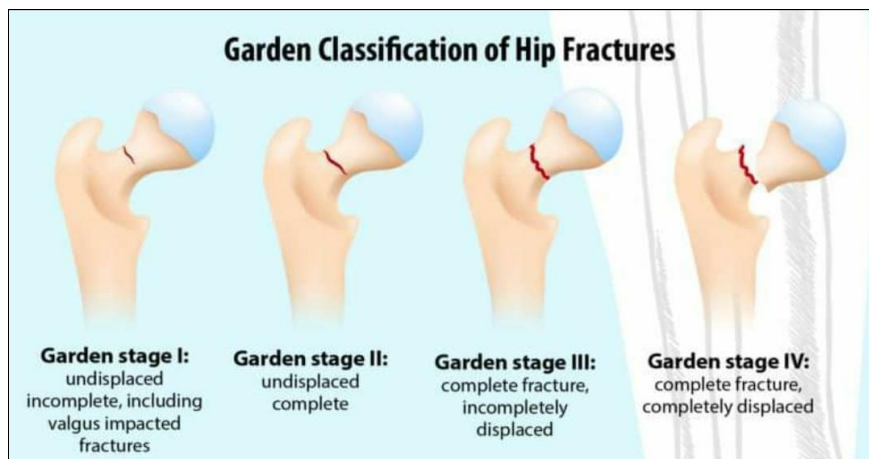
Study design: Prospective study.

Method of collection of data

Procedure

A study was done prospectively including 30 patients having fracture involving neck portion of femur in young patients studied between January 2020 to December 2021 at the Department of Orthopaedics in our institution. Patients who sustained neck of femur fracture aged from 20 to 50 years and who wanted for the treatment & review were included in the study, while pediatric patients, patients with more than 50 years of age, patients with old fractures and patients not willing to follow up were not included. All patients me to the

ER or orthopaedic department. Thorough history was taken regarding the details of the injury and elicited history to rule out any associated fractures, head/ chest/ abdominal injury. The vitals of the patient was monitored regularly. A physical examination was carried out. General examination of the entire body was done especially chest compression, spine tenderness. Local examination of the affected hip was done and findings such as the attitude of the limb, amount of shortening, tenderness over Scarpa's triangle, range of movements of joints of affected limb and examination to rule out any neurovascular injury was done. The patients were then radiologically evaluated and standard trauma series X-ray such as X-ray of chest anteroposterior view, X-ray pelvis with both hips anteroposterior view, X-ray C-spine anteroposterior & lateral views, X-ray of affected hip with traction and internal rotation and lateral views were taken. Routine blood tests were done. All fractures were classified using Gardens & Pauwels classification. Skin traction was applied with appropriate weight. The patients were allotted into two groups using lottery method. Group A underwent CC screw fixation. Group B underwent SHS fixation. The patients underwent surgery after obtaining informed consent & fitness for surgery.



All procedures were done under spinal/ general anaesthesia using antibiotic cover. Intravenous. Cefaperazone + Sulbactam 1.5 grams was given one hour before surgery & continued for 5 days postoperatively. The procedures were done by placing patient in supine position in a fracture table under C-arm guidance. Traction, external rotation then internal rotation was done to ring the fracture in place preoperatively and confirmed on AP and lateral views. A lateral approach was used for the exposure in both procedures. In CC screw fixation, after adequate exposure guide wires were inserted then drilling was done using it as a guide, 3 parallel CC screws were inserted in inverted triangle configuration to produce compression of the fracture. In SHS fixation, incision and exposure were larger when compared to CC screw fixation. A guidewire was inserted superiorly for the de-rotation screw and a de-rotation screw was inserted. A guidewire was inserted for the dynamic hip screw then after drilling through the guidewire, a dynamic hip screw of appropriate size was inserted till the subchondral level. Then a short barrel 4 holed plate was placed over the lateral cortex and held in place using four 4.5mm cortical screws. After both procedures, haemostasis was ensured. The wound was closed in layers and a sterile dressing was applied. The patients were made to sit upon the evening of the same day,

then started on the active ankle, knee mobilization and isometric quadriceps exercises. The patients were started on strict non-weight bearing walking with walking frame support. Post-operative X-rays were taken and the reduction was satisfactory. Periodic sterile dressing was done on the 2nd and 5th postoperative days. Removal of sutures was done on the postop day 12. After discharge, the patients reviewed at 1st, 3rd, 6th months. Radiological evaluation was done on each review and functional outcome was measured using Harris Hip score and documented. The data collected were analyzed using the 22.0 version of SPSS. Variables that are continuous were given as mean \pm standard deviation and variables that are categorical were given as percentages & numbers. The comparison of categorical variables was done using the Chi-square test. If P-value was less than 0.05 then it was taken as statistically significant.

Results

A group of 30 patients with fracture involving neck portion of femur treated with either cancellous screws or sliding hip screws was taken into this study between January 2020 to December 2021. The average age of patients was 34.7 (Fig.1).The study group had 13 gentlemen and 17 women (Fig.2).

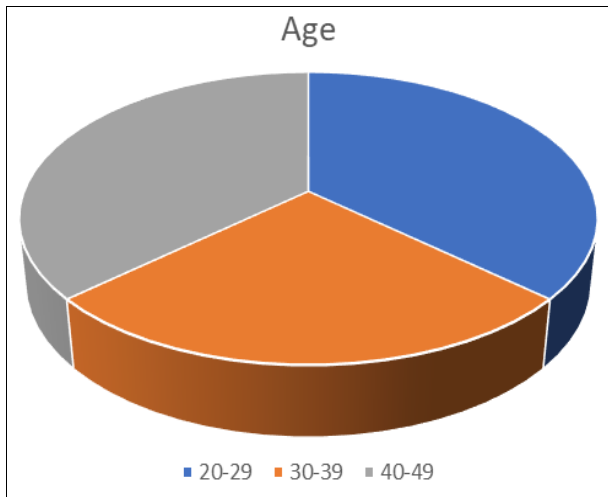


Fig 1: Age of the patients

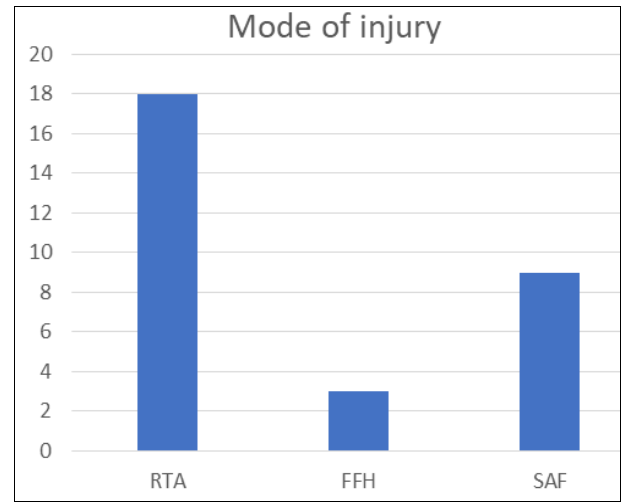


Fig 4: Mode of injury

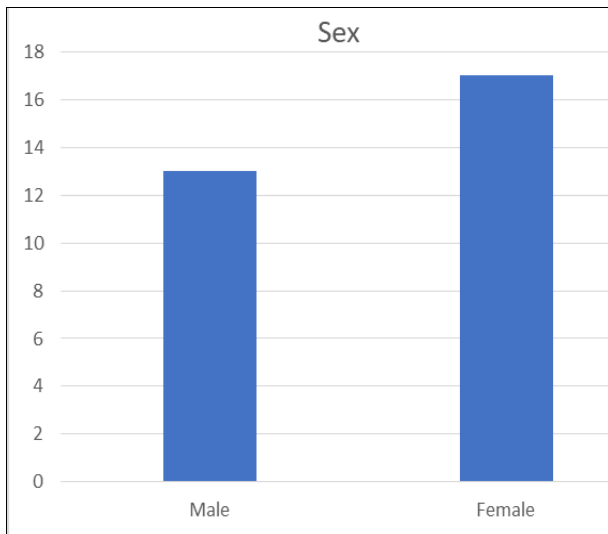


Fig 2: Gender distribution

Among 30 patients, the left side was more commonly injured accounting for 16 patients (Fig.3). RTA was more common injury mode accounting for 19 patients (Fig.4).

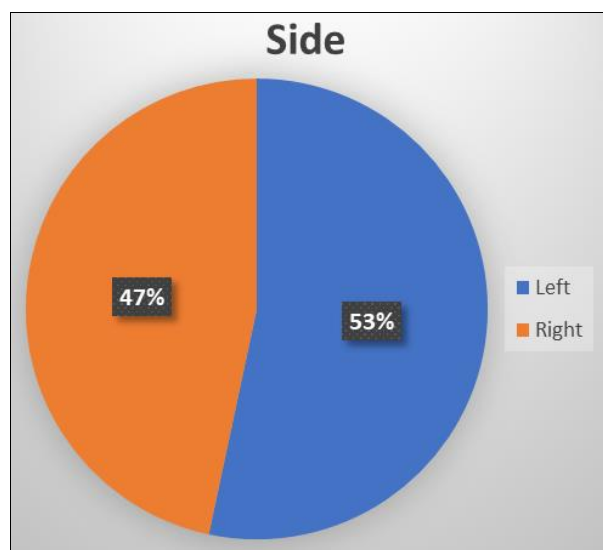


Fig 3: Side involvement

A group of 15 patients underwent CCS fixation and 15 patients underwent SHS fixation. With 15 patients, type 2 fractures of the femoral neck according to Gardens classification was more commonly seen in this study (Fig.5).

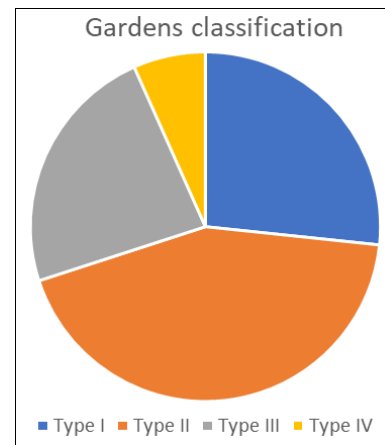


Fig 5: Gardens classification

The average preoperative Pauwels angle in the study was 41° ranging from 28° to 55°. The average surgery time for group A was 72.9 minutes and was 117.5 for group B. Hence, the average surgical time was statistically significant. The average loss of blood during group A was 180 millilitre and it was 230 millilitres for group B. The average stay in hospital was 7 days for group A and 14 days for group B which is statistically significant. The average time for clinical union of fracture was 13 weeks for group A and 11.5 weeks for group B. The average postoperative Harris hip score was 86.5 for group A and was 84.5 for group B. Postoperatively, 2 patients in group A had limb length discrepancy of 0.5 to 1cm which did not need a sole/heel raise and was tolerated well. All patients came back to pre-injury level after 16 weeks and had no pain or gait abnormalities. 3 patients in group B had superficial surgical site infection which resolved well after treating it with oral antibiotics. There were no other complications such as loss of reduction, screw backout or cut through, deep infection, chondrolysis or avascular necrosis. No patients was lost during review (Table.1).

Discussion

The management of fracture involving neck portion of femur in young population is an emergency procedure [6, 7]. In elderly individuals, the treatment of choice for this type of fracture would be a hip replacement [8, 9]. In young population, we have to try to salvage the femoral head and so arthroplasty is not the treatment of choice for them [10, 11, 12]. In an acute presentation of fracture involving neck portion of femur in young population, fixation with either CCS or SHS is the first choice of treatment [13, 14]. It is less traumatic and cost effective, provides the possibility of retaining femoral head which can provide improvement in function, and prevents the need for replacement. The surgery aims to adequately reduce the fracture and fix it to reduce the complications of intracapsular neck fractures like AVN of head or non-union [15, 16, 17]. The principle of cannulated cancellous screws is to produce interfragmentary compression between fragments and reduction of the fracture [18]. The principle of the SHS is controlled collapse of fracture after reduction [19, 20]. The reason of the study is to determine which treatment is better which is based on the reoperation rate and the occurrence of complications. Multiple factors were used to find which method is reliable. Those factors are surgical time, blood loss, hospital stay, time for clinical union, hip ROM, functional outcome using a visual analogue score and Harris hip score.

All the patients presented to our hospital at an average of 24 hours since the initial injury. The fracture involving neck portion of femur can be categorized using Garden's classification into 4 types or simply into Undisplaced or displaced. Type-II was more seen in the study. The average time for the clinical union was 13 weeks for group A and 11.5 weeks for group B. The average surgery time in group A was found to be significant statistically (p less than 0.05) compared to group B. The average hospital stay in group A was found to be significant statistically (p less than 0.05) compared to group B. By the end of 16 weeks, all the patients went to their pre-injury levels and were able to walk comfortably without pain. Limb length discrepancy of 0.5-1cm was seen in 2 subjects in the SHS group which was tolerated well without the need for sole/heel raise. No major complications were seen and no subjects were lost to follow up. All patients were elated with the outcome after the treatment.

Stockton *et al.* found that the failure of fixation of fracture involving neck portion of femur in patients aged 18–55 years and insisted that both SHS and CCS were similar in the rate of failure which is similar in our study [19]. However, the sliding hip screw had an association with cutout of screw because of cancellous trabeculae failure to prevent the femoral head rotation. The CC screws can fail by collapse in varus. Tolga Kaplan *et al.* concluded there was no superiority between both groups according to union times and functional results which was a similar conclusion to our study [5]. We had a union rate of 100% in our study with no implant failure or avascular necrosis at the last follow up. After reviewing with other studies, we concluded that there was nil significance statistically in various outcomes among both groups except group A had significantly lower surgical duration and hospital stay compared to group B. So, fixation of fracture involving neck portion of femur in young population in the acute setup to salvage the femoral head can be done using either the CC screws or the SHS with good fracture union, good functional results.

Conclusion

The fixation of fracture involving neck region of femur in younger patients using both the CC screws and a SHS showed no statistically better functional score or hip ROM with no significant complications but cannulated cancellous screw group was better in terms of average surgical duration and hospital stay.

Conflict of Interest

Not available

Financial Support

Not available

References

- Parker M, Johansen A. Hip fracture. *BMJ*. 2006;333(7557):27-30. <https://doi.org/10.1136/bmj.333.7557.27>
- Jettoo P, James P. Dynamic hip screw fixation versus multiple screw fixation for intracapsular hip fracture. *J Orthop Surg (Hong Kong)* 2016;24(2):146-149. <https://doi.org/10.1177/1602400204>
- Nauth A, Creek AT, Zellar A, Lawendy A-R, Dowrick A, Gupta A, *et al.* Fracture fixation in the operative management of hip fractures (FAITH): an international, multicentre, randomised controlled trial. *The Lancet* 2017;389(10078):1519-1527
- Gullberg B, Johnell O, Kanis JA. World-wide projections for hip fracture. *Osteoporos Int*. 1997;7(5):407-413
- Kaplan T, Akesen B, Demirağ B, Bilgen S, Durak K. Comparative results of percutaneous cannulated screws, dynamic compression type plate and screw for the treatment of femoral neck fractures. *Turk J Trauma Emerg Surg*. 2012;18(1):65-70
- Barnes R, Brown JT, Garden RS, Nicoll EA. Sub capital fractures of the femur. A prospective review. *J Bone Joint Surg Br*. 1976;58(1):2-24.
- Shah AK, Eissler J, Radomisli T. Algorithms for the treatment of femoral neck fractures. *Clin Orthop Relat Res*. 2002;399:28-34.
- Lu-Yao GL, Keller RB, Littenberg B, Wennberg JE. Outcomes after displaced fractures of the femoral neck. A meta-analysis of one hundred and six published reports. *J Bone Joint Surg Am*. 1994;76(1):15-25.
- Ly TV, Swiontkowski MF. Management of femoral neck fractures in young adults. *Indian J Orthop*. 2008;42(1):3-12. <https://doi.org/10.4103/0019-5413.38574>
- Dedrick DK, Mackenzie JR, Burney RE. Complications of femoral neck fracture in young adults. *J Trauma*. 1986;26(10):932-937.
- Yih-Shiunn L, Chien-Rae H, Wen-Yun L. Surgical treatment of undisplaced femoral neck fractures in the elderly. *Int Orthop*. 2007;31(5):677-682. <https://doi.org/10.1007/s00264-006-0243-3>
- Rogmark C, Carlsson A, Johnell O, Sernbo I. A prospective randomised trial of internal fixation versus arthroplasty for displaced fractures of the neck of the femur. The functional outcome for 450 patients at two years. *J Bone Joint Surg Br*. 2002;84(2):183-188.
- Rupprecht M, Grossterlinden L, Sellenschloh K, Hoffmann M, Puschel K, Morlock M, *et al.* Internal fixation of femoral neck fractures with posterior comminution: a biomechanical comparison of DHS(R) and Intertan nail(R). *Int Orthop*. 2011;35(11):1695-1701. <https://doi.org/10.1007/s00264-010-1199-x>

14. Dijkman BG, Kooistra BW, Pemberton J, Sprague S, Hanson BP, Bhandari M. Can orthopedic trials change practice? *Acta Orthop.* 2010;81(1):122-125. <https://doi.org/10.3109/17453671003587093>
15. Jain NB, Losina E, Ward DM, Harris MB, Katz JN. Trends in the surgical management of femoral neck fractures in the United States. *Clin Orthop Relat Res.* 2008;466(12):3116-3122. <https://doi.org/10.1007/s11999-008-0392-3>
16. Gupta M, Arya RK, Kumar S, Jain VK, Sinha S, Naik AK. Comparative study of multiple cancellous screws versus sliding hip screws in femoral neck fractures of young adults. *Chin J Traumatol.* 2016;19(4):209-212.
17. Higgins JP, Green S. *Cochrane handbook for systematic reviews of interventions.* The Cochrane collaboration and Wiley & Sons, Ltd; c2008. <https://doi.org/10.1002/9780470712184>
18. Moher D, Liberati A, Tetzlaff J, Altman DG, Group P. Preferred reporting items for systematic reviews and meta-analyses: the PRISMA statement. *J Clin Epidemiol.* 2009;62(10):1006-1012. <https://doi.org/10.1016/j.jclinepi.2009.06.005>
19. Hozo SP, Djulbegovic B, Hozo I. Estimating the mean and variance from the median, range, and the size of a sample. *BMC Med Res Methodol.* 2005;5:13. <https://doi.org/10.1186/1471-2288-5-13>
20. Fixation using Alternative Implants for the Treatment of Hip fractures I. Fracture fixation in the operative management of hip fractures (FAITH): an international, multicentre, randomised controlled trial. *Lancet.* 2017;389(10078):1519-1527. [https://doi.org/10.1016/S0140-6736\(17\)30066-1](https://doi.org/10.1016/S0140-6736(17)30066-1)

How to Cite This Article

Vignesh PSA, Aakash V, Kumaran A, Vignesh G, Subash Y. Comparison of functional outcome between the SHS and CC screws for fixation of fracture involving neck of femur in young adults: A prospective study. *International Journal of Orthopaedics Sciences.* 2023;9(1):71-75

Creative Commons (CC) License

This is an open access journal, and articles are distributed under the terms of the Creative Commons Attribution-NonCommercial-ShareAlike 4.0 International (CC BY-NC-SA 4.0) License, which allows others to remix, tweak, and build upon the work non-commercially, as long as appropriate credit is given and the new creations are licensed under the identical terms.