

E-ISSN: 2395-1958
P-ISSN: 2706-6630
IJOS 2022; 8(4): 119-125

www.orthopaper.com
Received: 08-08-2022
Accepted: 07-09-2022

Dr. S Ahamed Nazeer
Post Graduate, Department of Orthopaedics, Rajah Muthiah Medical College and Hospital, Chidambaram, Tamil Nadu, India

Dr. A Senthilnathan
Professor and Head, Department of Orthopaedics, Rajah Muthiah Medical College and Hospital, Chidambaram, Tamil Nadu, India

Dr. R Prabhakar
Lecturer, Department of Orthopaedics, Rajah Muthiah Medical College and Hospital, Chidambaram, Tamil Nadu, India

Corresponding Author:
Dr. S Ahamed Nazeer
Post Graduate, Department of Orthopaedics, Rajah Muthiah Medical College and Hospital, Chidambaram, Tamil Nadu, India

Functional outcome of total hip arthroplasty based on acetabular version on CT: A combined retrospective & prospective study

Dr. S Ahamed Nazeer, Dr. A Senthilnathan and Dr. R Prabhakar

DOI: https://doi.org/10.22271/ortho.2022.v8.i4b.3250

Abstract
Aim: To analyse the functional and radiological outcome of acetabular version in total hip replacement by Modified Harris Hip Score and by using 3D computed tomography respectively
Background: Proper placement and orientation of the acetabular components of a total hip replacement are important for the prevention of dislocation, early component damage, and decreased postoperative range of motion
Introduction: The version and the inclination of the acetabular component in THR are important for movement and stability and to reduce wear of the component. The dislocation rate and movements of hip are majorly depending on acetabular cup version.
Design: Prospective and Retrospective study
Materials and Methods: Initially 20 patients of Total Hip Replacements done in Government Cuddalore Medical College Erstwhile Rajah Muthiah Medical College and Hospital will be studied prospectively and retrospectively during the study period August 2020 to November 2022.
Result: This study reveals that acetabular component placed within the safe zone described by Lewinnek resulted in an excellent functional outcome and reduced complications. Harris Hip Score was used for assessment of functional outcome
Conclusion: Acetabular component placement plays a significant role in excellent functional outcome and prevention of complications.

Keywords: Acetabulum, Arthroplasty, Computed Tomography, Measurement, anteversion

Introduction

Proper and exact placements of acetabular and femoral components and its orientation in total hip arthroplasty are very important for the prevention of implant dislocation, premature component wear, and restricted postoperative range of motion [5, 8, 10,1 1]. To evaluate component orientation, variety of imaging techniques and measurement parameters were used. Intraoperative surgical estimates, postoperative radiographs, and computed tomography (CT) and magnetic resonance imaging (MRI) have all been used to evaluate arthroplasty orientation [1, 3, 4, 12, 15]. It is very much important to understand the definition of the terms to describe acetabular cup position, to discuss the evaluation of orientation in total hip arthroplasty.

Malpositioning of the acetabular components has been associated with impingement, dislocation, accelerated polyethylene wear, pelvic osteolysis, component loosening and migration. To avoid complications, the components should be implanted in a defined safe range. Great variations have been reported for the components' orientation which resulted in difference in the functional outcome post operatively using Modified Harris Hip Score. The main purpose of the present study is to investigate the variation and accuracy of version of acetabular component implanted using a manual technique and its functional outcome.

Materials and Methods

In this study we determine the associations between component version and functional outcome after Total Hip Arthroplasty, by reviewing CT scans of 20 primary total hip replacements in which manual technique was used for component placement.

There were 11 males and 9 females. The mean age at the time of surgery was 49 years (range, 23–75 years) at time of operation. 9 (45%) THAs were done in the patients' right hip and 11(55%) in the left. The indication for Total Hip Replacements included Secondary osteoarthritis of hip, Neck of Femur fracture, Non Union Neck of Femur fracture, Avascular Necrosis of Femoral head.

All replacement surgeries were done under spinal anaesthesia with the patient in lateral position using a posterior approach. The surgeons always stood on the patient's side for the insertion of acetabular component, and from the patient's posterior side for inserting the femoral stem .We determined the anteversion of the acetabular component by position of transverse acetabular ligament and anatomic elements of the acetabulum fossa. By using alignment guides provided with the implant, acetabular component kept in orientation for 20° anteversion and 45° vertical tilt. Femoral stem was inserted in the stable position possible for the anatomy of individual patients. Femoral Stem position was achieved by keeping the knee flexed to 90° and the leg in special orientation as a reference for anteversion. Postoperatively after one week each patient underwent a pelvic CT examination, and version of the acetabular and femoral components were measured.

The most commonly used method for defining acetabular version anatomically and radiographically [1, 6, 9, 11, 13, 18], is the modified Murray's concept, namely the "Acetabular component version defined as the angle between a line connecting the lateral anterior and posterior margins of the acetabular component and the sagittal plane defined as the plane perpendicular to a line connecting two identical points on either side of the pelvis .Computed Tomography is superior in evaluating the orientation of the acetabular cup component [1, 2, 12, 14, 16], and more accurate than intra operative surgical estimates or radiographs [17]. Axial CT image of the pelvis is used to define CT version of the acetabulum. A straight line is drawn connecting the most anterior and posterior points of the prosthetic acetabular cup. Version is described as the angle between the straight line described above and line drawn perpendicular to the line connecting two similar bony points on both side of the pelvis i.e the sagittal plane of the body. Anterior (anteversion) is defined when the angle opens to the front of the pelvis and posterior (retroversion) if it opens to the back of the pelvis [7, 17].

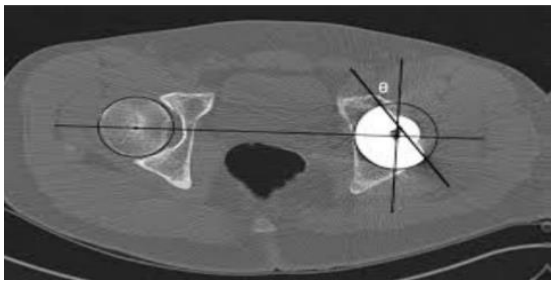

Fig 1: Acetabular anteversion

Femoral component version was calculated as the angle between a line from the center of the prosthesis' femoral neck to the centre of femoral head, and a line connecting the posterior aspect of both the femoral condyles, respectively.

Inclination of the acetabular component was measured using radiograph of anteroposterior view of pelvis with bilateral hip joint in supine position. The angle of the abduction component of acetabulum was measured with respect to a horizontal line through the bottom edge of the teardrops as recommended by Sutherland et al.[19] In order to minimize inter-observer variability, a single investigator performed all of the measurements

Inclusion Criteria

1. THR done during study period and within last 3 years
2. Both unilateral and bilateral THR patient.
3. Patients willing for follow-up

Exclusion Criteria

1. Patients with Knee Ankylosis
2. Patients with Severe Spine Kyphosis
3. Pregnant Mothers
4. Patient who underwent trauma to the operated side recently.
5. Patient with severe co-morbidities.
6. Patients not willing for study and follow up

Results

Table 1: Gender distribution

Gender	Number of patients	Percentage
Male	11	55
Female	9	45

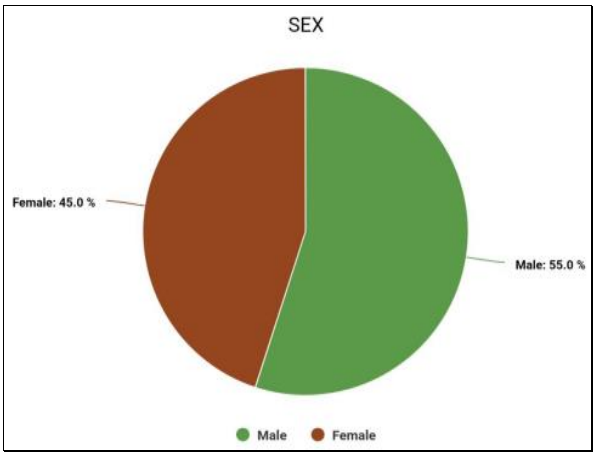

Chart 1: Gender distribution

Table 2: Age distribution

Variable	N	Min	Max	Mean	Std. Deviation
Age	20	23.00	66.00	49.65	9.467177

Age (in years)	No. of patients	Percentage
20 - 30	1	5
31 - 40	1	5
41 - 50	10	50
51 - 60	5	25
61 - 70	3	15
Total	20	100

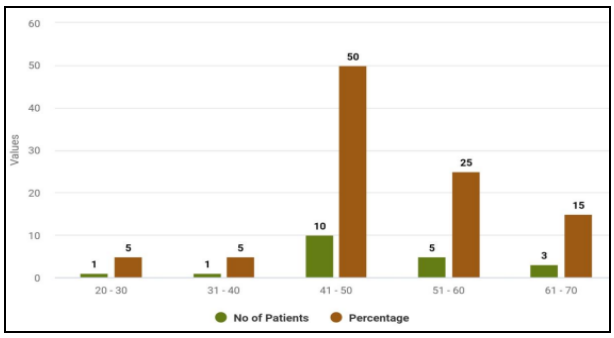

Chart 2: Age distribution

Table 3: Laterality

Side	No. of patients	Percentage
Left	11	55
Right	9	45

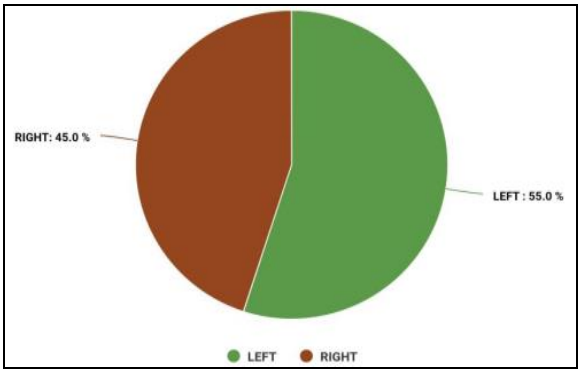

Chart 3: Laterality

Table 4: Modified Harris Hip Score

Variables	N	Min	Max	Mean	S. D
HHS	20	78.00	92.00	88.45	3.3791

Modified HHS	Score	No. of patients	Percentage
Excellent	90 - 100	10	50
Good	80 - 89	9	45
Fair	70 - 79	1	5
Total		20	100

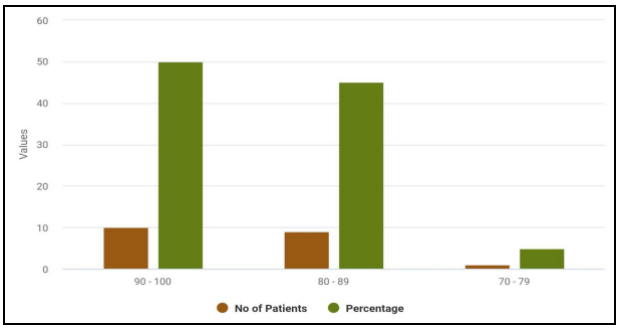

Chart 4: Modified Harris Hip Score

Table 5: Acetabular cup anteversion

Variables	N	Min	Max	Mean	S. D
Acetabular cup anteversion	20	10.4	29.7	20.95	5.468

Acetabular cup version [deg]	No. of patients	Percentage
10.0 - 12.5	1	5
12.6 - 16.5	4	20
16.6 - 22	7	35
22.1 - 25	3	15
>25	5	25
Total	20	100

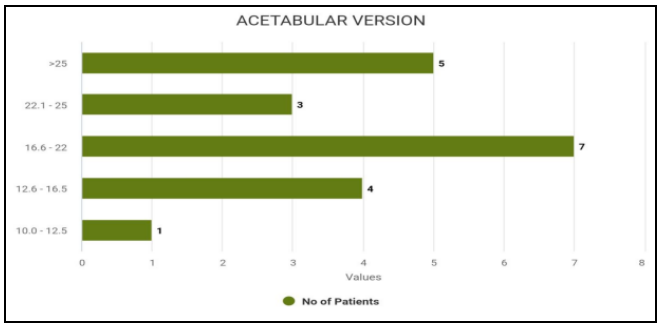

Chart 5: Acetabular cup anteversion

Table 6: Pain

Pain	No. of patients	Percentage
No pain	18	90
Mild pain	2	10

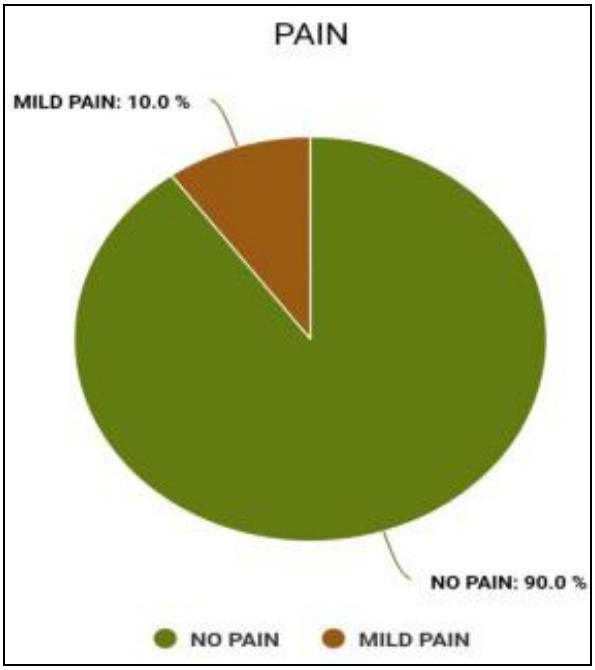

Chart 6: Pain

Table 7: Limping

Limp	No. of patients	Percentage
No limp	18	90
Moderate limp	2	10

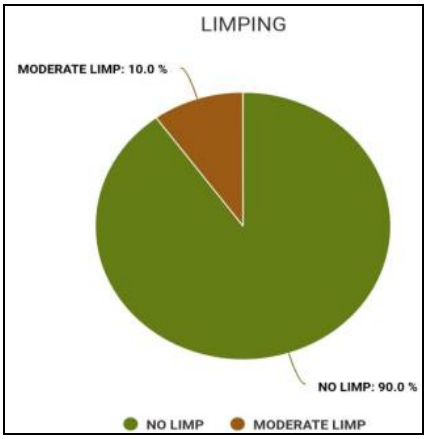

Chart 7: Limping

Table 8: Complications

Complication	No. of patients	Percentage
Dislocation of hip	Nil	0
Nil	20	100

Table 9: Indications in our study

Indications	No. of patients	Percentage
Neck of femur fracture	6	30
Avascular necrosis	4	20
Non union neck of femur fracture	4	20
Osteoarthritis	4	20
Others	2	10
Total	20	100

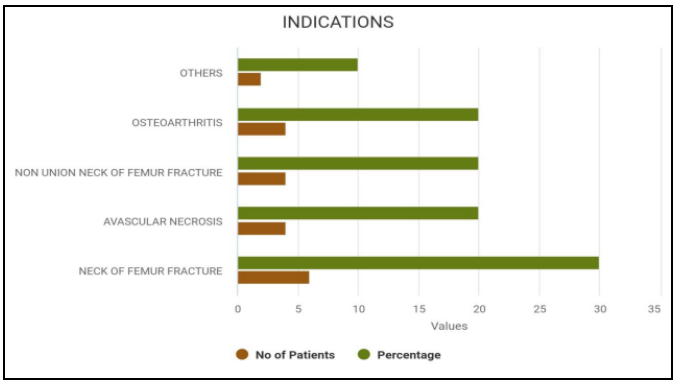

Chart 8: Indications in our study

Discussion

To avoid impingement, dislocation, wear rates, it is very important to understand the implant factors and pelvic anatomy in optimal cup positioning and it is very difficult and challenging in defining the optimal cup positions.

Acetabular cup should be placed and checked in all sagittal, coronal and axial planes. The lever arm forces and the joint reaction force are affected in extreme mediolateral positions.

For stability and survival of implant it is very important in proper placement of components. Position of the patient, pelvic orientation, Increased BMI, surgical approach, surgeon experience, inaccuracy, and inadequacy of mechanical guides are certain factors influencing the cup position. [20]

Why Posterior Approach

Woo (1982) [29]; Paterno (1997); Li (1999) reported- "The posterior approach is usually considered, because it is easy to perform, less extensive tissue dissection, which gives shorter duration of operation timing, and blood loss will be minimum. During the procedure, exposure of the femur is good so that the risk of femoral fracture is reduced Since the abductor muscles are not dissected, problems with gait are less associated. However, visualising the acetabulum intra operatively is more difficult, increased dislocation rates are main drawbacks.

Patients over 7-23% often suffer from persistent lateral thigh or hip pain Post-operatively [21]. Persistent pain due to impingement [22], dislocation [24], and liner fracture [23] is mainly due to improper acetabular positioning. These unexpected results lead to dissatisfaction in patients after a total hip arthroplasty.

Impingement: Acetabular component which is not covered by bone of the pelvis resulted due to retroversion or lateralization of component may act as risk factor for iliopsoas impingement [25]. A cup inclination of 45° to 55° has been recommended to avoid impingement post operatively. Impingement, clinically recorded as maximum flexion-extension, abduction –adduction and axial rotation of the femur. To rule out the impingement, the patient must not feel pain in all the above mentioned movements.

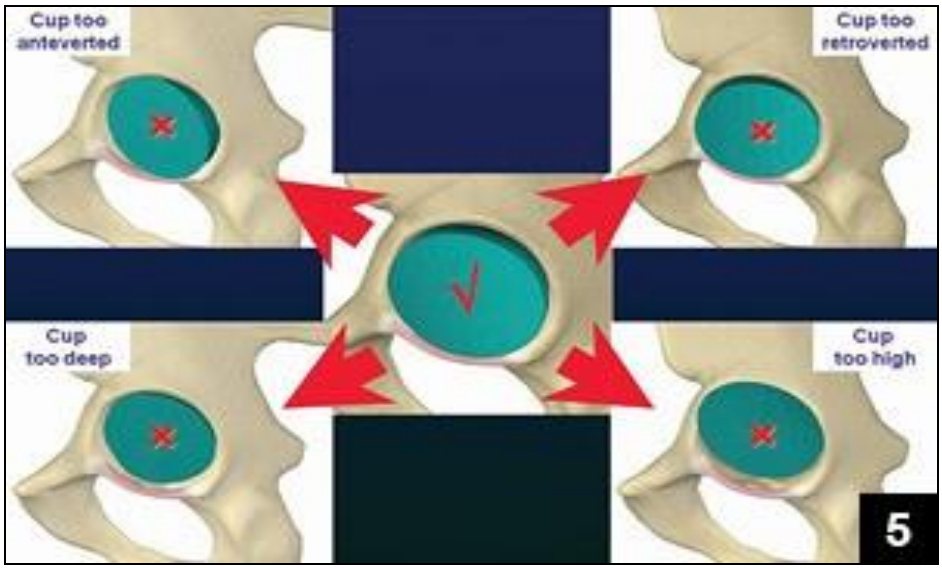

Fig 2: Acetabular cup orientation

Dislocation

Lewinnek et al. after studied nine dislocations originally defines acetabular cup safe zone as 15±10 degrees of anteversion and 40±10 degrees of inclination [24]. This "safe zone" gained popularity and has been scrutinized by many surgeons [26]. The so called proper position of acetabular component discussed in older studies and literature are mainly based on dislocation rates [27].

Toshinori Masaoka, Kengo Yamamoto, Takaaki Shishido, Yoichi Katori: [28], According to this author, study of hip dislocation after total hip replacement, dislocation rate is mainly decided by the acetabular cup version and is more important in achieving the stable hip joint.

Functional outcome

In our study for patient functional outcome score, Lewinnek's "safe zone" does not play any significant role. There are no studies on functional outcomes of patients that show any correlation of cup positioning in "safe zone". The functional outcome of acetabular component positioning in Total Hip Arthroplasty on patient satisfaction has not been studied yet. Patient functional outcome scores are clinically good in our study within the cup positions studied.

In our study it was found that there is significant difference in functional outcome with changes in CT-anteversion values. Many studies have proved that ideal cup anteversion is essential and critical for preventing impingement phenomenon, dislocation, accelerated wear and longevity of implant.

In our study of 20 patients, it was found that 10 patients had

excellent, 9 patients had good and one patient had fair outcome based on Modified Harris Hip Score.

In our study of 20 cases, 11 were male and 9 were female. The mean age of patients in our study was 49.65 and were followed for a period of 6 months. The mean postoperative Harris Hip Score was 88.45. Mean cup anteversion is 20.95. All were found to lie within the safe zone as proposed by Lewinnek et al. [18]. The dislocation rate is zero.

Conclusion

Total Hip Arthroplasty in various indications brings about definite functional improvement as well as pain relief, increased range of movement with good functional improvement in various patients. The surgical approach utilised also plays a very important role in preventing various complications. Surgeon expertise is also a must to deal.

Beside all these factors, Acetabular component placement plays a significant role in excellent functional outcome and prevention of complications. Primary Total Hip Arthroplasty is an emerging trend with better clinical and functional outcome with the newly available modular implants and better surgical techniques. All the components were placed within the Lewinnek safe zones and the outcome resulted finally is excellent with zero dislocation rate. The good functional outcome for the patients with an average modified Harris Hip Score of 88 proves that the acetabular cup placement is very essential in all Total Hip Arthroplasty.

Case Illustration

A 50 Year old male - Avascular Necrosis of Femur head- Left Hip

Fig 3: Pre Op X-ray

Fig 4: Post Op X-ray

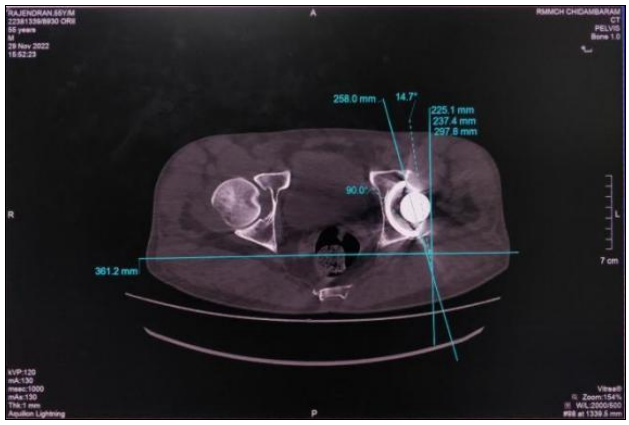

Fig 5: Acetabular Anteversion

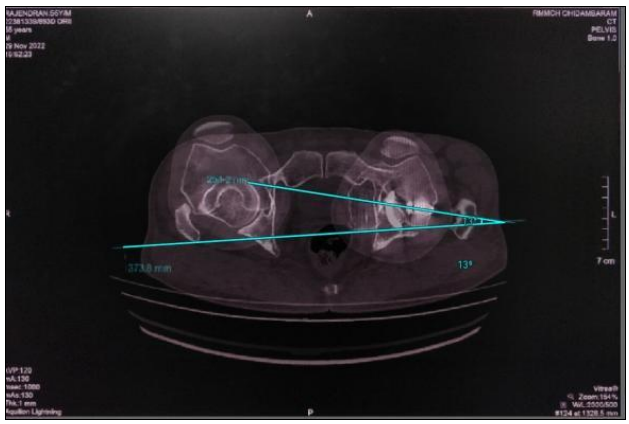

Fig 6: Femoral Anteversion

Fig 7: Follow up

Acknowledgement
Not available

Conflict of Interest
Not available

Financial Support
Not available

References

1. Ackland MK, Bourne WB, Uhthoff HK. Anteversion of the acetabular cup. Measurement of angle after total hip replacement. J Bone Jt Surger. 1986;68(3):409-413.
2. Barmeir E, Dubowitz B, Roffman M. Computed tomography in the assessment and planning of complicated total hip replacement. Acta Orthop Scand. 1982;53:597-604.
3. Blendea S, Eckman K, Jaramaz B, Levison TJ, Digioia AM. Measurements of acetabular cup position and pelvic spatial orientation after total hip arthroplasty using computed tomography/ radiography matching. Comput aided Surg Off J Int Soc Comput Aided Surg. 2005;10(1):37-43. Available at: http://www.ncbi.nlm. nih.gov/pubmed/16199380.
4. Chandler DR, Tarr RR, Gruen TA, Sarmiento A. Radiographic assessment of acetabular cup orientation. A new design concept. Clin Orthop Relat Res. 1984;186:60-64.
5. D'Lima DD, Urquhart AG, Buehler KO, Walker RH, Colwell CW. The effect of the orientation of the acetabular and femoral components on the range of motion of the hip at different head-neck ratios. J Bone Jt Surg. 2000;82(3):315-321. Available at: http:// www.ncbi.nlm.nih.gov/pubmed/10724224.
6. Ghelman B, Kepler CK, Lyman S, Della Valle AG. CT outperforms radiography for determination of acetabular cup version after THA. Clin Orthop Relat Res. 2009;467(9):2362-2370. Available at: http:// www. pubmed central. nih. gov / articlere nder. fcgi? artid=2866933 & tool=pmcentrez & rendertype=abstract.
7. Hassan DM, Johnston GHF, Dust WNC, Watson G, Dolovich AT. Accuracy of intraoperative assessment of acetabular prosthesis placement. J Arthroplasty. 1998;13:80-84. doi:10.1016/S0883- 5403(98) 90079-1.
8. Herrlin K, Pettersson H, Selvik G. Comparison of two- and threedimensional methods for assessment of orientation of the total hip prosthesis. Acta radiol. 1988;29(3):357-361. Available at: http:// www.ncbi. nlm.nih. gov/pubmed/2968109.
9. Kummer FJ, Shah S, Iyer S, DiCesare PE. The effect of acetabular cup orientations on limiting hip rotation. J Arthroplasty. 1999;14:509-513. doi:10.1016/S0883-5403(99) 90110-9.
10. Lewinnek GE, Lewis JL, Tarr R, Compere CL, Zimmerman JR. Dislocations after total hip-replacement arthroplasties. J Bone Jt Surg. 1978;60(2):217-220. Available at: http://www.ncbi.nlm.nih.gov/pubmed/641088.
11. Mian SW, Truchly G, Pflum FA. Computed tomography measurement of acetabular cup anteversion and retroversion in total hip arthroplasty. Clin Orthop Relat Res. 1992;276:206-209.
12. Murphy SB, Simon SR, Kijewski PK, Wilkinson RH, Griscom NT. Femoral anteversion. J Bone Joint Surg Am. 1987;69:1169-1176. doi:10.1097/01241398-198707000 -00026.
13. Murray MM. Current status and potential of primary ACL repair. Clin Sports Med. 2009;28(1):51-61. Available at: http://www.ncbi. nlm.nih.gov/pubmed/19064165.
14. Murray D. The definition and measurement of acetabular orientation. J Bone Jt Surgery; 1993. p. 228–232. Available at: http://www.bjj.boneandjoint.org.uk/content/75-B/2/228.abstract.Accessed June 18, 2013.
15. Najarian BC, Kilgore JE, Markel DC. Evaluation of component positioning in primary total hip arthroplasty using an imageless navigation device compared with traditional methods. J Arthroplasty. 2009;24:15-21. doi:10.1016/j.arth.2008.01.004.
16. Olivecrona H, Weidenhielm L, Olivecrona L, et al. Spatial component position in total hip arthroplasty. Accuracy and repeatability with a new CT method. Acta radiol. 2003;44(1):84-91.
17. Wines AP, McNicol D. Computed tomography measurement of the accuracy of component version in total hip arthroplasty. J Arthroplast. 2006;21:696-701. doi:10.1016/j.arth. 2005.11.008.
18. Woo R, Morrey B. Dislocations after total hip arthroplasty. J Bone J t Surg Am, 1982, 64(9). Available at: http://surgical techniques. jbjs. org/ data/ Journals/ JBJS/ 608/ 1295. pdf.
Accessed June 20, 2013.
19. Sutherland CJ, Wilde AH, Borden LS, Marks KE. A 10-year follow-up of one hundred consecutive Müller curved-stem total hipreplacement arthroplasties. J Bone Joint Surg Am. 1982;64(7):970–982
20. DiGioia AM, Jaramaz B, Blackwell M, Simon DA, Morgan F, Moody JE, *et al*. The Otto Aufranc Award: image guided navigation system to measure intraoperatively acetabular implant alignment. Clin Orthop Relat Res. 1998;355:8-22.
21. Beswick AD, et al. What proportion of patients report long-term pain after total hip or knee replacement for osteoarthritis? A systematic review of prospective studies in unselected patients. BMJ Open. 2012;2(1):e000435.
22. Shon WY, et al. Impingement in Total Hip Arthroplasty: A Study of Retrieved Acetabular Components. J

Arthroplasty. 2005;20(4):427-35.
23. Yamaguchi M, et al. The spatial location of impingement in total hip arthroplasty. J Arthroplasty. 2000;15(3):305-13.
24. Lewinnek GE, et al. Dislocations after total hip-replacement arthroplasties. J Bone Joint Surg Am. 1978;60(2):217-20.
25. O'Sullivan M, et al. Iliopsoas tendonitis a complication after total hip arthroplasty. J Arthroplasty. 2007;22(2):166-70.
26. Eilander W, et al. Functional acetabular component position with supine total hip replacement. BJJ. 2013;95(10):1326-31.
27. Kennedy JG, et al. Effect of acetabular component orientation on recurrent dislocation, pelvic osteolysis, polyethylene wear, and component migration. J Arthroplasty. 1998;13(5):530-4.
28. Toshinori Masaoka, Kengo Yamamoto, Takaaki Shishido, Yoichi Katori: study of hip dislocation after total hip replacement; Journal list > Int orthop > v 30; 2006 Feb.
29. Woo RYG, Morrey BF. Dislocations after total hip arthroplasty. J Bone Joint Surg. 1982;64-A:1295-306.

How to Cite This Article
NS Ahamed, A Senthilnathan, R Prabhakar. Functional outcome of total hip arthroplasty based on acetabular version on CT: A combined retrospective & prospective study. International Journal of Orthopaedics Sciences. 2022;8(4):119-125.