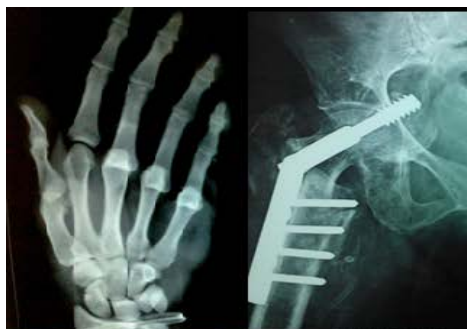



# International Journal of Orthopaedics Sciences

E-ISSN: 2395-1958  
P-ISSN: 2706-6630  
IJOS 2022; 8(4): 47-52  
© 2022 IJOS  
[www.orthopaper.com](http://www.orthopaper.com)  
Received: 06-07-2022  
Accepted: 11-08-2022

**Dr. RS Boobathi Raja**  
Post Graduate, Department of  
Orthopaedics, Rajah Muthiah  
Medical College and Hospital,  
Chidambaram, Tamil Nadu,  
India

**Dr. Dhanpal Singh**  
Professor, Department of  
Orthopaedics, Rajah Muthiah  
Medical College and Hospital,  
Chidambaram, Tamil Nadu,  
India

**Dr. K Parasuraman**  
Assistant Professor, Department  
of Orthopaedics, Rajah Muthiah  
Medical College and Hospital,  
Chidambaram, Tamil Nadu,  
India

**Dr. A Manikandarajan**  
Assistant Professor, Department  
of Orthopaedics, Rajah Muthiah  
Medical College and Hospital,  
Chidambaram, Tamil Nadu,  
India

**Corresponding Author:**  
**Manikandarajan**  
Assistant Professor, Department  
of Orthopaedics, Rajah Muthiah  
Medical College and Hospital,  
Chidambaram, Tamil Nadu,  
India

## Management of unstable intertrochanteric fracture by proximal femoral nailing with trochanteric buttress plating

**Dr. RS Boobathi Raja, Dr. Dhanpal Singh, Dr. K Parasuraman and Dr. A Manikandarajan**

**DOI:** <https://doi.org/10.22271/ortho.2022.v8.i4a.3241>

### Abstract

**Aim:** The aim of the study is to evaluate the anatomical reduction and augmenting the lateral wall with trochanteric buttress plating along with PFN in an unstable IT fractures with broken lateral wall.

**Background:** Unstable IT fractures have poor contact between fragments, loss of posteromedial support, reverse oblique type, severe comminution and has subtrochanteric extension. Unstable IT fracture with coronal split presents a great challenges to an orthopaedic surgeon. This study evaluates augmenting the lateral wall with trochanteric buttress plating along with PFN for unstable IT fractures with a broken lateral wall.

**Design:** Prospective study.

**Materials and Methods:** Totally 20 patients of unstable intertrochanteric fractures treated in Rajah Muthiah Medical College and Hospital were studied during the study period August 2020 to November 2022.

**Result:** In our study the patients were followed up for 1 year. Modified Harris Hip Score was excellent in 60% of the patients with the mean value of 87.25. Mean duration of surgery 99.25 min. Mean blood loss 330ml. Mean time of union 15.15 weeks.

**Conclusion:** Although reconstruction of calcar is a main predictor of successful trochanteric fracture fixation, augmenting the lateral wall with Trochanteric buttress plate along with PFN is also a Major factor for successful fixation of unstable IT fractures.

**Keywords:** Unstable IT, lateral wall, augmentation, stable fixation

### Introduction

Unstable intertrochanteric fracture are those where there is a poor contact between fragments, especially medially and posterior cortical displacement, comminution or a fracture pattern such as the weight bearing forces tend to displace the fracture further or a reverse oblique type.

Stable intertrochanteric fractures are commonly treated with proximal femoral nailing with the failure rate of less than 2% [1]. Positioning of lag screw too close to fracture site or through a broken lateral wall has been found to be a potential reason for failure [2]. The treatment of unstable intertrochanteric fracture is more controversial. The unstable intertrochanteric fracture treated with PFN has high rate of failure ranging from 4% to 15% [3].

Intramedullary nailing has become a better choice of implant for stabilization the unstable trochanteric fracture [4]. Biomechanically PFN is a better choice of implant for unstable fractures as nail gives posteromedial support and resist excess collapse [5]. The advantages of intramedullary devices are it withstands the stress of axis shift, has good fixation and less damage to blood vessels [6, 7].

Unstable intertrochanteric fracture with coronal split continue to be a great challenge to an orthopaedic surgeons. The main objective of our study is to hypothesis that anatomical reduction and augmenting the lateral wall with trochanteric buttress plate along with PFN which increase the stability of bone Implant and reduces the rate of complication [8].

### Materials and Method

After obtaining institutional ethical board approval a prospective non randomized study conducted from August 2020 to November 2022 at Rajah Muthiah Medical College And Hospital, Chidambaram.

Totally 20 patients of unstable intertrochanteric fractures were included with the age group ranges from 18 to 80 with 12 male and 8 female patients. The diagnosis of unstable fracture is made on radiographic appearance of fractures with the involvement of posteromedial and posterolateral part of the trochanter. The CT scan was not used because of cost effective manner.

Boyd and Griffin classification was used for evaluation. Informed consent was taken for all subject. A thorough history and clinical examination was done for assessment.

**Inclusion Criteria**

- Age above 18 below 80
- Boyd and griffin type 3 and 4 intertrochanteric fractures

**Exclusion Criteria**

- Previous surgery of proximal femur
- Associated neurological disorder
- Stable intertrochanteric fracture.

**Table 1:** Demographic characteristics of the patient

Parameters	Data	Total
Age	30 to 50; 6 50 to 60; 5 60 to 80; 9	20
Sex	Male; 12 Female; 8	20
Type of Fracture Boyd and griffin	Type iv -8 Type iii- 12	20
Location	Right hip -11 LET hip-9	20
Mode of trauma RTA	11	20
Self-fall	6	
Fall from height	3	

**Implant Design**

The trochanteric buttress plate is a 3mm anatomically contoured plate with 2 oblique holes for passing 6.5 mm derogation screw and 8mm compression screw. The plate is designed in such a way that it flush with the lateral wall making fixation with the bone. The PFN along with plate a single assembly thus reinforcing fixation. The proximal part of plate has multiple holes for 4.9 mm locking screws to fix bone pieces to trochanter. The distal portion of plate has two 4.5 mm holes for both unicortical and bicortical fixation of plate to upper portion of proximal femur. The whole assembly has a good rigid fixation and buttressing effect on lateral wall.

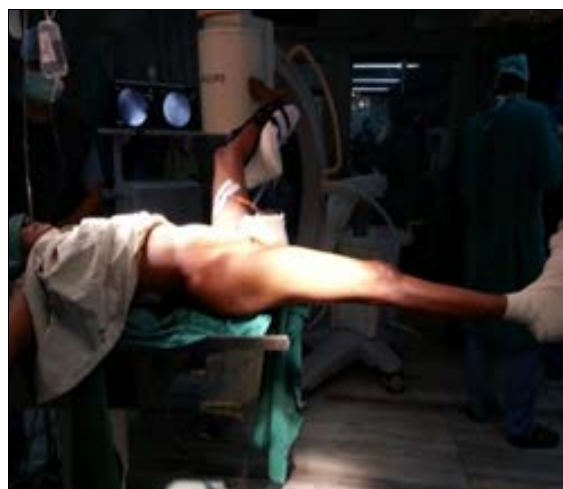

**Fig 1:** PFN with Trochanteric buttress plating

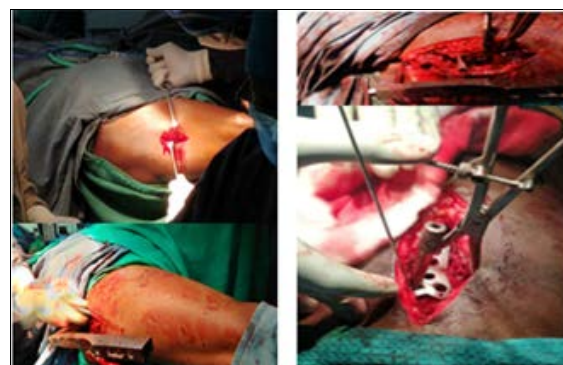**Operative Procedure**

Under anesthesia patients were positioned on a traction table and screened under C-ARM to check the reduction in Ap and lateral view (Fig-2 a,b). Entry made using bone awl just medial to the tip of greater trochanter. Fossa finder introduced and guide wire passed (Fig-2 d). At this stage the decision regarding using buttress plate is made, it is observed that if the guide pin passes through the broken lateral wall, on

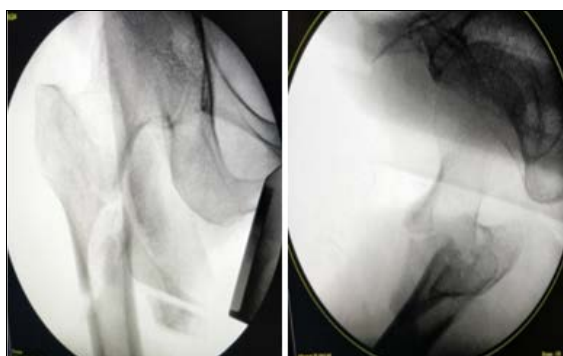passing the compression screw the screw head gets buried into the lateral wall and no compression is achieved (Fig-2 e). In such a situation use of trochanteric buttress plate enables early mobilization and promotes fracture healing. Serial reaming done and the nail is passed through the guide wire. The holes in PFN were aligned in the direction of neck properly just above the calcar. The incision may be extended distally to accommodate the buttress plate. The plate is inserted in such way to accommodate the proximal guide pins along with PFN. The guide wire sleeve targeted through the jig into the corresponding holes of plate and guide wire into the head and neck of femur. The placement of guide wire is confirmed under C-ARM and drilled and fixed with corresponding screws (Fig-2 f). The final tightening was completed after the release of traction. The inferior holes in the plate were fixed unicortically, the distal locking was checked under C-ARM guidance, which enables a rigid fixation of lateral wall.



**Fig 2:** a) Position of the patient in traction table



**Fig 2:** b) Skin incision, nail insertion and trochanteric plate placement



**Fig 2:** c) C-ARM images showing unstable IT

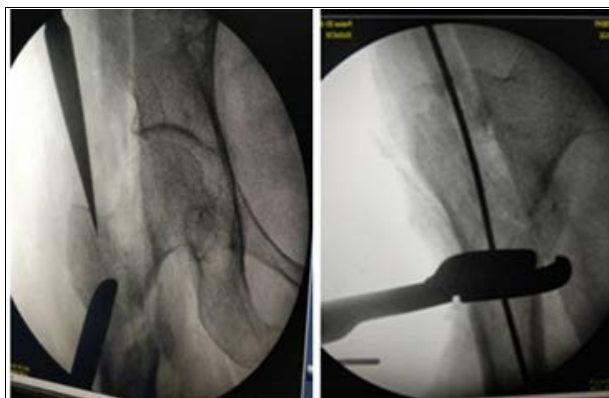


Fig 2: d) Image showing trochanteric entry point

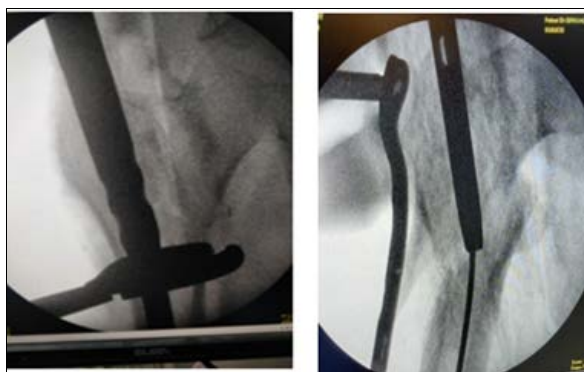


Fig 2: e) Image showing guide wire insertion and PFN

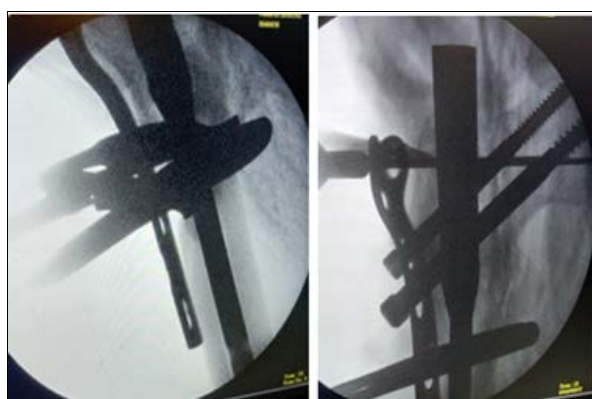

Fig 2: f) Image showing lateral wall reduction with trochanteric buttress plating

**Post-operative protocol**

Elevation of operated limb for a day. Broad spectrum antibiotics for 5 days. Static quadriceps exercises were performed on the 3rd post-operative day. Active quadriceps exercise were performed on the 5th post-operative day. Toe touch weight bearing started at the 1st week with the help of walker or crutches. Suture removal done at the 2nd week post-operatively. The patient were followed up clinically and radiologically at regular interval for possible complication and progress of union. Partial weight bearing started at 1st month and full weight bearing at 3rd month based on the evidence of radiological union and confirmation of clinical union by assessing pain, fracture gap and other parameters clinically.

**Result**

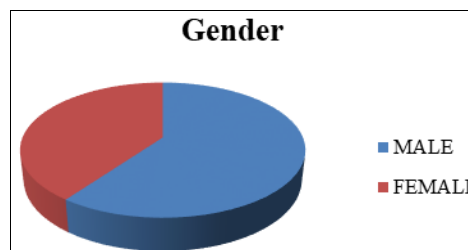
All the patients were followed up for the minimum of 12 months. Overall functional outcome based on modified Harris hip score.

The outcome was classified as poor if <70, fair if 70 to 79, and good if 80 to 89 and excellent when more than 90. 12 patients had excellent result (60%), 5 had good result (25%),

3 had fair result (15%) with the mean score of 87.25% (Table-7, Graph-4). Totally 12 male (60%) and 8 female patients (40%) (Table-2, Graph-1). Union was determined clinically by absence of pain and radiologically by complete bridging of the fracture site in both orthogonal projection. The mean union time is 15.15 months (Table-6). Average delay between the time of operation and the time of injury was 3 to 12 days mostly due to comorbidity condition associated with age and delay in presentation. Post-operative x-ray shows anatomical reduction in 11 cases (55%) and acceptable reduction in 9 cases (45%) and they do not have limb length discrepancy. The mean duration of surgery is 99.25 min (Table-3, Graph-2). The mean intraoperative blood loss is 330 ml (Table-4). The tip apex distance of the femoral neck screw less than 25 mm achieved in all the patients. Identifiable rotation of the proximal fragment on x-ray was not observed in any of the patients. 12 patients (60%) had no complaints, 5 complaint of persistent pain (25%) in hip, 2 patient has 8 to 9 mm shortening (10%) but none required shoe raise, 1 had varus angulation (5%) (Table-5, Graph-3). Normal range of motion was observed in 11 patients (55%), 5 had slightly decrease in range of motion (25%), 4 had limited flexion and abduction (20%) with fair muscle power. Hip abductor function was observed to be adequate in most of the cases at final follow up. No cases of implant failure, or fixation failure were observed in our study.

Table 2: Age distribution in our study

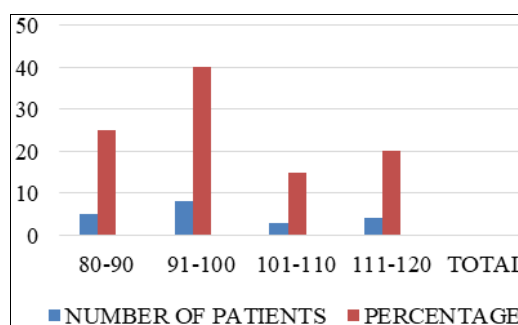
Age (in years)	Number of patients	Percentage
31-40	2	10
41-50	4	20
51-60	5	25
61-70	9	45
Total	20	100



Graph 1: In our study most of the cases were male 60%

Table 3: Association with duration of surgery

Duration of surgery (in minutes)	Number of patients	Percentage
80-90	5	25
91-100	8	40
101-110	3	15
111-120	4	20
Total	20	100



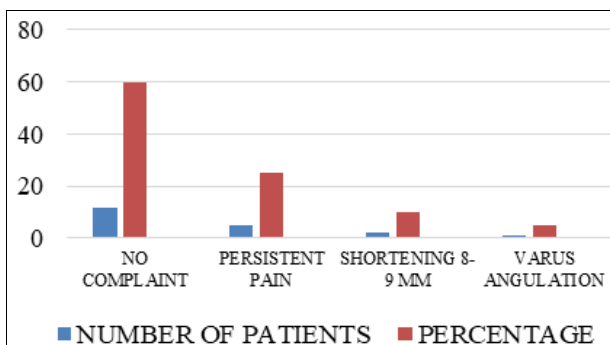
Graph 2: Duration of Surgery

**Table 4:** Associated blood loss

Blood Loss (in ml)	Number of patients	Percentage
250-300	9	45
301-350	8	40
>350	3	15
Total	20	100

**Table 5:** Post op Complications

Post op complication	Number of patients	Percentage
Varus Angulation	1	5
Persistent pain	5	25
Shortening <9 mm	2	10
Nil	12	60
Total	20	100



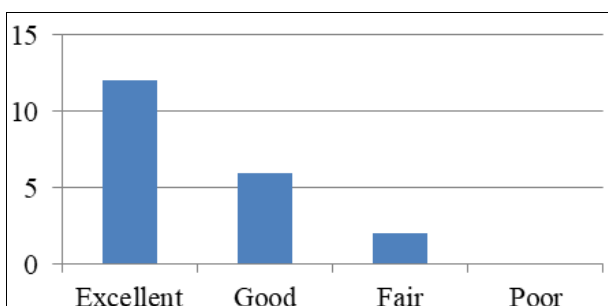
**Graph 3:** Showing Post op Complications

**Table 6:** Association with Time of Union

Time of union (in weeks)	Number of patients	Percentage
12-14	11	55
15-17	5	25
18-20	3	15
>20	1	5
Total	20	100

**Table 7:** Association with Modified Harris Hip Score

Harris Hip score	Number of patients	Percentage
Excellent	12	60
Good	6	30
Fair	2	10
Poor	0	0
Total	20	100



**Graph-4:** Functional outcome using Modified Harris Hip Score

**Discussion**

Traditionally the medial and posteromedial fractures fragments have been considered to be important elements in determining the severity of intertrochanteric hip fractures [17]. In unstable intertrochanteric fractures, the integrity of lateral femoral wall can be restored with augmentation of PFN with trochanteric buttress plate [18].

There is still a lot of debate with the ideal implant to be used for unstable intertrochanteric fractures. For the treatment of unstable intertrochanteric fractures dynamic hip screw was the implant of choice previously. Generally dynamic hip screw have led to many failures in unstable intertrochanteric fractures [9]. Failure of dynamic hip screw in such fractures can be implicated to the lever arm being along and its placement away from the mechanical axis of the body which makes a load bearing device [10].

Intramedullary devices works on the load sharing principle and has smaller bending moments, hence it has advantage in an unstable intertrochanteric fractures fixation and allows for early weight bearing and prevent excessive fracture collapse [11, 13]. Some of the implant related complications in trochanteric fractures stabilization are lateral protrusion of screws, screw cutouts, Z or reverse Z effect and the fracture of lateral trochanteric wall [12].

Ganjale S.B, and his associates opine that in PFN surgery also lateral wall instability is as important as it is in DHS fixation. Failure rate of a gamma nail for the treatment of unstable trochanteric fractures ranges from 12.7% to 15%. Secondary varus collapse in 25.7%, cutout of proximal screws in 5.7%, 5.7% nonunion, and reoperation in 14.3% cases was reported by Uzun *et al.* [15]

Fogagnolo *et al.* in their study had a complication rate of about 23.4% by using PFN in the treatment of an unstable trochanteric fractures [14]. Then came the PFNA- antiroation nail with the helical blade for stabilization of these fractures and showed varying results. Many authors in their studies claimed that PFNA device had theoretical advantage over DHS system in fixing the osteoporotic bones.

Takigami *et al.* observed 14% complication rate of the cases and 4% required reoperation after use of PFNA. Though the proximal femoral nail acts as a buttressing device and prevents medialization in cases of posteromedial defects, it provides no stability on the lateral side if lateral wall is compromised [16].

Many authors have used a combination of implants or have augmented PFN with a augmentation plate to restore the lateral wall and have achieved significant reduction in varus collapse and subsequent reduction in limb length discrepancy. S.B. Ganjale *et al.* [15] recently have shown that their newly designed plate has significantly reduced incidence of Z effect and excessive varus collapse and reduced lateralization of greater trochanter. And this specialized plate enhances fixation strength of PFN even in coronal split fractures and has demonstrated the importance of integrity of lateral femoral wall construct to prevent reoperation in an unstable trochanteric fractures. In our study the complication rates was less when compared with other implants and other studies on unstable trochanteric femur fractures and with the use of this implant, we have achieved good primary fracture compression during fixation and maintenance of reduction without varus collapse and shortening up to fracture union.

The lateral wall reconstruction significantly decreases the incidence of lateralization of greater trochanter with limited telescoping of comminuted fragments following weight bearing and resulted in better hip abductor function [19, 20].

Therefore the study indicates that addition of trochanteric buttress plate over intramedullary device is likely to improve the stability of fracture fixation, while simultaneously permitting a controlled sliding collapse. Improved bony contact between the proximal and distal fragments by stabilization of the comminuted lateral wall is likely to

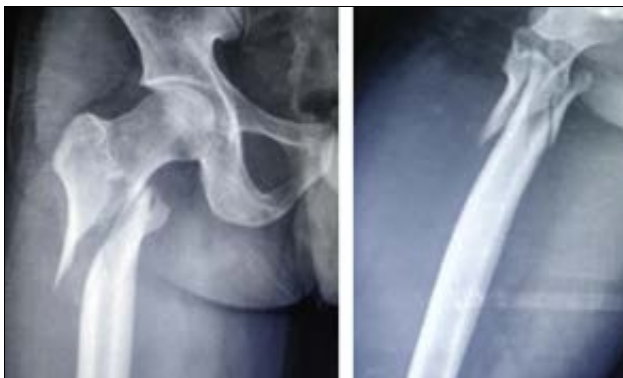improve the chance of union and maintenance of adequate lever arm.

**Conclusion**

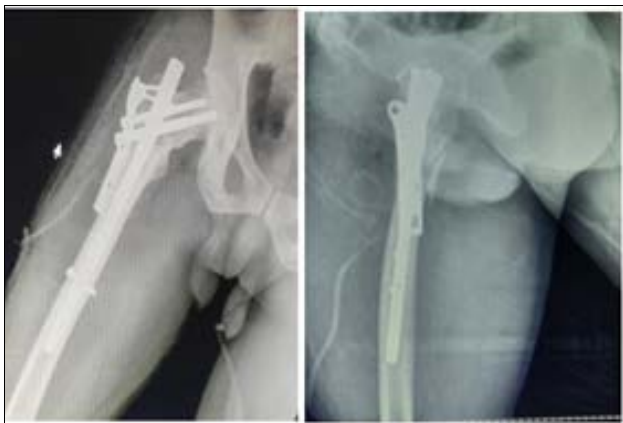Augmentation of PFN with Trochanteric buttress plate allows reconstruction of lateral wall in an unstable intertrochanteric fractures. This creates a biomechanically stable trochanteric construct allowing early mobilization, ensuring significant reduction in excessive collapse and subsequently reduced limb length discrepancy. The superior functional and radiological outcomes in patients with unstable intertrochanteric fractures indicates combination of PFN with Trochanteric buttress plate is likely to be the better option in the management of unstable IT fractures when compared to PFN alone.

**Case Illustration**

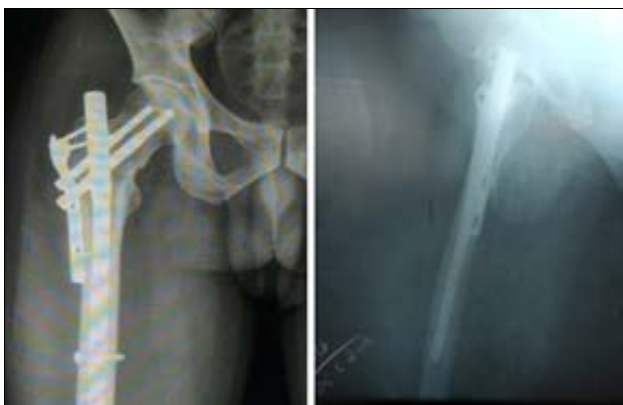**60 year old male h/o RTA and sustained injury to right hip**



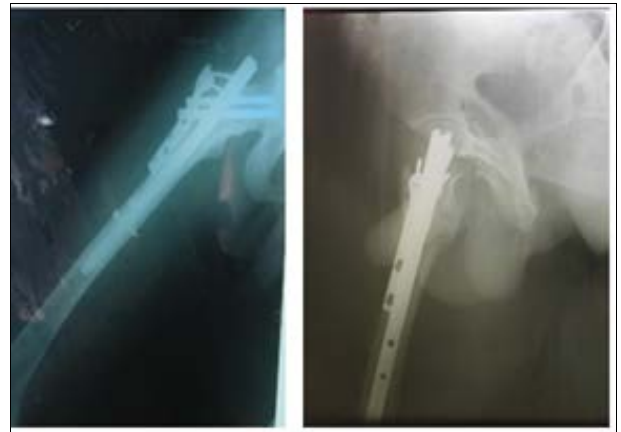
Preop



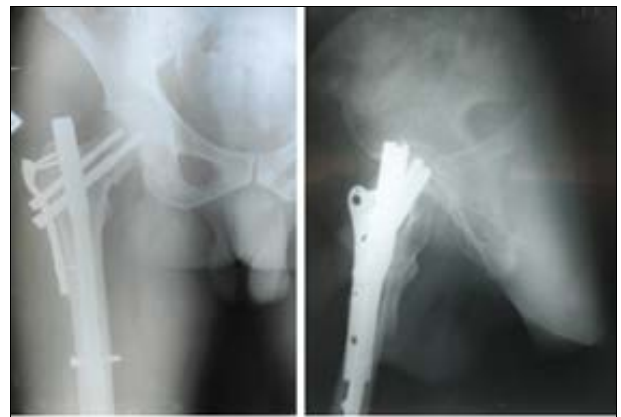Post op



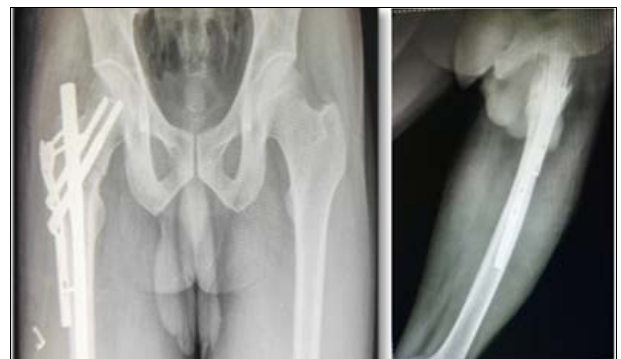1 month follow up



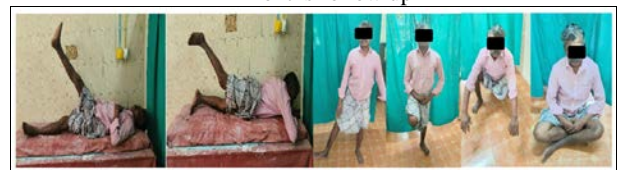3 month follow up



6 months follow up



12 months follow up



Follow Up

**Acknowledgement**

Not available

**Author's Contribution**

Not available

**Conflict of Interest**

Not available

**Financial Support**

Not available

**References**

1. Gotfried Y. Integrity of the lateral femoral wall in intertrochanteric hip fractures: an important predictor of a reoperation. *J Bone Joint Surg Am.* 2007;89(11):2552-3; author reply 2553.
2. Sharma G, Gn KK, Khatri K, Singh R, Gamanagatti S, Sharma V. Morphology of the posteromedial fragment in pertrochanteric fractures: a three-dimensional computed tomography analysis. *Injury.* 2016;48(2):419-31.
3. Fogagnolo F, Kfuri M, Paccola CAJ. Intramedullary fixation of pertrochanteric hip fractures with the short AO-ASIF proximal femoral nail. *Arch Orthop Trauma Surg.* 2004;124(1):31-7.
4. Socci AR, Casemyr NE, Leslie MP, Baumgaertner MR. Implant options for the treatment of intertrochanteric fractures of the hip: rationale, evidence, and recommendations. *Bone Joint J.* 2017;99-B(1):12833.
5. Klinger HM, Baums MH, Eckert M, Neugebauer RA. comparative study of unstable per- and intertrochanteric femoral fractures treated with dynamic hip screw (DHS) and trochanteric butt-press plate vs. proximal femoral nail (PFN). *Zentralbl Chir.* 2005;130(4):301-6.
6. Jonnes C, Shishir SM, Najimudeen S. Type II Intertrochanteric Fractures: Proximal Femoral Nailing (PFN) versus Dynamic Hip Screw (DHS). *The Archives of Bone and Joint Surgery.* 2016;4:23-28.
7. Barquet A, Gelink A, Giannoudis PV. Proximal femoral fractures and vascular injuries in adults: incidence, aetiology and outcomes. *Injury.* 2015;46:2297-2313.
8. Gadegone WM, Shivashankar B, Lokhande V, Salphale Y. Augmentation of Proximal Femoral Nail in Unstable Trochanteric Fractures; c2017.
9. Babhulkar Sudhir S. Management of trochanteric Fractures. *Indian Journal of Orthopaedics.* 2006;40(4):210-218.
10. Ansari Moein CM, Verhofstad MHJ, Bleys RLAW, Werken C van der, Soft tissue injury related to the choice of entry point in antegrade femoral nailing; pyriform fossa or greater trochanter tip. *J Clin Orthop Injury.* 2005;36:1337-1342.14.
11. Salvati EA, Wilson PD. Long Term Results of Femoral Head Replacement. *The Journal of Bone and Joint Surgery. American.* 1973;55(A):516-524. <https://doi.org/10.2106/00004623-197355030-00007>
12. Gadegone WM, Salphale YS. Short Proximal Femoral Nail Fixation for Trochanteric Fractures. *Journal of Orthopaedic Surgery (Hong Kong).* 2010;18:39-44. <https://doi.org/10.1177/230949901001800109>
13. Soni M, Anand V, Sikdar J, Singh R, Sidhu V, Goyal C. Comparative Study of Proximal Nailing versus Dynamic Hip Screw Device in the Surgical Management of Intertrochanteric Fractures. *Clinical Orthopaedics and Trauma.* 2015;6:71.
14. Megas P, Kaisidis A, Zouboulis P, Papas M, Panagopoulos A, Lambiris E. Comparativestudy of the Treatment of Pertrochanteric Fractures-Trochanteric Gamma Nail vs. Proximal. Femoral Nail. *Zeitschrift Fur Orthopadie Und Ihre Grenzgebiet;* c2005143. p. 252.
15. Ganjale SB, Gadegone WM, Kothadia P. Trochanteric Buttress Plate Combined with Proximal Femoral Nail for Unstable Intertrochanteric Fractures. *Innovative Technique]. Open Journal of Orthopedics.* 2018;8:235247. <https://doi.org/10.4236/ojo.2018.86027>
16. Takigami I, Matsuoto K, Ohara A, Yamanaka Uzun K, M, Erturer E, *et al.* Long Term Radiographic Complications Following Treatment of Unstable Intertrochanteric Femoral Fractures with Proximal Femoral Nail and Effects on Functional Results; c2009.
17. Bojan AJ, Beimel C, Taglang G, Collin D, Ekholm C, Jönsson A. Critical factors in cut-out complication after gamma nail treatment of proximal femoral fractures. *BMC Musculoskeletal Disorders.* 2013;14(1):1.
18. Schipper IB, Steyerberg EW, Castelein RM, van der Heijden FH, den Hoed PT, Kerver AJ, *et al.* Treatment of unstable trochanteric fractures. Randomised comparison of the gamma nail and the proximal femoral nail. *J Bone Joint Surg Br.* 2004;86(1):86-94.
19. Li S, Chang SM, Niu WX, Ma H. Comparison of tip apex distance and cut-out complications between helical blades and lag screws in intertrochanteric fractures among the elderly: a meta-analysis. *J Orthop Sci.* 2015; 20(6):1062-9.
20. Tan BY, Lau AC, Kwek EB. Morphology and fixation pitfalls of a highly unstable intertrochanteric fracture variant. *J Orthop Surg.* 2015;23(2):142-5.

**How to Cite This Article**

Raja RSB, Singh D, Parasuraman K, Manikandarajan A. Management of unstable intertrochanteric fracture by proximal femoral nailing with trochanteric buttress plating. *International Journal of Orthopaedics Sciences.* 2022;8(4):47-52.

**Creative Commons (CC) License**

This is an open access journal, and articles are distributed under the terms of the Creative Commons Attribution-NonCommercial-ShareAlike 4.0 International (CC BY-NC-SA 4.0) License, which allows others to remix, tweak, and build upon the work non-commercially, as long as appropriate credit is given and the new creations are licensed under the identical terms.