



E-ISSN: 2395-1958
P-ISSN: 2706-6630
IJOS 2022; 8(3): 220-222
© 2022 IJOS
www.orthopaper.com
Received: 12-04-2022
Accepted: 18-05-2022

Dr. Basant Rai
Associate Professor,
GMC, Amritsar, Punjab, India

Dr. Abhishek Rai
Seth GS Medical College,
Mumbai, Maharashtra, India

Dr. Dixit Bansal
GMC, Amritsar,
Punjab, India

Dr. Mohit Singla
Senior Resident, PGIMS
Rohtak, Haryana, India

Corresponding Author:
Dr. Dixit Bansal
GMC, Amritsar,
Punjab, India

Assessment of management of fracture neck of femur with internal fixation alone or with fibular graft

Dr. Basant Rai, Dr. Abhishek Rai, Dr. Dixit Bansal and Dr. Mohit Singla

DOI: <https://doi.org/10.22271/ortho.2022.v8.i3d.3201>

Abstract

Background: Intracapsular femoral neck fractures are commonly seen in the elderly population after a trivial fall. The present study was conducted to assess management of fracture neck of femur with internal fixation alone or with fibular strut graft.

Materials & Methods: 52 patients of fracture neck of femur treated by close / open reduction and internal fixation using cannulated cancellous screws along with strut fibular graft of both genders were enrolled. Parameters such as mode of injury, range of movement and complications were recorded.

Results: Out of 52 patients, males were 32 and females were 20. Mode of accident was RTA in 28, fall in 16 and domestic violence in 8 cases. Range of motion flexion > 100 degrees was seen in 40 and < 100 degrees in 12 cases. Extension > 10 degrees was seen in 38 and < 10 degrees in 14 cases. Abduction > 25 degrees was seen in 44 and < 25 degrees in 8 cases. Complications observed were swelling in four, shortening of the affected limb in two and superficial infection in case.

Conclusion: Management of fracture neck of femur with cancellous cannulated screw and fibular strut graft is a reliable method of fixation.

Keywords: Femoral neck fracture, cancellous cannulated screw, fibular strut graft

1. Introduction

Intracapsular femoral neck fractures are commonly seen in the elderly population after a trivial fall. However, femoral neck fractures in adults younger than age 50 years are uncommon and often the result of high-energy trauma ^[1]. They account for only 2-3% of all femoral neck fractures. To evaluate and treat femoral neck fractures in young adults, it is important to understand and contrast the differences between elderly and young adult patients. Characteristic differences are seen with respect to the osseous and vascular anatomy, the mechanism of injury, associated injuries, fracture pattern and the goals of treatment ^[2].

The fracture pattern seen in young adults will be different from the elderly patients ^[3]. The poor bone quality and fall from a standing height leads to a low-energy injury and results in a femoral neck or intertrochanteric hip fracture; the femoral neck fracture seen in elderly patients will often be sub-capital. It is common to see a transverse fracture pattern with impaction at the fracture site ^[4]. The fracture pattern seen in young adults will be significantly different because of their better bone quality and higher energy mechanism. The treatment of old femoral neck fracture is a much bigger challenge than that of fresh fractures. Under these circumstances internal fixation has to be combined with some type of bone graft or osteotomy ^[5]. The addition of strut fibular graft have improved the rate of union specially if it has been delayed beyond 3 weeks. The functional results after union are quite satisfactory and lasting in very high percentage of cases ^[6]. The present study was conducted to assess management of fracture neck of femur with internal fixation alone or with fibular graft.

Materials and Methods

The present study comprised of 52 patients of fracture neck of femur treated by close / open reduction and internal fixation using cannulated cancellous screws along with strut fibular graft of both genders. All patients agreed to participate in the study.

Data such as name, age, gender etc. was recorded. Parameters such as mode of injury, range of movement and complications were recorded.

Data thus obtained were subjected to statistical analysis. P value < 0.05 was considered significant. **Results**

Table 1: Distribution of patients

Total- 52		
Gender	Males	Females
Number	32	20

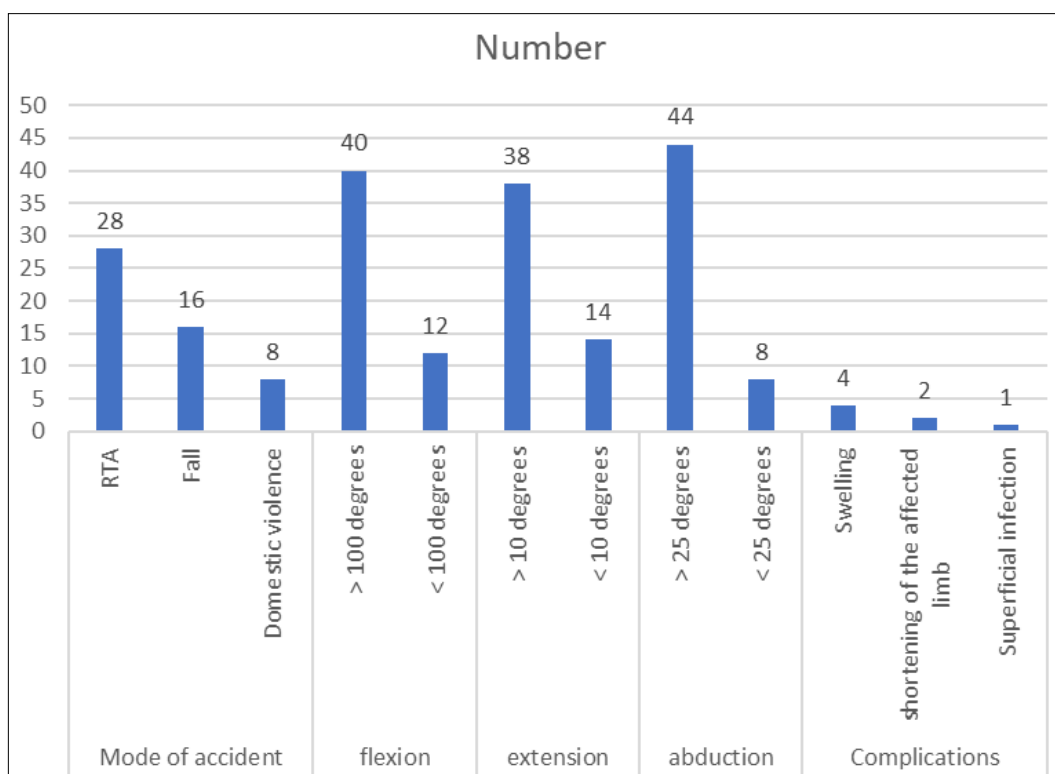
Table 1 shows that out of 52 patients, males were 32 and females were 20.

Table 2: Assessment of parameters

Parameters	Variables	Number	P value
Mode of accident	RTA	28	0.05
	Fall	16	
	Domestic violence	8	
flexion	> 100 degrees	40	0.01
	< 100 degrees	12	
extension	> 10 degrees	38	0.02
	< 10 degrees	14	
abduction	> 25 degrees	44	0.01
	< 25 degrees	8	
Complications	Swelling	4	0.03
	shortening of the affected limb	2	
	Superficial infection	1	

Table 2, graph 1 shows that mode of accident was RTA in 28, fall in 16 and domestic violence in 8 cases. Range of motion flexion > 100 degrees was seen in 40 and < 100 degrees in 12 cases. Extension > 10 degrees was seen in 38 and < 10

degrees in 14 cases. Abduction > 25 degrees was seen in 44 and < 25 degrees in 8 cases. Complications observed were swelling in four, shortening of the affected limb in two and superficial infection in one case.



Graph 1: Assessment of parameters

Discussion

In the elderly patients, femoral neck fractures usually occur as a result of a fall from standing height. Poor bone density, multiple medical problems and propensity to fall are major risk factors for femoral neck fracture [7]. In young adults, the mechanism of injury is often high-energy trauma, such as motor vehicle accident or fall from height. Fractures that occur in this normal bone density population require

substantial axial load with the hip in an abducted position [8]. The clinical evaluation of these patients requires a thorough trauma workup because they frequently have other associated injuries. Despite this, diagnosis and treatment of femoral neck fractures in young adults should only be superseded by other life and limb-threatening injuries [9]. The clinical presentation of patient with femoral neck fracture will show a shortened, flexed and externally rotated leg.

Radiographic evaluation should include antero-posterior (AP) pelvis, AP and lateral plain radiographs of the entire femur. Although uncommon, ipsilateral femoral neck and shaft fractures can occur in 2-6% of all femoral shaft fractures [10]. The present study was conducted to assess management of fracture neck of femur with internal fixation alone or with fibular graft.

We found that out of 52 patients, males were 32 and females were 20. Kumar *et al.* [11]. assessed the results of using free fibular graft to augment fracture fixation with cannulated cancellous screw for femoral neck. The present study includes 15 cases of fracture neck of femur in elderly patients of the age 20-60 years irrespective of sex treated by close / open reduction and internal fixation using DHS / AO cannulated cancellous screws along with strut fibular graft. 15 cases of fracture neck of femur were taken up for the study who reported to department of orthopaedics, PMCH between the ages of 20 – 60 years. The minimum duration between occurrence of fracture and surgical intervention was 3 weeks. This technique is an ideal treatment for patients with neglected intracapsular neck of femur in younger age group in our part.

We observed that mode of accident was RTA in 28, fall in 16 and domestic violence in 8 cases. Range of motion flexion > 100 degrees was seen in 40 and < 100 degrees in 12 cases. Extension > 10 degrees was seen in 38 and < 10 degrees in 14 cases. Abduction > 25 degrees was seen in 44 and < 25 degrees in 8 cases. Complications observed were swelling in 4, shortening of the affected limb in 2 and superficial infection in 1 case. Arnold *et al.* [12]. worked on 25 patients of ununited fracture neck of femur in age group 21-55 years. The gap between injury and operation included 6 weeks to 58 weeks. They were treated by closed reduction, cancellous screw fixation and fibular strut graft and followed up for 2-6 years. They used Mishra criteria for functional end results, which were excellent in 21, good in 3 and poor in 1 patient.

Banks [13]. in their study on 72 patients of neglected fracture neck femur and reported excellent hip in 41.66%, 27.77% had good hip, 20.83% had fair hip and remaining 9.72% had poor hip using Harris hip scoring system.

The limitation the study is small sample size and a short follow-up.

Conclusion

Management of fracture neck of femur with cancellous cannulated screw, supplemented with fibular strut graft is a reliable method of fixation.

References

1. Arbab S, Ud Din S. Osteosynthesis of intracapsular fracture neck of femur with cancellous screw and fibular graft. *J Postgrad Med Inst.* 1991;5(1):64-9.
2. Huang CH. Treatment of neglected femoral neck fractures in young adults. *Clin Orthop Relat Res.* 1986 May 1(206):117-126.
3. Haidukewych GJ. Salvage of failed treatment of femoral neck fractures. *Instr Course Lect.* 2009 Jan 1;58:83-90.
4. Pauyo T, Drager J, Albers A, Harvey EJ. Management of femoral neck fractures in the young patient: A critical analysis review. *World J Orthop.* 2014;5(3):204-217.
5. Zuckerman JD. *Comprehensive Care of Orthopaedic Injuries in the Elderly.* Baltimore: Urban & Schwarzenberg. 1991 Mar 1;5(1):118.
6. Banks HH. Non-union in fractures of the femoral neck. *Orthop Clin North Am.* 1974;5(4):865-85.

7. Chapman MW, Stehr JH, Eberle CF, Bloom MH, Bovill EG, Jr Treatment of intracapsular hip fractures by the Deyerle method. A comparative review of one hundred and nineteen cases. *J Bone Joint Surg Am.* 1975;57(5):735-44.
8. Estrada LS, Volgas DA, Stannard JP, Alonso JE. Fixation failure in femoral neck fractures. *Clin Orthop Relat Res.* 2002 Jun 1;399:110-118.
9. Kumar D, Gaurav Khemka, Vidya Sagar, Ashutosh Kumar, Santosh Kumar. Management of fracture neck of femur with internal fixation alone or with fibular graft. *International Journal of Orthopaedics Sciences.* 2019;5(2):84-87.
10. Arnold WD, Lyden JP, Minkoff J. Treatment of intracapsular fractures of the femoral neck. With special reference to percutaneous Knowles pinning. *J Bone Joint Surg Am.* 1974;56(2):254-62.
11. Banks HH. Factors influencing the results in fractures of the femoral neck. *J Bone Joint Surg.* 1962;44(5):931-64.