



E-ISSN: 2395-1958  
P-ISSN: 2706-6630  
IJOS 2022; 8(3): 181-188  
© 2022 IJOS  
[www.orthopaper.com](http://www.orthopaper.com)  
Received: 22-05-2022  
Accepted: 25-06-2022

**Dr. Somesh P Singh**  
HOU, Department of  
Orthopedic, BJMC, Asarwa,  
Ahmedabad, Gujarat, India

**Dr. Dhruv Patel**  
3rd Year Resident, Department  
of Orthopedic, BJMC, Asarwa,  
Ahmedabad, Gujarat, India

**Dr. Parth Patel**  
Senior Resident, Department of  
Orthopedic, BJMC, Asarwa,  
Ahmedabad, Gujarat, India

**Dr. Jay Oza**  
MBBS, Govt. Medical College,  
Surat, Gujarat, India

**Dr. Amay Khara**  
1<sup>st</sup> Year Resident, Department of  
Orthopedic, BJMC, Asarwa,  
Ahmedabad, Gujarat, India

**Corresponding Author:**  
**Dr. Somesh P Singh**  
HOU, Department of  
Orthopedic, BJMC, Asarwa,  
Ahmedabad, Gujarat, India

## A case report of revision hip surgery in dislocation of primary operated THA

**Dr. Somesh P Singh Sir, Dr. Dhruv Patel, Dr. Parth Patel, Dr. Jay Oza and Dr. Amay Khara**

DOI: <https://doi.org/10.22271/ortho.2022.v8.i3c.3198>

### Abstract

Total Hip Replacement is an increasingly common surgical intervention in the ageing population these days and with that it brings with it increasingly frequent complications. Posterior dislocation is more common, anterior dislocation is still a concern and its management is controversial. Study aims on understanding the pathology behind THR dislocation and ways to manage the same.

**Keywords:** Total hip replacement, anterior dislocation, revision THR, complications

### Introduction

Hip replacement is one of the most successful operations of the musculoskeletal system but it has some serious complications, one of them being total hip endoprosthesis which arises in 2% post-operative patients within 1 year of surgery. Other complications are –

- Aseptic loosening (36.5%)
- Infection (15.3%)
- THA dislocation (17.7%)

### Internationally, the number of THAs is projected to increase by 170% by the year 2030

The rate of dislocation of primary hip replacements is 0.2% to 10% whereas that of surgically revised artificial hip joints is 28% depending upon patient population, follow-up interval and type of prosthesis.

### Aim and Objectives

To study the pathophysiology and mechanisms leading to THA instability and to comment on the need for preemptive measures and algorithms to counter it.

### Conclusion

Dislocation following total hip replacement can be extremely traumatizing for patients. Thus, dislocation prophylaxis is essential. Apart from preoperative risk assessment, this includes proper surgical technique with optimized alignment of the components, soft-tissue balancing and head-neck ratio, as well as adequate surgical experience, proper post-operative orders, physiotherapy and follow-up. Treatment of instability after total hip replacement should follow a standardized algorithm.

### Epidemiology of THA Instability

Approximately 8 to 12% of annually performed hip surgeries are revision procedures of which THA dislocation constitutes 11 to 24% For a series of primary total hip replacements, it is reported that 59% (196 hips) of the dislocations occurred within the first three months after surgery and overall 77% (257 hips) within the first year. Another working group added that in their patient population (19 680 primary hip replacements) THA dislocations occurred in 513 cases, of which 32% manifested as late dislocations more than 5 years postoperatively; the recurrent dislocation rate among these patients was 55%.

The cumulative risk of dislocation within the first postoperative month is 1% and within the first year approximately 2%. Thereafter, the cumulative risk continuously increases by approximately 1% per 5-year period and amounts to approximately 7% after 25 years.

### Etiology and Classification

The dislocation is defined as the complete loss of articulation contact between two artificial joint components.

Optimum load transfer between pelvis and femur along with normal multi-axial mobility of joints and optimum muscular function is the aim here.

These biomechanical requirements can technically be met by stable prosthesis positioning, reconstruction of cup inclination and anteversion, stem ante-torsion, reconstruction of the rotational centre of the hip, offset, and leg length, as well as by using a muscle-sparing surgical technique.

Basically, THA dislocation can be caused by 3 mechanisms or a combination of 2 mechanisms which are presented in the following Table.

### Mechanisms of THA instability

**Table 1:** Cause and consequence of THA instability

Cause	Consequence
Malpositioning or loosening of stem or acetabular component	No sufficiently stable contact between joint partners
Contact between neck of the prosthesis and articular component	Primary impingement
Contact between bony femur and bony pelvis	Secondary impingement
Hyperlaxity of the joint due to muscular insufficiency or lack of soft tissue tension	Possibility of an abnormally placed head of femur

### Risk Factors for THA Dislocation

#### 1. Based On TimeLine

- Preoperative
- Perioperative
- Postoperative

#### 2. Casual Relationship

- Patient-related
- Surgeon related
- Implant related

#### Patient-Related Factors

The muscular and capsular guidance for the replaced hip joint is one of the key factors contributing to stability of the joint. Patients with neuromuscular conditions, such as cerebral palsy, muscle dystrophy and dementia and also Parkinson's disease have a higher dislocation incidence of between 5% and 8% annually.

Sarcopenia, loss of proprioception and the increased risk for falls cause increased risk of dislocation in old age people mainly more than 80 years. Non-compliance of postop orders and dislocation-promoting hip movements, such as deep flexion or internal rotation of the flexed hip joint, is not strictly avoided contributing to the dislocation.

High-impact factors contributing to the dislocation risk include anatomical variations of the hip, often occurring along with congenital hip dysplasia or metabolic bone disorders, rapidly progressive and inflammatory arthropathies, as well as necrosis of the femoral head.

Risk of dislocation increases substantially in cases with prior fractures or surgical procedures involving hip. After previous dislocation, periprosthetic fractures, and septic or aseptic loosening are associated with dislocation rates of up to 28% due to significant soft-tissue trauma, extensive scarring, heterotopic ossification, and acetabular or femoral bone loss.

Attention should be paid to the patient-related risk factors for assessing preoperative risk factors and informed consent discussion.

### Procedure Related Factors

#### 1. The Surgical Approach

Posterior approach to the hip, involving detachment of the external rotators and the posterior joint capsule, is associated with a higher dislocation risk compared with the lateral, anterolateral or anterior approaches. Positioning of the acetabular and femoral components.

However, the dislocation rates for the posterior approach can be significantly reduced to rates as low as 0.7% by anatomical repair of the posterior capsule and the external rotators combined with increased anteversion of the cup component.

However, an increased risk of functional weakening of the abductor muscles is present in the lateral trans gluteal approach to the hip joint.

#### 2. Positioning of Acetabular and Femoral Head Component

Even though both acetabular and femoral cup positioning is guided by individual anatomic requirements, the dislocation-stable cup position with an inclination of  $40\pm 10^\circ$  and an anteversion of 10 to  $20^\circ$  as published by Lewinnek is internationally considered desirable.

Intraoperative positioning, the patient-specific anatomical situation, periarticular contractures, malpositioning of the lumbosacral junction, and obesity as well as surgeon's experience contributes significantly

1. Soft Tissue Tension
2. The Surgeon's Experience

#### Implant Related Factors

A wide range of acetabular and femoral components as well as sliding pairings are available for primary and revision arthroplasties. The service life of these components and the abrasion of various sliding pairings are the main factors influencing late dislocation by material wear.

Other factor contributing to the instability is the implant design. The use of over-hemispheric acetabular and inlay components or extended prosthetic heads—intended to increase the stability of the prosthesis—cause primary impingement, i.e. early contact of the femoral component with the acetabular component.

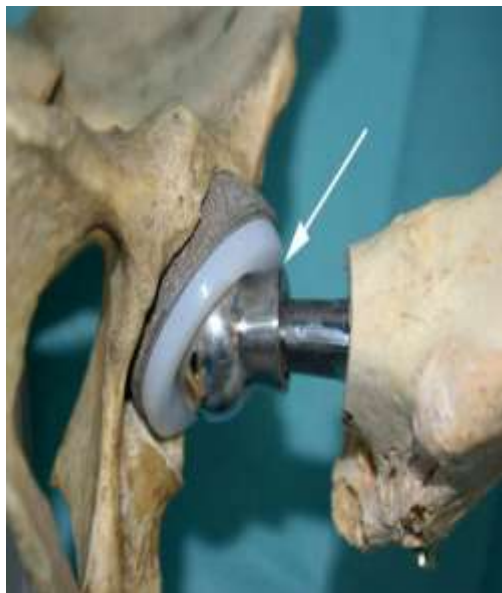The head-to-neck ratio is of special importance for the stability of the prosthesis and the impingement-free range of motion. Larger femoral heads (e.g. 36 mm) allow a wider mechanical range of motion compared with smaller head diameters (e.g. 28 mm) before the neck of the prosthesis strikes the rim of the acetabular component. In addition, JUMPING DISTANCE, that is, the distance a larger femoral head has to move away from the centre of the acetabular component before it can dislocate over the rim of the cup is longer.

However, larger femoral head has following disadvantages-

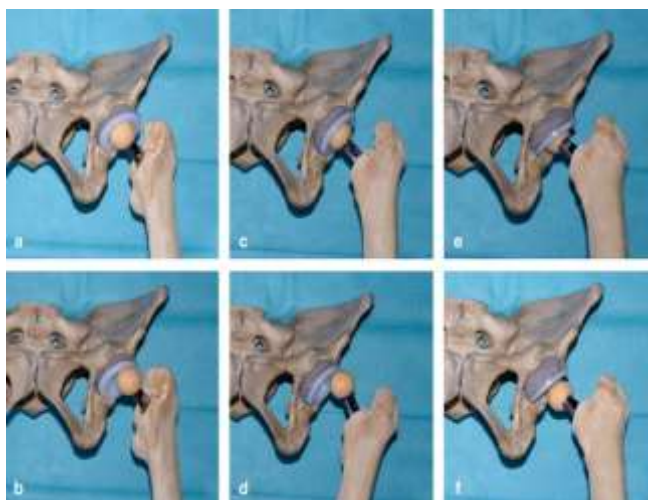
- Inlay thickness has to decrease with increasing head diameters
- Increased abrasion along the head-neck plug connection

- The stabilizing effect is lost in case of abductor insufficiency
- The increased range of motion promotes secondary impingement with resulting contact between proximal femur and pelvic bone.

Therefore femoral head more than 36 cm is not normally used.



**Fig 1:** Increased mobility for smaller head prosthesis



**Fig 2:** Instability due to small head prosthesis

**Case**

71 year old female patient

Name: Manguben

Complain- pain and difficulty in walking

Patient was outside operated for Avascular necrosis of hip 4 month back, Total hip replacement was done

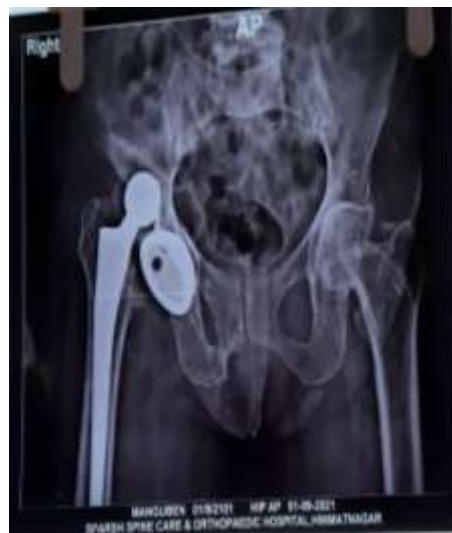Patient presented with dislocation of hip due to implant failure Right Side Pt came to Civil hospital Ahmedabad, xrays and CT scan of hip was done

Measurements were done for implant failure

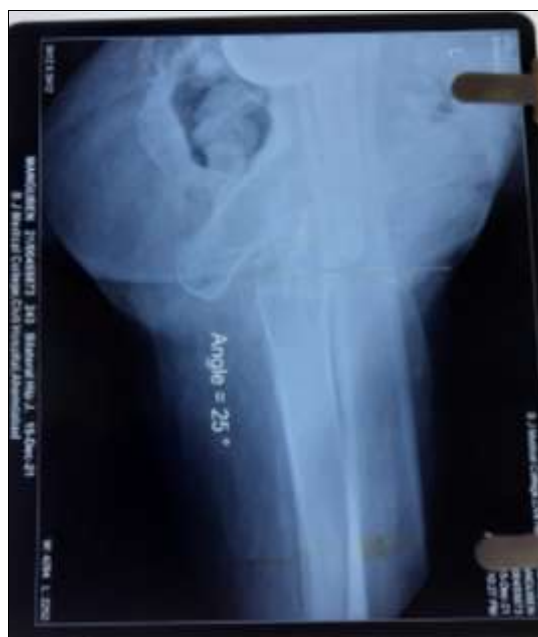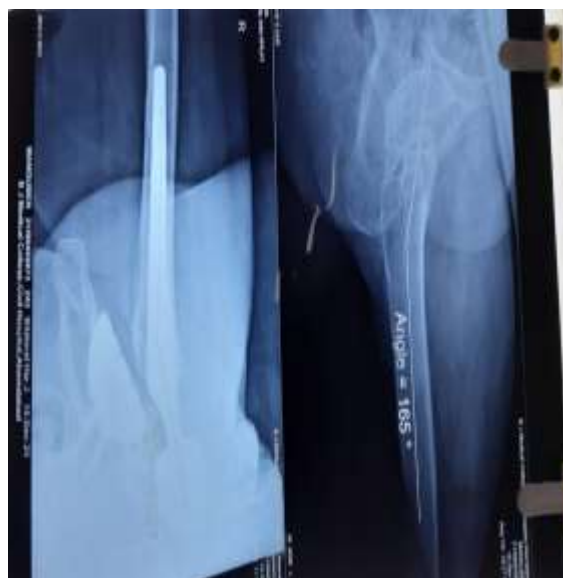**Operative note**

Patient in lateral position by using smith and rutherford incision, acetabular component implant removed by using stryker system followed by acetabular cup rimmed f/b acetabular cup of size 58 with constrained liner of size 34x58

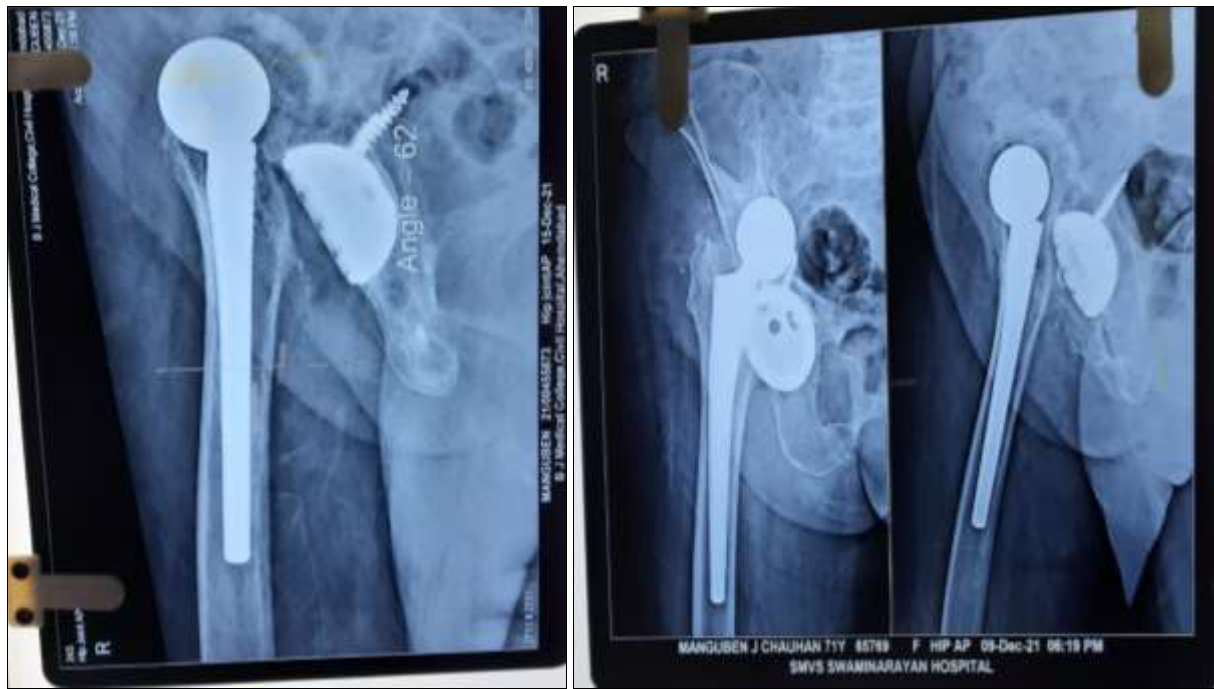
fixed f/b femoral head size 32 mm fitted f/b femoral head relocated and external fixators of hip tied and closure done.



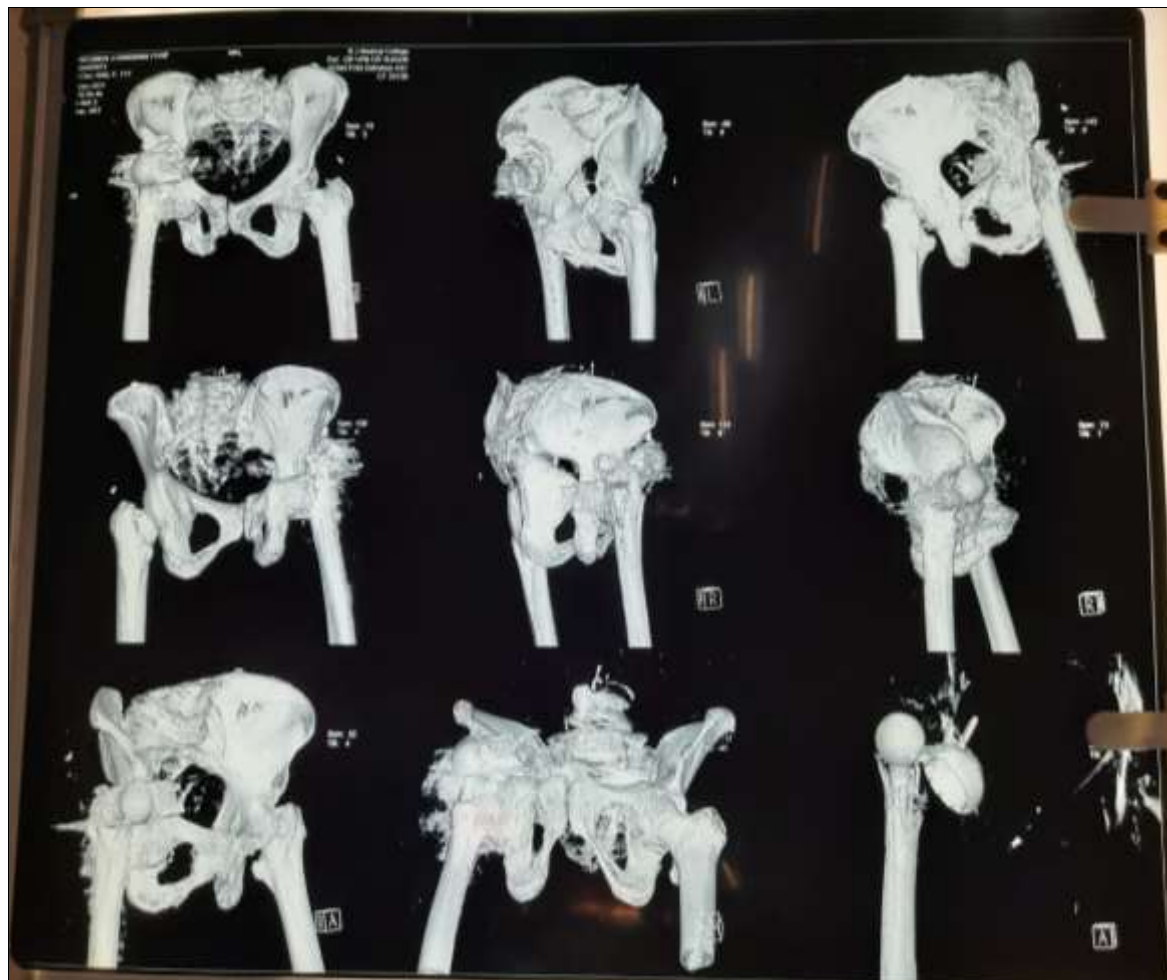**Fig 3:** X-ray PBH showing dislocated THR



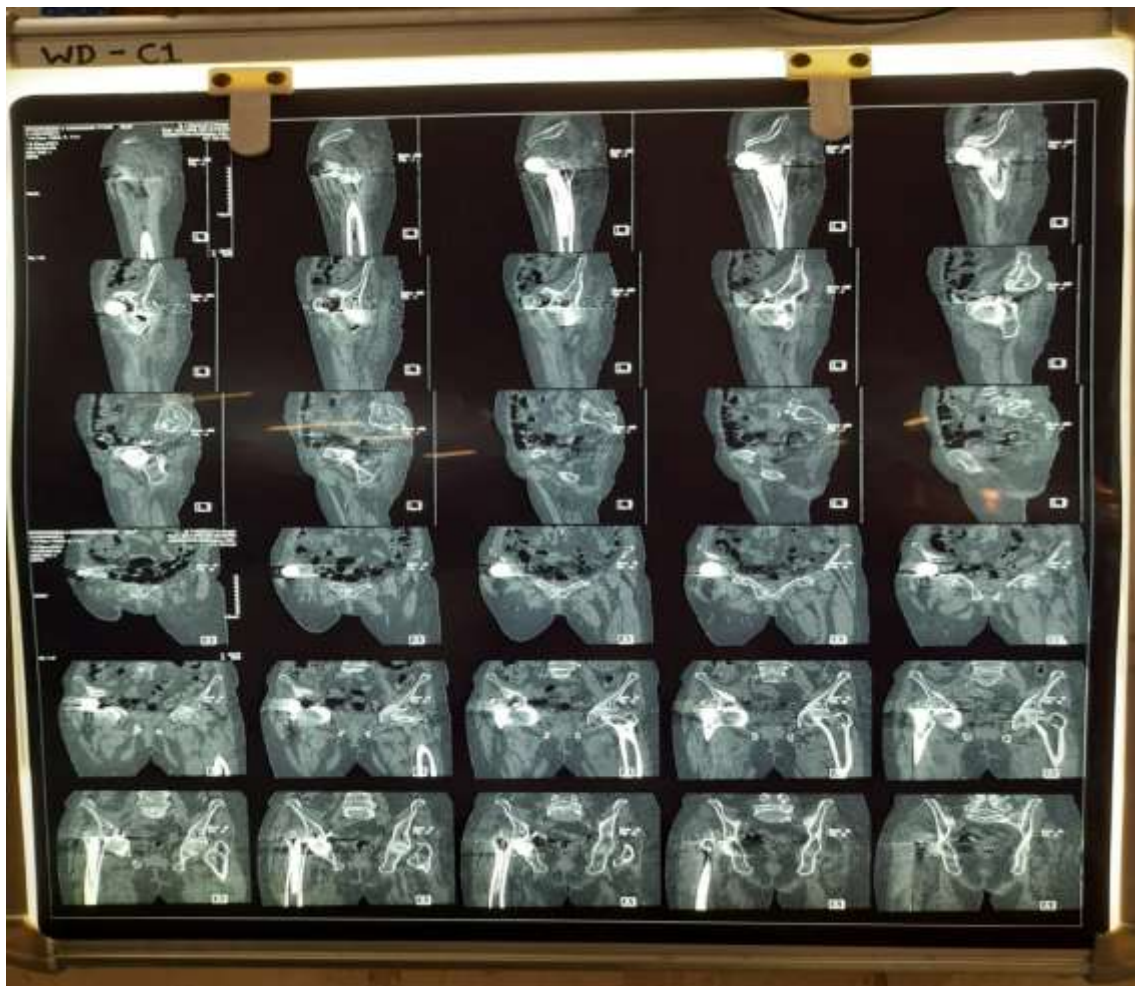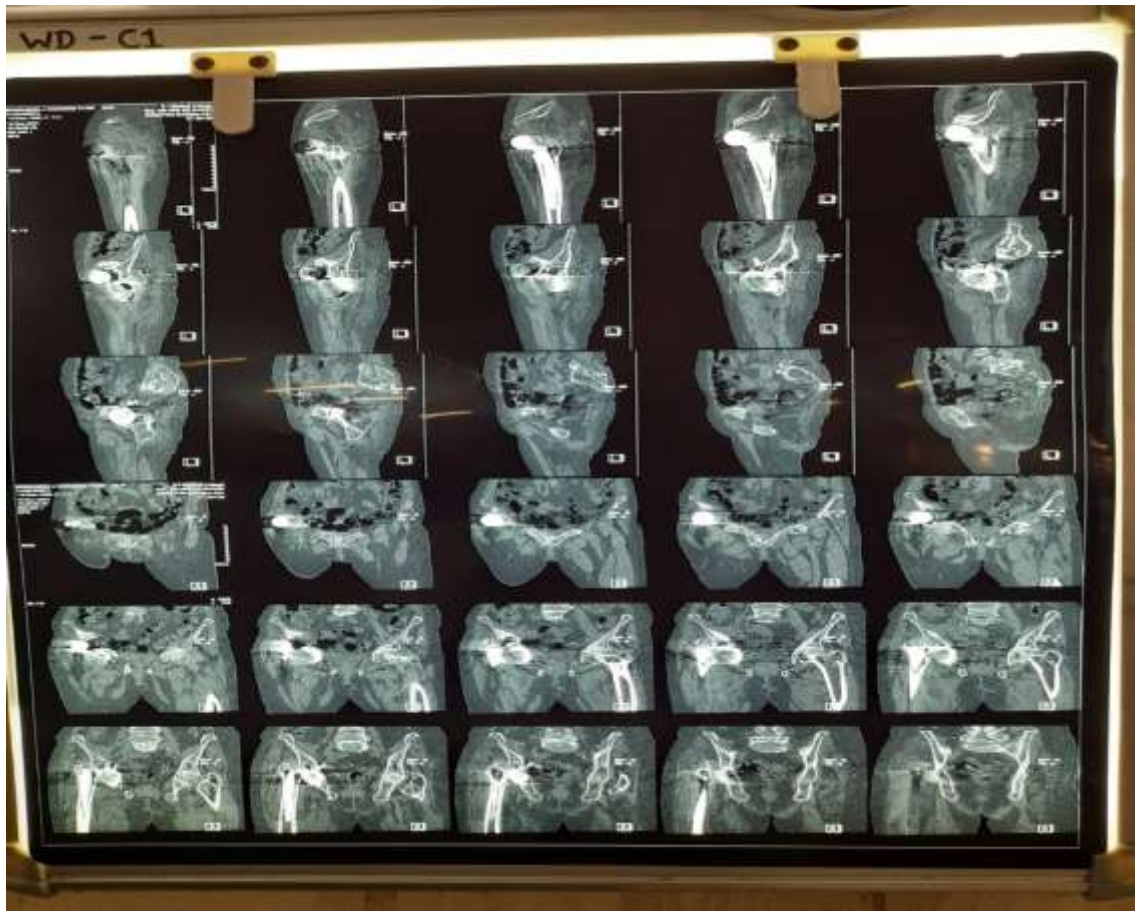**Fig 4:** X-ray Hip with femur AP, crossstable showing dislocated THR

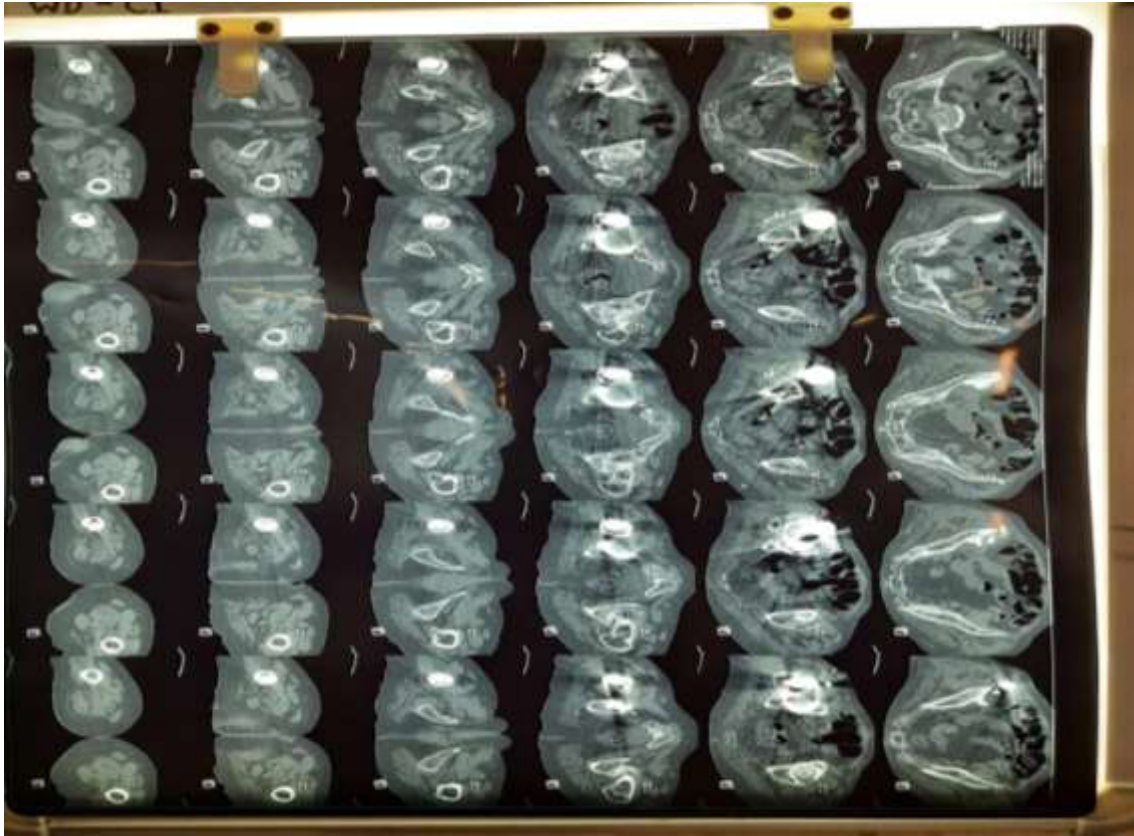

**Fig 5:** X-Ray Hip with femur AP, crosstable showing dislocated THR



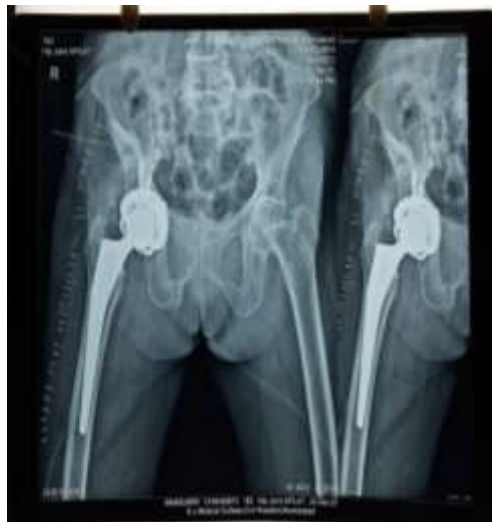**Fig 6:** 3DCT PBH – showing dislocated THR





**Fig 7:** MRI showing dislocated THR

### Post op xray



**Fig 8:** Post op Xray PBH and hip with femur AP after revision THR

### Management of Unstable Hip Arthroplasties

THA dislocation always requires medical intervention as self-reduction or reduction by a layperson without anesthesia is not possible. Immediate admission to a hospital, preferable where arthroplasties are performed, is crucial.

**History Taking:** Ask about the history of adequate trauma, or the sequence of motions that led to the dislocation. How long ago was the primary arthroplasty performed and is it the first incident or recurrent. Ideally, a copy of so-called prosthesis pass which identifies the components of the prosthesis should be added to the patient's medical records.

**Physical Examination:** The affected leg is shortened and

shows malrotation.

**Radiography:** Anterior-posterior view of the pelvis and, where possible, a second plane to rule out implant loosening or periprosthetic fracture.

A CT scan is indicated to enable 3-dimensional evaluation of component positioning, where conventional radiography findings are inconclusive with regard to implant malpositioning or loosening.

**Laboratory Tests:** To rule out inflammation and prosthetic joint infection. joint aspiration plus cell count should be performed, especially with late dislocation, because of the higher coincidence with septic loosening.

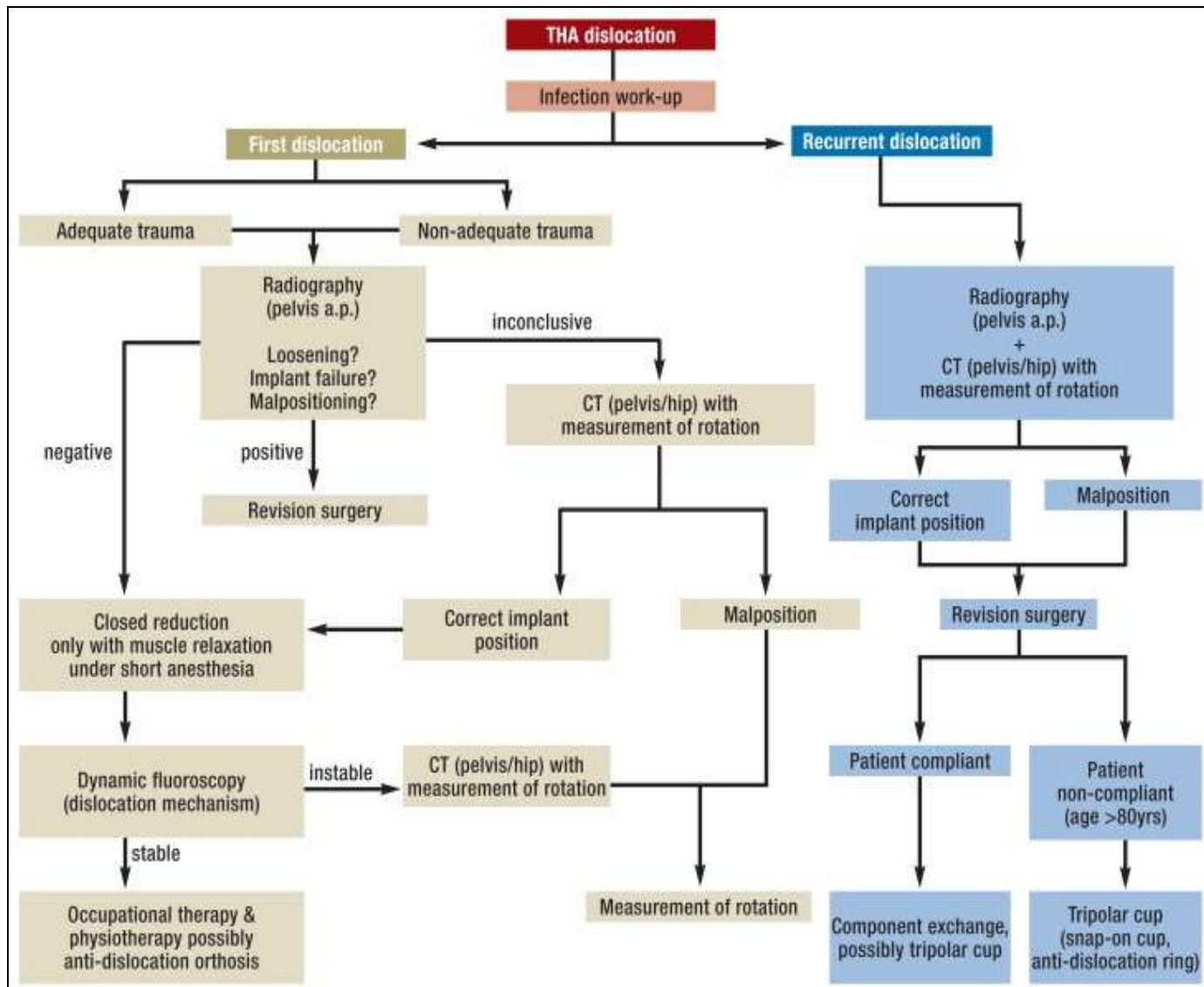


Fig 9: Flowchart showing management algorithm for dislocated THR

If the CT scan is not suggestive of malpositioning or loosening or can only be undertaken with a delay, reduction should be performed under short anesthesia in the operating room during the fasting interval.

Immediate reduction is essential. In case of concomitant compression of blood vessels and nerves.

The sufficiency of the pelvis-trochanter soft tissues and the dislocation mechanism are evaluated under dynamic fluoroscopy. A femoral head with distractibility of more than 1 cm is indicative of pelvis-trochanter insufficiency.

Conservative treatment with occupational therapy and physiotherapy can be initiated where movement stability is achieved after reduction. Commercially available orthoses, primarily limiting flexion and adduction, offer both the patient and the doctor a certain degree of security and are openly discussed with the patient.

Revision surgery is required in patients in whom dynamic fluoroscopy reveals instability. In patients with soft tissue insufficiency, soft tissue tension can be increased without extending the leg by increasing the offset, the distance between the femoral stem and the hip joint rotation center. In addition, techniques, such as capsule suture, fascial tightening and the use of attachment tubes, as well as a combination of these techniques are available. The head-neck ratio should always be optimized.

Surgical revision should generally be considered in patients

with recurrent dislocations. In case of component malpositioning, it is necessary to perform a component exchange. In patients with muscular or coordination deficits, tripolar head systems may be used which allow movement of a mobile polyethylene cup both in the bone-anchored socket and along the head of the prosthesis. This design enables recentering of the joint with shifting of the inlay in the acetabular component when the neck of the prosthesis gets in contact with the polyethylene inlay. This implant has the disadvantage in hip revision surgery that it offers limited modularity and does not allow screw augmentation for cup anchoring. Over-hemispheric enclosure of the head are rarely used due to their high failure rates, constrained inlays or snap-in cups with circular.

**Conclusion**

Dislocation following total hip replacement can be extremely traumatizing for patients. Thus, dislocation prophylaxis is essential. Apart from preoperative risk assessment, this includes proper surgical technique with optimized alignment of the components, soft-tissue balancing and head-neck ratio, as well as adequate surgical experience, proper post operative orders, physiotherapy and follow up. Treatment of instability after total hip replacement should follow a standardized algorithm.

**References**

1. Hutten D. Luxations et subluxations des prothèses totales de hanche J Duparc (Ed.), Cahiers d'enseignement de la SOFCOT, 55, Elsevier, Paris. 1996;55:19-46.
2. Goutallier D, Garabadian JM, Allain J, Bernageau J. Influence des torsions osseuses des membres inférieurs sur l'apparition des gonarthroses fémorotibiales latéralisées Rev Chir orthop. 1997;83(7):613-621.
3. Le Mouel S, Allain J, Goutallier D. Analyse actuarielle à 10 ans d'une cohorte de 156 prothèses totales de hanche cimentées à couple de frottement alumine/polyethylene Rev Chir Orthop. 1998;84(4):338-345.
4. Allain J, Lemouel S, Goutallier D, Voisin MC. Poor eight-year survival of cemented zirconia-polyethylene total hip replacements J Bone Joint Surg (Br). 1999 Sep;81(5):835-842.
5. Nishii T, Sugano N, Miki H, Takao T, Yoshikawa H. Influence of component positions on dislocation: computed tomographic evaluations in a consecutive series of total hip arthroplasty J Arthroplasty. 2004 Feb 1;19(2):162-166.
6. Nishihara S, Sugano N, Nishii T, Ohzono K, Yoshikawa H. Measurements of pelvic flexion angle using three-dimensional computed tomography Clin Orthop. 2003 Jun 1;411:140-151.
7. Miam SW, Truchly G, Pfum FA. Computed tomography measurement of acetabular anteversion and retroversion in total hip arthroplasty Clin Orthop. 1992 Mar 1(276):206-209.
8. Olivecrona H, Weidenhielm L, Olivecrona L, Beckman MO, Stark A, Noz ME. A new CT method measuring cup orientation after total hip arthroplasty: A study of 10 patients Acta Orthop Scand. 2004 Jan 1;75(3):252-260.
9. Pinoit Y, Girard J, May O, Ala Eddine T, Laffargue P, Cotten A, *et al.* Influence de l'équilibre pelvien sur la mesure tomodensitométrique de l'orientation des cupules de prothèse de hanche: Analyse de 56 prothèses instables et de 59 cas témoin Rev Chir Orthop. 2007;93(Suppl. 4):S85
10. Ala Eddine T, Migaud H, Chantelot C, Cotten A, Fontaine C, Duquenois A. Variations of pelvic anteversion in the lying and standing positions: Analysis of 24 control subjects and implications for CT measurement of position of a prosthetic cup Surg Radiol Anat. 2001 Jun;23(2):105-110
11. De Thomasson E, Guinguand O, Terracher R, Mazel C. Rôle de la courbure rachidienne sagittale dans la survenue des luxations précoces après reprise de prothèse totale de hanche. À propos d'une analyse prospective de 49 reprises de prothèses totales Rev Chir Orthop. 2004 May 1;90(3):226-231.
12. Andre S, Feuillade de Cauvin P, Tiberi F, Postel M. Luxations des prothèses totales de type Charnley modifiées Kerboull Rev Chir Orthop. 1983;69(6):447-453
13. Fontes D, Benoit J, Lortat-Jacob A, Didry R. La luxation des prothèses totales de hanche. Validation statistique d'une modélisation, à propos de 52 cas Rev Chir Orthop. 1991;77(3):163-170
14. Lewinnek GE, Lewis JL, Tarr R, Compere CL, Zimmermann JR. Dislocations after total hip replacement arthroplasties J Bone Joint Surg (Am). 1978 Mar 1;60(2):217-220.