

E-ISSN: 2395-1958
P-ISSN: 2706-6630
IJOS 2022; 8(3): 71-77
© 2022 IJOS
www.orthopaper.com
Received: 13-04-2022
Accepted: 02-06-2022

Dr. Premkumar P
Post Graduate, Department of
Orthopedics, Mahatma Gandhi
medical college and research
Institute, Puducherry, India

Dr. Ram Kumar S
Assistant Professor, Department
of Orthopedics, Mahatma
Gandhi medical college and
research Institute, Puducherry,
India

Dr. Rajarajan D
Assistant Professor,
Department of Orthopedics
Mahatma Gandhi medical college
and research Institute,
Puducherry, India

Dr. Nandakumar R
Professor, Department of
Orthopedics, Mahatma Gandhi
medical college and research
Institute, Puducherry, India

Outcomes of minimally invasive spine decompression in lumbar spinal stenosis and intervertebral disc prolapse: A prospective study

Dr. Premkumar P, Dr. Ram Kumar S, Dr. Rajarajan D and Dr. Nandakumar R

DOI: <https://doi.org/10.22271/ortho.2022.v8.i3b.3172>

Abstract

Introduction: Lumbar spinal stenosis and intervertebral disc prolapse are the most common cause of back pain and sciatica. Both conditions are traditionally treated by a midline lumbar incision, after which the paraspinal muscles are elevated from the spinous processes and lamina and retracted laterally and extensively. Minimally invasive lumbar decompression is a procedure designed to debulk hypertrophied ligamentum flavum and removal of the herniated disc with a goal of relieving neural compression. Our study aimed to assess the outcome in terms of improvement in neurology, extent of pain relief in the postoperative period and complications in patients undergoing minimally invasive spine decompression.

Methodology: The present study was conducted in a tertiary care hospital. A total of 16 patients who satisfied both the inclusion and exclusion criteria and gave informed consent were recruited for the study from January 2020 to March 2021. All patients underwent minimally invasive spine decompression by tubular retractors. Outcome measures used are Visual analog score for leg pain and back pain, Modified Oswestry Disability Index (MODI), Roland Morris Disability Questionnaire (RMDQ) and neurological examination preoperatively and postoperatively at 6 weeks, 3 months and 6 months.

Results: Out of 16 patients, ten patients had intervertebral disc prolapse and six had lumbar spinal stenosis. L4L5 was the most common level seen in our patients. Mean pre-operative VAS score was 6.88 and 4.44 for leg pain and back pain, there was significant reduction at the end of 6 months. Mean preoperative MODI score was 66.38, preoperatively 13 patients (81%) had crippling back pain, 3 patients (18.75%) had severe disability. At the end of 6 months, all 16 patients had less than minimal disability. Mean preoperative roland morris disability score was 11.31 ± 0.61 . There was a significant mean improvement at 6 months postoperatively from the preoperative baseline score. Nine patients (43.8%) had a motor deficit of which 4 patients had a significant motor power improvement. Two patient had complications, one patient had CSF leak intraoperatively and the other patient developed a superficial wound infection.

Conclusion: Minimally invasive spine surgery is an excellent surgical option in patients with lumbar spinal stenosis and prolapsed intervertebral disc. Patients who underwent minimally invasive spine decompression had satisfactory functional outcome in terms of pain relief, minimal hospital stay and early return to day to day activities.

Key Words: Intervertebral disc prolapse, lumbar spinal stenosis, minimally invasive spine decompression, roland morris disability questionnaire, modified oswestry disability index, mis tubular discectomy

Introduction

Intervertebral disc prolapse (IVDP) and lumbar spinal stenosis (LSS) are two most common health conditions affecting lumbar spine and is a leading cause of disability, negatively impacting work performance and overall well-being^[1]. LSS is a degenerative spinal condition causing narrowing of the spinal canal by ligamentous or bony pathologies like ligamentum flavum hypertrophy, herniated disc, facet hypertrophy and spondylolisthesis leading to symptoms such as neurogenic claudication and back pain^[2]. IVDP is a common cause of sciatica, where the herniated disc compresses exiting or traversing nerve roots. The conventional treatment for both, IVDP and LSS has been decompression by laminectomy or discectomy^[3,4].

Corresponding Author:
Dr. Premkumar P
Post Graduate, Department of
Orthopedics, Mahatma Gandhi
medical college and research
Institute, Puducherry, India

In spite of years of advancement in spine surgery, direct decompression of the neural elements by removal of herniated portion of the intervertebral disc, bone structures such as the lamina, medial facet, and ligamentum flavum, all that can cause central and lateral recess stenosis, is still the gold standard treatment for both disorders. Both conditions are traditionally treated by a midline lumbar incision, after which the paraspinal muscles are separated from the spinous processes and lamina and retracted laterally and extensively causing significant muscle damage [5].

In minimally invasive spine decompression, the paraspinal muscle is not separated from the spinous processes, favouring a lateral incision and muscle splitting technique over a subperiosteal dissection technique used in earlier treatments. Instead, the paraspinal muscle fibres are separated to create a spinal column corridor. This method is intended to result in less soft tissue injury and hence less postoperative pain.⁶ Our study aimed to assess the outcome in terms of improvement in neurology, extent of pain relief in the postoperative period and complications in patients undergoing minimally invasive spine decompression by tubular retractors.

Methodology

We conducted a prospective interventional study between January 2020 – May 2021 in a tertiary care hospital with Institutional Human Ethical Committee (IHEC) approval. Patients with low back ache and leg pain between 18-75 age who were diagnosed with lumbar canal stenosis and intervertebral disc prolapse who failed to respond to trial of conservative management for 6 weeks were included. Patients with acute cauda equina syndrome, history of previous spine surgery and neoplastic lesion were excluded.

After obtaining informed and written consent, 16 patients were included in the study. Socio-demographic details such as age, sex, gender were obtained. Neurological examination was done and deficits were documented. Patient reported outcome measures (PROM) were used preoperatively and postoperatively to assess the pain severity and functional disability. Visual analogue score (VAS) for both low back pain and leg pain, Modified Oswestry Disability Index (MODI), Roland Morris Disability Questionnaire (RMDQ) were the outcome measures used. All patients underwent minimally invasive spine decompression by tubular retractors under general anesthesia (Fig 1, 2, 3). Postoperatively patients were shifted to post-operative ward following surgery. Patients were mobilised on the night of surgery or postoperative day 1 and discharged after wound inspection and dressing. Appropriate physiotherapy was advised to the patients. Suture removal was done on postoperative day 12 in outpatient department. Then patients were followed up at 6 weeks, 3 months, 6 months and outcomes were assessed. Statistical analysis was performed using Statistical Package for Social Sciences (SPSS) for windows 26.0. (SPSS, Inc. Chicago, Illinois). Descriptive statistics were applied for demographic details. Categorical variables were presented in the form of a frequency. Continuous variables were presented as Mean \pm Std. Deviation form. Paired t test was applied to compare pre-operative and subsequent follow-up such as 6 weeks, 3 months and 6 months for all the parameters.

Results

3 patients belonged to 21-40 years of the age group and 13

patients belonged to 41-60 years of the age group. Patients age ranges from 24 years to 58 years. 9 patients (43.8%) were male and 7 patients (56.2%) were female. Out of 16 patients, 10 (62.5%) patients had intervertebral disc prolapse and 6 patients (37.5%) had lumbar spinal stenosis

L4L5 (56.3%) was the most commonly involved level, 9 patients had L4L5 level, 3 patients had L3L4 (18.8%) and 3 patients had L5S1(18.8%). Only one patient (6.3%) had L2L3 involvement who had sacralised L5. Mean preoperative VAS score was 6.88 ± 1.25 for leg pain, there was a significant reduction in the leg pain postoperatively at 6 weeks, 3 months and 6 months. There was a 76%, 88% and 92.7% decrease in leg pain at 6 weeks, 3 months and 6 months postoperatively. Mean preoperative VAS score for backache was 4.44 ± 1.50 , there was significant reduction in the postoperatively 6 weeks, 3 months and 6 months. There was 56%, 65% and 70% decrease in back ache at 6 weeks, 3 months and 6 months postoperatively.

Mean MODI was observed highest pre operatively 66.38 ± 8.26 . At 6 weeks it was 24.50 ± 6.21 , at 3 months it was 13.94 ± 4.71 . It was lowest at 6 months 6.69 ± 3.77 . There was a significant reduction in the disability was seen in the postoperative period at 6 weeks, 3 months and 6 months.

Roland Morris Disability was observed highest pre-operatively 11.31 ± 2.57 , followed by 6 weeks 4.31 ± 1.30 , 3 months 2.75 ± 0.85 and 6 months 1.38 ± 0.61 . There was significant reduction in disability postoperatively at 6 weeks, 3 months and 6 months. There was a mean improvement of 61.25 ± 10.47 at 6 weeks, 74.93 ± 8.65 at 3 months and 87.60 ± 5.73 at 6 months postoperatively from the preoperative baseline score.

Preoperatively 13 patients (81%) had crippling back pain, 3 patients (18.75%) had severe disability. There was a significant reduction postoperatively at 6 weeks and 3 months. At 6 months, all 16 patients had less than minimal disability. Two patients had complications. One patient had CSF leak intraoperatively and other patient has superficial surgical site infection postoperatively which settled with oral antibiotics and regular dressing. Nine (43.8%) out of 16 patients had a motor deficit. 4 out of 9 patients had +1 motor power improvement by the end of six months. Average hospital stay of 4 days. Patients without intraoperative or postoperative complications were discharged on postoperative day 1 or postoperative day 2 after wound inspection. Minimum hospital stay was 3 days.

Table 1: Patient demographics

Gender	Number	Percentage (%)
Female	7	43.8
Male	9	56.2
Total	16	100
Pathology		
IVDP	10	62.5
LCS	6	37.5
Total	16	100
Level		
L2L3	1	6.3
L3L4	3	18.8
L4L5	9	56.3
L5S1	3	18.8
Total	16	100

Table 2: Comparison of Visual Analog Score for Leg Pain, back pain

Visual Analog Score for Leg Pain		Mean	Std. Deviation	p-value
Pair 1	Pre-Operative	6.88	1.25	0.001*
	6 weeks	1.63	.88	
Pair 2	Pre-Operative	6.88	1.25	0.001*
	3 months	1.19	0.75	
Pair 3	Pre-Operative	6.88	1.25	0.001*
	6 months	0.50	0.63	
Visual Analog Score for Back Pain				
Pair 1	Pre-Operative	4.44	1.50	0.001*
	6 weeks	1.94	0.68	
Pair 2	Pre-Operative	4.44	1.50	0.001*
	3 months	1.56	0.62	
Pair 3	Pre-Operative	4.44	1.50	0.001*
	6 months	1.31	0.63	

*Indicates statistically significance difference ($p < 0.05$)

Table 3: Comparison of Modified Oswestry Disability

Modified Oswestry Disability		Mean	Std. Deviation	p-value
Pair 1	Pre-Operative	66.38	8.26	0.001*
	6 weeks	24.50	6.21	
Pair 2	Pre-Operative	66.38	8.26	0.001*
	3 months	13.94	4.71	
Pair 3	Pre-Operative	66.38	8.26	0.001*
	6 months	6.69	3.77	

*Indicates statistically significance difference ($p < 0.05$)

Table 4: MODI Interpretation

MODI	Preoperative		6 weeks		3 months		6 months	
	N	%	N	%	N	%	N	%
0-20%	0	0	6	37.5	14	87.5	16	100
20-40%	0	0	10	62.5	2	12.5	0	0
40-60%	3	18.75	0	0	0	0	0	0
60-80%	13	81.25	0	0	0	0	0	0
80-100%	0	0	0	0	0	0	0	0

Table 5: Comparison of Roland Morris Disability

Roland Morris Disability		Mean	Std. Deviation	p-value
Pair 1	Pre-Operative	11.31	2.57	0.001*
	6 weeks	4.31	1.30	
Pair 2	Pre-Operative	11.31	2.57	0.001*
	3 months	2.75	0.85	
Pair 3	Pre-Operative	11.31	2.57	0.001*
	6 months	1.38	0.61	

*Indicates statistically significance difference ($p < 0.05$)

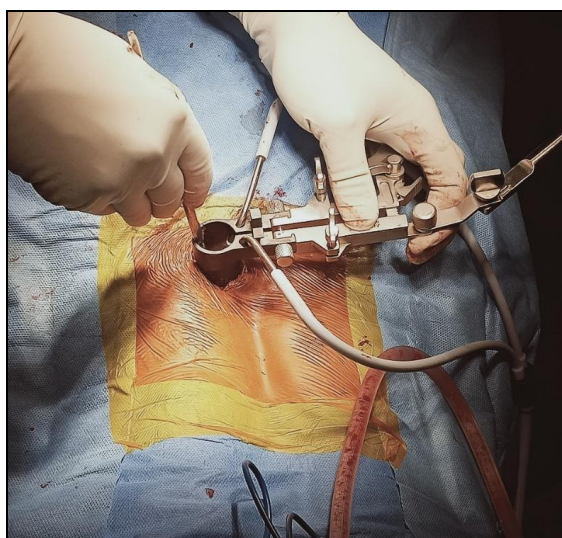


Fig 1: Demonstration of the port being situated through the muscle-splitting approach and docked on the lamina immediately above the disc herniation. The port is then attached to the table.

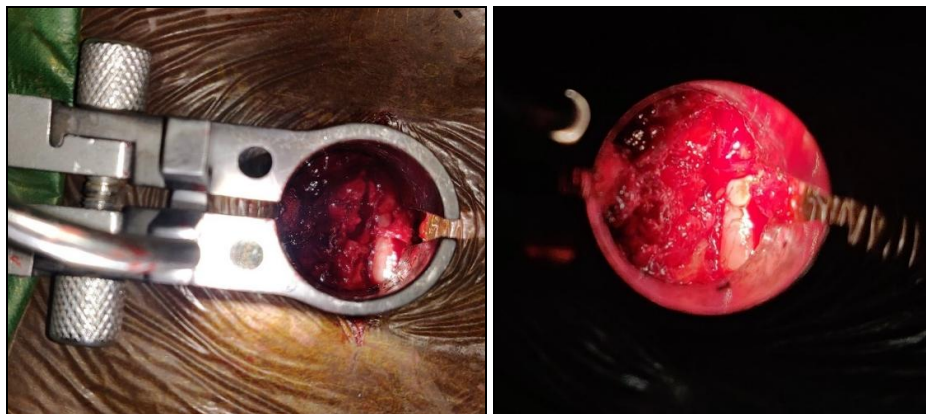


Fig 2: (a, b) Visualisation of Dura following left laminotomy in a 51-year-old female patient with Intervertebral disc prolapse L2L3 with left radiculopathy

Discussion

Lumbar spinal stenosis, a degenerative condition, is referred to as narrowing of central spinal canal, vertebral foramina, and/or lateral recesses, causing impingement on nearby neurologic structures. This condition largely affects the elderly and can cause a variety of debilitating symptoms, including back pain and radicular leg pain and neurogenic claudication. Similar symptoms can also occur due to vertebral disc herniation causing impingement on neurologic structures. In the absence of progressive neurologic deficit or intractable pain, first-line treatment is nonoperative, consisting of physical therapy and pharmacotherapy (analgesics, steroids)^[7].

When nonoperative measures fail to provide relief, surgical decompression of neural element significantly alleviated symptoms^[8, 9]. Surgical techniques vary, but traditional “open” lumbar decompression procedures involve subperiosteal dissection of the paraspinal musculature to facilitate laminectomy and/or laminotomy. The adaptation of minimally invasive spine techniques for single-level surgery allowed for equally efficacious lumbar decompressions with the goal of decreasing postoperative pain, muscle disruption, blood loss, and length of hospitalization^[8]. Several studies have reported that single-level MIS decompression of lumbar compressive pathology leads to improved postoperative functional outcome and pain scores^[10].

As surgeons expertise with methods has grown in recent times, indications for MIS had escalated dramatically. The usual open foraminotomies, discectomies, and laminectomies have been superseded by microendoscopic and discectomies, microscopic foraminotomies and laminectomies by a lateral incision and tubular dilator retraction^[11, 12]. Surgeons increasing comfort with the tube allows them to perform these procedures in the cervical, thoracic, and lumbar spine.

The majority of MIS techniques currently use progressive dilators to dilate through the muscle onto the targeted level of the facet. Through the biggest dilation tube, interlaminar space is viewed, and inferior margin of lamina is removed with a Kerrison or drill. For foraminotomies and discectomies, a piece of the medial facet is frequently resected^[13]. Drills, pituitaries, Kerrisons and knives are examples of long and angled devices that were invented for allowing visibility as well as dissection. The endoscope or microscope can be utilised for visualisation.

When the endoscope or microscope is angled medially in the lumbar spine, it can decompress the contralateral lateral recess, allowing for minimally invasive laminectomies^[14]. A portion of the inferior spinous process can be excised if more

visibility is required. Patients have shown that these procedures produce similar, if not better, results than standard open approaches^[15 16].

Neurogenic claudication, which is caused by lumbar spinal stenosis, causes excruciating discomfort in the lower back and extremities, as well as significant functional limitations, particularly in the elderly^[17]. Walking causes neurogenic claudication symptoms, which are eased by sitting. Spinal extension (walking and standing) is thought to cause neurogenic claudication by reducing cross-sectional areas of central canal, which causes painful nerve root ischemia and nerve root compression. Spinal flexion relieves the compression by allowing the central canal to widen, resulting in pain alleviation and the remission of those symptoms. Contrary to radicular pain symptoms, neurogenic claudication symptoms are not frequently dermatomal in distribution. Radicular pain is caused by inflammation of a nerve root and radiates in a dermatomal pattern from the back and buttocks into the leg^[18, 19]. Neurogenic claudication patients nearly usually have degenerative soft tissue and bone disease as a result of a combination of disc protrusion, thickened or ossified ligamentum flavum, facet joint hypertrophy, or osteophytes. According to Hansson and colleagues^[20], LFH was responsible for 50 to 85 percent of central canal narrowing, which lead to the conclusion that the LF played a prominent role in load-induced lumbar spinal canal narrowing. Furthermore, a high incidence of multiple-level stenosis is a typical feature of neurogenic claudication^[21].

There have been a few publications suggesting that patients undergoing multilevel decompressions for LSS had worse outcome than those who underwent single-level surgery. Ulrich *et al.*^[22] have recently reported similar long-term patient-reported outcome measures outcomes but significantly higher rates of perioperative complications in patients undergoing multilevel decompressions. Adilay and Guclu reported worse outcome scores for patients undergoing multilevel decompressions, in addition to higher perioperative complications^[23]. These findings are likely a reflection of the increased magnitude of the surgery and possibly greater age or comorbidities in those patients who require multilevel decompression. In that regard, the use of MIS techniques is appealing when developing surgical treatment plans for such patient populations. Therefore, our study purpose was to assess the outcome in terms of improvement in neurology, extent of pain relief in the postoperative period and complications in patients undergoing minimally invasive spine decompression.

The present study demonstrates MIS approaches towards LSS

and IVDP resulted in prominent changes in muscle damage at a mean follow-up of half a year. In our study, a significant reduction was observed in the leg pain postoperatively at 6 weeks, 3 months & 6 months. There was a 76%, 88% and 92.7% decrease in leg pain at 6 weeks, 3 months and 6 months postoperatively. There was also significant reduction in the postoperatively 6 weeks, 3 months and 6 months and patients had early return to daily activities. There was 56%, 65% and 70% decrease in back ache at 6 weeks, 3 months and 6 months postoperatively. These findings are in accordance with a case study performed by Alimi *et al.* [24], studied in which 110 patients one, two, or three levels of microsurgical tubular laminotomy from L2 to S1. A subgroup of patients with similar bilateral buttock and leg pain were investigated, and the unilateral method for bilateral decompression resulted in a bilaterally equal reduction in VAS values which demonstrates the ability of unilateral approach to accomplish bilateral decompression. Almost three-quarters of the people in the study reported significant pain relief. Patients with equal bilateral buttock & leg discomfort saw a bilaterally identical significant reduction in VAS scores, demonstrating that a unilateral technique can provide clinically relevant bilateral decompression [24]. Rosen *et al.* did a study on 57 patients over the age of 75 and found that their VAS and ODI scores improved without any major complications [25]. When Aleem and Rampersaud compared these scores between old patients (age >70 years) and younger patients (age < 70 years), they found similar results [26]. In our study, out of 16, about 13 patients (81.2%) belonged to 41-60 years of the age group.

Our study employed the Modified Oswestry disability index to measure both pain and functional status and to evaluate disability caused by lower backache. There was a significant reduction in the disability in the postoperative period at 6 weeks, 3 months and 6 months. Preoperatively 13 patients (81%) had crippling back pain, 3 patients (18.75%) had severe disability. There was a significant reduction postoperatively at 6 weeks and 3 months. At end of 6 months, all 16 patients had less than minimal disability. The results of minimally invasive spine decompression patients in our study are similar and compares favourably to 2-year MILD results previously reported. Patients showed a statistically significant reduction in pain and statistically significant improvement in physical function and mobility as measured by the ODI and ZCQ domains from baseline to 2 years in a report by Chopko in 2013 and a recent study by Staats *et al.* in 2018 [27 28]. Patients were satisfied two years post-surgery, according to the mean ZCQ patient satisfaction score. The SPORT trial, a randomised controlled trial with a concurrent observational cohort, provides best known data supporting surgical treatment of lumbar stenosis [8].

Our study used the Roland Morris Disability Questionnaire to study self-rated physical disability caused by low back pain. There was significant reduction in disability at 6 weeks, 3 months & 6 months postoperatively. It could be due to minimally invasive decompression decreasing surgical trauma, allowing earlier mobilization post-surgery.

There was significant difference in SF-12 physical component score at 6 weeks, 3 months and 6 months compared to preoperative score and with respect to SF-12 Mental component, where a significant improvement was observed in 6 weeks postoperative period compared to pre-operative score. In a systematic review conducted in 2016, Phan *et al.* found that satisfaction rates in the minimally invasive group were considerably higher compared to open group (84 percent

vs. 75.4 percent), whereas back pain Visual Analog Scale scores were lower [29]. There was, however, less blood loss and a shorter stay in the hospital (2.1 days). Although dural injuries and CSF fluid leaks were comparable, the minimally invasive cohort had lower reoperation rates (1.6 percent vs. 5.8%), which was not significant when only randomised evidence was included.

Our data was not in line with SF-12 findings of Khanna *et al.* whose study population also demonstrated sustained and statistically significant improvement beyond Minimum clinically importance difference in all Patient-Reported Outcome Measures (PROM) categories except for the SF-12 MCS at the 3-month, 6-month, 1-year, and 2-year followup [30].

Our study reported complications in 2 out of 16 patients, one patient had intraoperative dural tear and other patient had superficial wound infection. The spinous processes, interspinous ligaments, bilateral lamina, sections of the facet joints and capsule, and LF are all resected extensively for typical LSS and IVDP treatment. These classic operations of a wide decompressive laminectomy, medial facetectomy, and foraminotomy have been used for decades with varying degrees of success [31]. However, such extensive open decompression is associated with significant pain, hospitalization, morbidity, a prolonged recovery period, and an increased incidence of complications. Deep venous thrombosis, pulmonary embolism, pulmonary atelectasis, pneumonia, urinary tract infections, ileus, and narcotic dependency are some of these potentially devastating sequelae. These issues arise as a result of a heightened surgical stress response. Tissue trauma is the most critical event that triggers stress response [31]. Extensive surgical tissue trauma can also have delayed long-term functional consequences. Loss of the midline supraspinous/interspinous ligament complex can lead to a loss of flexion stability, thereby increasing the risk of delayed spinal instability [32 33]. After considerable muscle retraction during open surgical decompression, Mayer *et al.* found a reduction in paraspinal muscular strength and atrophy [34]. See and Kraft echoed these concerns in their observation of chronic denervation and electromyographic abnormalities of the paraspinal muscles after open surgery [35]. Sihvonen *et al.* then linked this iatrogenic paraspinal muscle injury to a higher incidence of postoperative failed back syndrome [36]. MIS procedures could successfully reduce the extent of tissue damage, thus proving to be a valuable tool in reducing the probability of these unfavourable outcomes. Contrary to our study findings, Ha *et al.* in a recent study reported no complications following minimally invasive unilateral laminectomy for bilateral decompression using a tubular retractor [37].

Although open surgery is frequently seen as an excellent option and may be required for some subjects, MISD may be used for patients who may not tolerate a more invasive procedure and also it has a unique role as a solution when conservative therapies have failed, and the risks of more invasive approaches may not be warranted. It is important to note that MIS does not affect surgical options for the few patients who do not respond to this treatment. Because of the very minimally invasive approach and targeted subtle decompression, there is minimal or no scar tissue that would increase the risk of possible future open spine surgery. Patients that opt for open surgical decompression can no longer be candidates for less invasive treatments, which is another crucial factor in treatment planning [28].

Our study reported an average hospital stay of 4 days. Patients

without intraoperative or postoperative complications were discharged on postoperative day 1 or postoperative day 2 after mobilisation and wound inspection. The minimum hospital stay was three days, which matched findings from a systematic review conducted by Phan and colleagues in 2016, which found reduced blood loss and a shorter hospital stay (2.1 days)^[29]. Although dural injuries & CSF fluid leaks were similar, the minimally invasive cohort had reduced reoperation rates (1.6 percent vs. 5.8%), which was not significant when only randomised evidence was included.

Minimally invasive spine decompression using tubular retractors is an excellent surgical option for patients suffering from lumbar spinal stenosis and intervertebral disc prolapse due to its minimally invasive nature, high success rate, and long-term outcomes.

References

- Vos T, Flaxman AD, Naghavi M, Lozano R, Michaud C, Ezzati M, *et al.* Years lived with disability (YLDs) for 1160 sequelae of 289 diseases and injuries 1990-2010: a systematic analysis for the Global Burden of Disease Study 2010. *Lancet*. 2012 Dec 15;380(9859):2163-96.
- Garfin SR, Herkowitz HN, Mirkovic S. Spinal stenosis. Instructional course lectures. 2000;49:361-74.
- Nath R, Middha S, Gupta AK, Nath R. Functional outcome of surgical management of degenerative lumbar canal stenosis. *Indian J Orthop*. 2012;46(3):285-90.
- Wankhade UG, Umashankar MK, Reddy BSJ. Functional Outcome of Lumbar Discectomy by Fenestration Technique in Lumbar Disc Prolapse – Return to Work and Relief of Pain. *J Clin Diagn Res*. 2016 Mar;10(3):RC09-RC13.
- Errico TJ, Fardon DF, Lowell TD, NASS. Open discectomy as treatment for herniated nucleus pulposus of the lumbar spine. *Spine J*. 2003 Jun;3(3 Suppl):45S-49S.
- Deen HG, Fenton DS, Lamer TJ. Minimally invasive procedures for disorders of the lumbar spine. *Mayo Clin Proc*. 2003 Oct;78(10):1249-56.
- Lurie J, Tomkins-Lane C. Management of lumbar spinal stenosis. *BMJ*. 2016 Jan 4;352:h6234.
- Weinstein JN, Tosteson TD, Lurie JD, Tosteson ANA, Blood E, Hanscom B, *et al.* Surgical versus nonsurgical therapy for lumbar spinal stenosis. *N Engl J Med*. 2008 Feb 21;358(8):794-810.
- Thomé C, Zevgaridis D, Leheta O, Bänzner H, Pöckler-Schöniger C, Wöhrle J, *et al.* Outcome after less-invasive decompression of lumbar spinal stenosis: a randomized comparison of unilateral laminotomy, bilateral laminotomy, and laminectomy. *J Neurosurg Spine*. 2005 Aug;3(2):129-41.
- Nerland US, Jakola AS, Solheim O, Weber C, Rao V, Lønne G, *et al.* Minimally invasive decompression versus open laminectomy for central stenosis of the lumbar spine: pragmatic comparative effectiveness study. *BMJ*. 2015 Apr 1;350:h1603.
- Thongtrangan I, Le H, Park J, Kim DH. Minimally invasive spinal surgery: a historical perspective. *Neurosurg Focus*. 2004 Jan 15;16(1):E13.
- Snyder LA, O'Toole J, Eichholz KM, Perez-Cruet MJ, Fessler R. The Technological Development of Minimally Invasive Spine Surgery. *Biomed Res Int*. 2014;2014:293582.
- An HS, Andersson G, Lieberman I, Riew D, Transfeldt E. Minimally invasive surgery for lumbar degenerative disorders: Part II. Degenerative disc disease and lumbar stenosis. *Am J Orthop (Belle Mead NJ)*. 2000 Dec;29(12):937-42.
- Lee P, Liu JC, Fessler RG. Perioperative results following open and minimally invasive single-level lumbar discectomy. *J Clin Neurosci*. 2011 Dec;18(12):1667-70.
- Dasenbrock HH, Juraschek SP, Schultz LR, Witham TF, Sciubba DM, Wolinsky JP, *et al.* The efficacy of minimally invasive discectomy compared with open discectomy: a meta-analysis of prospective randomized controlled trials. *J Neurosurg Spine*. 2012 May;16(5):452-62.
- Rahman M, Summers LE, Richter B, Mimran RI, Jacob RP. Comparison of techniques for decompressive lumbar laminectomy: the minimally invasive versus the "classic" open approach. *Minim Invasive Neurosurg*. 2008 Apr;51(2):100-5.
- Katz JN, Harris MB. Clinical practice. Lumbar spinal stenosis. *N Engl J Med*. 2008 Feb 21;358(8):818-25.
- Allegri M, Montella S, Salici F, Valente A, Marchesini M, Compagnone C, *et al.* Mechanisms of low back pain: a guide for diagnosis and therapy. *F1000Res*. 2016;5:F1000 Faculty Rev-1530.
- Bogduk N. On the definitions and physiology of back pain, referred pain, and radicular pain. *Pain*. 2009 Dec 15;147(1-3):17-9.
- Hansson T, Suzuki N, Hebelka H, Gaulitz A. The narrowing of the lumbar spinal canal during loaded MRI: the effects of the disc and ligamentum flavum. *Eur Spine J*. 2009 May;18(5):679-86.
- Mekhail N, Costandi S, Abraham B, Samuel SW. Functional and patient-reported outcomes in symptomatic lumbar spinal stenosis following percutaneous decompression. *Pain Pract*. 2012 Jul;12(6):417-25.
- Ulrich NH, Burgstaller JM, Held U, Winklhofer S, Farshad M, Pichierri G, *et al.* The Influence of Single-level Versus Multilevel Decompression on the Outcome in Multisegmental Lumbar Spinal Stenosis: Analysis of the Lumbar Spinal Outcome Study (LSOS) Data. *Clin Spine Surg*. 2017 Dec;30(10):E1367-75.
- Adilay U, Guclu B. Comparison of Single-Level and Multilevel Decompressive Laminectomy for Multilevel Lumbar Spinal Stenosis. *World Neurosurg*. 2018 Mar;111:e235-40.
- Alimi M, Hofstetter CP, Torres-Campa JM, Navarro-Ramirez R, Cong GT, Njoku I, *et al.* Unilateral tubular approach for bilateral laminotomy: effect on ipsilateral and contralateral buttock and leg pain. *Eur Spine J*. 2017 Feb;26(2):389-96.
- Rosen DS, O'Toole JE, Eichholz KM, Hrubec M, Huo D, Sandhu FA, *et al.* Minimally invasive lumbar spinal decompression in the elderly: outcomes of 50 patients aged 75 years and older. *Neurosurgery*. 2007 Mar;60(3):503-9; discussion 509-510.
- Aleem IS, Rampersaud YR. Elderly patients have similar outcomes compared to younger patients after minimally invasive surgery for spinal stenosis. *Clin Orthop Relat Res*. 2014 Jun;472(6):1824-30.
- Chopko BW. Long-term results of percutaneous lumbar decompression for LSS: two-year outcomes. *Clin J Pain*. 2013 Nov;29(11):939-43.
- Staats PS, Chafin TB, Golovac S, Kim CK, Li S, Richardson WB, *et al.* Long-Term Safety and Efficacy of Minimally Invasive Lumbar Decompression Procedure

- for the Treatment of Lumbar Spinal Stenosis With Neurogenic Claudication: 2-Year Results of MiDAS ENCORE. *Reg Anesth Pain Med*. 2018 Oct;43(7):789-94.
29. Phan K, Mobbs RJ. Minimally Invasive Versus Open Laminectomy for Lumbar Stenosis: A Systematic Review and Meta-Analysis. *Spine (Phila Pa 1976)*. 2016 Jan;41(2):E91-100.
 30. Khanna R, Malone H, Keppetipola KM, Deutsch H, Fessler RG, Fontes RB, *et al*. Multilevel Minimally Invasive Lumbar Decompression: Clinical Efficacy and Durability to 2 Years. *Int J Spine Surg*. 2021 Aug;15(4):795-802.
 31. Hurri H, Slätis P, Soini J, Tallroth K, Alaranta H, Laine T, *et al*. Lumbar spinal stenosis: assessment of long-term outcome 12 years after operative and conservative treatment. *J Spinal Disord*. 1998 Apr;11(2):110-5.
 32. Tsai RY, Yang RS, Bray RS. Microscopic laminotomies for degenerative lumbar spinal stenosis. *J Spinal Disord*. 1998 Oct;11(5):389-94.
 33. Tuite GF, Stern JD, Doran SE, Papadopoulos SM, McGillicuddy JE, Oyedijo DI, *et al*. Outcome after laminectomy for lumbar spinal stenosis. Part I: Clinical correlations. *J Neurosurg*. 1994 Nov;81(5):699-706.
 34. Mayer TG, Vanharanta H, Gatchel RJ, Mooney V, Barnes D, Judge L, *et al*. Comparison of CT scan muscle measurements and isokinetic trunk strength in postoperative patients. *Spine (Phila Pa 1976)*. 1989 Jan;14(1):33-6.
 35. See DH, Kraft GH. Electromyography in paraspinal muscles following surgery for root compression. *Arch Phys Med Rehabil*. 1975 Feb;56(2):80-3.
 36. Sihvonen T, Herno A, Paljärvi L, Airaksinen O, Partanen J, Tapaninaho A. Local denervation atrophy of paraspinal muscles in postoperative failed back syndrome. *Spine (Phila Pa 1976)*. 1993 Apr;18(5):575-81.
 37. Ha S, Hong Y, Lee S. Minimally Invasive Lumbar Spinal Decompression in Elderly Patients with Magnetic Resonance Imaging Morphological Analysis. *Asian Spine J*. 2018 Apr;12(2):285-93.