



International Journal of Orthopaedics Sciences

E-ISSN: 2395-1958
P-ISSN: 2706-6630
IJOS 2022; 8(3): 43-45
© 2022 IJOS
www.orthopaper.com
Received: 06-05-2022
Accepted: 18-06-2022

Dr. Wenlin Wang
Professor, Department of Chest
Wall Surgery, Guangdong
Second Provincial General
Hospital, Guangzhou, China

Dr. Weiguang Long
Associate Professor, Department
of Chest Wall Surgery,
Guangdong Second Provincial
General Hospital, Guangzhou,
China

Dr. Yang Liu
Resident Doctor, Department of
Chest Wall Surgery, Guangdong
Second Provincial General
Hospital, Guangzhou, China

Dr. Bin Cai
Resident Doctor, Department of
Chest Wall Surgery, Guangdong
Second Provincial General
Hospital, Guangzhou, China

Dr. Juan Luo
Resident Doctor, Department of
Chest Wall Surgery, Guangdong
Second Provincial General
Hospital, Guangzhou, China

Corresponding Author:
Dr. Wenlin Wang
Professor, Department of Chest
Wall Surgery, Guangdong
Second Provincial General
Hospital, Guangzhou, China

Wenlin procedure for treatment of barrel chest

Dr. Wenlin Wang, Dr. Weiguang Long, Dr. Yang Liu, Dr. Bin Cai and Dr. Juan Luo

DOI: <https://doi.org/10.22271/ortho.2022.v8.i3a.3171>

Abstract

A Barrel chest is a kind of thoracic deformity. Clinically, it is always secondary to chronic lung disease, which does not need treatment. Barrel chest is also common in young people and adults. Due to the serious impact on the appearance of the thorax, patients always have strong desires for surgery. We applied Wenlin procedure to the operation of the barrel chest and achieved satisfactory results. This paper introduces the Wenlin procedure of a 25-year-old male patient with barrel chest.

Keywords: Wenlin procedure, barrel chest, thorax, patients

Introduction

Barrel chest is a common thoracic deformity, but the deformity in most patients is a secondary lesion, mostly secondary to chronic lung disease, which is the result of long-term compensatory overload of chest wall [1]. Such a deformity does not need treatment. However, there is another clinical situation. Barrel chest exists in young or middle-aged people. Such deformity is a primary deformity. Because it affects the appearance of the chest wall, it will bring trouble to patients, and patients always have a strong desire for treatment. So far, we are the only one who has done surgery for this kind of deformity in the world, and there are no other doctors reported to do this kind of work [1]. We use a special operation designed by us, namely Wenlin procedure. This operation was first used for the treatment of pectus carinatum [2]. Later, we found that this operation can also be used for the treatment of barrel chest. This provides an effective method for the treatment of this deformity. This paper reports the treatment of a patient with barrel chest and introduces the concrete method of Wenlin procedure.

Case Report

The patient was a 25-year-old male. He found that his chest was barrel-shaped since childhood, but there was no discomfort. Before puberty, Although he was not satisfied with the appearance of his chest wall, his desire for surgery was not strong. After puberty, he was troubled by the appearance of the chest wall, resulting in serious introversion and longing for treatment. The patient was finally admitted to our hospital for surgical treatment. Preoperative physical examination showed that the appearance of chest wall was barrel-shaped [Fig 1]. The anterior and posterior diameter increased significantly, and the intercostal space widened. Imaging examination showed that the anterior and posterior diameter of chest wall increased, the cross-section was round, and the intercostal distance increased [Fig 2]. The patient was diagnosed as barrel chest before operation, and the operation was performed under general anesthesia. The supine position was adopted, and incisions were made on both chest walls respectively, which were located between the axillary frontline and the axillary midline. The chest wall muscles are dissected to reveal the bony structures of the chest wall. Three tunnels were made in front of the sternum, and three steel bars were placed into the tunnels respectively. Both ends of the steel bars were fixed on the ribs with steel wires [Fig 3]. After the anterior chest wall is flattened, the transverse diameter of the thorax increases, the anterior and posterior diameter shortens, and the chest wall appearance gradually returns to its normal shape. After closing the incision, the operation was completed [Fig 4]. The operation time was 69 minutes, smooth without any complications.

The patient recovered smoothly and was discharged 7 days after operation. There were no complications after 2 years of follow-up. The bars were removed 2 years after operation. The chest shape is basically normal, and there is no abnormal appearance.

Discussion

Barrel chest is a special type of thoracic deformity, which is completely different from other kinds of deformities in appearance. However, if comparing with pectus carinatum, the internal relationship between the two deformities can be found. If the pectus carinatum is regarded as a local protrusion of the anterior chest wall, the barrel chest can be regarded as an overall protrusion of the anterior chest wall. Theoretically, since they all have protrusion, they can be corrected in a similar way.

For patients with pectus carinatum, we designed a very effective surgical method, Wenlin procedure [2]. After research, we found that this kind of operation can also be used in the treatment of barrel chest. After full preparation, we began to perform the operation. So far, we have completed a large number of barrel chest operations and achieved satisfactory results [1].

Although barrel chest is similar to pectus carinatum, it is also different when using Wenlin procedure. The main technical points include the following:

1. More steel bars are needed. Due to the wide range of barrel chest protrusion, there must be a sufficient number of steel bars to ensure that the protrusive deformity is flattened.
2. Steel bars need to be placed reasonably. Due to the large area of protrusion, each steel bar needs to be placed in a suitable position to have a good orthopedic effect.
3. The balance of force need to be noticed seriously. Because the bony structures are rigid, the stress must be reasonably distributed. Otherwise, it may cause related complications and even lead to operation failure.

This patient is an adult male and is the most common type of barrel chest patient. During the operation, we used 3 steel bars. After proper placement and fixation, we achieved satisfactory results.

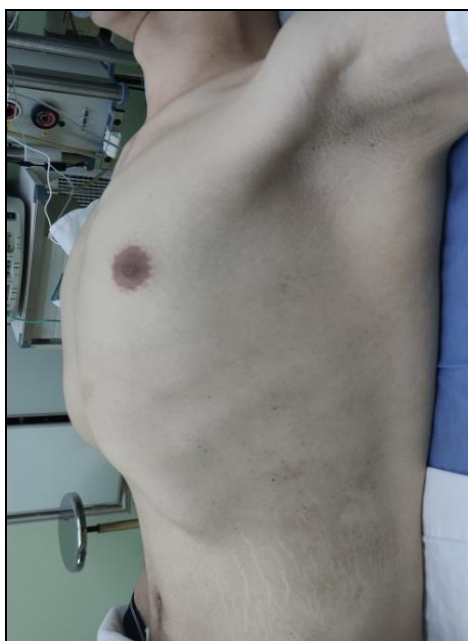

Fig 1: Chest wall appearance before operation.

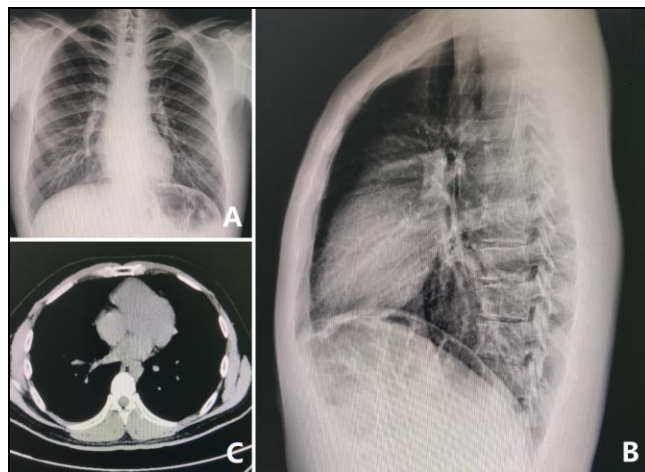


Fig 2: Imaging examination of chest wall. A, B, X-ray examination; C. CT scan examination.

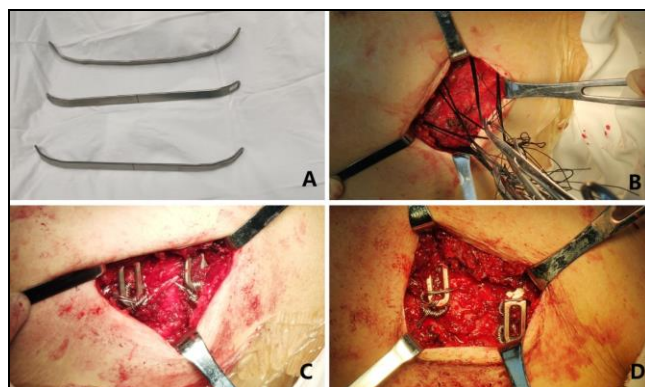


Fig 3: Operation pictures. A, Three steel bars used in the operation; B, The steel wire traction lines are placed; C, D. both ends of the steel bars are fixed to the ribs.

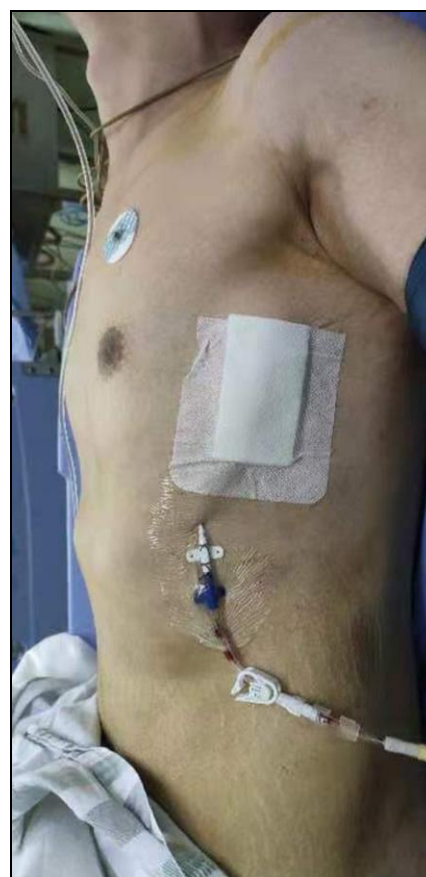

Fig 4: Chest wall appearance after operation.

Conclusion

Our experience shows that although barrel chest is a special deformity, it can be corrected by Wenlin procedure. Because this method belongs to the category of minimally invasive surgery, it can obtain very satisfactory results.

Reference

1. Wang W. Minimally invasive surgical technique for barrel chest. Surg Case Rep. Doi: 10.31487/j.SCR.2018.02.005.
2. Wang W, Long W, Liu Y, Cai B, Luo J. Wenlin procedure: A novel surgical technique for pectus carinatum. International Journal of Case Reports in Surgery 2022;4(1):10-12.
3. Wang W, Long W, Liu Y, Cai B, Luo J. Morphological characteristics of Wenlin chest. International Journal of Case Reports in Surgery. 2022;4:22-4.