

E-ISSN: 2395-1958
P-ISSN: 2706-6630
IJOS 2022; 8(2): 95-100

www.orthopaper.com
Received: 07-02-2022
Accepted: 09-03-2022

Sagar Dave
Department of Orthopaedic, Sancheti Institute of Orthopaedic, Pune, Maharashtra, India

Chetan Pradhan
Department of Orthopaedic, Sancheti Institute of Orthopaedic, Pune, Maharashtra, India

Atul Patil
Department of Orthopaedic, Sancheti Institute of Orthopaedic, Pune, Maharashtra, India

Chetan Puram
Department of Orthopaedic, Sancheti Institute of Orthopaedic, Pune, Maharashtra, India

Parag Sancheti
Dean, Sancheti Institute of Orthopaedic, Pune, Maharashtra, India

Ashok Shyam
Department of Orthopaedic, Sancheti Institute of Orthopaedic, Pune, Maharashtra, India

Corresponding Author:
Sagar Dave
Department of Orthopaedic, Sancheti Institute of Orthopaedic, Pune, Maharashtra, India

Pre-operative use of CT based three-column concept for fragment specific fixation of proximal tibia fractures in a series of 84 cases

Sagar Dave, Chetan Pradhan, Atul Patil, Chetan Puram, Parag Sancheti and Ashok Shyam

DOI: https://doi.org/10.22271/ortho.2022.v8.i2b.3119

Abstract
Background: It is important to classify proximal tibia fractures based on CT scan in addition to plain radiograph. The 3-column concept was introduced to classify these fractures based on a transverse CT scan. This study aimed to evaluate the surgical and functional outcomes of fragment specific fixation in proximal tibia fractures using the 3-column concept.
Materials and Methods: 84 cases of proximal tibia fractures (mean age: 42.85±11.94 years, range 23-72 years; 65 males and 19 females) were classified based on the 3-column concept (24 - 1 column, 50 – 2 column, 10 – 3 column). The surgical approach was decided for fragment-specific fixation based on the column involved. The clinic-functional assessment was done using fracture union time, range of motion, Oxford Knee Score and Functional Knee Society Score.
Results: The mean follow up duration was 1.2-1.5 years. The average fracture union time was 15.63±1.98 weeks (range, 12-21 weeks). The mean flexion achieved at the final follow up was 132.74±4.49 degrees (range, 130-135 degrees). The mean follow-up Oxford Knee Score was 47.98±0.109 (range, 45-48) and the mean Functional Knee Society Score was 99.88±1.09 (range, 90-100) in all patients after 1 year. 2 patients showed they delayed wound healing with superficial infection and 1 patient had a stiff knee. There was no other complication.
Conclusion: Using the CT-based three-column concept for fragment-specific fixation pre-operatively helps treat a complex proximal tibia fracture with acceptable complication rates and good functional outcomes.

Keywords: Proximal tibia, CT scan, oxford knee score, functional knee society score, fracture union, range of motion

Introduction

Proximal tibia fractures pose a great challenge in front of the surgeon because they vary from simple to complex, with little or extensive articular involvement. The high variability of the fracture patterns makes it important to classify these fractures based on CT scans in addition to X-ray [1]. These fractures appear either as isolated fracture lines or as part of a multicolumn plateau fracture, both in sagittal as well as coronal planes [2, 3, 4]. Multicolumn fractures were occasionally missed on plain X-rays and were not included in initial classifications of tibial plateau fractures, thus causing difficulty in both surgical approach and fixation method [5. 6]. CF Luo *et al*. [7] described the 3-column concept and classified these fractures based on a transverse CT scan. This concept stressed upon the need to stabilize all 3 columns of the tibial plateau for better surgical and functional outcome [7].

The benefit of 3 column classification over the traditional Schatzker classification [8] is that it gives a transverse view of the tibial plane which helps to find the exact location of the fracture [7]. This helps the surgeon to identify the most suitable approach for the specific fracture as well as to find the degree of articular involvement. Very few studies have been published in which fragment-specific fixation is carried out for this type of a fracture based on column involvement [7, 9, 10].

The purpose of this study was to correlate the use of the 3-column concept for fragment specific fixation of proximal tibia fractures, thus, studying their surgical/functional outcomes as well as the complications associated with the same.

Materials and Methods

This was a prospective study between May 2017 to September 2018 in which 84 patients with closed proximal tibia fractures above 18 years of age, they were treated surgically. Approval was obtained from the our committee. Polytrauma patients and those with compound proximal tibia fractures were excluded. The mean age of the patients in this study was 42.85±11.94 years (range 23-72 years). There were 65 males and 19 females. 4 cases had an ACL avulsion fracture additionally.

After the primary clinical evaluation, plain radiography in the form of anteroposterior (AP), lateral, oblique X-rays and CT scanning of the affected knee was done. The column involvement was observed on the transverse CT cuts.

The fractures were classified based on Luo's 3-column concept [7], according to which, this study had 24 single-column fractures, 50 patients had 2 column involvement and 10 patients had 3 column involvement. The condition of the soft tissues was evaluated before the operation for swelling and blisters over the affected limb. The surgery was delayed in 48 cases due to the above-mentioned reasons for a minimum of 1 to a maximum of 6 days. After soft tissue healing, the patients were taken up for surgery once the edema and blisters resolved.

Informed consent from involved cases was taken prior to surgery. All patients were surgically treated using fragment specific plates.

The anterolateral or the posteromedial approaches for proximal tibia [11] were used, either individually or both together as per column involvement. The anterolateral approach was used in 26 cases, the posteromedial approach in 23 cases and both approaches were used together in 35 cases, the fractures being multi-columnar. Provisional fixation was done with K wires and reduction was verified with the help of an image intensifier. Lag screw was used in 34 cases, either separately or through the plate. The fragment specific plate was inserted and secured on top of the periosteum deep to the muscle envelope. Hockey stick plates were used in 38 cases, T plates were used in 53 cases, raft plates were used in 22 cases, posteromedial plates were used in 17 cases and variable-angle LCPs were used in 5 cases. Autografts were used for 26 cases.

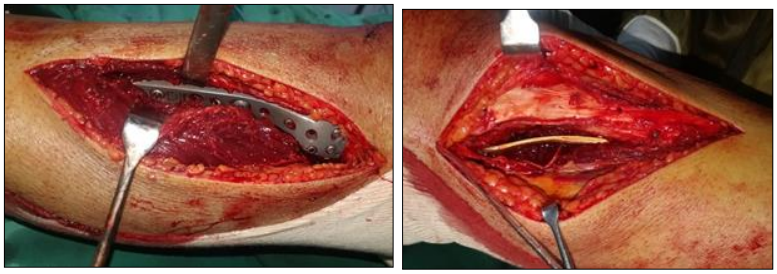

A B

Fig 1: (a) Raft plate fixed by anterolateral approach and (b) Posteromedial plate fixed by posteromedial approach

A B

Fig 2: (a) Final view of incisions before closure and (b) Image intensifier view

A post-operative X-ray was taken immediately and the operated knee was immobilized in a long leg knee brace for 2 weeks with intermittent removal of the brace 4 times a day. Gentle knee range of motion (ROM) on angle frame and active quadriceps and hamstring strengthening were encouraged. At two weeks, the brace was discarded and full ROM was started. Early mobilization without weight bearing was started depending on the strength of fixation and severity of soft tissue injury. In the 4 fractures associated with an ACL avulsion, ROM was delayed by one week. Partial weight bearing was started at around 6 weeks, which progressed to full weight bearing over the next 6 weeks, depending on radiological bone healing.

Patients were followed up at 1 month, 3 months, 6 months, 1 year and 1.5 years, when Oxford Knee Score (OKS)[12] and Functional Knee Society Score (FKSS)[13] were calculated, range of motion (ROM) was assessed. Anteroposterior and lateral radiographs were obtained to assess fracture union

(FU), depending on the disappearance of the fracture line, taking into account articular congruity and metaphyseal alignment. Bony union was noted when at least 3 healed cortices were found on follow up X-ray [7].

Statistical analysis

Data analysis was performed by using SPSS (Statistical Package for social sciences) version 25.0. Qualitative data variables are expressed by using frequency and percentage (%). Quantitative data variables are expressed by using Mean and SD. ANOVA test was used to compare the mean Oxford knee score, functional knee society score, ROM and fracture union with respect to Luo classification. P-value <0.05 considered as significant.

Results

The average follow-up duration was 1.2-1.5 years and no patients were lost to follow-up. The average fracture union time for all cases was 15.63±1.98 weeks (range, 12-21 weeks) and it did not vary with column involvement (Tab 1). The average flexion (in degrees) of the affected knee at final follow up was 132.74±4.49 degrees (range, 130-135) as compared to that of the opposite knee, which was 138.57±3.85 degrees (Deficit – 5.83±0.64 degrees). It was observed that 2 and 3 column fractures had a similar range of motion over time; single column fractures showed a better range of motion comparatively (Tab 2)

Table 1: Mean duration of fracture union with respect to Luo Classification

Column involvement	Number of patients	Fracture union time	p-value
1 column	24	15.17±1.79	
2 column	50	15.92±2.06	0.269
3 column	10	15.03±2.01	

p-value > 0.05 (Not Significant) ANOVA test used

Table 2: Mean ROM with respect to Luo Classification

ROM (flexion in degrees) at	1 Column (n=24)	2 Column (n=50)	3 Column (n=10)	p-value
1 month	109.17±2.82	89.00±5.80	84.00±5.16	< 0.001
3 months	118.33±5.65	100.40±2.83	100.00	< 0.001
6 months	119.43±5.66	101.50±2.84	100.00	< 0.001
1 year	129.17±2.82	120.20±1.41	120.00	< 0.001
Final Follow Up	136.17±2.83	130.20±1.44	130.00	< 0.001

Significant (p-value < 0.05) ANOVA test used

Table 3: Mean OKS with respect to Luo Classification

OKS at	1 Column (n=24)	2 Column (n=50)	3 Column (n=10)	p-value
1 month	22.71±12.11	17.58±9.02	14.60±13.49	0.068
3 months	32.17±7.53	32.64±5.35	31.00±5.31	0.730
6 months	40.17±5.08	40.36±3.06	31.10±3.78	0.636
1 year	47.67±1.43	47.98±0.14	47.30±2.21	0.143
Final Follow Up	48.00	47.98±0.14	48.0	0.717

Not Significant (p-value > 0.05) ANOVA test used

Table 4: Mean FKSS with respect to Luo Classification

FKSS at	1 Column (n=24)	2 Column (n=50)	3 Column (n=10)	p-value
1 month	18.33±11.76	15.10±10.90	19.50±7.61	0.325
3 months	72.71±10.93	72.80±8.09	75.0±5.27	0.752
6 months	90.42±10.83	91.20±9.18	89.0±11.0	0.802
1 year	99.58±2.04	99.80±1.41	100.0	0.746
Final Follow Up	100.00	99.80±1.41	100.0	0.717

p-value > 0.05 (Not significant) ANOVA test used

The OKS and FKSS were found to be better in fractures with minimum column involvement at initial follow ups. But the mean OKSS was 47.98±0.109 (range 45-48) and the mean FKSS was 99.88±1.09 (range 90-100) at the final follow up.

Table 5: Comparison of previous studies with regards to OKS at final follow up and incidence of wound infection

Study by	No. of cases	OKS	Wound Infections (No. of cases)
Weil *et al*. (2008) [3]	27	29	-
Ching Lee *et al*. (2013) [14]	15	42.17	1
Khatri *et al*. (2014) [15]	65	44.03	9
Jagdev *et al*. (2017) [16]	23	39.78	2
Sanjeev P *et al*. (2018) [17]	20	40.4	1
Our study	84	47.98	2

In this study, 2 patients showed delayed wound healing with a superficial infection which healed within one month by an extended course of oral broad-spectrum antibiotics and wound care. One patient had a stiff knee but got a satisfactory range of motion of 130 degree with no extensor lag or flexion deformity after rigorous physiotherapy over 3 months. No other complication was noted.

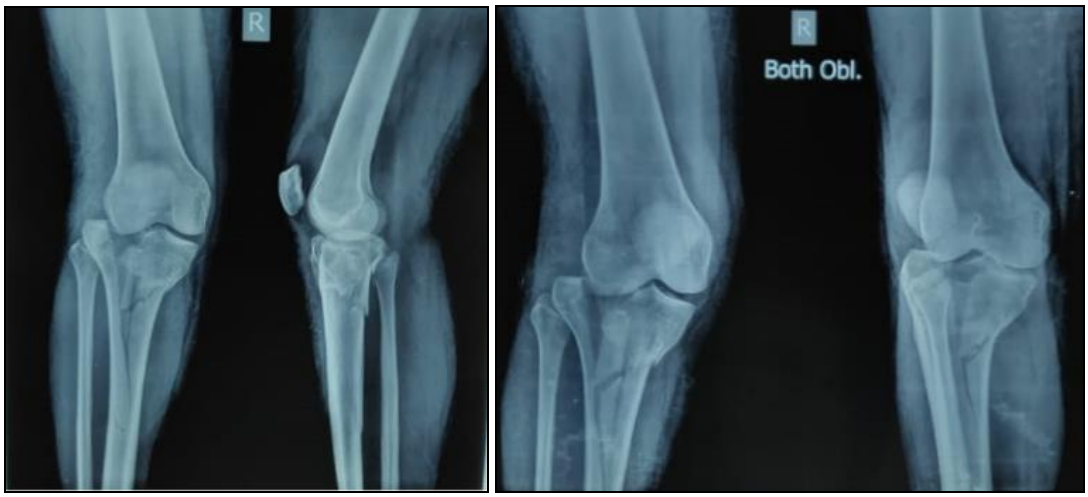

A

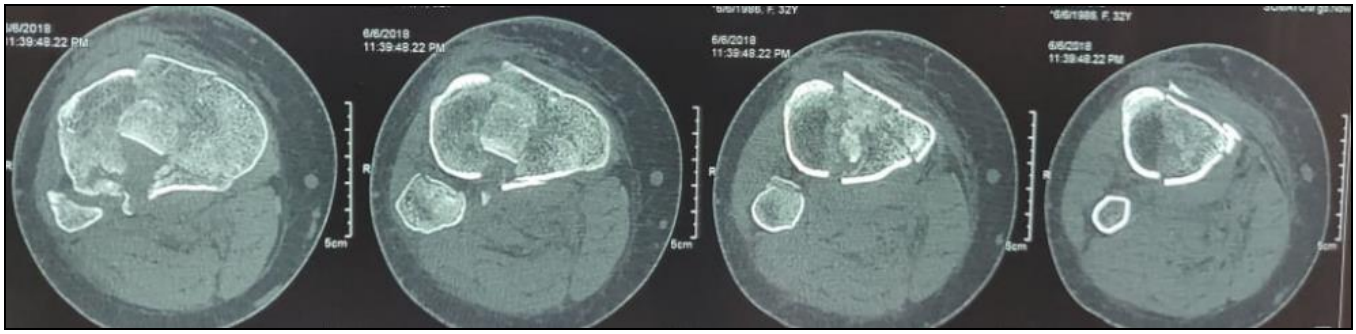

B

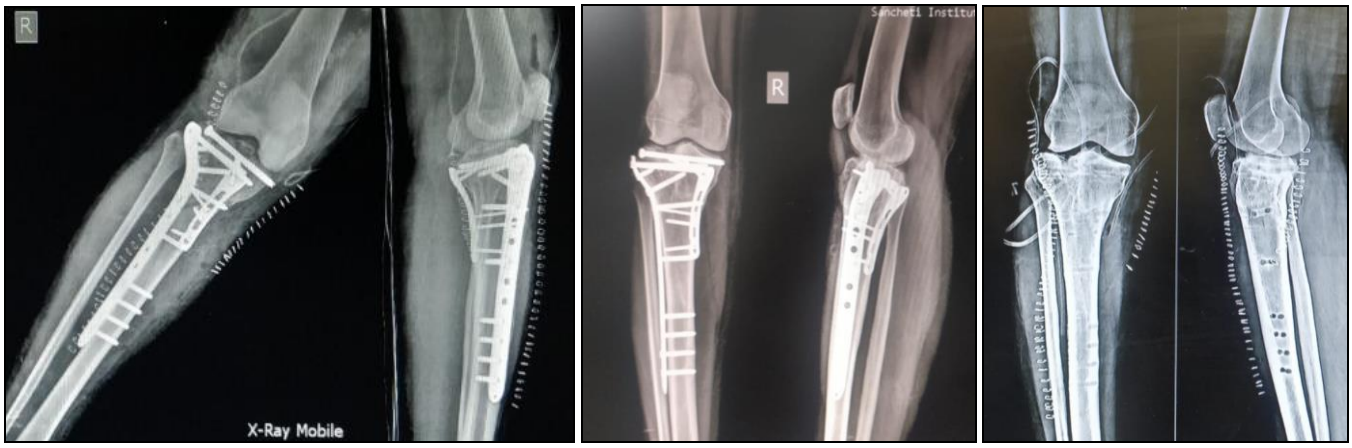

C D E

F

Fig 3(a): 32 years old female, a case of closed right proximal tibia bicondylar fracture due to road traffic accident. (b): Pre-operative CT scan - lateral and posteromedial column involvement. (c): Post-operative radiograph – lateral hockey stick plate and posteromedial plate used with a screw. (d): Final follow up radiograph at 1.5 years (e) Implant removal done at 1.5 years. (f) Clinical picture after implant removal showing flexion and extension

Discussion

Most of the classification systems like Schatzker classification [8] for proximal tibia fractures use two-dimensional images, in which only medial and lateral columns are appreciated, without stressing on the posterior column. Using Luo's concept based on a CT scan [7], posterior column fixation is stressed when the fractures involve the posterior aspect of the tibial plateau.

In similar studies, coronal splits of the posterior tibial plateau were considered as a separate group on plain X-ray [7, 18], but it proved to be inadequate [2, 3], because this type of fracture appears confusing on a plain radiograph. With careful review and application of the CT scan for the evaluation of these fractures, many more fracture planes were identified. Many similar studies were done which proved that these complex fractures are under-evaluated on plain radiograph and the operative plans were changed in the majority of the cases after a pre-operative CT scan was obtained [2, 3, 19-21].

The mean fracture union time of all the cases in this study was comparable with previous studies in which the time for fracture union ranged from 13-18 weeks [10, 20, 26, 27]. The mean flexion achieved in this study at final follow up was better than that achieved in similar studies done previously, their range being 106-121 degrees [10, 16, 28].

Improved functional scores (OKS and FKSS) were obtained in this study as compared to previous studies [3, 10, 14-17, 27, 29]. OKS of the patients, as proved in previous studies, was variable, with the majority of patients showing an excellent OKS at final follow up. (Tab 5).

Several factors may have contributed to the successful clinical, functional and radiological outcomes in this study: 1) Pre-operative planning based on CT scan in addition to plain radiography [7, 10] 2) advancements in implant design – use of fragment specific plates which were thinner, more malleable and pre-contoured with lesser chances of hardware prominence and infection as compared to traditional locking

plates [9, 10, 20] 3) patients were followed up routinely on a regular basis, thus improving their compliance with weight bearing restriction and rehabilitation protocol 4) soft tissue integrity was respected in all the surgical decision-making, contributing to relatively low overall complication rates, thus, providing good articular reduction and stable fixation [9, 10, 22-25].

Two patients showed they delayed wound healing with superficial infection and one patient had a stiff knee. The infection rate in this study was 2.38%. The number of post-operative complications encountered in this study was relatively low as compared with previous studies [10, 30-32], in which the infection rate was observed to be 4-12% (Tab 5). Thus, there are no significant complications with wound healing when multiple incisions are taken safely. This may be because of various measures taken pre-operatively as well as intra-operatively in regards to sterility, soft tissue healing before surgery, respecting the soft tissue integrity intra-operatively and post-operative wound care [9, 10, 22-25, 33].

The few drawbacks that can be mentioned would be that this was a single centre study with a limited sample size. The learning curve involved in fragment specific fixation is unpredictable. Also, in the case of a polytrauma or a compound injury, the outcome of a similar fracture cannot be predicted. The choice of implants, preferred approach and the rehabilitation protocol may vary among different centres or surgeons.

Conclusion

Using pre-operative CT scanning for fragment specific fixation gives a pre-planned, systematic, soft-tissue friendly perspective in the management of this highly complex and variable type of fracture, which is evident from the acceptable complication rate and good functional outcomes obtained in this study.

References:

1. Chen P, Shen H, Wang W, Ni B, Fan Z, Lu H. The morphological features of different Schatzker types of tibial plateau fractures: a three-dimensional computed tomography study, J OrthopSurg Res. 2016 Aug 27;11(1):94.
2. Bhattacharyya T, McCarthy LP 3rd, Harris MB, *et al*. The posterior shearing tibial plateau fracture: treatment and results via a posterior approach. J Orthop Trauma. 2005;19:305-310
3. Weil YA, Gardner MJ, Boraiah S, Helfet DL, Lorich DG. Posteromedial supine approach for reduction and fixation of medial and bicondylar tibial plateau fractures. J Orthop Trauma. 2008;22:357-362
4. Zeng ZM, Luo CF, Putnis S, Zeng BF. Biomechanical analysis of posteromedial tibial plateau split fracture fixation. Knee. 2011;18(1):51-4
5. Rombold C. Depressed fractures of the tibial plateau. Treatment with rigid internal fixation and early mobilization. A preliminary report. J Bone Joint Surg (Am). 1960;42-A:783-97
6. Hohl M. Tibial Condylar Fractures. J Bone Joint Surg (Am). 1976;49:1455-1467
7. Luo CF, Sun H, Zhang, Zeng BF: Three column fixation for complex tibial plateau fractures, J Orthop Trauma. 2010 Nov;24(11):683-92
8. Schatzker J, Mc Broom R, Bruce D. The tibial plateau fracture. The Toronto experience 1968-1975. Clin Orthop Relat Res. 1979;(138):94-104
9. Bogdan Y, Tornetta III P. Fragment-Specific Fixation of Proximal Tibia Fractures: Case Report and Surgical Technique.
10. Yukai Wang, Congfeng Luo, Yi Zhu, Qilin Zhai, Yu Zhan, Weijian Qiu, *et al*. Updated Three-Column Concept in surgical treatment for tibial plateau fractures – A prospective cohort study of 287 patients, Injury, Int. J Care Injured. 2016;47:1488-1496.
11. Müller ME, Allgöwer M, Müller ME, Schneider R, Willenegger H. Manual of internal fixation: techniques recommended by the AO-ASIF group. Springer Science & Business Media, 1991.
12. Dawson J, Fitzpatrick R, Murray D, Carr A. Questionnaire on the perceptions of patients about total knee replacement. J Bone Joint Surg Br. 1998 Jan;80(1):63-9
13. Insall JN, Dorr LD, Scott RD, Scott WN. Rationale of the Knee Society clinical rating system. Clin Orthop Relat Res. 1989 Nov;(248):13-4.
14. Lee TC, Huang HT, Lin YC, Chen CH, Cheng YM, Chen JC. Bicondylar tibial plateau fracture treated by open reduction and fixation with unilateral locked plating. The Kaohsiung journal of medical sciences. 2013 Oct 1;29(10):568-77.
15. Khatri K, Lakhotia D, Sharma V, Kiran Kumar GN, Sharma G, Farooque K. Functional evaluation in high energy (Schatzker type V and type VI) Tibial plateau fractures treated by open reduction and internal fixation. International scholarly research notices, 2014.
16. Jagdev SS, Pathak SK, Salunke A, Maheshwari P, Ughareja P, Shah S. Functional outcome of Schatzker type V and VI tibial plateau fractures managed with open reduction internal fixation using dual plates. International Journal of Research in Orthopaedics. 2017 Sep;3(5):961.
17. Sanjeev P. A study on functional and radiological outcome of complex tibial plateau fractures by posteromedial plating (Doctoral dissertation, Tirunelveli Medical College, Tirunelveli)
18. Khan RM, Khan SH, Ahmad AJ, *et al*. Tibial plateau fractures. A new classification scheme. Clin OrthopRelat Res. 2000;375:231-242.
19. Macarini L, Murrone M, Marini S, *et al*. Tibial plateau fractures: evaluation with multidetector-CT. La Radiologia medica. 2004;108(5-6):503-514.
20. Barei DP, O'Mara TJ, Taitsman LA, Dunbar RP, Nork SE. Frequency and fracture morphology of the posteromedial fragment in bicondylar tibial plateau fracture patterns. J Orthop Trauma. 2008;22(3):176-82.
21. Wicky S, Blaser PF, Blanc CH, *et al*. Comparison between standard radiography and spiral CT with 3D reconstruction in the evaluation, classification and management of tibial plateau fractures. Eur Radiol. 2000;10:1227-1232.
22. Khatri K, Sharma V, Goyal D, *et al*. Complications in the management of closed high-energy proximal tibial plateau fractures. Chin J Traumatol. 2016;19:342-347.
23. Jöckel JA, Erhardt J, Vincenti M, *et al*. Minimally invasive and open surgical treatment of proximal tibia fractures using a polyaxial locking plate system: a prospective multi-centre study. Int Orthop. 2013;37:701-708.
24. Yoo BJ, Beingessner DM, Barei DP. Stabilization of the posteromedial fragment in bicondylar tibial plateau fractures: a mechanical comparison of locking and nonlocking single and dual plating methods. Journal of

Trauma and Acute Care Surgery. 2010 Jul 1;69(1):148-55.
25. Zeng ZM, Luo CF, Putnis S, Zeng BF. Biomechanical analysis of posteromedial tibial plateau split fracture fixation. The Knee. 2011 Jan 1;18(1):51-4.
26. Surwase GJ, Mishra D, Mehra AK. Functional outcome and duration of union in proximal tibial fractures treated with locking compression plate. International Journal of Orthopaedics. 2019;5(2):128-32.
27. Zhang Y, Fan D, Ma B, Sun S. Treatment of complicated tibial plateau fractures with dual plating via a 2-incision technique. Orthopedics. 2012;35(3):359-64.
28. Carlson DA. Posterior bicondylar tibial plateau fractures. J Orthop Trauma. 2005;19:73-78.
29. Srinivas C, Satish P, Murthy GV, Raju B. Functional outcome of schatzker type 5 and 6 tibial plateau fracture treated by proximal locking plate. Journal of evolution of medical and dental sciences-JEMDS. 2018 Nov 26;7(48):5141-4.
30. Prasad GT, Kumar TS, Kumar RK, Murthy GK, Sundaram N. Functional outcome of Schatzker type V and VI tibial plateau fractures treated with dual plates. Indian journal of orthopaedics. 2013 Mar;47(2):188.
31. Ebraheim NA, Sabry FF, Haman SP. Open reduction and internal fixation of 117 tibial plateau fractures. Orthopedics. 2004;27(12):1281-7.
32. Barei DP, Nork SE, Mills WJ, Coles CP, Henley MB, Benirschke SK. Functional outcomes of severe bicondylar tibial plateau fractures treated with dual incisions and medial and lateral plates. J Bone Joint Surg. 2006;88(8):1713-21.
33. Cole PA, Zlowodzki M, Kregor PJ. Treatment of proximal tibia fractures using the less invasive stabilization system: surgical experience and early clinical results in 77 fractures. J Orthop Trauma. 2004;18(8):528-35.