

E-ISSN: 2395-1958
P-ISSN: 2706-6630
IJOS 2022; 8(2): 47-52

www.orthopaper.com
Received: 09-01-2022
Accepted: 21-02-2022

Dr. Viraj Rajendrakumar Patel
MS Orthopaedics,
Consultant Orthopaedic Surgeon,
Department of Orthopedic, SSG Hospital, Government Medical College, Baroda, Gujrat, India

Corresponding Author:
Dr. Viraj Rajendrakumar Patel
MS Orthopaedics,
Consultant Orthopaedic Surgeon,
Department of orthopedic, SSG Hospital, Government Medical College, Baroda, Gujrat, India

A hospital-based assessment of the clinical and radiological outcome of extra-articular metaphyseal proximal tibia fractures treated with proximal tibia plates using the MIPPO technique using Rasmussen's scoring system

Dr. Viraj Rajendrakumar Patel

DOI: https://doi.org/10.22271/ortho.2022.v8.i2a.3116

Abstract
Aim: To assess the clinical and radiological outcome of extra-articular metaphyseal proximal tibia fractures treated with proximal tibia plates using the MIPPO technique using Rasmussen's scoring system.
Materials and Methods: Data related to demographics, mechanism of injury, details of trauma, hospitalization detail, operation description, post-operative rehabilitation, complications, clinical and functional outcomes were collected during the period of hospital stay and follow-up visits in the OPD clinic. Follow-up was conducted regularly at the interval of 4 weeks. The patients were followed up in the outpatient department. At the follow-up, a thorough clinical and radiological evaluation was done for the progress of union, healing of trauma wound, and joint stiffness. Once the fracture had shown early signs of union, partial weight bearing was started on the injured limb. On follow up, the patients were evaluated clinically and radiologically according to the proforma decided (Modified Rasmussen's criteria for clinical and Radiological evaluation).
Results: Majority (83.34%) of the patients in our study were males between the age group of 21-60 years. 90% of the patients had high energy proximal tibia fractures, which were caused by road traffic accidents (RTA) with a peak incidence in the fourth and fifth decade of life. Total 5 patients developed a superficial infection which was resolved by daily dressings and parenteral antibiotics. Rasmussen's score was applied to assess functional and radiological outcomes. In our study, according to Rasmussen's clinical scoring, 66.67% of patients had excellent, 12% of patients had well and 10% of patients had fair results. In our study, according to Rasmussen's radiological scoring, 80% of patients had excellent and 20% of patients had good results.
Conclusion: MIPPO is a relatively new concept in fracture management; but with the improved instrumentation and implants, it has the potential to become one of the mainstays of fracture management in the years to come.

Keywords: MIPPO, proximal tibia, fractures

Introduction

The proximal tibia fractures account for 5-11% of all tibia fractures. Fractures of the proximal tibia can be quite challenging to manage. They are notoriously difficult to reduce, align and stabilize and are prone to develop wound infections [1].

High-energy tibial plateau fractures, usually resulting from axial loading in combination with varus/valgus stress forces, present a variety of soft tissue and bony injuries that can produce permanent disabilities and their treatment is often challenged by severe fracture comminution, instability, displacement and extensive soft tissue injuries. These fractures constitute about 8% of all fractures in the elderly and 1% in general. In young adults, they are the result of high-energy trauma; most commonly road traffic accidents (RTAs), while in the elderly, they usually follow domestic falls [2, 3].

In displaced or unstable complex proximal tibia fractures, osteosynthesis is mainly done by using plates. Open reduction and internal fixation of proximal tibia fractures with plates can achieve good anatomical reduction, resulting in extensive devitalization of soft tissue, leading to wound healing problems [4, 8].

Extensive periosteal stripping and soft tissue dissection drain the fracture hematoma; thus, may compromise the blood supply of fracture fragments and result in complications such as infection, delayed unions, and nonunion leading to multiple surgeries. The incidence of skin necrosis, nonunion and infections increases especially for the extended lateral and medial approaches [9, 12].

With the gradual changes in the treatment modalities of fractures of the proximal tibia from conservative measures like cast bracing, traction, immobilization to surgical intervention for better results, there is a need for better conservative minimal invasive surgery and better fracture fixation techniques. With the better understanding of fracture healing biology and biomechanics of fracture fixation and healing, there is the evolution of the new concept of fracture fixation with fixed angular stable plates and minimally invasive surgical techniques [13-16].

Indirect reduction and minimally invasive percutaneous fixation appear to have a proven value in managing these fractures. Proximal tibia plating with the MIPPO technique can be used with severe soft tissue damage as the plates are considered to preserve the periosteal blood supply [1]. MIPPO technique maintains a biologically favorable environment for healing by reducing soft tissue trauma caused by surgical exposure and stabilizing the fracture without opening the fracture site [3].

Key to success includes early surgery, preservation of the biological healing potential and careful attention to surgical details [1]. The treatment goals include satisfactory restoration of mechanical alignment, maximum anatomical reduction of the articular surface and stable fixation that allows an early range of motion of the knee. The optimal method of treating a proximal tibia fracture is the method that better balances soft-tissue management and fracture reduction and alignment [6, 17-20].

Hence the present study was conducted to assess the clinical and radiological outcome of extra-articular metaphyseal proximal tibia fractures treated with proximal tibia plates using the MIPPO technique using Rasmussen's scoring system.

Materials and Methods

This study was carried out at the Department of Orthopaedics, Sir Sayajirao General Hospital (S.S.G.H.) and Government Medical College, Vadodara from January 2020 to December 2020. 33 patients were enrolled in the study based on the inclusion and exclusion criteria during this period. With 3 patients being lost to follow-up during the course of the study before completing at least 6 months of follow-up, we had 30 patients remaining in our study. Patients were followed up prospectively for a minimum of six months.

Inclusion Criteria

- All the fractures of the proximal tibia (Metaphyseal) without intraarticular extension, with a recent (<2 weeks) history of trauma.
- Closed fractures and open grade I fractures.

Exclusion Criteria

- Pathological fractures
- Fractures in children (< 18 years)
- Old and neglected fractures(> 2 weeks)
- Proximal tibia fractures with intraarticular extension
- All open grade II& III fractures
- Crush injuries
- Previously operated Fractures
- Fractures with existing or impending compartment syndrome.

Management

Primary Management

All the patients were managed on an emergency basis as per ATLS (Advance Trauma Life Support) protocol in the casualty. History taking, general examination and local examination were conducted in the trauma care centre. Once stabilized, relevant X-rays were done. Fractures were classified according to OTA/AO classification. All patients were monitored stringently for signs and symptoms of compartment syndrome. All wounds (if any) were covered by sterile dressing after cleansing with betadine, H_2O_2 and normal saline wash. Temporary immobilization was given by the above knee posterior plaster splint. Primary debridement and suturing were performed in open grade-1 fractures. In all open fractures, tetanus prophylaxis in the form of Tetanus Toxoid and Tetanus immunoglobulin were given. Injection diclofenac 50 mg i.m. was given to all patients as analgesic. Parenteral antibiotics i.e. injection ceftriaxone 1gm i.v. BD + injection metronidazole 400 mg i.v. TDS were started in all open injuries.

Pre-operative Management

Necessary investigations for surgical fitness were conducted. We had routinely done complete blood count (CBC), Renal function tests(RFT), Liver function tests (LFT), Random blood sugar (RBS), serum HIV, serum HbSAg, serum HCV in all of our patients. Closed fractures with edema were splinted and regular calf girth charting was done. Oral proteolytic enzymes i.e. combination of Bromelain 90mg + Rutoside Trihydrate 100mg + Trypsin-Chymotrypsin 50000 AU were given to relieve edema. Limb elevation was given to all the patients. Patients were taken for the surgery as soon as the swelling subsided and wrinkle sign appeared.

Selection of implant

In all our patients, we used proximal locking compression tibia plate. Plate placement and its length were evaluated according to the fracture geometry visible on antero-posterior and lateral X-ray views of the affected limb. Size of implant was decided pre-operatively considering magnification on X-rays and also intra-operatively under IITV guidance. The size was determined as requiring 6-8 cortices in the metaphysis and 8-10 in the diaphysis spanning the fracture. Site of plate placement, (medial or lateral) was decided depending on the proximal tibia fracture pattern and skin conditions.

Anaesthesia

Spinal, epidural or general anaesthesia was given to the patient as per the anaesthetists' opinion. Spinal anaesthesia was most commonly preferred by the anaesthetists. Tourniquet was not used in any case.

Surgery

Position: Surgery was performed on plain table in supine position. The knee was flexed on a quadriceps board with variable adjustment or with a bolster under the knee for fracture alignment and ease of reduction. The affected limb was scrubbed and prepared with diluted savlon. Painting and draping was done under aseptic and antiseptic conditions. Draping was done in such manner that the area from middle of thigh to ankle was exposed for proper recognition of anatomical landmarks. Intravenous antibiotics i.e. inj. ceftriaxone 1gm + inj. sulbacutm 1 gm was administered prior to incision.

Fig 1: Draping

Preliminary reduction was done with traction and manipulation under image intensifier before starting the surgical procedure.

Minimally invasive Percutaneous Plate Osteosynthesis (MIPPO)

After painting and draping, again the reduction was checked in image intensifier and incision was put depending on the fracture and size of implant used. Incisions were anticipated and planned according to skin condition and fracture geometry of proximal tibia. It was attempted to keep length of incision minimum at the proximal side enough to negotiate the plate. However this was not achieved at cost of the difficulty of surgeons but at the same time care was taken not to do over retraction. Distally small incisions were kept directly over the holes of the plate either by clinical palpation or after confirmation under image intensifier.

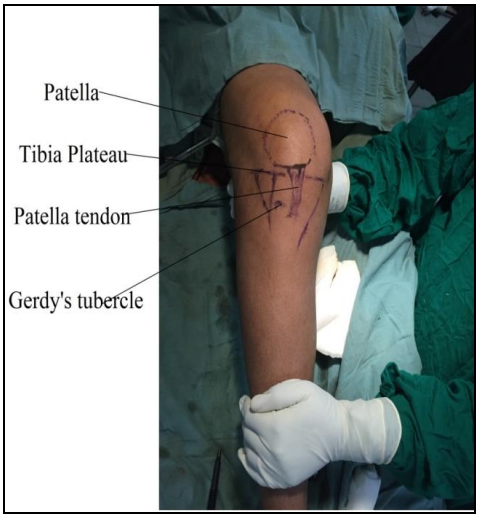

Fig 2: Landmarks

Fig 3: Provisional plate placement

Fig 4: Planning Incision (MIPPO)

Proximal Incision

Small incision of 3-4 cm length was taken starting just distal to the knee joint line and extending distally with anterior convexity to end just near tibia shin, sufficient in length so that minimum of 3 screw of 6.5 mm cancellous locking screws could be negotiated proximal to the fracture.

Fig 5: Proximal Incision (MIPPO)

Fig 6: Plate Insertion (MIPPO)

Distal Incision

The distal incision was kept directly over the holes of the plate, just lateral to the shin of tibia over the lower end of the plate under IITV guidance.

Fig 7: Distal Incision (MIPPO)

Reduction and Fixation

At the proximal incision, the subcutaneous tissue was cut in the line of the incision and the origin of the tibialis anterior muscle was stripped off. The periosteum was not stripped off. The plate was now slided across the fracture site under IITV image control (under sub muscular plane).Thus here a space was created by gentle blind dissection in the plane beneath the muscle and the periosteum with stripper. The drill guide threaded in to one of the combi holes in the proximal part of the plate was used as a handle for percutaneous insertion of plate.

After the implant was slided, indirect reduction was achieved as far as possible mainly by longitudinal traction and manipulation under image intensifier. Under image intensifier now the plate was manipulated and exact position of the implant was achieved. Provisional k-wires were used to maintain reduction. Once the position of the plate was confirmed on image intensifier it was held with the bone in the same position by a k-wire.

After confirming the position of plate under IITV guidance and finalizing the reduction, the proximal screw was inserted. (6.5 mm simple cancellous or locking cancellous). Metaphyseal cancellous screws and cortical screws in diaphysis were used outside the plate as required to maintain reduction replacing provisional k-wire. Depending on the quality of bone and proximity of the plate to the bone, simple 4.5 mm cortical or locking screws were used to fix the plate distally. Insertion of cortical screw first distally pulls the bone flush to the plate. However this was avoided if it compromised the quality of reduction and the fixation was continued using locking screws. Followed by, at least 3 locking cancellous screws were passed proximally in metaphyseal bone as well as 6 cortices purchase in distally for adequate stability.

Closure

Proximal wound was closed in layers i.e. subcutaneous layer was closed with vicryl 1-0 and skin was closed with nylon 1-0 suture. The stab wounds were closed in single layer i.e. skin was closed with nylon 1-0 suture. Sterile dressing was done. Before shifting the patient out of the operation theatre, distal pulses i.e. posterior tibial arterial and dorsalis pedis arterial pulses, were palpated and confirmed. Above knee slab was applied.

Fig 8: Suturing

Post-operative Regime

The patient was immobilized with an above knee posterior slab and care was taken to prevent dependent edema of limb. Intravenous antibiotics i.e. injection Ceftriaxone 1gm + injection Sulbactum 1gm BD and injection Amikacin 500mg BD were given for first 3 days followed by oral antibiotics i.e. tablet Amoxycillin 625mg BD and tablet Levofloxacin 500 mg BD for 5 days in closed fractures. However in open fractures intravenous antibiotics were given till trauma wound showed signs of healing. Injection Metronidazole 400 mg i.v. TDS was given in all open injuries for 5 days. Injection tramadol 100mg BD was given intravenously in 100 ml normal saline pint for 3 days for post-operative pain relief. A post-operative X-ray was advised when the patient could be shifted comfortably. Quadriceps strengthening exercises (QSE), knee and ankle mobilization exercises, high sitting and non-weight bearing-crutch walking were started on the first post-operative day (1st POD) under observation. Above knee posterior slab was again applied after physiotherapy and was continued for 2 weeks.

Data collection, Follow-up & Evaluation

Data related to demographics, mechanism of injury, details of trauma, hospitalization detail, operation description, post-operative rehabilitation, complications, clinical and functional outcome were collected during the period of hospital stay and follow up visits in the OPD clinic. Follow up was conducted

regularly at the interval of 4 weeks. The patients were followed up in the outpatient department. At the time of follow up a thorough clinical and radiological evaluation was done for progress of union, healing of trauma wound and joint stiffness. Once the fracture had shown early signs of union, partial weight bearing was started on the injured limb. On follow up, the patients were evaluated clinically and radiologically according to the proforma decided (Modified Rasmussen's criteria for clinical and Radiological evaluation).

Statistical Analysis

Descriptive statistical methods and expression of results in terms of mean, chi-square test and others using Microsoft excel software with significant p value <0.05 were used for computation of data.

Results

Table 1: Age and Sex distribution

Age Group (years)	Male	Female	N (%)
21-30	2	1	3 (10.0)%
31-40	11	1	12 (40.0)%
41-50	11	2	13 (43.33%)
51-60	1	1	2 (6.67%)
Total	25	5	100

Majority (83.34%) of the patients in our study were males between the age group of 21-60 years. 40% patients were in the age group of 31-40 and 43.33% in 41-50 years. Only 6.67% patients were in the age group of 51-60 years. This can be attributed to outdoor activities being performed predominantly by young males and use of vehicles.

Table 2: Distribution according to mode and associated injuries

Mode of Injury	Number	Percentage (%)
RTA	27	90.0%
Fall from height	3	10.0%
Fracture type		
Close fractures	24	80.0%
OG-1 fractures	6	20.0%
Associated injuries		
Other than orthopaedic injuries	8	26.67%
No associated injuries	22	73.33%
Total	30	100.0%

In our study 90% of the patients had high energy proximal tibia fractures which were caused by road traffic accidents (RTA) with peak incidence in the fourth and fifth decade of life. In our study 73.33% of the patients had no associated injuries. 8 (26.67%) patients also suffered from head injuries for which thorough investigations were done.

Table 3: Distribution of complications

Complication	Number	Percentage (%)
Infection (Superficial)	5	16.67
Infection (deep)	0	0
Implant Failure	0	0
Varus deformity	0	0
Limping (due to shortening of limb)	0	0
None	25	83.33
Total	30	100

In the present study 5 patients developed superficial infection which resolved by daily dressings and parenteral antibiotics. Inject able antibiotics were given according to culture & sensitivity reports of the fluid collected from the suture site. These patients required a longer duration of hospital stay. These patients were discharged from the hospital after the wound became healing.

Table 4: Outcome assessment using Rasmussen's score

Outcome	Clinical Results N (%)	Radiological Results N (%)
Excellent	20 (66.67%)	24 (80%)
Good	7 (23.33%)	6 (20%)
Fair	3(10%)	0
Poor	0	0
Total	30	30

Rasmussen's score was applied to assess functional and radiological outcome. In our study, according to Rasmussen's clinical scoring, 66.67% patients had excellent, 12% patients had well and 10% patients had fair results. In our study, according to Rasmussen's radiological scoring, 80% patients had excellent and 20% patients had good results.

Only 3 patients had fair results in clinical Rasmussen scoring. Out of 3 patients, 2 patients were in the age group of 51-60 years. They had persistent pain over leg after routine activities such as, standing for more than 30 minutes, sitting crossed leg for more than 20 minutes and walking for more than 15 minutes.

Discussion

In this era, road traffic accidents (RTA) and industrial accidents lead to increased number of tibia fractures. Management of fractures of the proximal tibia is a cause of debate, and remains challenging for orthopaedic surgeons.

Treatment of extra-articular proximal tibial fractures is challenging, and it is associated with higher rates of complications when compared with treatment of diaphyseal tibial fractures. The spectrum of injuries to the tibia is so variable that no single method has been proven uniformly successful. Extensive dissection through tenuous soft-tissue envelope to achieve reduction and use of conventional stabilizing implants, may significantly increase postoperative infection rates and implant failure and thus it may lead to loss of fracture reduction hindering long-term successful outcome. Prompt diagnosis, thorough pre-operative assessment of the bony and soft tissue trauma, adequate soft tissue monitoring, anatomic reduction and sound fixation allowing early joint movement and intensive rehabilitation are mandatory for good clinical results.

The implementation of contemporary reduction techniques and novel implants allow the surgeon to attain stable fixation without compromising the surrounding soft tissues. In our study, minimally invasive operative techniques with application of locking plating systems offered the ideal combinations in terms of bone fixation and soft tissue sparing. The advantage of MIPPO plating include biological fixation without extensive soft tissue stripping, earlier mobilization and shorter duration of hospital stay. Mean hospital stay of patients in our study was 5 days emphasizing the importance of plating with MIPPO technique.

In our study, 5 out of 30 patients had superficial infection (16.67%). Superficial infection was seen at the suture site of proximal incision. It was resolved by daily dressings and parenteral antibiotics. The low incidence of infection in our study can be attributed to the fact that due care was taken to delay surgery in excessive soft tissue swelling, maintaining thorough aseptic precautions and minimal skin incisions of

MIPPO technique.

According to Rasmussen clinical scoring system, our study showed excellent results in around 66.67% (N=20) of the patients, 23.33% (N=7) had good and 10% (N=3) had fair results. Rasmussen's radiological scores did not match the functional scores. This was comparable with study of Asimuddin M and Kulkarni M involving 20 patients treated with minimally invasive percutaneous plate osteosynthesis technique [3]. However, when the chi–square test was applied, the difference between radiological and clinical results in our study was not statistically different and the results are similar. Some bias or error in judgment of radiographs is inherent in these types of studies. We cannot readily rule out objective bias in our radiological assessment.

Conclusion

MIPPO is a relatively new concept in fracture management; but with the improved instrumentation and implants, it has the potential of becoming one of the mainstays of fracture management in the years to come. With our experience of the present study, we recommend the MIPPO (minimally invasive percutaneous plate osteosynthesis) as an effective option for extra articular proximal tibia fractures though careful technique and patient selection are crucial.

References

1 Dr. Gajanan Chintawar, *et al*. Evaluation of Outcome of Proximal Tiobia Fracturs Managed with MIPPO. Indian Journal of Orthopedic Surgery. 2016;2(2):156-164.

2 Dr. Niravkumar Moradiya *et al*. A Study of tibia plateau fractures treated with locking tibia plate: a study of 63 cases. Indian Journal of Orthopedic Sciences. 2016;2(4):368-374.

3 Dr. Mohamamd Asimuddin, *et al*. A clinical study of minimally invasive percutaneous plate osteosynthesis of proximal tibia fractures using locking compression plate. Indian Journal of Orthopedics Sciences. 2017;3(1):740-746.

4 Dr. Daokate PD, *et al*. Clinical and Radiological Evaluation of Patients of Proximal Tibia Fractures Treated with Long Proximal Tibial Locking Plate by Minimally Invasive Plate Osteosynthesis Technique. International Journal of Scientific Study. 2017;5(4).

5 John Kurylo C, *et al*. Extra articular Proximal Tibia Fractures: Nail or Plate? AAOS Instructional Courses Lectures. 2013, 62.

6 Pandey Anil, *et al*. Comparative analysis of closed recution and expert tibia nailing and open reduction and plate & screw fixation in the treatment of proximal tibia extra articular fractures. International Journal of Orthopedic Sciences. 2019;5(1):328-332.

7 Joon-Woo Kim, *et al*. Minimally invasive Plate Osteosynthesis for Open Fractures of the Proximal Tibia. Clinics in Orthopedic Surgery. 2012;4:313-320.

8 Paul Dan Sirbu, *et al*. Minimally Invasive Plate Osteosynthesis (MIPO) in Long Bone Fractures-Biomechanics-Design-Clinical Results. www.intechopen.com

9 Henley MB, Chapman JR, Agel J, Harvey EJ, Whorton AM, Swiontkowski MF. Treatment of type II, IIIA, and IIIB open fractures of the tibial shaft: a prospective comparison of unreamed interlocking intramedullary nails and half-pin external fixators. J Orthop Trauma. 1998;12(1):1-7.

10 Xue D, Zheng Q, Li H, Qian S, Zhang B, Pan Z. Reamed and undreamed intramedullary nailing for the treatment of open and closed tibial fractures: A subgroup analysis of randomized trials. Int Orthop. 2010;34(8):1307-13.

11 Whittle AP, Russell TA, Taylor JC, Lavelle DG. Treatment of open fractures of the tibial shaft with the use of interlocking nailing without reaming. J Bone Joint Surg Am. 1992; 74(8):1162-71.

12 Oh CW, Oh JK, Kyung HS, *et al*. Double plating of unstable proximal tibial fractures using minimally invasive percutaneous osteosynthesis technique. Acta Orthop. 2006; 77(3):524-30.

13 Oh JK, Oh CW, Jeon IH, *et al*. Percutaneous plate stabilization of proximal tibial fractures. J Trauma. 2005;59(2):431-7.

14 Lindvall E, Sanders R, Dipasquale T, Herscovici D, Haidukewych G, Sagi C. Intramedullary nailing versus Percutaneous locked plating of extra-articular proximal tibial fractures: comparison of 56 cases. J Orthop Trauma. 2009; 23(7):485-92.

15 Raikin S. From son-M I, Combined limited internal fixation with circular frame external fixation of intraarticular tibial fractures; Orthopedics. 1999 Nov;22(11):1019.

16 Phisitkul P, McKinley TO, Nepola JV, Marsh JL. Complications of locking plate fixation in complex proximal tibia injuries. J Orthop Trauma. 2007;21(2):83-91.

17 Dirschl DR, Dawson PA. Injury severity assessment in tibial plateau fractures. Clin Orthop Relat Res. 2004;423:85-92.

18 Hu YL, Ye FG, Ji AY, *et al*. Three-dimensional computed tomography imaging increases the reliability of classification systems for tibial plateau fractures. Injury. 2009;40:1282-5.

19 Dirschl DR, Del Gaizo D. Staged management of tibial plateau fractures. Am J Orthop (Belle Mead NJ). 2007;36:12-7.

20 Gaston P, Will EM, Keating JF. Recovery of knee function following fracture of the tibial plateau. J Bone Joint Surg Br. 2005;87:1233-6.