



# International Journal of Orthopaedics Sciences

E-ISSN: 2395-1958  
P-ISSN: 2706-6630  
IJOS 2022; 8(1): 581-589  
© 2022 IJOS  
[www.orthopaper.com](http://www.orthopaper.com)  
Received: 18-11-2021  
Accepted: 23-12-2021

**Dr. Momanyi Alex**  
Orthopedics Surgery, Moi  
University/Moi Teaching and  
Referral Hospital, Kenya

**Dr. Barry Ayumba**  
Head of Department,  
Orthopedics and Trauma  
Surgery, Moi University, Kenya

**Mohamed GY El-badawi**  
Head of Department, Human  
Anatomy, Moi University,  
Kenya

## Surgical anatomy of the femoral nerve in formalin prefixed cadavers in an adult Kenya population

**Dr. Momanyi Alex, Dr. Barry Ayumba and Mohamed GY El-badawi**

**DOI:** <https://doi.org/10.22271/ortho.2022.v8.i1h.3075>

### Abstract

**Background:** Ethnic variations involving femoral nerve have been described in literature. This nerve is the largest branch of the lumbar plexus. It innervates the hip flexors, knee extensors, and sensory function to medial and anterior aspects of the thigh. Risks of insults to nerve can be non-iatrogenic (trauma), and iatrogenic (approaches to the acetabulum, pelvis and proximal femur). The study aimed at providing precise description of variant anatomy of nerve, hence will help surgeons avoid iatrogenic insults.

**Methods:** An anatomic descriptive cross-sectional study design involving fifty six (56), formalin prefixed adult cadaveric specimens. The length of the femoral nerve in relation to the inguinal ligament and its bony attachments, and the patterns of distribution of main branches in the regions were defined.

**Results:** Males- 35 (Left=17, Right=18); Females- 21(Left=7, Right=14). Femoral nerve location: 53.02 mm (SD 14.59) from the ipsilateral anterior superior iliac spine (ASIS). Nerve trunk in relation to inguinal ligament measured: 47.85mm (SD 13.719) from the psoas muscle proximally and branched 29.32 mm (SD 14.239) distally. Innervations and branches: quadriceps in all specimens (Posterior); Sartorius muscles (Anterior), with noted variability in individual muscles. Branching pattern variations: 6 limbs (10.71%) at ligament level, 2(3.57%) limbs more proximal, while one nerve was split by a slip from the psoas muscle and then united 25.88mm proximal to ligament. The variations in sex were not statistically significant ( $p > 0.05$ ).

**Conclusion:** The anatomical course, length and branches of the femoral nerve in relation to inguinal ligament concur to great extent with described anatomic studies with some noted variability. Surgeons should be aware of the anatomic variations of femoral nerve and be cautious when operating in the zones traversed by the nerve.

**Keywords:** Femoral neuropathy, iatrogenic femoral nerve injury, acetabular/pelvic/ proximal femur surgery, femoral nerve orthoplasty

### 1. Introduction

The femoral nerve is the largest branch of the lumbar plexus arising from the posterior division of the ventral rami of L2, L3 and L4 nerve roots [occasionally receiving L1 and L5 spinal nerve roots]. Its trunk emerges on the anterolateral aspect of the psoas major muscle approximately 4cm proximal to the inguinal ligament [1-4].

It traverses beneath the inguinal ligament to emerge within the femoral triangle lying lateral to the femoral sheath. The nerve emerges in a groove between the iliacus and psoas muscles at the midpoint of the inguinal ligament where its course is directly anterior to the capsule of the hip joint separated by the iliopsoas tendon [5]. It then divides 2-4cm [1-1.5inches] below the mid-point of the inguinal ligament into the anterior and posterior branches. The anterior branch has motor [pectineus and sartorius muscles] and sensory [intermediate and medial cutaneous femoral nerves] branches. The posterior branch has motor [quadriceps femoris] and sensory [saphenous nerve] branches [6].

The femoral nerve function plays an important ambulatory role primarily in the stance phase of gait [7]. The documented ethnic and demographic variations in course and branching pattern [8] and its intimate relationship with the pelvis, hip joint and proximal femur places it at risk of injury through dislocations, fractures, direct blows or surgery. Femoral neuropathy results in ipsilateral hip flexion and knee extension deficits and hypoesthesia impairment on the anteromedial aspect of the thigh [9] and patella areflexia.

**Corresponding Author:**  
**Dr. Momanyi Alex**  
Orthopedics Surgery, Moi  
University/Moi Teaching and  
Referral Hospital, Kenya

Injury is associated with high patient morbidity with impairment in basic daily functions including walking, climbing up and down stairs. There has been a gradual increase in cases of femoral neuropathy following hip arthroplasty [10]. The increasing number of non-iatrogenic and iatrogenic femoral nerve insults, the documented ethnic variations, and the unknown course of the femoral nerve among the Kenyan population demonstrate the need for an anatomic description of the nerve among our population. Findings could be applied in validating previously described femoral nerve anatomy applicable in preoperative and intraoperative planning. Findings from this study will provide a precise anatomical guide to orthopaedic and non-orthopaedic surgeons in various pelvic and pelvic-femoral surgeries [9]. Morphometric findings from this study could act as a foundation for subsequent related studies. Precise anatomical knowledge of the femoral nerve will minimise direct transection, electrocautery or suture placement associated femoral nerve insults.

**Methods**

**2.1 Study site**

The study was conducted at the Human Anatomy Laboratory, Moi University School of Medicine.

**2.2 Study design**

The study was an anatomical descriptive cross-sectional design.

**2.3 Study population**

This included sequentially selected adult Kenyan formalin prefixed cadaveric pelvic and lower limb specimens. Majority of the limbs available were disarticulated along the Hemipelvectomy planes. This plane extends along the pubic symphysis and the ipsilateral sacroiliac joint with preservation of the ipsilateral pelvic bones. This preserved the bony attachments of the inguinal ligament as well as the distal portions of the psoas major and iliacus muscles. Thus, the proximal portion of the femoral nerve as it emerges at the anterolateral distal portion of the psoas major was followed to the level of the inguinal ligament. Sex of the cadavers was recorded in the data collection sheet.

**2.4 Eligibility Criteria**

**2.4.1 Inclusion criteria**

All adult pelvic and lower limb cadavers without gross evidence of fracture, pathology or prior surgery were included.

**2.4.2 Exclusion criteria**

Deformed or mutilated cadavers were excluded from the study.

**2.5 Sampling and Sample size determination**

The maximum number of affixed unilateral pelvic and lower limb cadaveric specimens attainable at the Moi University Human Anatomy Laboratory meeting the inclusion criteria

totalled 56 specimens.

**2.6 Data Collecting Materials/Tools and Methods/Techniques**

**2.6.1 Data Collecting Materials/Tools**

The cadavers were dissected, and the parameters were measured using a Vernier calliper accurate to 0.01mm. Data was captured in structured data collection forms. The innervations patterns of the main branches [anterior and posterior] were also photographed using a digital camera [Sony® DSC-W180 10.1 megapixels].

**2.6.2 Data Collection Technique/Method**

Dissections were done according to the techniques described by The Cunningham’s Manual of Practical Anatomy 16<sup>th</sup> Edition [11].

Muscular branches of the femoral nerve were identified, and their course described by dissection of the anterior compartment of the thigh. The distance of the femoral nerve at the level of the inguinal ligament from the anterior superior iliac spine was measured and labelled as AFN. Similarly, the distance of the femoral nerve at the level of the inguinal ligament from the pubic symphysis was measured and labelled as PFN. The length of the femoral nerve proximal to the inguinal ligament as it emerged on the anterolateral aspect of the psoas major was measured and labelled as FN1. The length of the femoral nerve just distal to the inguinal ligament to its point of division into the main branches [anterior and posterior] was measured within the femoral triangle and labelled as FN2. The points of innervations of the muscular branches was also recorded within the femoral triangle and labelled in relation to the muscle to which it innervated.

The measurements obtained were subjected to statistical analysis to determine any statistically significant differences in nerve distribution between both sexes.

**3. Results**

**3.1 Bio-demographics**


**Table 1:** Bio- demographics

Variable	Total [n]	95% Confident Interval
Total specimen	56	100%
<b>Sex of the Limb</b>		
Female	21	37.50[24.92-51.45]
Male	35	62.50[48.55-75.08]
<b>Side of the Limb</b>		
Left	24	42.86[29.71-56.78]
Right	32	57.14[43.22-70.29]
<b>Female specimen</b>		
Left	7	33.33[14.59-56.97]
Right	14	66.67[43.03-85.41]
<b>Male specimen</b>		
Left	17	48.57[31.38-66.01]
Right	18	51.43[33.99-68.62]

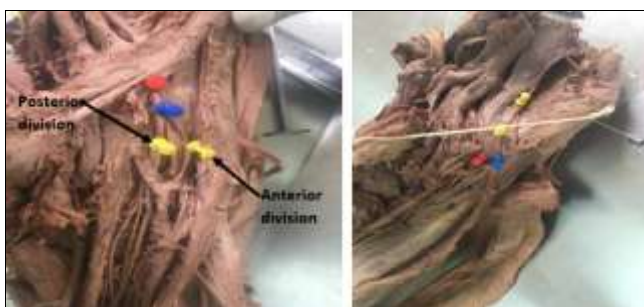
**3.2 Length of the femoral Nerve and its Muscular branches**

**Table 2:** Length of the nerve trunk with relation to bony landmarks

	FN1	FN2	AFN	PFN
Mean	47.85 [SD 13.72]	29.32 [SD 14.24]	53.02 [SD 14.59]	72.87 [SD 19.75]
Median	45.78 [IQR 13.68]	31.02 [IQR 13.69]	54.75 [IQR 12.12]	76.49 [IQR 15.59]
Mode	49.10	31.87	49.10	85.00



**Fig 1:** Measurements and landmarks. [a] Pins positioned at ASIS and midpoint of pubic symphysis [PS] with thread to denote level of inguinal ligament. Red thumb pin -position of the femoral nerve. [b] Measurement of FN2 from level of inguinal ligament to point of branching. Yellow pin-femoral nerve at inguinal ligament level; red pin--branching point; blue pin--posterior division [c] [FN1] measurement of femoral nerve from iliopsoas proximal to inguinal ligament. Yellow pin--femoral nerve; red pin--posterior division; blue pin--anterior division.



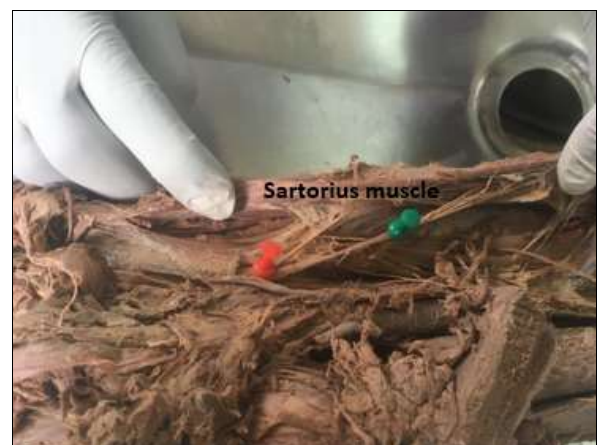**Fig 2:** Observed normal described branching pattern of the femoral nerve distal to inguinal ligament into anterior and posterior divisions. [a] red pin--femoral nerve at level of inguinal ligament; blue pin--point of branching into anterior and posterior divisions [yellow pins] [b] yellow pin--femoral nerve; blue pins--anterior division; red pin--posterior division

**3.3 Branching patterns of the femoral nerve**

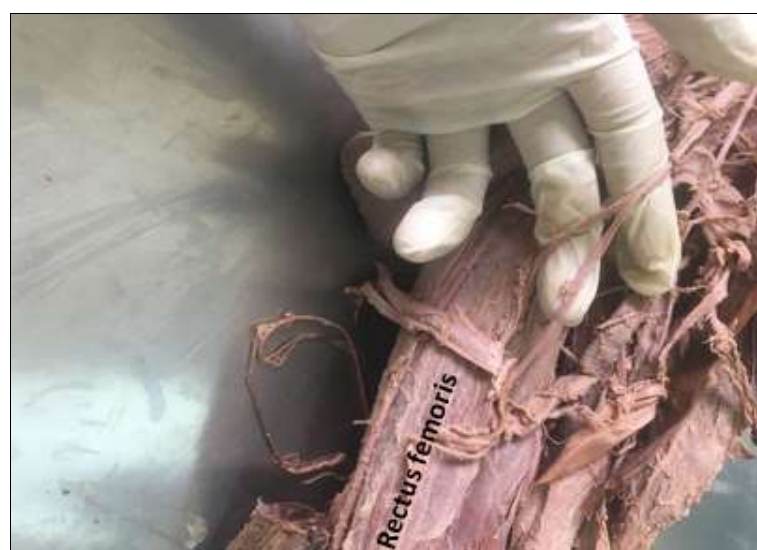

**Fig 3:** Normal branching pattern of the femoral nerve distal to the inguinal ligament. Green pin--position of femoral nerve at the inguinal ligament level. Blue pin--anterior division; yellow pin--posterior division

**3.4 Patterns of distribution of the anterior and posterior muscular branches**



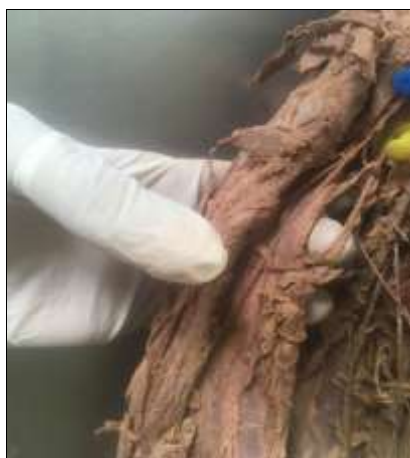**Fig 4:** Three anterior femoral nerves slips innervating deep to the Sartorius



**Fig 5:** Two muscular nerve slips to the medial border of the rectus femoris

**Table 3:** Branching patterns of the femoral Nerve

Variable	Total [n]	95% Confidence Interval
<b>Anterior Branch to Sartorius</b>		
Deep 3 branches	4	7.14[1.98-17.29]
Deep to Sartorius one Branch	43	76.79[63.58-87.02]
Deep with 2 branches	8	14.29[6.38-26.22]
Resected	1	1.79[10.05-9.55]
<b>Posterior Branch To <i>rectus femoris</i></b>		
Along medial border	26	46.43[33.99- 60.26]
Deep to muscle single branch	27	48.21[34.66-61.97]
Deep arising before reaching the Inguinal Ligament.	2	3.57[0.44-12.31]
Missing/Not seen	1	1.79[0.05-9.55]
<b>Posterior Br. To <i>vastus Lateralis</i></b>		
Along the Medial border	54	96.43[87.69-99.56]
Four branches to medial border	1	1.79[0.05-9.55]
Two deep branches to medial border	1	1.79[0.05-9.55]
<b>Posterior Br. To <i>Vastus Intermedius</i></b>		
Along Medial border	44	78.57[65.56-88.41]
Superficial perforates Muscle	12	21.43[11.59- 34.44]
<b>Posterior Br. To <i>Vastus medialis</i></b>		
In the adductor canal	55	98.21[90.45-99.95]
Three Br. To <i>V. Medialis</i>	1	1.79[0.05-9.55]
<b>Observed anatomical Variations</b>		
None	47	83.93[71.67-92.38]
Branching at Inguinal Ligament	6	10.71[4.03-21.88]
Branching proximal to Inguinal Ligament	2	3.57[0.44-12.31]
Slip from Psoas dividing nerve trunk into two uniting proximal to Inguinal Ligament	1	1.79[0.05-9.55]

**Fig 6:** Commonest innervation pattern to the vastus lateralis with one nerve slip along the medial border**Fig 7:** Four muscular nerve slips along the medial border of the vastus lateralis.**Fig 8:** Three muscular slips along the medial border of the vastus medialis**3.5 Observed anatomical branching pattern variations.**

Any anatomical variation in the femoral nerve was also noted for each record. Majority, 47[83.93%] [71.67-92.38], of the cadaveric limbs had no observed anatomical variations observed. However, 6 cadaveric specimens, [10.71%] [4.03-21.88], demonstrated the nerve branching at the level of the inguinal ligament. A further 2[3.57%] [0.44-12.31] had a more proximal branching above the level of the inguinal ligament [Figure 9]. One cadaveric limb had the femoral nerve branching 30.44mm while the other 27.39mm proximal to the level of the inguinal ligament.



**Fig 9:** [a] Femoral nerve branching proximal to the inguinal ligament, [b] Femoral nerve branching at the level of the inguinal ligament

One studied specimen had a more variant anatomy with a slip from the psoas muscle dividing the nerve trunk into two

divisions that were uniting 25.88mm proximal to the inguinal ligament [Figure 10].



**Fig 10:** Psoas muscle slip dividing the nerve trunk into 2 slips [blue pins] that united 25.88mm proximal to the inguinal ligament forming the main nerve trunk [yellow pin] that divided distally from the level of the inguinal ligament into anterior [green] and posterior [red] divisions

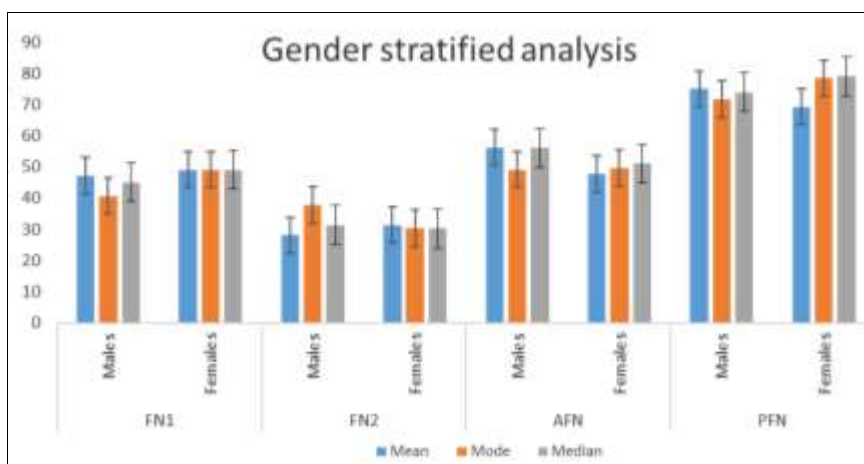
**3.6 Gender- stratified Sub analysis**

Stratified analysis for each of the sex of the limbs was

conducted to ascertain existence of any gender differences.

**Table 4:** Gender stratified subanalysis

		Mean	Mode	Median
FN1	Males	47.13 [SD 14.46]	40.74	45 [IQR 15.82]
	Females	49.04 [SD 12.64]	49.1	49.1 [IQR 8.34]
FN2	Males	28.09 [SD 14.17]	37.742	31.32 [IQR 10.11]
	Females	31.36 [SD 14.45]	30.36	30.25 [IQR 19.40]
AFN	Males	56.19	49.1	56.1 [IQR 9.79]
	Females	47.74 [SD 20.91]	49.61	51.1 [IQR 13.17]
PFN	Males	75.02 [SD 10.74]	71.66	73.9 [IQR 13.88]
	Females	69.29 [SD 29.25]	78.43	79.01 [IQR 10.77]



**Fig 11:** Gender stratified sub-analysis

**Table 5:** Stratified sub-analysis for statistical significance

	Test	Test Value	Cut off	p- Value
FN1	Pooled <i>t</i> - Test	0.5	0.6192	
	ANOVA	0.24991		0.6192
	Mann Whitney	0.4029		0.5256
FN2	Pooled <i>t</i> - Test	0.33	0.4109	
	ANOVA	0.68667		0.411
	Mann Whitney	0.6608		0.4163
AFN	Pooled <i>t</i> - Test	-2.17	0.0346	
	ANOVA	4.7003		0.3046
	Mann Whitney	1.2291		0.2676
PFN	Pooled <i>t</i> - Test	-1.04	0.2968	
	ANOVA	1.1097		0.2968
	Mann Whitney	0.6195		0.4312

The comparative sub analysis of individual measurements demonstrated variability in lengths between genders but the *p*-values >0.05 demonstrated no statistical significance in variance. This demonstrates no significant gender differences as shown in literature.

### Discussion

Descriptions of iatrogenic insults and position of the femoral nerve in relation to the proximal femur have been documented [12, 13]. Some studies have demonstrated position of the femoral nerve with various subtypes of femur neck fractures and possibility of iatrogenic insults [14]. Cadaveric studies have further demonstrated variant course and branching of the femoral nerve even with reference to the individual nerve roots precedent to and after the formation of the nerve [4, 15-17]. This variability should be considered in individuals presenting with idiopathic atraumatic/traumatic motor or sensory deficits along the femoral nerve innervation dermo-myotome path. Femoral nerve blocks are also useful in providing anaesthesia and postoperative analgesia for non-hip fracture surgery and extracapsular neck of femur fractures [14].

#### 4.1 Length of the femoral Nerve and its Muscular branches

The mean length of the nerve proximal to the inguinal ligament but distal to anterolateral border of the psoas muscle was 47.85mm [SD 13.719], concurs with documented findings [1, 2]. However, there is paucity of studies with reference to any ethnic/racial variability and with regard to the muscle bulk of the psoas muscle or in relation to actual length of the individual nerve roots. This therefore demonstrates that the nerve underlies the fascia iliaca for around 5cm proximal to the inguinal ligament which should be considered in patients presenting with hip/knee arthralgia as a consequence of iliacus hematoma or abscess [18-21].

The mean length of the femoral nerve distal to the inguinal ligament to the point of branching into anterior and posterior branches was 29.32 mm [SD 14.239]. This was slightly higher than that described on average by Gustafson *et al.*, [2009] [22] at 15.0 mm which would propose a slightly more distal branching point in our population. Vloka *et al.*, 1999 [23] in a New York based cadaveric study involving 9 specimens described the nerve branching within 2.5cm distal to the inguinal ligament and its importance in appropriate estimation for femoral nerve regional anesthesia block necessary for orthopedic procedures. This figure still fell slightly short of our mean finding suggesting a longer nerve length distal to the inguinal ligament in Kenyan population.

The femoral nerve mean length was 53.02 mm [SD 14.59] from the ipsilateral anterior superior iliac spine at the level of

the inguinal ligament. This finding was lower than that described in a multi-ethnic retrospective MRI study based in Chicago by Watson, Bohnenkamp, El-Bitar, Moretti, and Domb, [2014] [8], which averaged at 28.67mm. The findings in our study were close to the vectors measured among African Americans and Hispanics described in the study. This might demonstrate that the femoral nerve distance from the ASIS among Caucasians and Asians as ascribed in the study might be smaller compared to that in Kenyan population.

At the level of the inguinal ligament the mean length of nerve was 72.87mm [SD 19.75] from the midline of the *symphysis pubis*. Overall the described cumulatively averaged medio-lateral distance from the ASIS to the pubic symphysis corresponded with literature findings [22] with the nerve being at the midpoint of the inguinal ligament. This concurs with the finding in the Kenyan study that the nerve was slightly lateral to the mid – inguinal point. The above findings suggest that in Kenyan population the femoral nerve lies at the midpoint of the inguinal ligament lying averagely 53mm from the ASIS and around 73mm from the midpoint of the pubic symphysis. This therefore approximates the position of the nerve to avoid iatrogenic insults while doing certain approaches to the pelvis and proximal femur including the Iliioinguinal, Stoppa, Iliofemoral and Smith Patterson approaches with reference to the commonly used intraoperative anatomic bony landmarks [12].

#### 4.2 Branching patterns

Similar to two Chinese cadaveric studies by Boo-Chai, [1984] [24] and Yu *et al.*, [2010] [25], the majority of the specimens demonstrated a single branch coursing deep to the Sartorius muscle proximally with some specimens having 2 to 3 sub-branches to the muscle. However, 21.43%, of our specimens had 2-3 twigs arising directly from the anterior branch and coursing deep to the muscle. This finding further augments usability of the Sartorius muscle for muscle compartment transfer in reconstructive arthroplasty.

Innervation to the *rectus femoris* from our study was from the posterior branch which was mostly through a single branch deep to the muscle, 27[48.21%] [CI 34.66-61.97], or along the medial border, 26[46.43%] [CI 33.99-60.26]. This concurred with a Canadian cadaveric study by Yang and Morris, [1999] [26] in which the rectus was innervated by a single muscular branch from the posterior division deep/posterior to the muscle or along the medial border. However, it was not noted to split into 2 branches before entering the muscle as described in the study. Sung *et al.*, [2003] [27] in a Korean cadaveric study demonstrated findings which concurred with Kenyan study with the nerve running along the medial border but described 2 subbranches with the superior subbranch

running deep with the inferior entering the muscle along the medial border. Therefore, our Kenyan study findings concur with those described in other studies showing no noted interracial/ethnic variability with reference to innervation of the *rectus femoris* from the femoral nerve.

Consideration was made for the innervation of the remaining three *vasti* muscle of the quadriceps *femoris* group. The innervation pattern for the *Vastus lateralis* muscle, almost all, 54 [96.43%] [CI 87.69-99.56], revealed an innervation of a single branch along the medial border of the muscle. There were only two exceptions to this pattern, one with four branches to the medial border of the muscle and another with two branches to the medial border each representing 1.79% [CI 0.05-9.55]. Sung *et al.*, [2003] [27] in a Korean cadaveric study demonstrated similar findings but majority of the specimens had 2 subbranches along the medial border. This would suggest no difference in variability in the innervation pattern of the vastus lateralis between Koreans and Kenyan population other than presence of subbranches before perforating the medial aspect of the muscle.

However, unlike the Korean study by Sung *et al.*, [2003] [27], innervation of the *Vastus Intermedius* in Kenyan study was along the medial border, 44[78.57%] [CI 65.56-88.41], with only a few having superficial nerves perforating the muscle 12[21.43%] [CI 11.59-34.44]. Both studies however demonstrate a single nerve to the intermedius muscle. Thiranagama, [1990] in a Sri Lankan cadaveric study made mention of the vastus intermedius receiving a nerve slip from lateral branch of the nerve to the vastus medialis but this was not evident in any of the Kenyan specimens dissected. Our study findings therefore concur with the general described consensus on innervation of the femoral nerve. There was however paucity of cadaveric studies further describing the innervation pattern of the vastus intermedius muscle.

Similar to an Indian cadaveric study by Rajput, Rajani, and Vaniya, [2017] [29] and a south African cadaveric study [30], the *vastus medialis* was solely innervated from the posterior branch of the femoral nerve, but no relation to the subsartorial canal was mentioned. It was further described that the nerve further subdivided before entering the substance of the muscle. A southern Asian [Sri Lankan] study by Thiranagama, [1990] [28] involving 30 cadaveric limbs with a higher male ratio made mention of the nerve to vastus medialis within the adductor canal as found in the Kenyan study but describes this branch as the thicker medial branch from the posterior division. Unlike the Kenyan study, there was mention of an additional slender lateral branch which arose directly from the posterior division of the femoral nerve and made no entry into the adductor canal and further innervated the vastus intermedius.

#### 4.3 Observed anatomical branching pattern variations.

Similar to a French cadaveric study by Galtier *et al.*, [1995] [31] and a Korean study by Sung *et al.*, [2003] [27] no differences were observed between right and left limbs as described in literature. No gender differences were observed as has been described in literature [15, 27, 31].

In most of the specimen, no anatomical variation was observed 47[83.93%] [71.67-92.38]. However, 6 cadaveric specimens [10.71%] [4.03-21.88] demonstrated the nerve branching at the level of the inguinal ligament. A variation described in literature by Das and Vasudeva, 2007 [32] in an Indian cadaveric case report, was observed in 2[3.57%] [0.44-12.31] limbs having a more proximal branching above the

level of the inguinal ligament. One cadaveric limb had the femoral nerve branching 30.44mm while the other 27.39mm proximal to the level of the inguinal ligament. This was almost similar to the measurement described at 32mm. Astik and Dave, [2011] demonstrated a similar variation but the measurements were larger at 40mm and 38 mm [15].

One studied specimen had a more variant anatomy with a slip from the psoas muscle dividing the nerve trunk into two divisions that were uniting 25.88mm proximal to the inguinal ligament. This variation has been described in an Asian cadaveric study by Astik and Dave, [2011] [16] in which the nerve trunk united 40 and 45mm proximal to the inguinal ligament. Variant slips of the iliopsoas major muscles split the femoral nerve into 2 or 3 slips in 35.3% [16], 7% [13] and 2.2% [33]. Jevlev *et al.*, [2005] reported an accessory iliopsoas muscle which split the left femoral nerve in a female cadaver [34].

Variant muscular slip of psoas major or accessory slips from iliacus which cause tension of the femoral nerve should be suspected in patients with referred pain to the hip and knee joints [17]. This variation is an important differential in persistent knee and hip arthralgia in orthopaedic patients and can be accentuated by hyperextension or external hip rotation.

#### 4.4 Gender stratified sub analysis

A sub analysis was conducted to determine any existing differences between male and female specimen. On comparison of all the measurements between males and females, it was noted that the confidence intervals overlap, an indication that there is no statistically significant differences between the two genders as described in literature [15, 27, 31].

#### List of abbreviations and acronyms

A.S.I.S	Anterior Superior Iliac Spine
E.M.G	Electromyography
M.T.R.H	Moi Teaching and Referral Hospital
O.R.I.F	Open Reduction and Internal Fixation
T.F.L	Tensor Fascia Lata
T.H.A	Total Hip Arthroplasty

#### 5. Conclusion

The course, length, and distribution of the femoral nerve in the Kenyan population concur to some extent with described anatomic studies with some noted variability. The zone 53.02 mm [SD 14.59] from the ASIS or 72.87mm [SD 19.75] from the pubic symphysis at the level of the inguinal ligament should be approached with caution when making incisions to the pelvis/proximal femur as this would place the femoral nerve at risk of iatrogenic insult.

#### 5.1 Statements/Declarations

##### 5.1.1 Conflicts of Interest Statement

The authors certify that they have NO affiliations with or involvement in any organization or entity with any financial interest (such as honoraria; educational grants; participation in speakers' bureaus; membership, employment, consultancies, stock ownership, or other equity interest; and expert testimony or patent-licensing arrangements), or non-financial interest (such as personal or professional relationships, affiliations, knowledge or beliefs) in the subject matter or materials discussed in this manuscript.

##### 5.1.2 Funding/Support Statement

The study was fully funded by the researcher and no external grants or sponsorship were sought/received.

## 6. Acknowledgements

Foremost, I would like to express my sincere gratitude to colleagues for the continuous support of this research project, for their patience, motivation, enthusiasm, and immense knowledge.

**6.1 Data availability Statements:** The data that support the findings of this study are available from the corresponding author, [A.M.], upon reasonable request.

## 7. Ethical considerations

Prior to commencement of the study, ethical approval was sought from the Department of Human anatomy and the Institution Research and Ethics Committee (IREC) Moi University. The Anatomy Act Chapter 243-9 (Revised Edition of 2012) of The Laws of Kenya (48) was strictly adhered to. This act states and entitles a person registered as a student in an approved school of anatomy to examine and conduct anatomical research on human cadavers as long as the requirements stipulated in the act are strictly adhered to. Data confidentiality was strictly maintained and this included use of passwords in the database.

- IREC Moi University Approval Number: 0003353
- Reference number: IREC/2019/143

## 8. References

1. Oyedun OS, Rukewe A, Fatiregun A. Femoral nerve dimensions at the inguinal ligament and inguinal crease levels: Implications for femoral nerve block. *J Morphol Sci.* 2014;31(4):207-9.
2. Davis TT, Bae HW, Mok JM, Rasouli A, Delamarter RB. Lumbar plexus anatomy within the psoas muscle: Implications for the transpsoas lateral approach to the L4-L5 disc. *J Bone Jt Surg - Ser A.* 2011;93(16):1482-7.
3. Gindha GS, Deepti A, Subhash K, Usha C. Variations in origin of femoral nerve from the lumbar plexus [a cadaveric study]. *Int J Pharma Sci Res.* 2015;6(4):660-5.
4. Swami S, VB, DS. Anatomical Variations in Formation and Branching Pattern of the Femoral Nerve in Iliac Fossa. *Sch J Appl Med Sci.* 2020;08(02):608-11.
5. Standring S, Gray H. Gray's anatomy: the anatomical basis of clinical practice. 40th ed. New York: Churchill Livingstone/Elsevier. 2008, 1551.
6. Cunningham DJ, Romanes J. Cunningham's text-book of anatomy. In: 12th ed. New York: Oxford University Press. 1995 [cited 2019 Mar 27], 794-5. Available from: <https://adams.marmot.org/Record/.b17502330?searchId=94285459&recordIndex=1&page=1>
7. Burke NG, Walsh M, O'Brien T, Synnott K. Diagnostic Gait Pattern of a Patient with Longstanding Left Femoral Nerve Palsy: A Case Report. *J Orthop Surg [Internet].* 2010;18(3):382-4. Available from: <http://journals.sagepub.com/doi/10.1177/230949901001800327>
8. Watson JN, Bohnenkamp F, El-Bitar Y, Moretti V, Domb BG. Variability in Locations of Hip Neurovascular Structures and Their Proximity to Hip Arthroscopic Portals. *Arthrosc J Arthrosc Relat Surg [Internet].* 2014 Apr [cited 2018 Dec 10];30(4):462-7. Available from: <http://www.ncbi.nlm.nih.gov/pubmed/24560908>
9. Bono V, la Bella V, Spataro R. Bilateral iatrogenic femoral neuropathy. *J Clin Neurol.* 2015;11(4):398-9.
10. Al-Ajmi A, Rouseff RT, Khuraiabet AJ. Iatrogenic femoral neuropathy: Two cases and literature update. *J Clin Neuromuscul Dis.* 2010;12(2):66-75.
11. Koshi DR. Cunningham's Manual of Practical Anatomy. In: 16<sup>th</sup> ed. New York: Oxford University Press. 2017, 283-8.
12. Chelly JE, Uskova AA, Plakseychuk A. The role of surgery in postoperative nerve injuries following total hip replacement. *J Clin Anesth [Internet].* 2010;22(4):285-93. Available from: <http://dx.doi.org/10.1016/j.jclinane.2009.10.006>
13. Vázquez MT, Murillo J, Marañillo E, Parkin IG, Sanudo J. Femoral nerve entrapment: A new insight. *Clin Anat.* 2007;20(2):175-9.
14. Haddad FS, Williams RL. Femoral nerve block in extracapsular femoral neck fractures. *J Bone Jt Surg - Ser B.* 1995;77(6):922-3.
15. Astik RB, Dave UH. Anatomical Variations in Formation and Branching Pattern of the Femoral Nerve in Iliac Fossa: A Study in 64 Human Lumbar Plexuses. *People's J Sci Res.* 2011;4(2):14-9.
16. Anloague PA, Huijbregts P. Anatomical Variations of the Lumbar Plexus: A Descriptive Anatomy Study with Proposed Clinical Implications. *J Man Manip Ther [Internet].* 2009;17(4):107E-114E. Available from: <http://www.tandfonline.com/doi/full/10.1179/106698109791352201>
17. Spratt JD, Logan BM, Abrahams PH. Variant slips of psoas and iliacus muscles, with splitting of the femoral nerve. *Clin Anat.* 1996;9(6):401-4.
18. Yi TI, Yoon TH, Kim JS, Lee GE, Kim BR. Femoral neuropathy and meralgia paresthetica secondary to an iliacus hematoma. *Ann Rehabil Med [Internet].* 2012;36(2):273-7. Available from: <http://www.scopus.com/inward/record.url?eid=2-s2.0-84862015862&partnerID=40&md5=15ab7c3212b75e7a8ad41fb45fc1b999>
19. Nobel W, Marks SC, Kubik S. The anatomical basis for femoral nerve palsy following iliacus hematoma. *J Neurosurg.* 1980;52(4):533-40.
20. Ha YC, Ahn IO, Jeong ST, Park H Bin, Koo KH. Iliacus hematoma and femoral nerve palsy after revision hip arthroplasty: A case report. *Clin Orthop Relat Res.* 2001;(385):100-3.
21. Andreani L, Nucci AM, Giuntoli M, Lisanti M. Compressive Femoral Neuropathy Associated with Iliopsoas Hematoma Complicating Hip Hemiarthroplasty: A Case Report. *J Orthop case reports.* 2017;7(5):3-6.
22. Gustafson KJ, Pinault GCJ, Neville JJ, Syed I, Jr JAD, Jean-Claude J, *et al.* Fascicular anatomy of human femoral nerve: Implications for neural prostheses using nerve cuff electrodes. *J Rehabil Res Dev [Internet].* 2009;46(7):973. Available from: <http://www.rehab.research.va.gov/jour/09/46/7/pdf/gustafson.pdf>
23. Vloka JD, Hadžić A, Drobnik L, Ernest A, Reiss W, Thys DM. Anatomical landmarks for femoral nerve block: A comparison of four needle insertion sites. *Anesth Analg.* 1999;89(6):1467-70.
24. Boo-Chai K. Blood supply and nerve innervation of the sartorius muscle. [Chinese]. *Plast Reconstr Surg.* 1984;74(2):322.
25. Yu DZ, Liu AT, Dang RS, Zhang C Sen, Zhang JL, Chen G, *et al.* Intramuscular innervations of muscle flaps that are commonly used in clinical settings. *Surg Radiol Anat.* 2010;32(7):637-46.
26. Yang D, Morris SF. Neurovascular anatomy of the rectus



- femoris muscle related to functioning muscle transfer. *Plast Reconstr Surg.* 1999;104(1):102-6.
27. Sung DH, Jung J-Y, Kim H-D, Ha BJ, Ko YJ. Motor branch of the rectus femoris: anatomic location for selective motor branch block in stiff-legged gait. *Arch Phys Med Rehabil.* 2003;84(7):1028-31.
  28. Thiranagama R. Nerve supply of the human vastus medialis muscle. *J Anat.* 1990;170:193-8.
  29. Rajput H, Rajani S, Vaniya VH. Variation in morphometry of vastus medialis muscle. *J Clin Diagnostic Res.* 2017;11(9):AC01-4.
  30. Nozic M, Mitchell J, De Klerk D. A comparison of the proximal and distal parts of the vastus medialis muscle. *Aust J Physiother.* 1997;43(4):277-81.
  31. Galtier B, Buillot M, Vanneuville G. Anatomical basis of the role of vastus medialis muscle in femoro-patellar degenerative arthropathy. *Surg Radiol Anat.* 1995;17(1):7-11.
  32. Das S, Vasudeva N. Anomalous higher branching pattern of the femoral nerve: a case report with clinical implications. *Acta Medica [Hradec Kralove] [Internet].* 2007;50(4):245-6. Available from: <http://www.embase.com/search/results?subaction=viewrecord&from=export&id=L351556832\nhttp://sfx.library.uu.nl/utrecht?sid=EMBASE&issn=12114286&id=doi:&title=Anomalous+higher+branching+pattern+of+the+femoral+nerve:+a+case+report+with+clinical+implicatio>
  33. Spratt JD, Logan BM, Abrahams PH. Variant slips of psoas and iliacus muscles, with splitting of the femoral nerve. *Clin Anat [Internet].* 1996 Jan 1 [cited 2018 Dec 11];9(6):401-4. Available from: <http://doi.wiley.com/10.1002/%28SICI%291098-2353%281996%299%3A6%3C401%3A%3AAID-CA8%3E3.0.CO%3B2-D>
  34. Jelev L, Shivarov V, Surchev L. Bilateral variations of the psoas major and the iliacus muscles and presence of an undescribed variant muscle – accessory iliopsoas muscle. *Ann Anat - Anat Anzeiger [Internet].* 2005 Jul [cited 2018 Dec 11];187(3):281-6. Available from: <http://linkinghub.elsevier.com/retrieve/pii/S0940960205000300>