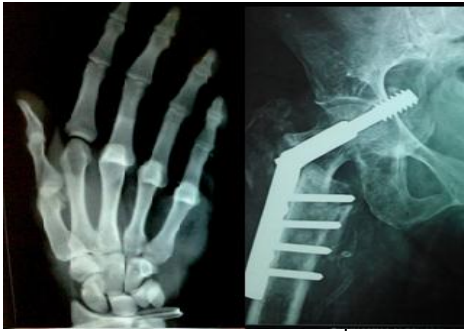

International Journal of Orthopaedics Sciences

E-ISSN: 2395-1958
P-ISSN: 2706-6630
IJOS 2022; 8(1): 336-339
© 2022 IJOS
www.orthopaper.com
Received: 17-10-2021
Accepted: 19-12-2021

Dr. Abhishek Kumar Rai
Senior Resident, Department of
Orthopaedics, Seth GS Medical
College and KEM Hospital,
Mumbai, Maharashtra, India

Dr. Ajay Kumar Shukla
Senior Resident, Department of
Orthopaedics, Seth GS Medical
College and KEM Hospital,
Mumbai, Maharashtra, India

Dr. Surendar Singh Bava
Professor and Head of Unit,
Department of Orthopaedics,
Seth GS Medical College and
KEM Hospital, Mumbai,
Maharashtra, India

Dr. Dixit Bansal
MBBS, Government Medical
College, Amritsar, Punjab, India

Dr. Geekesh Kumar KG
Senior Resident, Department of
Orthopaedics, Seth GS Medical
College and KEM Hospital,
Mumbai, Maharashtra, India

Dr. Syed Hifzur Rahman
Senior Resident, Department of
Orthopaedics, Seth GS Medical
College and KEM Hospital,
Mumbai, Maharashtra, India

Corresponding Author:
Dr. Surendar Singh Bava
Professor and Head of Unit,
Department of Orthopaedics,
Seth GS Medical College and
KEM Hospital, Mumbai,
Maharashtra, India

Radiological assessment of collapse of distal end radius fracture followed by close reduction and cross k wire fixation

Dr. Abhishek Kumar Rai, Dr. Ajay Kumar Shukla, Dr. Surendar Singh Bava, Dr. Dixit Bansal, Dr. Geekesh Kumar KG and Dr. Syed Hifzur Rahman

DOI: <https://doi.org/10.22271/ortho.2022.v8.i1e.3038>

Abstract

Background: Distal end radius fractures are the commonest occurring fractures occurring in upper extremity. They represent one-sixth of all fractures treated in emergency department. The present study was conducted to assess collapse in distal end radius fracture following close reduction and cross K wire fixation using standard AP and lateral radiological parameters of reduction.

Materials & Methods: A sample of 40 patients who underwent K wire fixation for unstable fractures of distal radius over a period of 18 months reporting serially to the orthopaedics OPD a single tertiary hospital were included.

Results: The mean immediate postoperative volar tilt was 10.08°, while at 6 weeks postoperative, it was found to be 8.91° respectively. The mean immediate postoperative radial inclination was 24.02°, while at 6 weeks postoperative, it was found to be 22.67° respectively. The mean immediate postoperative Ulnar variance was 0.38 mm while at 6 weeks postoperative, it was found to be - 0.008 mm respectively. Significant results were obtained while comparing the Ulnar variance at different postoperative time intervals. Collapse in volar tilt after K wire removal was seen in 71.11 percent of the patients. Among these, 1°, 2° and 3° collapse of volar tilt was seen in 31.11 percent, 33.33 percent and 6.67 percent of the patients respectively.

Conclusion: The closed reduction and percutaneous K-wire fixation is a least invasive, safer, and effective method to maintain the reduction, prevent significant collapse during healing, and maintain the stability of the distal radio-ulnar joint even when the fracture is grossly comminuted, intra-articular, or unstable.

Keywords: Percutaneous K-wire fixation, closed reduction, distal end radius

Introduction

Fractures of the distal radius account for some of the most common low-energy fractures seen in ambulatory orthopaedics accounting for between 8% and 15% of all bone related injuries in adults. It is second only to the hip as the most commonly fractured bone in the elderly [1]. Additionally, the subluxation of the annular ligament which stabilizes the proximal radius is an injury commonly seen by pediatricians. Distal end radius fractures are the commonest occurring fractures occurring in upper extremity they represent one-sixth of all fractures treated in emergency department [2]. Although it was described more than 199 years ago controversies still exist regarding the best mode of treatment, immobilization & prediction of results. Many of the societal effects of these fractures extend beyond the significant medical costs, including decreased school attendance, lost work hours, loss of independence and lasting disability. Fragmented care and coding discrepancies can make accounting for the true number of these fractures difficult, likely underestimating the rates typically quoted in the literature. When analyzing the incidence of distal radius fractures, there are three major populations to consider: children and adolescents, young adults, and the elderly. The pediatric and elderly populations are both considered at high risk for this injury [3].

There are numerous treatment modalities available to orthopaedic surgeons in the treatment of a distal radius fracture; these include closed reduction and casting, closed reduction and

percutaneous pinning by different methods such as Kapandiji intrafocal pinning, transradial styloid pinning, pinning via the Listers tubercle or transulnar pinning [4]. Other modalities of treatment include closed reduction and external fixation by means of ligamentotaxis to realign fracture displacement, open reduction by volar or dorsal approach and internal fixation by different implants such as screws, plates, or screws with locking plate [5]. The present study was conducted to assess collapse in distal end radius fracture following close reduction and cross K wire fixation using standard AP and lateral radiological parameters of reduction.

Materials & Methods

A sample of 40 patients who underwent K wire fixation for unstable fractures of distal radius over a period of 18 months reporting serially to the orthopaedics OPD in a single tertiary hospital were included in this retrospective study. Radiographs taken just prior to removal of K wires and repeat radiographs taken at one month after wire removal were analyzed to study three radiological parameters; Palmar or dorsal tilt, radial inclination and ulnar variance. Volar or dorsal tilt - A line is drawn joining the most distal ends of the volar and dorsal side of the radius. Another line perpendicular to the longitudinal axis of the radius is drawn. The angle between the two lines is the angle of volar or dorsal tilt of the wrist. Measurement of volar or dorsal tilt should be made in true lateral view of the wrist because pronation of the forearm reduces the volar tilt and supination increases it. When dorsal tilt is more than 11 degrees, it is associated with loss of grip strength and loss of wrist flexion.

Radial inclination - It is the angle between a line drawn from the radial styloid to the medial end of the articular surface of the radius and a line drawn perpendicular to the long axis of the radius. Loss of radial inclination is associated with loss of grip strength.

Ulnar variance - It is the vertical distance between a horizontal line parallel to the articular surface of the radius and another horizontal line drawn parallel to the articular surface of the ulnar head. Positive ulnar variance (ulna appears longer than radius) disturbs the integrity of triangular fibrocartilage complex and is associated with loss of grip strength and wrist pain. Standard wrist radiographs include the PA, lateral, and 45-degree semi-pronated oblique. These

allow for improved evaluation of the distal radioulnar joint (DRUJ) and the distal radius. Results were assessed statistically with p value less than 0.05 considered significant.

Results

Table 1: Age-wise distribution of patients

Age group (years)	Number of patients	Percentage of patients
41 to 50	14	31.11
51 to 60	19	42.22
61 to 70	12	26.67
Total	45	100
Mean ± SD	55.4 ± 7.43	

Table 1 shows that 42.22 percent of the patients belonged to the age group of 51 to 60 years while 26.67 percent of the patients belonged to the age group of 61 to 70 years respectively. 31.11 percent of the patients belonged to the age group of 41 to 50 years. Mean age of the patients was 55.4 years.

Table 2: Gender-wise distribution of patients

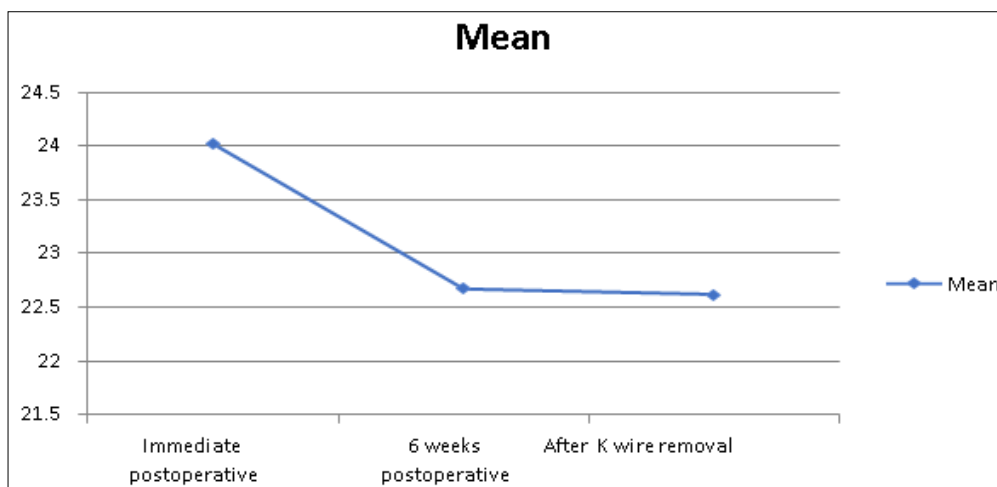
Gender	Number of patients	Percentage of patients
Males	22	48.89
Females	23	51.11
Total	45	100

Table 2 shows that there were 22 males and 23 females.

Table 3: Volar Tilt postoperative correction

Volar or Dorsal Tilt (°)	Mean	SD
Immediate postoperative	10.08	2.15
6 weeks postoperative	8.91	1.96
After K wire removal	8.91	1.96
p- value	0.029 (Significant)	

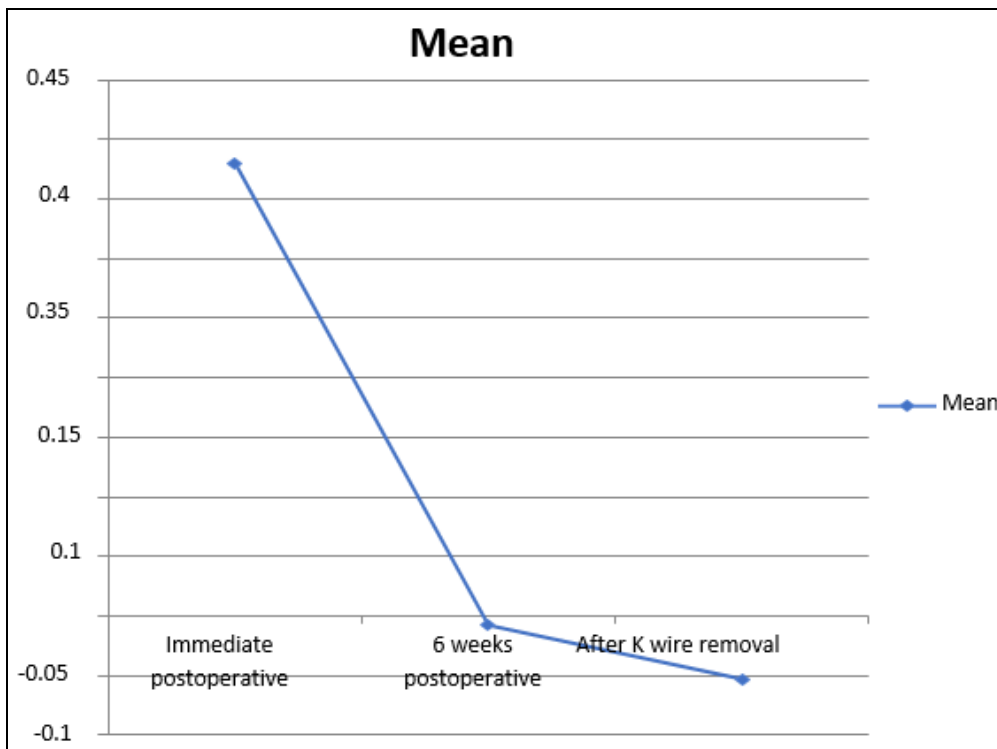
Table 3 shows that mean immediate postoperative volar tilt was 10.08° while at 6 weeks postoperative, it was found to be 8.91° respectively. Mean Volar Tilt after K wire removal was 8.91°. Significant results were obtained while comparing the volar tilt at different postoperative time intervals.



Graph 1: Radial inclination postoperative correction

Graph 1 shows that mean immediate postoperative radial inclination was 24.02° while at 6 weeks postoperative, it was found to be 22.67° respectively. Mean radial inclination after

K wire removal was 22.67°. Significant results were obtained while comparing the radial inclination at different postoperative time intervals.



Graph 2: Ulnar variance postoperative correction

Graph 2 shows that mean immediate postoperative Ulnar variance was 0.38 mm while at 6 weeks postoperative, it was found to be - 0.008 mm respectively. Mean Ulnar variance after K wire removal was 0.053. Significant results were obtained while comparing the Ulnar variance at different postoperative time intervals.

Table 4: Collapse in volar tilt after K wire removal

Collapse	Number of patients	Percentage
Absent	13	28.89
1°	14	31.11
2°	15	33.33
3°	3	6.67
Total	45	100

Table 4 shows that collapse in volar tilt after K wire removal was seen in 71.11 percent of the patients. Among these, 1°, 2° and 3° collapse of volar tilt was seen in 31.11 percent, 33.33 percent and 6.67 percent of the patients respectively.

Table 5: Collapse in radial inclination after K wire removal

Collapse	Number of patients	Percentage
Absent	11	24.44
1°	15	33.33
2°	12	26.67
3°	4	8.89
4°	3	6.67
Total	45	100

Table 5 shows that collapse in radial inclination after K wire removal was seen in 75.56 percent of the patients. Among these, 1°, 2°, 3° and 4° collapse of radial inclination was seen in 33.33 percent, 26.67 percent, 8.89 percent and 6.67 percent of the patients respectively.

Table 6 shows that collapse in ulnar variance after K wire removal was seen in 66.67 percent of the patients. Among these, 0.5 mm, 1 mm and 2 mm collapse of radial inclination was seen in 51.11 percent, 13.33 percent and 2.22 percent of the patients respectively.

Table 6: Collapse in Ulnar variance after K wire removal

Collapse	Number of patients	Percentage
Absent	15	33.33
0.5 mm	23	51.11
1 mm	6	13.33
2 mm	1	2.22
Total	45	100

Discussion

With the wide array of treatment options now available, this is an exciting era for the treatment of fractures of the distal radius. An improved understanding of kinematics, bone quality, and muscle forces acting across the fracture has led to increased awareness of a fracture’s relative stability, as well as the development of innovative devices to counteract these forces and restore stability. Innovations have occurred in closed treatment, percutaneous fixation, external fixation, and in particular, implants for internal fixation. However, new devices and techniques require careful assessment of efficacy, risk, and benefit as they are applied in practice, especially since the incidence of this fracture is likely to rise in an aging population [6].

Distal radius fractures are the most common fractures seen in the emergency department. Despite relative improvements in fracture fixation stability, there remained no hard data for surgeons to link patient function or outcome with treatment variables. Surgeons used a variety of techniques ranging from casting with or without Kirschner wire fixation to pins and

plaster or external fixation, without comparative studies or a means to judge results. The early method of closed reduction and cast immobilization has resulted in malunion, joint stiffness, and deformity. It adversely affects the wrist and hand function by interfering with the mechanical advantage of the extrinsic hand musculature [7]. Closed reduction and Plaster of Paris (POP) immobilization often leads to collapse of the radius. The present study was undertaken for assessing collapse in distal end radius fracture following close reduction and cross K wire fixation using standard AP and lateral radiological parameters of reduction (Palmar or dorsal tilt, radial inclination and ulnar variance). A total of 45 patients were analysed.

In the present study, 42.22 percent of the patients belonged to the age group of 51 to 60 years while 26.67 percent of the patients belonged to the age group of 61 to 70 years respectively. 31.11 percent of the patients belonged to the age group of 41 to 50 years. Mean age of the patients was 55.4 years. Challani A *et al.* [8], in their study reported the mean age of the patients to be 34.5 years.

In the present study, 48.89 percent of the patients were males while the remaining were females. In the present study, mean immediate postoperative volar or dorsal tilt was 10.08° while at 6 weeks postoperative, it was found to be 8.91° respectively. The mean Volar or Dorsal Tilt after K wire removal was 8.91°. Significant results were obtained while comparing the volar or dorsal tilt at different postoperative time intervals. Mean immediate postoperative radial inclination was 24.02° while at 6 weeks postoperative, it was found to be 22.67° respectively. Mean radial inclination after K wire removal was 22.67°. Significant results were obtained while comparing the radial inclination at different postoperative time intervals. Mean immediate postoperative Ulnar variance was 0.38 mm while at 6 weeks postoperative, it was found to be -0.008 mm respectively. Mean Ulnar variance after K wire removal was -0.053. Significant results were obtained while comparing the Ulnar variance at different postoperative time intervals. Similar results have been reported in the past literature [9, 10, 11, 12]. In another study conducted by Chung PY *et al.* [13], the mean radial height, radial inclination, radial tilt and ulnar variance measures before fracture reduction were 9.22 mm, 19.08 degrees, -14.67 degrees and 2.83 mm.

In the present study, Collapse in volar tilt after K wire removal was seen in 71.11 percent of the patients. Among these, 1°, 2° and 3° collapse of volar tilt was seen in 31.11 percent, 33.33 percent and 6.67 percent of the patients respectively. Collapse in radial inclination after K wire removal was seen in 75.56 percent of the patients. Among these, 1°, 2°, 3° and 4° collapse of radial inclination was seen in 33.33 percent, 26.67 percent, 8.89 percent and 6.67 percent of the patients respectively. Collapse in ulnar variance after K wire removal was seen in 66.67 percent of the patients. Among these, 0.5 mm, 1 mm and 2 mm collapse of radial inclination was seen in 51.11 percent, 13.33 percent and 2.22 percent of the patients respectively. Panthi *et al.* [14], in their study, made radiographic measurements using a goniometer to assess the amount of collapse. The preoperative mean dorsal angle and the mean ulnar variance were 22.33 and 3.66, respectively. Following surgical correction, the mean dorsal angle and ulnar variance were -6.87 and 1.17, respectively. The amount of collapse measured at the six-month final assessment in the mean dorsal angle and ulnar variance was 0.94 and 0.51, respectively. Weber documented that collapse of the fracture is unavoidable because the compressive forces generated by the tendons of flexor and the extensor muscles crossing the wrist cannot be counteracted by the supporting plaster. Need for intact volar buttress and

dorsal tension by traction or external fixator was stressed to prevent them.

Conclusion

The closed reduction and percutaneous K-wire fixation is a least invasive, safer, and effective method to maintain the reduction, prevent significant collapse during healing, and maintain the stability of the distal radio-ulnar joint even when the fracture is grossly comminuted, intra-articular, or unstable.

References

1. Simic PM, Weiland AJ. Fractures of the distal aspect of the radius: changes in treatment over the past two decades. *Instr Course Lect.* 2003;52:185-95.
2. Jupiter JB. Fractures of distal end of radius. *J Bone Joint Surg (Am).* 1991;73:461-9.
3. Cooney WP 3rd, Dobyns JH, Linscheid RL. Complications of Colles fractures. *J Bone Joint Surg (Am).* 1980;62:613-9.
4. Miyake T, Hashizume H, Inoue H, Shi Q, Nagayama N. Malunited colles' fracture. Analysis of stress distribution. *J Hand Surg [Br].* 1994;19(6):737-42.
5. Quinn SF, Murray W, Watkins T, Kloss J. CT for determining the results of treatment of fractures of the wrist. *AJR Am J Roentgenol.* 1987;149:109-11.
6. Nissen-lie HS. Fracture radii "typical" *Nord Med.* 1939;1:293-303.
7. Gunay C, Oken OF, Yavuz OY, Günay SH, Atalar H. Which modality is the best choice in distal radius fractures treated with two different Kirschner wire fixation and immobilization techniques?. *Turkish Journal of Trauma and Emergency Surgery.* 2015 Mar 1;21(2):119-26.
8. Challani A, Agrawal A, Kadam R, Jain V, Shah A, Pandey S. Assessment of radiological evidence of collapse of distal end radius fracture after treating with cast, percutaneous k- wire fixation and external fixator. *Int J Res Orthop* 2018;4:367-70.
9. Hardik Kapopara, Vivek Dubey, Rajeev B. Reddy, Surya Chandramurthy, Sunil M. Shahane, Ashwin Samant. Functional, clinical and radiological outcome of extra articular distal end radius fracture in elderly patients, closed reduction and cross K-wiring versus conservative management (closed reduction and casting). *International Journal of Contemporary Medical Research* 2018;5(6):14-16.
10. Sam J. Functional Outcome Analysis of fixation of Distal Radius Fractures using 'Five Pin Technique' (Doctoral dissertation, Madras Medical College, Chennai). 2018.
11. Hodel S, Schraner C, Oehme F, van Leeuwen R, Link BC, Babst R, Beeres FJ. Factors predicting adverse outcome in complete intra-articular distal radius fractures. *European Journal of Trauma and Emergency Surgery.* 2019 Feb;28:1-7.
12. Gofton W, Liew A. Distal radius fractures: Non-operative and percutaneous pinning treatment options. *Orthop Clin North Am.* 2007;38:175-85.
13. Chuang PY, Yang TY, Shen SH, Tsai YH, Huang KC. The Effects of Dorsal Cortical Comminution on Radiographic Results following Percutaneous Pinning for Extra- Articular Colles' Fracture. *BioMed research international.* 2015.
14. Panthi S, Khatri K, Kharel K, Byanjankar S, Sharma JR, Shrestha R, *et al.* Radiological and functional outcome of displaced Colles' fracture managed with closed reduction and percutaneous pinning: a prospective study. *Cureus.* 2017 Jan;9(1).