

E-ISSN: 2395-1958
P-ISSN: 2706-6630
IJOS 2022; 8(1): 103-109

www.orthopaper.com
Received: 12-10-2021
Accepted: 21-12-2021

Dr. M Chakravarthi
Postgraduate Student, Department of Orthopaedics, Rajah Muthiah Medical College and Hospital, Annamalai University, Tamil Nadu, India

Dr. A Senthilnathan
Professor, Department of Orthopaedics, Rajah Muthiah Medical College and Hospital, Annamalai University, Tamil Nadu, India

Dr. R Prabhakar
Lecturer, Department of Orthopaedics, Rajah Muthiah Medical College and Hospital, Annamalai University, Tamil Nadu, India

Dr. K Vijaya Shankar
Assistant Professor, Department of Orthopaedics, Rajah Muthiah Medical College and Hospital, Annamalai University, Tamil Nadu, India

Corresponding Author:
Dr. M Chakravarthi
Postgraduate Student, Department of Orthopaedics, Rajah Muthiah Medical College and Hospital, Annamalai University, Tamil Nadu, India

Transient weakness of extensor hallucis longus after proximal fibular osteotomy for the management of medial compartmental osteoarthritis of knee

Dr. M Chakravarthi, Dr. A Senthilnathan, Dr. R Prabhakar and Dr. K Vijaya Shankar

DOI: https://doi.org/10.22271/ortho.2022.v8.i1b.2994

Abstract
Aim: To evaluate the reason behind the extensor hallucis longus weakness transiently after proximal fibular osteotomy for the management of medial compartmental osteoarthritis of the knee, and to determine the correct level of osteotomy below the level of tip of fibular head.
Materials and Methods: A prospective study from October 2019 to October 2021 at Rajah Muthiah Medical College and Hospital, in 15 patients who underwent proximal fibular osteotomy for medial compartmental osteoarthritis of knee, three patients postoperatively develops EHL weakness transiently analysed and evaluated in this study. All postoperative complications are noted and evaluated periodically for all patients, recovery of power of EHL muscle and other motor sensory status is also noted.
Results: Out of 15 patients surgically managed with PFO, only three patients developed transient EHL weakness and one patient developed transient numbness over the lateral aspect of foot. Among those three patient two patient recovered from neuropraxia within 6 weeks and one patient recovered after 8 months .transient numbness over lateral aspect of foot in a patient recovered within 3 weeks. Commonly fibula resected within or at the level of 6cm below the fibular head develops EHL weakness. Post operative EMG and NCS also done to confirm neuropraxia. later on fibula resected 24% length of total fibula below the fibular head, not encountered the immediate postop EHL weakness.
Conclusion: The optimal site for fibular osteotomy for PFO in medial compartmental osteoarthritis of knee is at the junction of 24% of fibular length above and 76% below the osteotomy location. Provides good pain relief and functional recovery without transient EHL weakness and other complications. EHL weakness occurs mostly due to traction neuropraxia to the nerve which supplying the EHL muscles, more likely to occur in very high osteotomy less than 6cm from tip of fibular head.

Keywords: Transient extensor hallucis longus weakness, common peroneal nerve neuropraxia, proximal fibular osteotomy, medial compartmental osteoarthritis of knee

Introduction

The emerging technique for the treatment of medial compartmental osteoarthritis of knee is a proximal fibular osteotomy. Osteoarthritis of knee is a chronic, progressive and degenerative disease. The pathological characteristics of Knee Osteoarthritis include joint structure degradation and cartilage destruction and hyperplasia, with joint pain, dysfunction and joint deformity as the main clinical symptoms. Genu varum is more common in OA because of the fact that the mechanical axis, even in normal knees, passes a just medial to the centre of the joint that drives 60%-80% of body weight through the medial side of the knee joint [1].

Concepts behind the PFO: The medial side of knee has only a single cortical support which is made up of fully cancellous bone, tends to collapse with advancing age, however, the lateral side of the knee is supported by three cortical support, one from tibia and two from fibula, making it rigid and un-collapsable. This leads to occurring and increasing varus deformity with age and causes medial compartment OA of the knee with a gradual reduction in medial joint space [2]. Hence, in proximal fibular osteotomy, by removing 1 to 2 cm of fibula six to nine cm from the tip of the fibular head, to relieve compartment pressure on medial side of knee, and realign it.

The PFO is characterised by a technically easy and simple procedure with minimal tissue damage, there is no need of internal fixation, less operating time, early weight-bearing, few complications and definite effects The present study analysed the effectiveness of proximal fibular osteotomy (PFO) to produce symptomatic relieving of knee pain and improvement of joint space in medial compartment and function range of motion in patient with medial compartmental osteoarthritis of knee.

PFO associated with occasional complications like neuropraxia, wound infection, vascular injury and joint infection in previous studies. But in our patients only complications occurs is transient EHL weakness, in this study we analysed the reason behind the transient EHL weakness and trying to attaining an optimal site for fibula resection from the tip of the fibular head.

The fibula is commonly used as an autograft and is the main source of graft for bridging defects in long bones resulting from tumor or trauma in which allograft are not adequate.

As a distal quarter of fibula is necessary to maintain a stable ankle mortise, it is proximal three quarter which is usually removed as a graft [3, 4].

These procedures associated with few complications, although muscle weakness may occur. Some authors attribute this due to alteration or loss of muscle attachment, weakness of extensor hallucis longus is seen most often.

The Common Peroneal Nerve

The common peroneal nerve arises from L4 to S2 nerve roots.

Motor distribution: The common peroneal nerve directly innervates the short head of the biceps femoris, it also supplies the muscles in anterior and lateral compartment of leg through branches.

Sensory distribution over the skin of the lateral aspect of leg and dorsal aspect of foot.

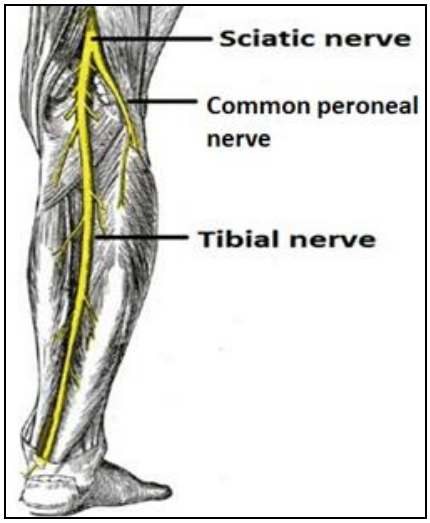

Fig 1: Anatomical course of common peroneal nerve

Anatomical Course: The sciatic nerve is divided into two branches at popliteal fossa, the common peroneal nerve begins at the apex of popliteal fossa and passes along the medial border of the biceps femoris. Running in a inferior and lateral direction. Over the lateral head of gastrocnemius. At that point two cutaneous branches arises from the nerve, which contributes innervation of the skin of the leg. By wrapping around the fibular neck, common peroneal nerve enter the lateral compartment of leg, travels between the attachment of peroneus longus muscle. Then terminates by dividing into superficial peroneal nerve and deep peroneal nerve.

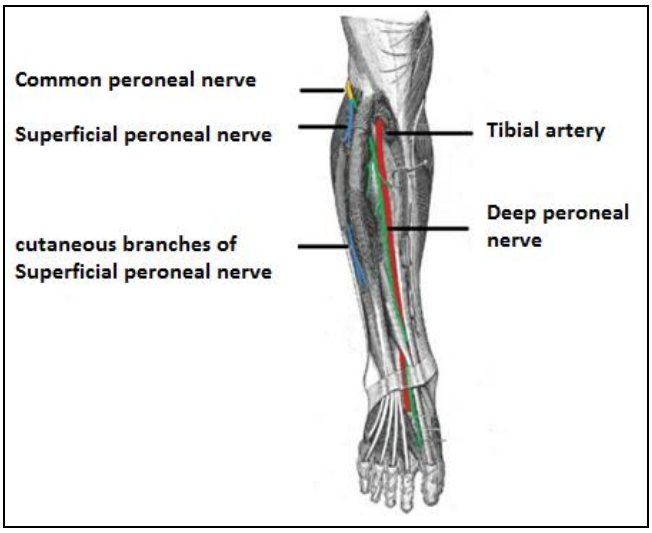

Fig 2: Branches of common peroneal nerve

Motor Functions: The common peroneal nerve innervates the short head of biceps femoris, which is part of the hamstring muscles, which flex at knee If the common peroneal nerve is damaged the patient may be unable to do dorsiflexion of ankle, Everson of foot and extensions of toes.

Superficial peroneal nerve: Superficial peroneal nerve supplies peroneus longus and peroneus brevis (muscles of lateral compartment of leg) these muscles evert the foot.

Deep peroneal nerve: supplies the anterior compartment muscles of leg, tibialis anterior, extensor digitorum longus and extensor hallucis longus. These muscles act to dorsiflex the foot and extend the digits and also supplies intrinsic muscles of foot.

Sensory Functions: The common peroneal nerve gives two cutaneous branches directly at the lateral head of gastronemius. In addition to these nerves, the terminal branches of the common peroneal nerve also have a cutaneous function.

Superficial peroneal nerve: Innervates the skin of the anterolateral aspect leg, and dorsal aspect of the foot (except the skin over first web space of foot).

Deep peroneal nerve: Innervates the skin over first web space of foot.

Sural communicating nerve – combines with a branch of the tibial nerve to form the sural nerve, which supplies the skin over the lower posterolatera aspect l leg. Lateral sural cutaneous nerve – supplies the skin over the upper lateral aspect of leg.

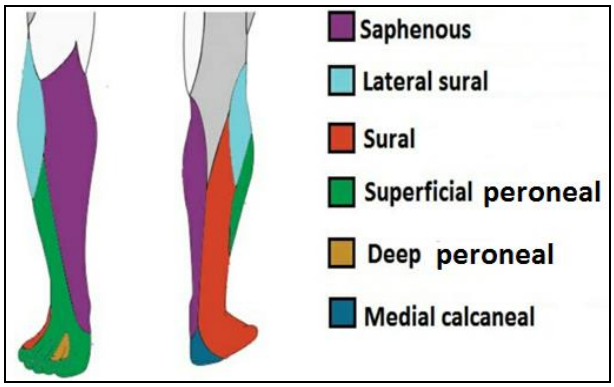

Fig 3: Sensory distribution

Damage to the Common peroneal Nerve

The common peroneal nerve is most commonly damaged by a neck of fibula fracture or the tight application of plaster cast.

Patients with common peroneal nerve damage will lose the ankle dorsiflexion. Hence the foot will appear permanently plantar flexed – known as foot drop. They may also present with a characteristic gait, as a result of the foot drop.

There will also be a loss of sensation over the dorsal aspect of the foot, and lateral suspect of the leg. Innervation is preserved on the medial side of the leg (supplied by the saphenous nerve, a branch of the femoral), and the heel and sole (supplied by the tibial nerve, a branch of the sciatic).

Materials and Methods

In October 2019, we observed isolated weakness of extensor hallucis longus in a patient during immediate post operative period who operated for medial compartmental osteoarthritis of knee with proximal fibular osteotomy, after the removal of 1.5 cm of fibula at the level of 6cm from the tip of fibular head.

This lead us to carry out a prospective study in 15 patients from October 2019 to October 2021in whome PFO were undertaken. Among 15 patients, three patients developed isolated weakness of extensor hallucis longus. A thorough clinical examination was carried out before surgery. No patient had any motor or Sensory impairment before the procedure.

The neurological examination was taken out in all patient during immediate postop period. The strength of each group muscle was graded clinically. All patient evaluated by EMG and NCS postoperatively.

Surgical techniques

The length of fibula to be removed is around 1.5 to 2cm, 6 to 9 cm from the head of fibula, the aim is to convert the knee joint as more balanced, by cutting fibular cortices, then unicortical support only on both sides of knee. That leads to correction of mechanical axis.

The resection should be high enough to cause a mechanical axis correction, but not high to lead lateral popliteal nerve damage.

The size of segment of fibula to be removed from the fibular head depends on the height of the patient and length of fibula, for shorter patients -1.5 cm resected below 6 cm, for taller patients -2cm resected below 8 to 9 cm.

The fibula length is measured from tip of fibular head to tip of lateral malleolus, resected segment should below 24% of length from head of fibula.

Fig 4: Optimal site for proximal fibular osteotomy

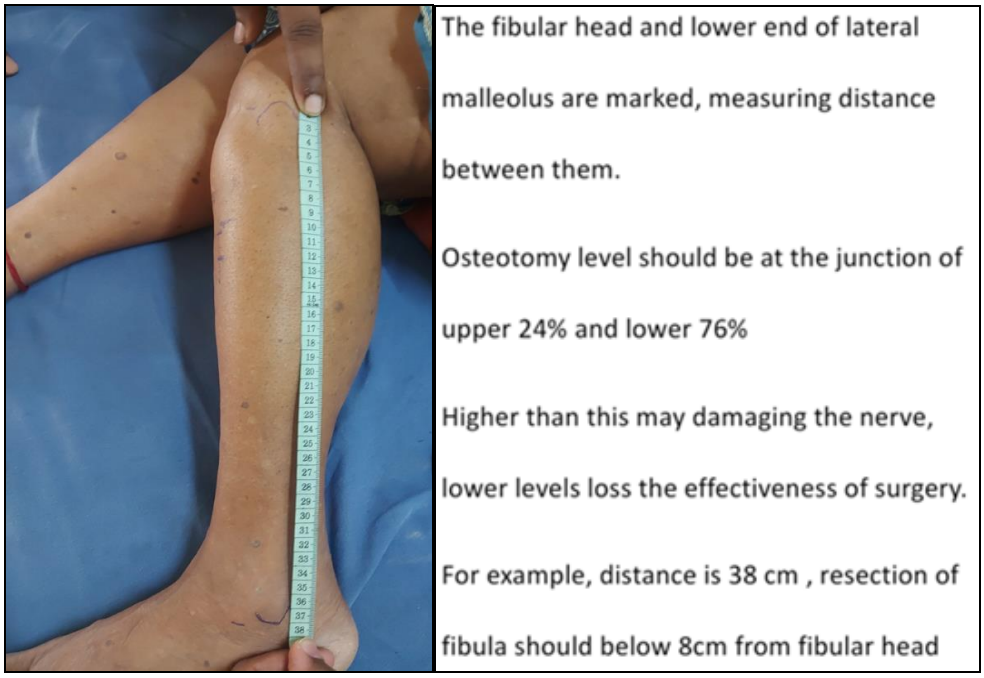

Fig 5: Pre-op Measurement of Fibular Length

All patients were operated under spinal anaesthesia, with a tourniquet control. Crystalloids in the form of normal Slaine (NS) and dextrose normal saline (DNS) were used as maintenance fluid.

Fig 6: Operated under spinal anaesthsia

Fig 7: Armamentarium

Positioning the Patient: patient in supine position, knee in 45 degrees of flexion, knee joint is free for flexion and extension.

Fig 8: Positioning the Patient

The fibular head tip is marked with a skin marker, and the appropriate downward distance measured.

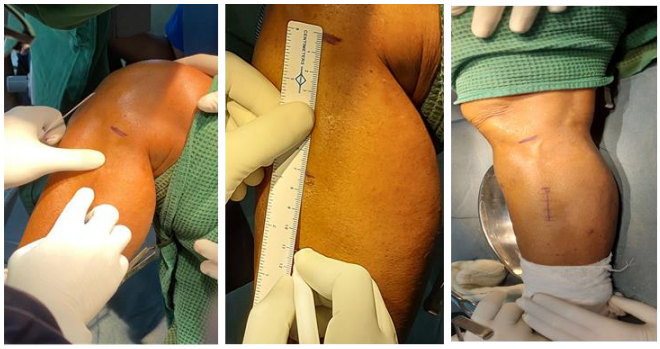

Fig 9: Intra op measurement of osteotomy level

A 4-8 cm lateral incision was made overlying the chosen site of osteotomy and dissection was carried out through the skin and subcutaneous tissues.

Fig 10: Skin incision

Through the plane between peroneus and soleus, fibular periosteum is reached which is incised about 1.5 to 2 cm at pre planned osteotomy site, periosteum elevated with periosteal elevator.

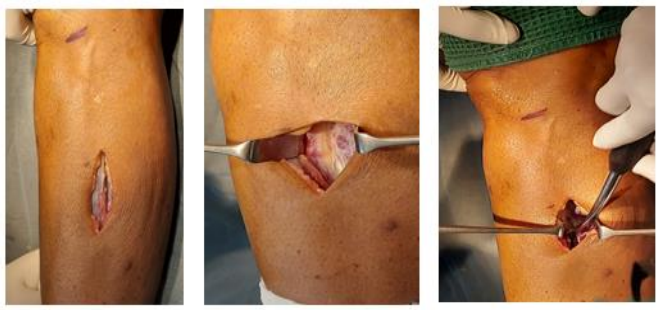

Fig 11: Fibular periosteum reached and elevated

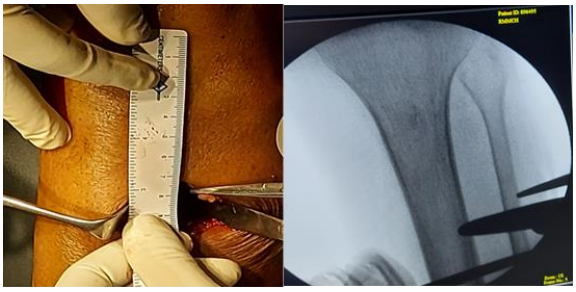

Fig 12: Length of resected segment measured and confirmed with c arm

A 1.5 to 2 cm of fibula was then resected with the help of an osscillating saw after placing a few drill holes and care must be taken not to overstretch the soft tissues too much to protect the nerve from damage.

Fig 13: Fibula resected with oscillating saw

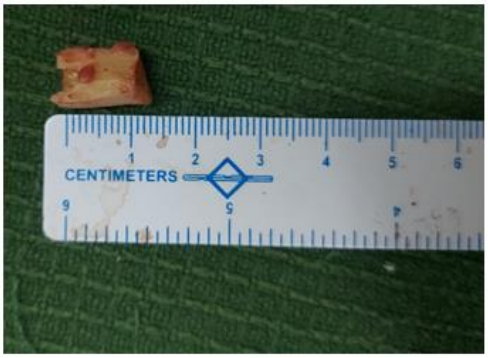

Fig 14: Resected segment of fibula

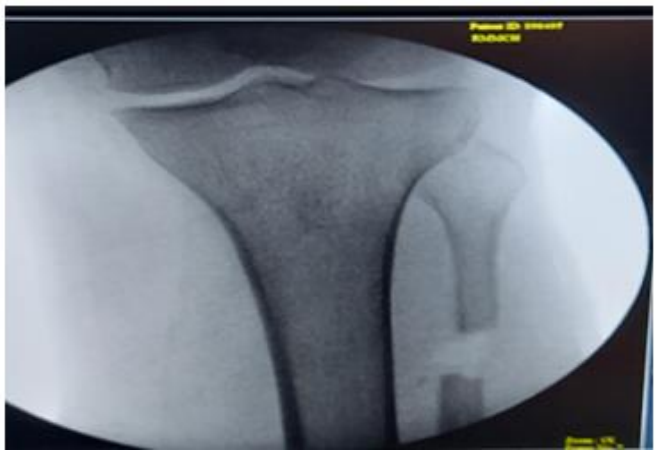

Fig 15: Intra op C arm Image

After attaining perfect hemostasis, thorough wound wash given and wound closed in layers and sterile dressing and compression bandage applied.

Fig 16: Skin close in layers

Postoperatively all patients are mobilised to stand and encourage to walk on the same day of surgery as soon as the patient recovered from anaesthesia, and were discharged on the second postop day after wound inspection. Antibiotics given intravenously for two days and then five days orally.

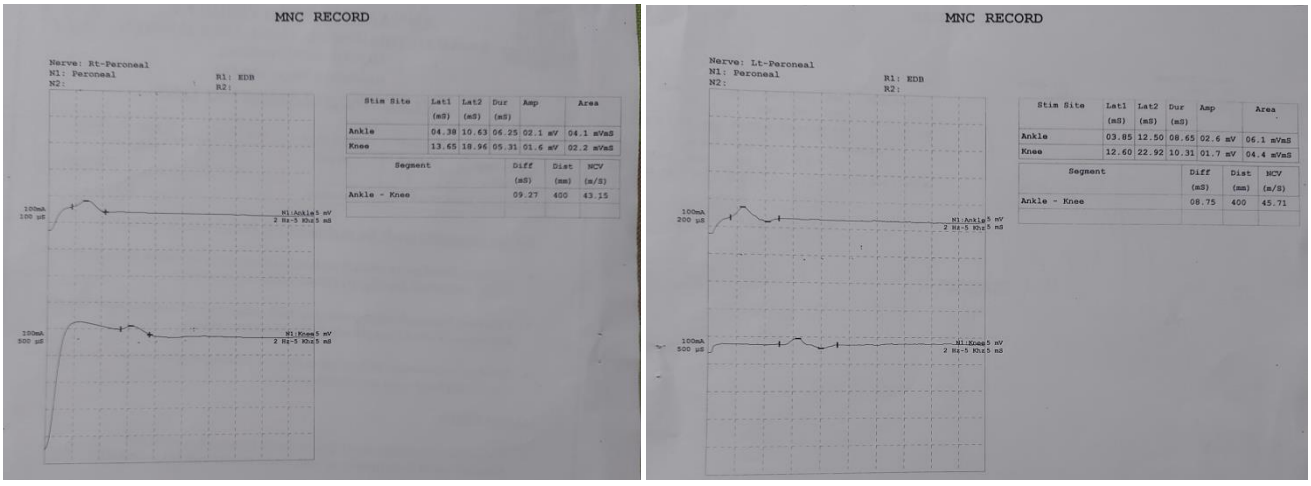

Fig 17: Post op nerve conduction study done to found neuropraxia

Results

15 patients (9 Males and 6 Females) with medial compartment arthritis of the knee who presented between October 2019 to October 2021 were managed with PFO. The mean duration of follow up 10 months. Mean operating time and Mean tourniquet time 15 minutes and 20 minutes

respectively. Mean tourniquet pressure 280 mm HG.

Males are more commonly seen affected in our study, with right knee more commonly affected than left. The age of the patients, ranged from 42 to 70 years with the mean age being 55.33 years.

Postoperatively 3 patients developed great toe drop, however, 2 patients recovered fully within 4-5 weeks, 1 patient have EHL weakness upto 8 months. There were no complications such as superficial or deep infection or common peroneal nerve palsy or loss of sensation over dorsum of foot encountered in our study. None of our patients were lost to follow up.

In all cases a 1.5 to 2 cm section of fibula was resected 7 to 9 cm below the fibular head. A total of 15patients knees with a follow up of more than 8 months were included in the study. In the AP and lateral standing X-rays, the Tibio femoral angle and the medial and lateral joint space were measured pre operatively and post operatively. In addition, the patients were evaluated on the basis of pre-operative and post-operative Visual Analog Score [5, 6], and knee scoring by the modified Oxford knee score [6].

Table 1: Evaluation of pre op and post op results

S. No	Component	Mean ± SD		p Value
		Pre - op	Post - op	
1	Visual analog scale score	7.7 ± 1.1	4.4 ± 1.3	<0.001
2	Modified Oxford Knees score	54.2 ± 6.7	69.4 ± 7.1	
3	Lateral Tibio Femoral angle in degress	187.7 ± 1.6	184.5 ± 1.8	
4	Medial Joint Space in mm	2.5 ± 1.2	4.5 ± 0.9	
5	Lateral Joint Space in mm	6.2 ± 0.9	4.7 ± 0.7	
6	Range of Motion in degress	134.5 ± 9.2	137 ± 8.6	

Complications encountered in patients

Table 2. Complications

Complications	Frequencies (n)	Percentage (%)
No complication	12	80
Neuropraxia	3	20
Wound infection	0	0
Vascular injury	0	0
Joint infection	0	0

In three patients with EHL weakness in immediate postop period power was graded from 0 to 3. All three patients were male and fibula resected at 6 cm from the tip of head of fibula. In other 12 patients EMG and NCS are normal [11]. In these patients with EHL weakness, EHL had been observed with nerve conduction in this branch to muscle was reduced ranging from 20.1 to 26 m/s, EMG studies show denervation fibrillation pattern. NCS and EMG became normal with increase of nerve conduction study in two patient at 6 weeks. One patient shows clinical sign of recovery and normal EMG and NCS after 8 months of surgery.

Discussion

Extensor digitorum longus, peroneus longus and extensor hallucis longus are attached to the upper and middle thirds of the anterior aspect of the fibula while peroneus brevis and tertius are attached to its lower part. Soleus and flexor hallucis longus are attached to the proximal and middle parts posteriorly [10]. Although the fibula is a good source of autograft, it is necessary to determine whether its partial removal results in dysfunction [4, 8, 9, 12-15]. Gore *et al* 3 observed weakness in the dorsiflexors and in the peroneus muscles after fibulectomy. They attributed this to the loss of their bony attachment. We also found isolated weakness of extensor hallucis longus after harvesting the fibula, but the other muscles which were attached to the same portion of the bone showed no loss of power. If this weakness was due to loss of the bony attachment, associated weakness of the other attached muscles would be expected. Out of 15 patients surgically managed with PFO in our study, only three patients developed transient EHL weakness and one patient developed transient numbness over lateral aspect of foot. Among those three patient two patient recovered from neuropraxia within 6 weeks and one patient recovered after 8 months .transient numbness over lateral aspect of foot in a patient recovered within 3 weeks. Commonly fibula resected with in or at the level of 6cm below the fibular head develops EHL weakness. Postoperative EMG and NCS also done to confirm neuropraxia. later on fibula resected 24% length of total fibula below the fibular head ,not encountered the immediate postop EHL weakness.

We were extremely careful in harvesting the fibula but encountered weakness of extensor hallucis longus in these patients. EMG and nerve-conduction studies showed damage to the nerve supply of this muscle. Nerve conduction velocity reduced ranging from 20.1 to 26 m/S Similar studies were carried out by Kirgis VOL. 86-B, No. 3, APRIL 2004 and Albrecht [15] although they described three variants. If the nerve passes close to the tibia it will not be damaged when the fibula is removed but if it is adjacent to the fibula, it may be compromise.

Conclusion

The optimal site for fibular osteotomy for PFO in medial compartmental osteoarthritis of knee is at the junction of 24% of fibular length above and 76%below the osteotomy location. Provides good pain relief and functional recovery without transient EHL weakness and other complications. EHL weakness occurs mostly due to traction neuropraxia to the nerve which supplying the EHL muscle, more likely to occur in very high osteotomy less than 6cm from tip of fibular head.

References

1. Ahlback S. Osteoarthrosis of the knee: a radiographic investigation. Acta Radiol. 1968;277(l):7-72.
2. Zhang Y, Li C, Li J, *et al*. The pathogenesis research of non-uniform settlement of the tibial plateau in knee degeneration and varus. J Hebei Med Univ. 2014;35(2):218-219.
3. Crenshaw AH JR. Surgical techniques and approaches. In: Canale ST, ed. Campbell's operative orthopaedics. Ninth ed. St Louis: Mosby 1998;1:42-3.
4. Wax MK, Winslow CP, Hansen J, *et al*. A retrospective analysis of temporomandibular joint reconstruction with free fibula microvascular flap. Laryngoscope 2000; 110:977-81.

5. Huskisson E. “Measurement of pain”. Lancet 304.7889 1974, 1127-1131.
6. Prakash L. “Knee Scoring and Outcome Prediction in developing a surgical paradigm of total knee replacement”. Indian Academy of Orthopaedic Surgeons, Instructional course lectures. 2016.
7. Gore DR, Gardner GM, Sepic SB, Mollinger LA, Murray AP. Function following partial fibulectomy. Clin Orthop 1987;220:206-10.
8. Lee EH, Goh JCH, Helm R, Pho RWH. Donor site morbidity following resection of the fibula. J Bone Joint Surg [Br]. 1990;72-B:129-31.
9. Goodacre TEE, Walker CJ, Jawad AS, Jackson AM, Brough MD. Donor site morbidity following osteocutaneous free fibula transfer. B J Plast Surg 1990;43:410-2.
10. Romanes GJ. Cunningham’s manual of practical anatomy. 15th ed. Oxford: ELBS. 1989;1:182-8.
11. Turek SL. Orthopaedic neurology. In: Orthopaedics, principle and their application. Fourth ed. Philadelphia, etc: Lippincott – Raven Publishers. 1998;1:474-9.
12. Pho RWH, Levack B, Satku K, Patradul A. Free vascularised fibular graft in the treatment of congenital pseudoarthrosis of the tibia. J Bone Joint Surg [Br] 1985;67-B:64-70.
13. Lambert KL. The weight bearing function of the fibular: a strain gauge study. J Bone Joint Surg [Am] 1971;53-A:507-13.
14. Anthony JP, Rawnsley JD, Benhaim P, *et al*. Donor leg morbidity and function after fibula free lap mandible reconstruction. Plast Reconstr Surg. 1995;96:146-52.
15. Kirgis A, Albrecht S. Palsy of the deep peroneal nerve after proximal tibial osteotomy: an anatomical study. J Bone Joint Surg [Am]. 1992;74-A:1180-5.