



International Journal of Orthopaedics Sciences

E-ISSN: 2395-1958
P-ISSN: 2706-6630
IJOS 2022; 8(1): 79-83
© 2022 IJOS
www.orthopaper.com
Received: 02-10-2021
Accepted: 09-12-2021

A Senthilnathan
Professor, Department of
Orthopaedics, Rajah Muthiah
Medical College, Chidambaram,
Tamil Nadu, India

R Prabhakar
Senior Resident, Department of
Orthopaedics, Rajah Muthiah
Medical College, Chidambaram,
Tamil Nadu, India

K Vijaya Shankar
Assistant Professor, Department
of Orthopaedics, Rajah Muthiah
Medical College, Chidambaram,
Tamil Nadu, India

P Krishna Balaji
Post Graduate, Department of
Orthopaedics, Rajah Muthiah
Medical College, Chidambaram,
Tamil Nadu, India

Corresponding Author:
K Vijaya Shankar
Assistant Professor, Department
of Orthopaedics, Rajah Muthiah
Medical College, Chidambaram,
Tamil Nadu, India

A comparative study to analyse the efficacy of platelet rich plasma versus corticosteroids in the treatment of chronic plantar fasciitis

A Senthilnathan, R Prabhakar, K Vijaya Shankar and P Krishna Balaji

DOI: <https://doi.org/10.22271/ortho.2022.v8.i1b.2991>

Abstract

Introduction: Chronic plantar fasciitis accounts for 15% of all foot disorders with 10% of the population affected over their life time. PRP is a biological blood derived autologous component rich in numerous growth factors and cytokines which is being widely used in various musculoskeletal disorders in recent times. In this study we compare the efficacy of PRP with steroid injection in the treatment of chronic plantar fasciitis.

Materials and Methods: 50 patients with unilateral chronic plantar fasciitis who were not responding to conservative management for 6 weeks were included in this study. The study was done at orthopaedics department at Rajah Muthiah Medical College and Hospital, Annamalai University from October 2020 to October 2021. Patients were randomly allocated into two groups. Group A [25 patients] received 2 cc of single dose platelet rich plasma [PRP] injection and group B [25 patients] were given 40 mg of 2cc depomedrol injection. Functional outcome was evaluated using visual analog score [VAS] and Foot and ankle ability measure [FAAM] scores at 0,4,8,12,24 weeks. Plantar fascia thickness was measured pre-injection and 6 months post injection using ultrasound.

Results: Group A [PRP] had pre- treatment VAS score of 8.5 and FAAM score of 30.08 after 6 months follow up the score was 1.60 and 82.86 respectively. Where as in group B [STEROID] had pretreatment VAS score of 8.3 and FAAM score of 29.96, 6 months follow up score of 3.85 and 70.18 respectively. Pre-treatment Plantar fascia thickness in group A was and group B was 5.95 and 5.76 respectively. 6 months follow up study shows thickness of 3.76 and 4.33 in group A and B.

Conclusion: Platelet rich plasma was found to be more effective in relieving the symptoms, increases the functional outcome compared to steroids in long term follow up.

Keywords: Platelet rich plasma, Visual analog score, FAAM score

Introduction

Plantar fasciitis is one of the most common foot condition encountered by an orthopaedic surgeon. It accounts for 15% of all foot disorders with almost 10% of the population affected over their life time. Although the etiology is not clearly understood there are evidences to suggest that it is probably initiated by repeated micro trauma. There may be structural disorders such as pes planus, pes cavus, over pronation, leg length discrepancy, excessive tibial torsion. Tightness of gastro soleus complex is also considered to be a contributing factor. The cause of pain may be multi factorial^[2,3]. Theories include inflammation of an overlying bursa, traumatic periostitis, tearing of the fibers of the attachment of the fascia and focal sepsis causing localized inflammation.

Patients have complaints of sharp pain, insidious in onset with maximal tenderness along the anteromedial aspect of calcaneum. Pain is more severe in morning after first step from bed and after prolonged sitting or inactivity.

Treatment options include Rest, NSAIDS, stretching protocols, foot orthotics, physiotherapy, ESWT, Cortico-steroid, autologous blood, PRP injection has also been included in recent times. Surgical management has been reserved for recalcitrant cases of plantar fasciitis.

Platelet rich plasma was developed in early 1970s and has been used for cartilage regeneration, chronic enthesopathies like plantar fasciitis, tennis elbow and in the field of sports medicine. It is an autologous blood derived biological product that has numerous cytokines and growth

factors like PDGF, TGF beta, EGF, VEGF, IGF, FGF and CTGF present on the alpha granules. These growth factors has mitogenic potential for both mesenchymal and osteoblast cells and regulate collagen synthesis, neo vascularization and angiogenesis.

Materials and Methods

The study was conducted at department of orthopaedics, Rajah Muthiah Medical College and Hospital, Annamalai University, Chidambaram from 2020-2021. 50 patients with unilateral chronic plantar fasciitis who were not responding to conservative management for 6 weeks were included in this

study. Ethical committee clearance was obtained. Informed written consent is obtained from all patients who were willing for the treatment and follow up. Patients were diagnosed chronic plantar fasciitis based on their history, radiological evaluation and ultrasonic evaluation of PF thickness and randomly allocated into two groups.

Group A [25 patients] received 2 cc of single dose platelet rich plasma [PRP] injection and group B [25 patients] were given 40 mg of 2cc depomedrol injection.

PRP Preparation



Fig 1: PRP preparation

Under strict aseptic precautions, [fig 1] 10 ml of patients own venous blood was withdrawn from cubital vein and was collected in pre sterilized centrifuge vials [17]. The centrifuge vials was loaded with anticoagulant acid citrate dextrose. The blood was then centrifuged in a cooling centrifuge [REMI] at a rate of 3200 rpm for 20 minutes. The blood is then separated in platelet poor plasma and platelet rich plasma. The platelet poor plasma is discarded and the PRP is collected in a syringe [26].

Ultrasonic Evaluation of Plantar Fascia Thickness

A diagnostic ultrasound machine with a 4 cm wide transducer head and 8 MHz probe was used [22]. The thickness of the plantar fascia was measured at the thickest portion from the base of the medial calcaneal tubercle where a bright echogenic line was easily visible. Plantar fascia thickness of more than 4mm was considered abnormal [1].

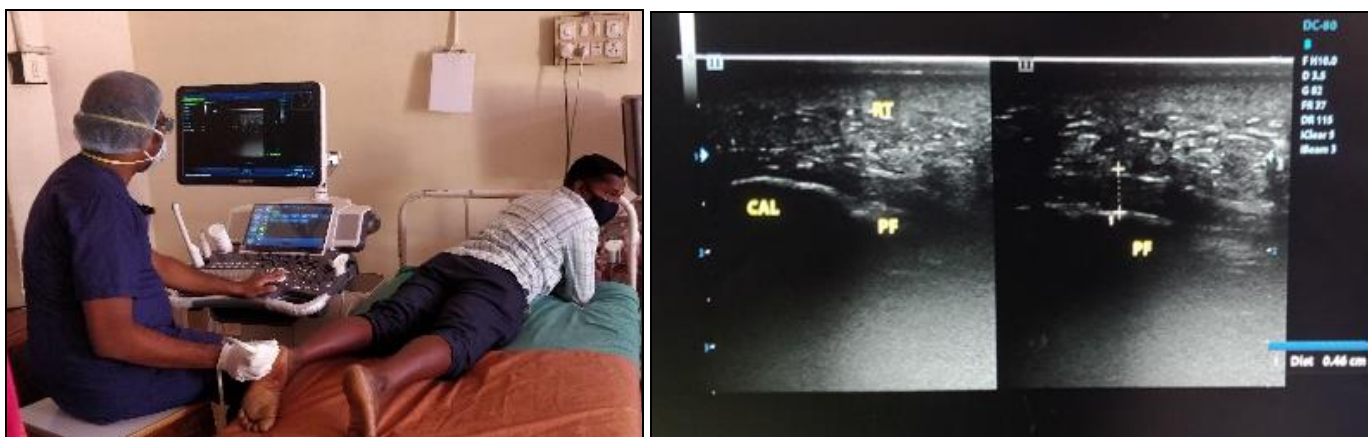

Fig 2: Ultrasonic Evaluation of Plantar Fascia Thickness

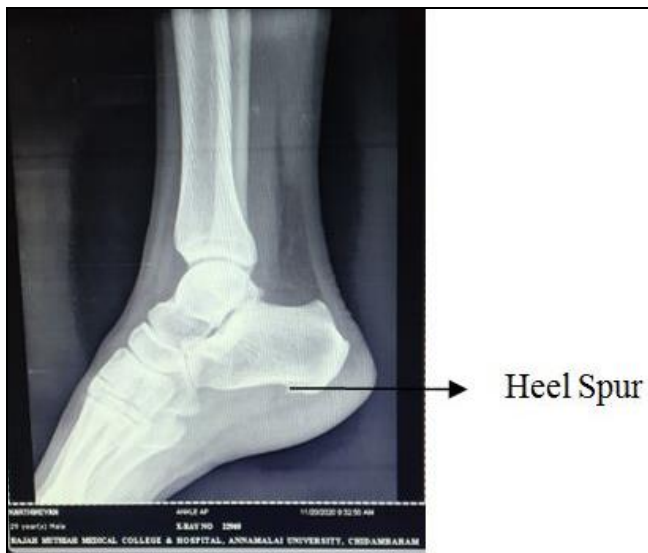

Fig 3: Heel Spur

Injection Protocol

PRP Injection

The procedure was done in a OPD basis under strict aseptic precautions [16, 18]. Patient lying in supine position the site of maximal tenderness over the medial calcaneal tubercle is identified. [fig 4] 2cc of 2 ml lidocaine is injected into the skin before PRP application. A ‘peppering’¹⁹ technique i.e., spreading in clockwise manner was used to achieve a more expansile zone of delivery over the plantar fascia [a single portal and 4 to5 passes through the fascia itself]

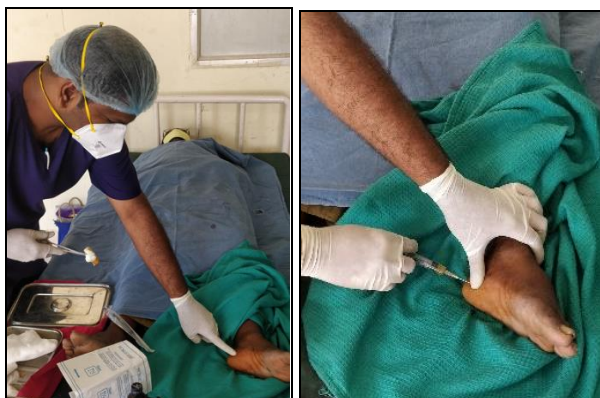

Fig 4: PRP injection technique

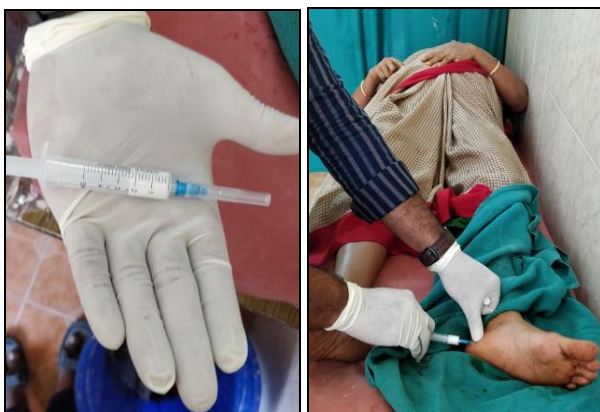

Fig 5: Corticosteroid Injection Application

Corticosteroid Injection:

2 ml of 40 mg depomedrol [fig 5] [methyl prednisolone] along with 2cc lidocaine is injected [12, 13].

Post Injection Protocol

The patients were monitored for 60 minutes after injection for any adverse reactions. Advised to limit their use of the feet and use of NSAIDS for 48 hrs. After 48 hrs, patients were given foot stretching protocols to follow for 3 weeks. At 4 weeks, patients were allowed to proceed with sporting or recreational activities. Any type of foot orthoses was not advised [11].

Assessment of Outcome

Patient outcome was assessed using VAS score based on pain scale and FAAM [FOOT AND ANKLE ABILITY MEASURE] for assessment of pain and functional outcome.

Results

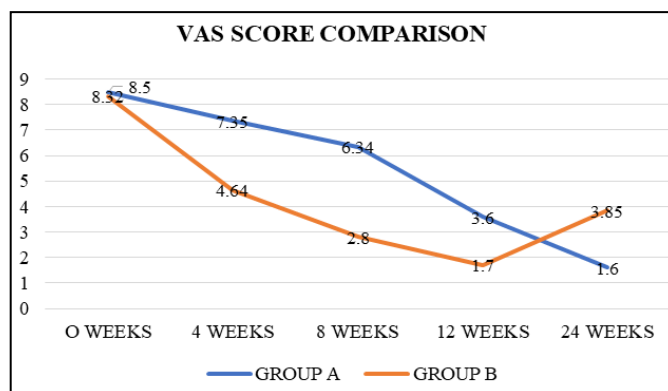
50 patients were included in the study, 25 patients in group A [PRP] and 25 patients in group B [steroid]. The mean patient age was 40 years. 30 female and 20 male patients with a total of 50 patients were studied.

VAS score

The base line VAS score was 8.5 in PRP group and 8.3 in steroid group. 12 weeks follow up VAS score was 3.6 and 1.7. After 24 weeks the final score in PRP group was 1.6 and 3.85 in steroid group [graph 1 and table 1] [24].

Table 1: VAS Score

Group Statistics	Groups	N value	Mean	Standard Error Mean	P value
VAS 0 weeks	A	25	8.50	0.361	<0.001
	B	25	8.30	0.074	<0.001
4 weeks	A	25	7.35	0.221	<0.001
	B	25	4.64	0.168	<0.001
8 weeks	A	25	6.34	0.157	<0.001
	B	25	2.80	0.221	<0.001
12 weeks	A	25	3.60	0.146	<0.001
	B	25	1.70	0.056	<0.001
24 weeks	A	25	1.60	0.012	<0.001
	B	25	3.85	0.142	<0.001



Graph 1: VAS Score

FAAM Score

The baseline FAAM score was 30.08 in PRP group and 29.96 in steroid group. 12 weeks follow up score was 70.96 and 82.07. After 24 weeks the final score in PRP group was 82.86 and 70.18 in steroid group [graph 2 and table 2]

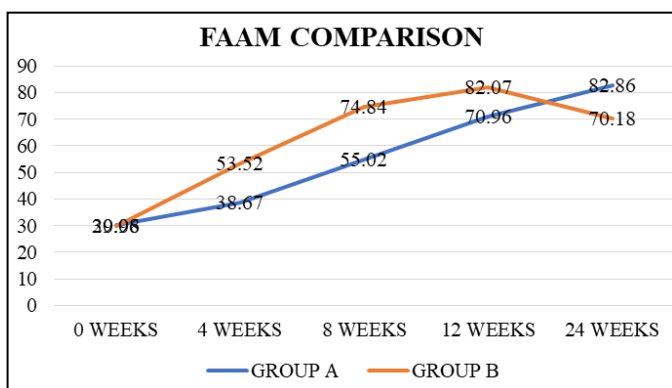
Ultrasonic Evaluation of Plantar Fascia Thickness

In PRP group, the mean plantar fascia thickness before injection was 5.98 mm. After 24 weeks the mean thickness was 3.5mm. In steroid group patients, the pre -treatment thickness was found to be 5.76 mm and 4.56 mm after 6

months follow up. There was a reduction in plantar fascia thickness in all patients [21, 22, 23].

Table 2: FAAM Score

Group statistics	Groups	N value	Mean	Standard Error Mean	P value
FAAM 0 Weeks	A	25	30.08	1.086	<0.001
	B	25	29.96	0.763	<0.001
4 Weeks	A	25	38.67	1.136	<0.001
	B	25	53.52	0.764	<0.001
8 Weeks	A	25	55.02	1.264	<0.001
	B	25	74.84	0.745	<0.001
12 Weeks	A	25	70.96	1.221	<0.001
	B	25	82.07	0.786	<0.001
24 Weeks	A	25	82.86	1.252	<0.001
	B	25	70.18	0.658	<0.001



Graph 2: FAAM Score

Discussion

Plantar fasciitis is the most common cause for heel pain and it is difficult to treat. In recent times, PRP has gained popularity in the treatment of various musculoskeletal disorders and in the field of sports medicine [2, 3, 4]. PRP has numerous growth factors and cytokines that is released from the alpha granules of the platelets which is responsible for the healing response in the plantar fascia injury zone [5, 6, 7]. It also releases fibroblasts and macrophages that heals the damaged collagen fibers. The release of enzymes from the cytokines and inhibition of COX-2 [cyclo-oxygenase-2] initiates early anti-inflammatory response after PRP injection.

Mark W. Scio, Joost, C Peerboms *et al.* [19] did studies on ‘peppering’ technique for the application of PRP injection which was found to be effective, so we followed the same method.

Both ultrasound and MRI helps in measuring the thickness of plantar fascia. In our study we used ultrasonic evaluation because it is non-invasive, no radiation exposure and cost-effective and well tolerated by the patient s, in comparison with MRI.

Matthew V. Smith, Sandra Klein *et al.* [20]. Studied FAAM score as the effective tool to analyze the functional outcome of the patient. It is sensitive to overall health status and comorbidities.

Aksahin *et al.* [25] did a comparative study on corticosteroid vs PRP injection for treatment of plantar fasciitis. 60 patients divided into 2 groups were included in this study and declared no significant difference between both groups after 3 weeks and 6 months follow up [8, 9, 10].

Raymond Rocco Monto *et al.* did studies on 40 patients who were randomly given ultrasound guided PRP and steroid injection. They used AOFAS score for evaluation. There was an initial improvement in steroid group that declined after 6

months whereas in PRP group the effect remained for 24 months [14, 15]. The limitation of this study is AOFAS score as there was no restriction of movements in plantar fasciitis pathology. VAS and FAAM score will be better scoring tool for overall functional outcome and patient satisfaction.

In a study done by Mukesh *et al.*, the mean VAS Score in steroid group patients was found to be 8.5, after 12 weeks for treatment the score improved to 1.1. At 26 weeks follow up the score was 4.9. In PRP group, the initial score was 8.6, after 12 weeks follow up the score improved to 3.4. At 26 weeks, there was a drastic improvement in pain and the VAS score was found to be 1.2

In our study, the steroid group patients had good pain relief and significant VAS score and FAAM score after 12 weeks of treatment. After 26 weeks follow up, there was a decline in pain relief and patient satisfaction. In PRP group, the long term up follow up was found to be satisfactory with significant improvement in VAS and FAAM score.

Out of the 50 patients, 4 patients in steroid and 1 patient in PRP group showed no improvement even after 24 weeks of follow up. Those patients were managed with physiotherapy and analgesics. No complications were observed in both groups.

Both PRP and steroids are effective in the treatment of chronic plantar fasciitis but from our study we observed PRP is found be durable, cost effective and safer than steroids because of its tissue regeneration properties, collagen up regulation and neo-vascularization of the injured plantar fascia that gives long term effects.

Conclusion

Chronic plantar fasciitis is a difficult condition to treat. Both PRP and steroids are good choice in treatment of this condition. Steroids provide immediate relief in pain symptoms only. Platelet rich plasma was found to be more effective in relieving the symptoms, increases the functional outcome compared to steroids in long term follow up

References

- Sorrentino F, Iovane A, Vetro A, Vaccari A, Midiri M. Role of high-resolution ultrasound in guiding treatment of idiopathic plantar fasciitis with minimally invasive techniques. *Radiol Med.* 2008 Jan; 113(4):486-495.
- Buchbinder R. Clinical practice. Plantar Fasciitis. *New Engl J Med.* 2004 May; 350(21):2159-2166.
- Singh D, Angel J, Bentley G, Trevino S. Fortnightly review: Plantar fasciitis. *BMJ* 1997 Jul 19; 315(7101):172-175.
- Lemont H, Ammirati KM, Usen N. Plantar fasciitis: a degenerative process (fasciosis) without inflammation. *J Am Podiatr Med Assoc.* 2003 May-Jun; 93(3):234-237.
- Snider MP, Clancy WG, McBeath AA. Plantar fascia release for chronic plantar fasciitis in runners. *Am J Sports Med.* 1983 Jul-Aug; 11:215-219.
- Tountas AA, Fornasier VL. Operative treatment of subcalcaneal pain. *Clin Orthop Relat Res.* 1996 Nov; (332):170-178.
- Jarde O, Diebold P, Havet E, Boulu G, Vernois J. Degenerative lesions of the Plantarfascia: surgical treatment by fasciectomy and excision of the heel spur. A report on 38 cases. *Acta Orthop Belg.* 2003 Jun; 69(3):276-274.
- American College of Foot and Ankle Surgeons. The diagnosis and treatment of heel pain. *J Foot Ankle Surg.* 2001 Sep-Oct; 40(5):329-340.

9. Donley BG, Moore T, Sferra J, Gozdanovic J, Smith R. The efficacy of oral non-steroidal anti-inflammatory medication (NSAID) in the treatment of plantar fasciitis: a randomized, prospective, placebo-controlled study. *Foot Ankle Int.* 2007 Jan; 28(1):20-23.
10. Landorf KB, Keenan AM, Herbert RD. Effectiveness of foot Orthoses to treat plantar fasciitis: a randomized trial. *Arch Intern Med.* 2006 Jun; 166(12):1305-1310.
11. DiGiovanni BF, Nawoczenski DA, Lintal ME, Moore EA, Murray JC, Wilding GE, *et al.* Tissue-specific plantar fascia-stretching exercise enhances outcomes in patients with chronic heel pain. A prospective, randomized study. *J Bone Joint Surg.* 2003 Jul; 85A(7): 1270-1277.
12. Haake M, Buch M, Schoellner C, Goebel F, Vogel M, Mueller I, Hausdorf J, *et al.* Extracorporeal shock wave therapy for plantar fasciitis: randomised controlled multicentre trial. *BMJ.* 2003 Jul 12; 327(7406):75.
13. Acevedo JI, Beskin JL. Complications of plantar fascia rupture associated with corticosteroid injection. *Foot Ankle Int.* 1998 Feb; 19(2):91-97.
14. Woelffer KE, Figura MA, Sandberg NS, Snyder NS. Five-year follow-up results of instep plantar fasciotomy for chronic heel pain. *J Foot Ankle Surg.* 2000 Jul-Aug; 39(4):218-223.
15. Conflitti JM, Tanquinio TA. Operative outcome of partial plantar fasciectomy and neurolysis to the nerve of the abductor digit minimi muscle for recalcitrant plantar fasciitis. *Foot Ankle Int.* 2004 Jul; 25(7):482-487.
16. Edwards S, Calandruccio J: Autologous blood injections for refractory lateral epicondylitis. *J Hand Surg Am.* 2003 Mar; 28(2):272-278.
17. Augustus D, Mazzocca AD, McCarthy MBR, Chowanec DM, Cote MP, Romeo AA, *et al.* Platelet-rich plasma differs according to preparation method and human variability. *The Journal of Bone & Joint Surgery.* 2012;94(4):308-316.
18. Scioli MW. Platelet-rich plasma injection for proximal plantar fasciitis. *Techniques in Foot & Ankle Surgery.* 2011;10(1):7-10.
19. Peerbooms, *et al.* *BMC Musculoskeletal Disorders.* 2010;11:69.
20. Smith, Matthew V, Klein Sandra E, Clohisy John C, Baca Geneva R, Brophy Robert H. Lower extremity specific measures of disability and outcomes in orthopaedic surgery. *The Journal of Bone and Joint Surgery.* 2012;94(5)468-477.
21. McMillan AM, Landorf KB, Barrett JT, Menz HB, Bird AR. Diagnostic imaging for chronic plantar heel pain: A systematic review and meta-analysis. *J Foot Ankle Res.* 2009;2:32.
22. Cheng JW, Tsai WC, Yu TY, Huang KY. Reproducibility of sonographic measurement of thickness and echogenicity of the plantar fascia. *J Clin Ultrasound.* 2012;40:14-19
23. Fabrikant JM, Soon Park T. Plantar fasciitis (fasciosis) treatment outcome study: plantar fascia thickness measured by ultrasound and correlated with patient selfreported improvement. *The Foot.* 2011;21:79-83
24. Gould D *et al.* Visual Analogue Scale (VAS). *Journal of Clinical Nursing.* 2001;10:697-706
25. Aksahin E, Dogruyol D, Yuksel HY, *et al.* The comparison of the effect of corticosteroids and platelet-rich plasma (PRP) for the treatment of plantar fasciitis. *Arch Orthop Trauma Surg.* 2012;132:781-785.
26. Tiwari M, Bhargava R. Platelet rich plasma therapy: A comparative effective therapy with promising results in plantar fasciitis. *Journal of Clinical Orthopaedics and Trauma.* 2013;4(1):31-3.