



E-ISSN: 2395-1958  
P-ISSN: 2706-6630  
IJOS 2022; 8(1): 127-134  
© 2022 IJOS  
[www.orthopaper.com](http://www.orthopaper.com)  
Received: 22-11-2021  
Accepted: 25-12-2021

**Dr. Lavakumar S Loya**  
Professor, Department of  
Orthopaedics, Mahadevappa  
Rampure Medical College,  
Kalaburgi, Karnataka, India

**Dr. Raj Vardhan Kollur**  
Junior Resident, Department of  
Orthopaedics, Mahadevappa  
Rampure Medical College,  
Kalaburgi, Karnataka, India

## A prospective study of management of inter-trochanteric fractures of femur by modified intramedullary implant

**Dr. Lavakumar S Loya and Dr. Raj Vardhan Kollur**

**DOI:** <https://doi.org/10.22271/ortho.2022.v8.i1b.2999>

### Abstract

**Background:** The best surgical strategy for extra-capsular proximal femoral fractures (PFFs) is controversial in the elderly. Poor bone quality and neck screw instability can adversely affect the results with currently available fixation devices, which predominantly consist in dynamic hip screw-plates and proximal reconstruction nails.

**Hypothesis:** The lag screw of the modified intramedullary implant achieves better cancellous bone compaction in the femoral neck, thereby decreasing the risk of secondary displacement.

**Materials and Methods:** We studied consecutive cases of modified intramedullary implant fixation performed between 2019 and 2021 in 20 patients (8 females and 12 males) with a mean age of  $71.3 \pm 9.02$  years. All patients were operated under hypotensive spinal-epidural anaesthesia in supine position on traction table. Patients were evaluated at pre op and post op follow up period with serial radiography and clinically by Harris Hip score (HHP) for pain and disability scoring.

**Results:** Mean follow-up in the 20 patients was  $12.3 \pm 7.5$  months (4–20 months). Fracture union was consistently achieved, after a mean of  $12.25 \pm 1.67$  weeks. After the last follow-up, the mean Harris hip score was  $86.8 \pm 7.3$  (range, 65–100); the score was excellent in 11 patients (55%), good in 5 (25%), fair in 2 (10%), and poor in 1 (5%).

**Conclusion:** Modified intramedullary implant has the advantages of a simple operation, few complications, and clinical efficacy for the treatment of intertrochanteric fractures. However, evaluation of its long-term efficacy and risk of other complications requires a large-sample, multicenter observational study.

**Keywords:** Intertrochanteric hip fracture, modified intramedullary implant, extra-capsular fracture, lag screw

### Introduction

The incidence of intertrochanteric fractures is increasing with the aging of society. Treatment of intertrochanteric fractures in elderly patients is a huge challenge for many trauma surgeons, mainly because many such patients have severe osteoporosis and medical disorders that increase the risks associated with surgery and anaesthesia. Therefore, choosing the optimal fixation method and instrumentation is essential for a positive therapeutic effect<sup>[1,2]</sup>.

More than 50% of intertrochanteric fractures are unstable. Unstable intertrochanteric fractures are those with major disruption of posteromedial cortex because of comminution or are fractures with reverse oblique patterns or fractures with subtrochanteric extension. Fractures without posteromedial cortex disruption or subtrochanteric extension are considered Stable.

Intertrochanteric fractures initially were treated conservatively by means of external splintage, skin traction, skeletal traction and Russell traction<sup>[3]</sup>. The anatomical and functional result could not be achieved. The radical concept of operative management of intertrochanteric fractures has evolved with newer strong and inert metal implants, improved devices and techniques for fixation.

The treatment of intertrochanteric hip fractures and especially unstable Intertrochanteric fractures in elderly remains challenge for orthopaedists. There is not a consensus of opinion as to the ideal implant for treatment of intertrochanteric fractures. The main goal of treatment is stable fixation that promotes early postoperative mobilization.

**Corresponding Author:**  
**Dr. Lavakumar S Loya**  
Professor, Department of  
Orthopaedics, Mahadevappa  
Rampure Medical College,  
Kalaburgi, Karnataka, India

Extra-medullary versus Intramedullary devices for stabilisation of proximal hip fractures have been extensively reported in the literature [4,5].

Several methods of internal fixation were advocated in treatment of intertrochanteric fractures. Extramedullary device systems like Dynamic Hip Screw have been extensively used for fixation. This open technique may result in deterioration of co-morbidities in patient [6]. Cutting out of Hip screw and collapse upon weight bearing were major concerns in such cases [7,8].

The strength of the fracture fragment-implant assembly depends upon various factors including [9].

- a) Bone quality,
- b) Fragment geometry,
- c) Reduction,
- d) Implant design and
- e) Implant placement.

Intramedullary devices appear to be highly appropriate due to their biomechanical properties. Although PFN is more popular implant, it comes with its own set of disadvantages, where it has two screws comparing to PFNA-II which has got only one helical blade and Modified Intramedullary Implant having only one lag screw and other disadvantages are Z-effect and Reverse Z-effect.

Modified Intramedullary Implant have been introduced as an intramedullary option in recent years. These devices were developed to obtain better fixation strength and better cancellous bone compaction in the femoral neck, thereby decreasing the risk of secondary displacement. The lag screw system is designed to advance hip fracture treatment with rotational stability design.

The lag screws are designed to transfer the load of the femoral head into the nail shaft by bridging the fracture line to allow fast and secure fracture healing.

The imperative goals of treatment are early mobilization by means of stable fixation using minimally invasive procedure. The Modified Intramedullary Implant may be a more biomechanically suitable implant for intertrochanteric fractures of femur.

## Materials and Methods

We studied consecutive cases of modified intramedullary implant fixation performed between 2019 and 2021 in 20 patients (8 females and 12 males) with a mean age of  $71.3 \pm 9.02$  years (range, 60–90 years). All patients were operated under hypotensive spinal-epidural anaesthesia in supine position on traction table. Patients were evaluated at pre op and post op follow up period with serial radiography and clinically by Harris Hip score (HHP) for pain and disability scoring.

## Preoperative examination and treatment

After admission to the hospital, each patient's limb was elevated on a pillow and abducted. If the patient was expected to undergo surgery within 7 days, the limb was put on only skin traction, not on skeletal traction.

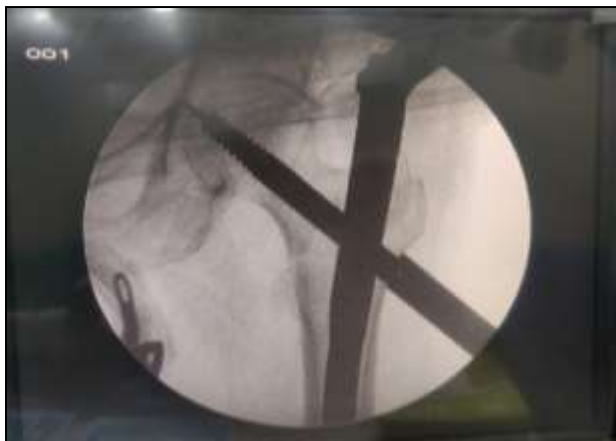
Elderly patients often have various medical disorders, and preoperative examination and treatment are thus very important. For patients aged more than 70 years, we routinely performed ultrasound examinations of the heart and lower extremity vasculature and assess cardiac function, excluding patients with deep vein thrombosis. For patients with respiratory infections, we administered preoperative antibiotics to maintain the patient's haemogram and C-reactive protein level within acceptable limits. The blood glucose level of patients with diabetes was monitored three times daily, excluding some patients with mild diabetes. Insulin therapy was administered to most patients, and the daily fasting and postprandial blood glucose level monitoring was done. A first-generation cephalosporin antibiotic was administered to prevent infection 30 min before surgery and repeated again within 24 h, antibiotic treatment was extended to next 4 days.

## Preoperative preparation

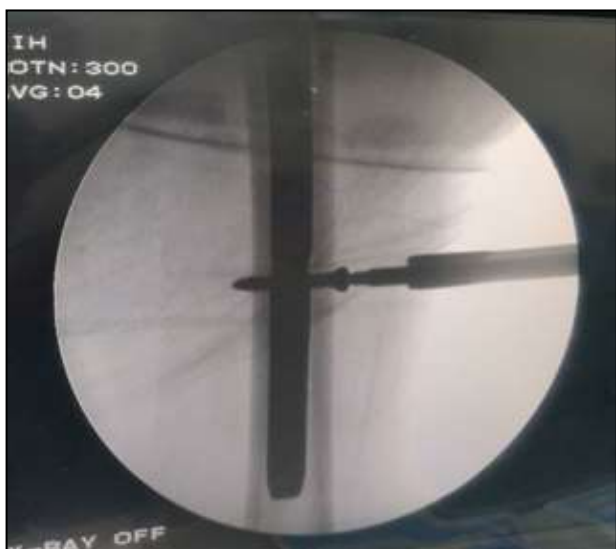Before surgery, all patients underwent lateral femoral X-rays, estimation of the size of the canal, and determination of the nail diameter and length. For patients with a shorter height, we carefully considered whether or not to use the modified intramedullary implant. For taller patients, patients with Evans type IV fractures and patients whose fracture line extended below the lesser trochanter, a 240-mm nail length was considered to increase the stability of the fixation.

## Surgical methods:

All operations were completed by an experienced orthopaedic surgeon. The patient was placed in the supine position on a traction table. The hip and knee of the healthy limb were flexed and abducted to facilitate lateral C-arm fluoroscopy. A single pad was placed under the hip to raise the limb by 5 cm, and the limb was adducted about  $10^\circ$ . The fracture was reset under C-arm X-ray fluoroscopy. An approximately 4- to 7-cm proximal and longitudinal incision was made through the fascia and gluteus to expose the tip of the greater trochanter. The proximal canal was then opened by evenly applied force to avoid breakage of the greater trochanter. After insertion of a reamed nail, fluoroscopy was performed to evaluate the fracture situation. By the anteroposterior C-arm fluoroscopy, the guide pin is located in 1/3 of the femoral neck and located central of the femoral neck by lateral fluoroscopy (fig 1a and 1b). If the position of the guide pin was poor, then the pin should be adjusted to the correct position, but repeated adjustments should be avoided.



**Fig 1A:** Intra-op image showing lag screw insertion



**Fig 1B:** Intra-op images showing distal screw insertion

### Postoperative rehabilitation

The first day after the isometric quadriceps and ankle pump exercises had been performed, the first 2 days of hip and knee flexion and extension exercises were initiated and the patients X-rays were reviewed.

### Postoperative follow-up and treatment evaluation:

The operative time was defined as the duration of time from the start of closed reduction to completion of wound suturing. The operative time, fluoroscopy time, blood loss during surgery, and load time after the operation were evaluated by retrospective statistical analysis. The average follow-up

period was  $12.3 \pm 7.5$  months (4–20 months). Clinical and radiographic examinations were performed at 6 weeks and at 3 and 6 months postoperatively. A Harris hip score of 90 to 100 was considered excellent, 80 to 89 was considered good, 70 to 79 was considered moderate, and  $\leq 69$  was considered poor.

### Results

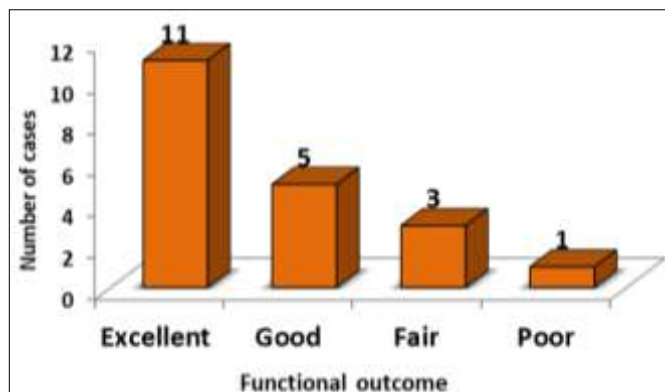
In total, 20 patients underwent closed reduction. The average time from injury to surgery was 3.7 days (range, 2–14 days). The mean operative time was  $47.6 \pm 15.52$  minutes (range, 35–110 min), intraoperative blood loss was  $93.75 \pm 17.67$  mL (range, 65–250 mL), number of intraoperative C-arm fluoroscopy procedures was  $2.7 \pm 1.4$  (range, 2–6), and total incision length was  $6.5 \pm 2.2$  cm (range, 5.5–13.0 cm). The Modified intramedullary implant is available in two different lengths: the standard length (240 mm) was used in 6 patients and a very short length (180 mm) was used in 14 patients. The Modified intramedullary nail is also available in four different diameters: (9, 10, 11, 12 mm) 9 mm was used in 4 patients, 10 mm was used in 9 patients, and 11 mm was used in 7 patients. The mean hospital stay was 11.15 days. All patients were followed up for  $12.3 \pm 7.5$  months (4–20 months).

X-ray evaluation showed a neck-shaft angle of  $134^\circ \pm 15^\circ$  (range,  $115^\circ$ – $150^\circ$ ). The fracture healing time averaged  $12.25 \pm 1.67$  weeks (range, 11–15 weeks).

One patient was lost to follow up due to death, unrelated to surgical complications, while 19 patients completed at least 6 months of follow up. The fracture healing time (union time) averaged  $12.25 \pm 1.67$  weeks (range, 11–19 weeks (table 1). No patients exhibited postoperative non-union, varus, or nail fracture. One patient came with screw back out, one had persistent limp, and two developed superficial skin infection. Two patients developed hip pain, after the administration of nonsteroidal anti-inflammatory drugs (NSAIDs) and the performance of physical therapy, patients with pain experienced improvement. Postoperatively, 80% of patients were ambulatory in the community and 10% were ambulatory but homebound. one patient was wheelchair bound.

There was one case of screw back out where patient came with complaint of hip pain at 6 month follow up, eventual removal of the lag screw was done. There were no cases of revision due to technical or implant failure and no reported case of lag screw (Richard screw) cut-out or penetration into the acetabular joint.

After the last follow-up, the mean Harris hip score was  $86.8 \pm 7.3$  (range, 65–100); the score was excellent in 11 patients (55%), good in 5 (25%), fair in 2 (10%), and poor in 1 (5%) (fig 2).



**Fig 2:** Study reveals that, 11 (55.0%) of cases functional outcome was excellent, 5(25.0%) of cases functional outcome was good, 3 (15.0%) of cases functional outcome was fair and 1 (5.0%) case functional outcome was poor

## Discussion

Trochanteric fractures occur mostly in elderly patients, and the outcome may be extremely poor if there is prolonged bed rest. Stable fixation that allows early mobilization is the treatment of choice. Opinions vary as to the best treatment for trochanteric fracture. Extramedullary devices such the dynamic hip screw are widely used locally although intramedullary nails are increasingly utilized for unstable trochanteric hip fractures due to their biomechanical advantages. Cemented hip hemiarthroplasties for intertrochanteric fractures have also been reported in the literature.

Intramedullary (IM) devices like the PFNA device and Gamma nails were not commonly used locally as they are associated with an unacceptable rate of cut-out and femoral shaft fractures <sup>[10, 11]</sup>, although other authors have reported excellent outcome with these IM nails <sup>[12, 13]</sup>. The new

modified intramedullary implant system is designed to facilitate minimally invasive surgery and reduce the operative time down to minimum by the aid of using new instrumentation and optimized surgical technique. The lag screw (fig 3) system is designed for advanced hip fracture treatment with rotational stability design. The lag screws are designed to transfer the load of the femoral head into the nail shaft by bridging the fracture line to allow fast and secure fracture healing. The thread design of the lag screw also offers excellent grip in the cancellous bone of the femoral head and strong resistance against cut-out. Specially four grooves are designed on the lag screw, so that the Set screw will be engaged which will help to fix lag screw and avoid rotational and medial migration of lag screw. The aim of this retrospective study was to evaluate this relatively new implant in our local population.



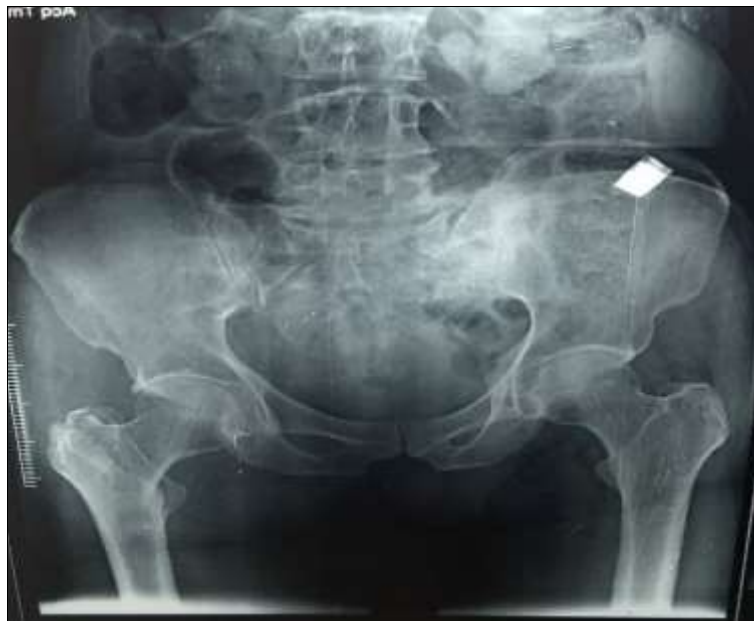**Fig 3:** Modified intramedullary implant and its parts

There was a predominance of elderly patients in our study, similar to others reports in the literature. The mean patient age was 71.3y in this study and the aetiology of most of the fractures was low-energy in nature, consisting of a domestic fall. There were no instances of lag screw penetration into the acetabulum or cut out in this study, a result similarly to those with the use of helical blade reported in the literature <sup>[14]</sup>.

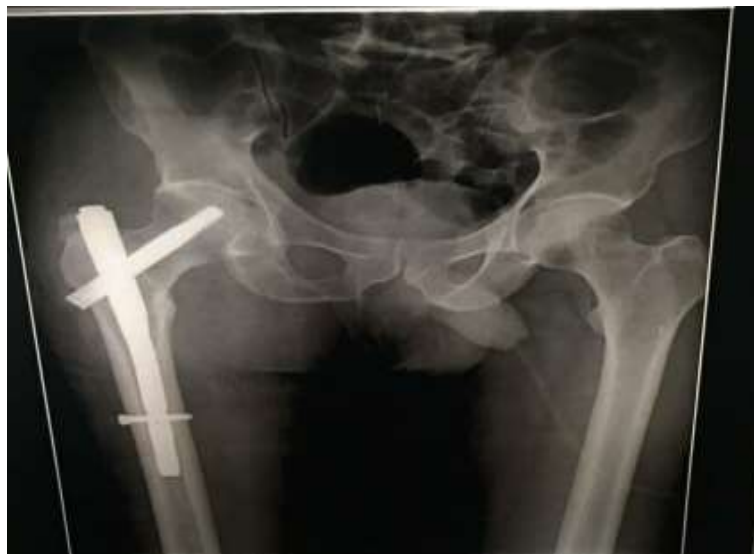There were 2 cases of wound infection among the patients analysed and all two were superficial infections. One of which required debridement and secondary suturing. The limited exposure and decrease in need of muscle release when utilising a Modified intramedullary implant system compared to extramedullary devices like the dynamic hip screw (DHS) can partly explain the relatively low rate of infection.

One limitation of the current study is its small sample size. Moreover, this study involves several surgeons who needed to overcome the learning curve of this relatively new implant. The implant is also more costly compared to the DHS and other intramedullary nails like PFNA. However, it is encouraging to see that 80% of our patients were able to regain preoperative ambulatory status at 6 months following surgery. Some patients required some form of walking aid due to fear of walking and/or weakened musculature. Good reduction of the fracture, and optimal positioning and length of the lag screw are crucial to achievement of good outcomes with the Modified intramedullary nail system. Further studies are needed to compare this new implant with extramedullary devices and other intramedullary designs.

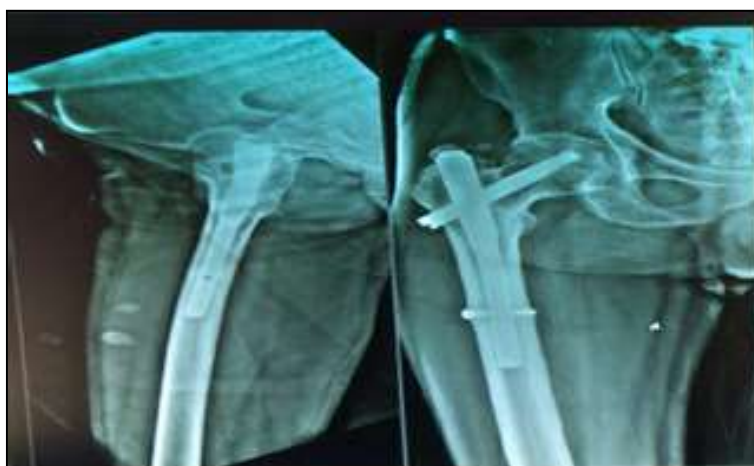**Case 1: 60-Year-old male, right trochanteric fracture**



**Fig 4A: Pre op X-ray**

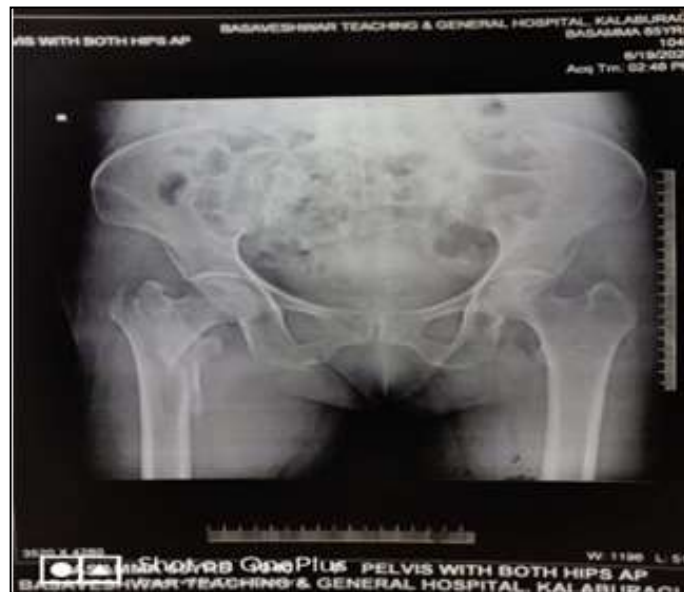

**Fig 4B: Xray at 6 weeks follow up**

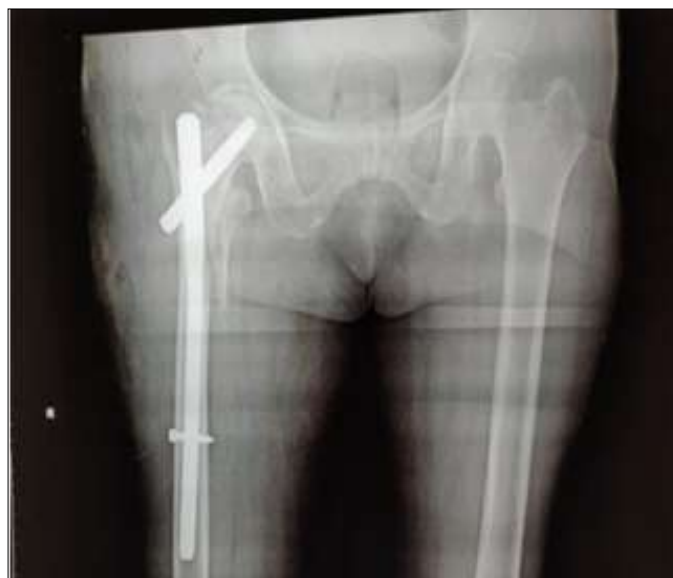

**Fig 4C: X ray 6 months follow up**

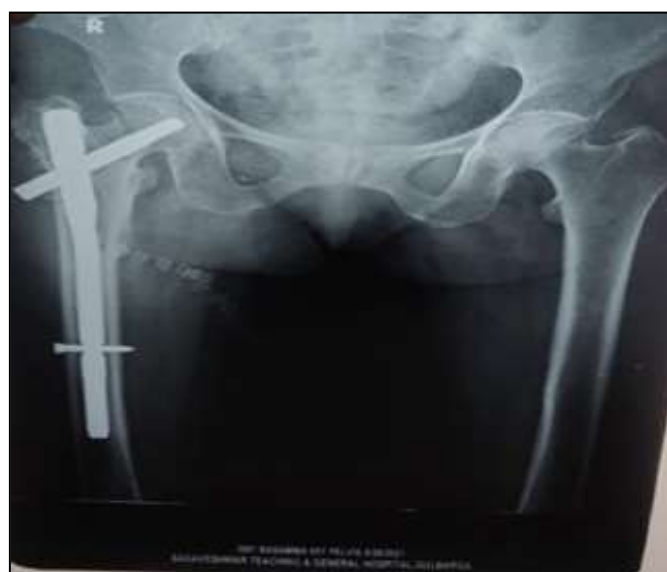**Case 2: 65-Year-old female, right intertrochanteric fracture with poster-medial comminution**



**Fig 5A:** Pre op X ray

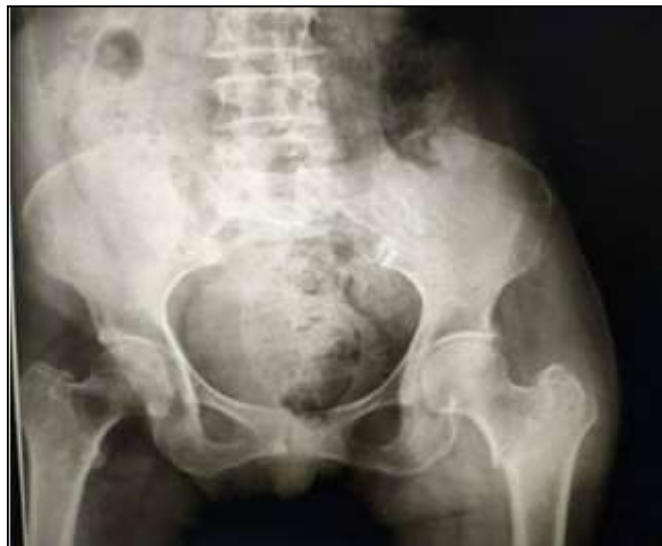

**Fig 5B:** Xray at 6 weeks follow up

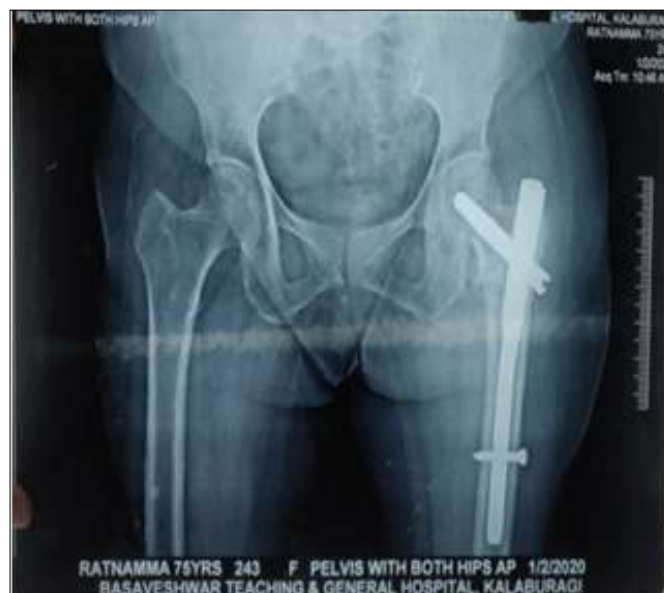

**Fig 5C:** Xray at 6 months follow up

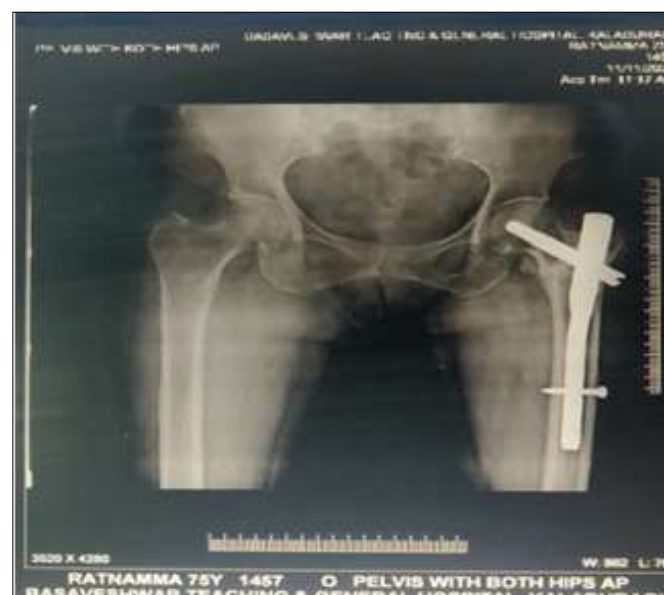**Case 3: 75-Year-old female, left intertrochanteric fracture**



**Fig 6A:** Pre-op xray



**Fig 6B:** Xray at 6 weeks follow up



**Fig 6C:** Xray at 6 months follow up

## Conclusion

Modified intramedullary nail has the advantages of a simple operation, few complications, and clinical efficacy for the treatment of intertrochanteric fractures. However, evaluation of its long-term efficacy and risk of other complications requires a large-sample, multicenter observational study.

## References

1. Muller ME, Nazarian S, Koch P, Schatzker J. The comprehensive classification of fractures of long bones. 1st ed. Berlin, Heidelberg, Germany, New York, NY, USA: Springer-Verlag, 1990.
2. Orthopaedic Trauma Association Committee for Coding and Classification Fracture and dislocation compendium. *J. Orthop. Trauma.* 1996;10(1):5-9, 1-154.
3. Dhal A, Varghese M, Bhasin VB. External Fixator of intertrochanteric fractures of femur. *JBJS (Br).* 1991;73B:955-58.
4. Butt MS, Krikler SJ, Nafie S, Ali MS. Comparison of DHS and Gamma nail: a prospective, randomized, controlled trial. *Injury.* 1995;26:615-18.
5. Schipper IB, Marti RK, van der Werken C. Unstable trochanteric femoral fractures: Extramedullary or Intramedullary fixation. Review of literature. *Injury.* 2004;35(2):142-51.
6. Morris AH, Zuckerman JD, American Academy of Orthopaedic Surgeons Council of Health Policy and Practice- Improving the continuum of care of patients with Hip fractures. *J Bone Joint Surg Am.* 2002;84:670-4.
7. Flores LA, Harrington IJ, Heller M. The stability of intertrochanteric fractures treated with sliding hip screw-plate. *J Bone Joint Surg Br.* 1990;72:37-40.
8. Simpson AH, Varty K, Dodd CA. Sliding hip screws: modes of failure. *Injury.* 1989;20:227-31.
9. Sadowski C, Lubbeke A, Saudan M, Riand N, Stern R, Hoffmeyer P. Treatment of reverse oblique and transverse intertrochanteric fractures with use of an intramedullary nail or a 95 degrees screw-plate: a prospective, randomized study. *J Bone Joint Surg Am.* 2002;84(3):372-81.
10. Albareda J, Laderiga A, Palanca D, Paniagua L, Seral F. Complications and technical problems with gamma nail. *Int Orthop.* 1996;20:4750.
11. Herrera A, Domingo LJ, Calvo A, Martinez A. A comparative study of trochanteric fractures treated with Gamma nail or the proximal femoral nail. *Int Orthop.* 2002;26:365-9.
12. Domingo LJ, Cecilia D, Herrera A, Resines C. Trochanteric fractures treated with a proximal femoral nail. *Int Orthop.* 2001;25:298-301.
13. Al-yassari G, Langstaff RJ, Jones JW, Al Lami M. The AO/ ASIF proximal femoral nail (PFN) for the treatment of an stable trochanteric fracture. *Injury.* 2002;16:386-93.
14. Brunner A, Jöckel JA, Babst R. The PFNA proximal femur nail in treatment of unstable proximal femur fractures-3 cases of postoperative perforation of the helical blade into the hip joint. *J Orthop Trauma.* 2008;22(10):731-6.