



E-ISSN: 2395-1958  
P-ISSN: 2706-6630  
IJOS 2022; 8(1): 119-122  
© 2022 IJOS  
[www.orthopaper.com](http://www.orthopaper.com)  
Received: 18-11-2021  
Accepted: 20-12-2021

**Dr. Rajashekar M**  
Professor and Unit Chief,  
Department of Orthopaedics,  
Dr. B.R. Ambedkar Medical  
College and Hospital,  
Bangalore, Karnataka, India

**Dr. Nithin Shekar C**  
a) 3rd Year PG Orthopaedics,  
Department of Orthopaedics,  
Dr. B.R. Ambedkar Medical  
College and  
Hospital, Bangalore,  
Karnataka, India  
b) Rajiv Gandhi University of  
Health Sciences, Bangalore,  
Karnataka, India

## Functional outcome of distal end femur fracture treated with locking compression plate

Dr. Rajashekar M and Dr. Nithin Shekar C

DOI: <https://doi.org/10.22271/ortho.2022.v8.i1b.2997>

### Abstract

**Aim of the study:** The aim of this study is to assess the functional outcome of distal femur fracture treated with a locking compression plate.

**Materials and methods:** The study was conducted from July 2019 to February 2021 at Dr BR Ambedkar Medical College and Hospital with follow-up period of six months. 20 skeletal mature patients fulfilling the inclusion criteria with distal end femur fractures were surgically treated with distal femoral locking compressive plate using a direct lateral approach. The clinical assessment was conducted for at least a period of 6 months postoperatively using the oxford knee scoring system.

**Results:** At six months of follow-up, 10 patients achieved range between 120 to 140°, 9 achieved between 100 to 120 and 1 had 95° flexion.

In the present study, 18 out of 20 cases (90%) showed a radiological union at 3 months' follow-up. 2 cases (10%) had radiological union at 6 months (24 weeks) of follow-up. In the present study, 85% of cases that is 17 of 20 cases had Oxford Knee Score of more than 41, 2 cases that is 10% had a score between 34 and 40, and only 1 had a score between 27 and 33. In the present study, 17 cases, i.e., 85% showed excellent functional outcome, while 2 cases showed good and 1 case had a fair outcome.

**Conclusion:** The use of LCP in distal femoral fracture promotes early radiological union, good knee range of movement and early recovery when fracture fixation is done following all the basic principles of fracture fixation.

Finally, it can be concluded that the use of LCP provides a good functional outcome for distal femur fractures, particularly in osteoporotic bones.

**Keywords:** Distal femur fracture, open reduction and internal fixation, distal locking compression plate

### Introduction

Distal femur fractures account for an estimated 6% of all femur fractures. The annual incidence of distal femur fractures is around 37/1,00,000 people [1]. High-speed vehicular accidents are responsible for distal femur fractures commonly observed in the young and middle-aged. Low energy mechanisms such as falls at home may be responsible for producing fractures of the distal femur in the elderly osteoporotic population, especially women [2]. These fractures are difficult to treat because of osteoporosis, severe comminution, too short distal femoral fragment compound injuries. The goals of surgical treatment should be an anatomic reduction of the articular surface, restoration of limb alignment, length, and rotation, bone grafting for extensive bone loss and stable fixation that allows for early mobilization [3]. There are different surgical options available: Antegrade nailing, retrograde nailing, blade-plate fixation, isolated screw fixation, locked plating, and as a part of damage control orthopedics, external fixator use. External fixation with devices such as the hybrid external fixator and the Ilizarov external fixator are excellent for treating comminuted fractures associated with bone loss. In addition to maintaining reduction whilst awaiting union, these devices can also be used to lengthen the bone. However, pin tract infections and joint contractures are common complications of these techniques. A proper understanding of the vascularity of tissue and the biology of bone is necessary for locking plate fixation [4]. For better stability in the osteoporotic bone multiple fixed angled screws were used to fix the locking plate. Multi articular fragments of the distal femur can be fixed by using more than one distal screw in this implant [4, 5]. Locking compression plates reduce varus collapse, which is encountered with the use of traditional plates [6, 7].

**Corresponding Author:**  
**Dr. Rajashekar M**  
Professor and Unit Chief  
Department of Orthopaedics  
Dr. B.R. Ambedkar Medical  
College and Hospital  
Bangalore, Karnataka, India

Oval shaped holes of the locking plate provides good compression to the bone while applying locking screws. LCP has more advantage than compression and bridge plating. This preserves periosteal vessels and reduce soft tissue damage. Therefore it acts like an internal fixator [8].

### Materials and Methods

This prospective study was conducted in patients fulfilling inclusion criteria treated for distal femoral fractures with locking compression plate in the department of orthopedics from July 2019 to February 2021 at Dr BR Ambedkar Medical College and Hospital with follow-up period of six months after obtaining patients consent.

#### Inclusion criteria

- Patients aged 18 years and above and of either sex.
- Patients with distal femur fractures as determined by clinical examination and diagnostic imaging (X-rays/CT if needed) done.
- Patients presenting with lower end femur fractures with or without osteoporotic changes are included in this study.
- Closed and open (type I & 2) distal femur fractures.

#### Exclusion criteria

- Patients below 18 years of age and open physis.
- Fracture more than 4 weeks old.
- Open (type III) distal femur fractures.
- Pre-existing local infection/ deformity.
- Patients are managed conservatively for other medical illness.
- Fracture lower end femur with neurovascular compromise or knee joint dislocations.
- Patients lost in Follow-up & noncompliance patients.

The patients were initially assessed in the emergency, Once other injuries were ruled out and the patients was hemodynamically stable, the injured limb was immobilized and an x-ray of the affected limb, distal femur with the knee joint AP & Lateral views were taken & fracture pattern classified according to AO classification.

#### Surgical Technique

Patient was placed in a supine position on the radiolucent operation table under spinal anesthesia with a rolled sheet under the knee joint. Tourniquet was applied to obtain a bloodless field for surgery. A direct lateral incision was used in all the cases under image intensifier guidance. The submuscular layer was split along its direction, using a periosteal elevator, the bone cleared from its soft tissue. The fracture was reduced by traction and manipulation under image intensifier guidance. K-wires were used to hold the intercondylar fragments in alignment, the K-wires were placed in such a manner that it would not hamper the plate placement. Appropriate length plate placed under image intensifier guidance and temporarily fixed using K-wires, compression screw placed to approximate the plate to the bone. Distal locking cancellous screws placed and proximal locking was done with minimal invasive technique. Tourniquet deflated, haemostasis achieved, drain placed, wound closed in layers sterile dressing done.

Post operatively, the patient limb was elevated and advised for ankle pump after recovering from anaesthesia. Intravenous antibiotics was administered for 3 days followed by 5 days of oral antibiotics, the drain was removed after 24 hours, knee mobilization started from day 2, suture removal was done on

14th day, the patients were kept non weight bearing for 6-8 weeks.

Follow-up was taken at 2 weeks, 6 weeks, 12 weeks, and 6 months to assess the functional and radiological outcome. The radiological outcome was checked using X-rays in AP and lateral views. Oxford Knee Score was used to assess the functional outcome. It is a questionnaire consisting of 12 questions assessing the functional status of the patient. The maximum score given is 48. Score of >41 is excellent; 34–40 is good functional status; 27–33 is fair; and score of <27 is considered poor functional result.

### Results

In our study of 20 cases the patients aged between 21 to 76 years, majority of the patients 80% (15 out of 20) were in the age group 21 to 40 years age group with mean age of 48.5.

In our study majority 85% (17 out of 20) was due to trauma road traffic accident, 3 had trivial trauma due to fall and 3 had open wound (gustillo-anderson type 1-2. gustillo-anderson type 2-1). All the fractures were classified according to AO classification.

The radiological union time was assessed by getting X-rays on the follow-up visits. 18 of 20 cases (90%) showed a radiological union at 3 months' follow-up. 2 cases (10%) had radiological union at 6 months (24 weeks) of follow-up.

**Table 1:** Radiological union in weeks

Duration in weeks	Number of cases (%)
≤12 weeks	18 (90)
12–24 weeks	2 (10)
Total	20 (100)

The mean knee range of motion was 113.75°, with 1 patient showing 10° of extension loss. Flexion of at least 110° was considered satisfactory, and 1 case had an unsatisfactory knee range of motion.

**Table 2:** Range of motion at the end of follow-up

Range of motion	Number of cases (%)
Up to 100	1 (5)
100–120	9 (45)
120–140	10 (50)
Total	20 (100)

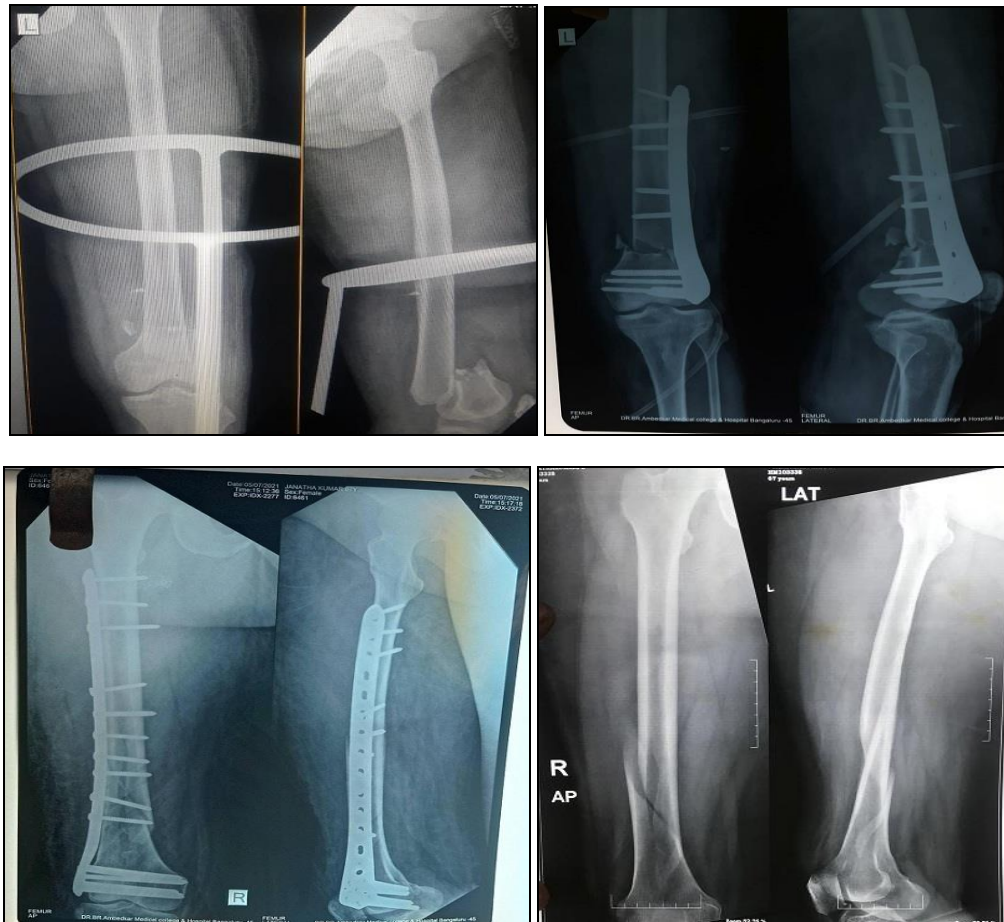
The mean Oxford Knee Score is 40.6. The Oxford Knee Score is a functional knee score of consisting of 12 questions. Total score is taken as 48. In the present study, 85% of cases that is 17 of 20 cases had a score of more than 41, 2 cases that is, 10% had a score between 34 and 40, and only 1 had a score between 27 and 33. Grading is done according to the score. It is designated as follows: Excellent - more than 41, good - 34–40, fair - 27–33, and poor - <27. In the present study, 17 cases, i.e., 85% showed excellent functional outcomes, while 2 cases showed good and 1 case had a fair outcome. There was no case with a poor functional outcome.

**Table 3:** Grading according to the Oxford Knee Score at end of the follow-up

Grading	Number of cases (%)
Excellent	17 (85)
Good	2 (10)
Fair	1 (5)
Poor	0 (0)
Total	20 (100)

Of a total of 20 cases in the present study, 3 cases had complications. There were no cases of any deep infection, malunion, or skin necrosis. 1 case had superficial infection, 2

had delayed union, i.e., union seen at 24 weeks of follow-up, 1 had knee stiffness that is 5%, and 2 cases had extension lag of 20° and 10°, respectively (6.67%). [Tables 1-3].



**Fig 1:** Pre Op & Post Op x-ray

## Discussion

In the present study, the most common mode of injury was road traffic accidents (85%) in young people & remaining (15%) was because of falls from height or domestic falls in the elderly. These are similar in the series of Ravi M Nayak *et al.*, where 77.41% cases were brought to the hospital due to road traffic accidents & 19.24% were due to falls and 10.04% were because of assault [9].

In a study on biomechanical testing of the LCP by Ahmad M *et al.*, [10] it was stated by increasing the distance from 2 to 6 mm both torsional rigidity and axial stiffness decreased by as much as 10–15%. It was found that increasing the distance between the plate and the bone significantly affected the construct stability. It was concluded that LCP behaved in a mechanically similar manner when fixed either flush to the bone or at 2 mm from the bone. However, when the LCP is fixed at a distance of 5 mm from the bone, both axial stiffness and torsional rigidity are decreased significantly. In the present study, the majority of the patients (90%) showed a radiological union at 12 weeks of follow-up and delayed union seen in 2 cases that is union seen at 24 weeks' follow-up, which matched the study done by Kanabar *et al.* of 12.5 weeks. The callus formation was assessed in both lateral and AP radiographs [11].

The mean range of motion in the present study was 113.75° with more than 80% patients having knee range of motion more than 110°. In the present study, ROM of the affected knee was > 120° in 10 (50%) cases, 100–120° in 9 (45%) cases and <100° in 1 (5%) cases. Other workers had similar

results in their studies like Ej Yeap *et al.*, observed that mean range of motion was 107.7° (range 40°–140°) [12]. In a study done by Pushkar and Bhan [13], it was stated that normal knee flexion is 140°. Laubenthal *et al.* have demonstrated that average motion required for: Normal - 93°, sitting - 100°, and squatting - 117°.

The functional outcome in this study was assessed using the Oxford Knee Scoring system. The mean score in this study was 40.6. Ganesh *et al.* [14], in their study of LISS in treatment of distal femur fractures showed 8% good and 92% excellent result using the Oxford Knee score. In our study, there excellent result was seen in 85% of cases, while 10% had good results.

Philips *et al.* [15] stated that the possible disadvantages of the use of the LISS fixator for distal femoral fractures include reduction difficulties of the metaphyseal-diaphyseal component of the fracture and accurate fixator placement. In addition, its use is technically demanding because fracture reduction and fixation must be obtained and performed simultaneously. In the present study, there were 2 cases of superficial bacterial infection, 2 cases of delayed union where delayed union was seen at around 24 weeks and 2 had extensor lag of 10 degree.

## References

1. Zlowodzki M, Bhandari M, Marek DJ, Cole PA, Kregor PJ. Operative treatment of acute distal femur fractures: Systematic review of 2 comparative studies and 45 case series (1989 to 2005). *J Orthop Trauma* 2006;20:366-71.

2. Martinet O, Cordey J, Harder Y. The epidemiology of fractures of the distal femur. *Injury*. 2000;31:62-63.
3. Mahesh DV, Gunnaiah, Vishwanath. Management of distal femur fracture by locking compression plate. *IJHSR*. 2014;4(5):235-40.
4. Egol KA, Kubiak EN, Fulkerson E, Kummer FJ, Koval KJ. Biomechanics of locked plates and screws. *J Orthop Trauma*. 2004;18(8):488-93.
5. Kregor PJ, Stannard J, Zlowodzki M, Cole PA, Alonso J. Distal femoral fracture fixation utilizing the Less Invasive Stabilization System (L.I.S.S.): the technique and early results. *Injury*. 2001;32(3):SC32-47.
6. Perren SM. Evolution of the internal fixation of long bone fractures. The scientific basis of biological internal fixation: choosing a new balance between stability and biology. *J Bone Joint Surg Br*. 2002;84:1093-1110.
7. Hugh Owen Thomas. Quoted by Rockwood CA, Green DP. *Fractures in adult*, 4<sup>th</sup>ed. 1996;2:1972-1993.
8. Vallier HA, Hennessey TA, Sontich JK, Patterson BM. Failure of LCP condylar plate fixation in the distal part of the femur. *J Bone Joint Surg*. 2006;88-A:846-53.
9. Ravi M Nayak, Koichade MR. Minimally invasive plate osteosynthesis using a locking compression plate for distal femoral fracture. *Journal of Orthopaedic Surgery*. 2011;19(2):185-90.
10. Ahmad M, Nanda R, Bajwa AS, Candal-Couto J. Biomechanical testing of locking compression plate: When does the distance between bone and implant significantly reduce construct stability. *Injury, Int. J. Care Injured*. 2007;38:358-64.
11. Schütz M, Müller M, Regazzoni P, Höntzsch D, Krettek C, Van der Werken C *et al*. Use of the less invasive stabilization system (LISS) in patients with distal femoral (AO33) fractures: A prospective multicenter study. *Arch Orthop Trauma Surg* 2005;125:102-8.
12. Yeap EJ, Deepak AS. Distal femoral Locking compression plate fixation in Distal Femoral Fractures: Early Results. *Malaysian Orthopaedic Journal*. 2007;1(1):12-17. ISSN 1985 2533.
13. Pushkar D, Bhan N. Comparison of results of distal femoral fractures treated by internal fixation with locking compression plate and retrograde femoral nail. *J Cont Med A Dent*. 2016;4:79-83.
14. Wilkens KJ, Curtiss S, Lee MA. Polyaxial locking plate fixation in distal femur fractures: A biomechanical comparison. *J Orthop Trauma*. 2008;22:624-8.
15. Nasr AM, McLeod I, Sabboubeh A, Maffulli N. Conservative or surgical management of distal femoral fractures. A retrospective study with a minimum five year follow-up. *Acta Orthop Belg*. 2000;66:477-83.