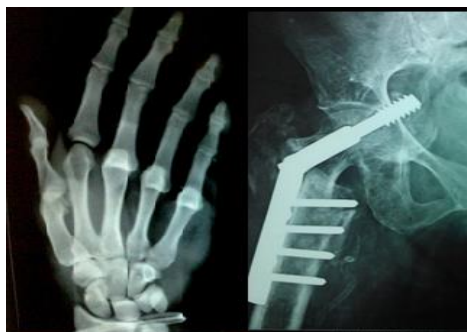

International Journal of Orthopaedics Sciences

E-ISSN: 2395-1958
P-ISSN: 2706-6630
IJOS 2022; 8(1): 25-28
© 2022 IJOS
www.orthopaper.com
Received: 25-10-2021
Accepted: 12-12-2021

Dr. Kamalesh Kumar A Patel
Assistant Professor at GMERS
Medical College, Himmatnagar,
Gujarat, India

Dr. Vijay J Patel
Assistant Professor at AMC MET
Medical College, Ahmedabad,
Gujarat, India

Dr. Raghav K Suthar
Assistant Professor at AMC MET
Medical College, Ahmedabad,
Gujarat, India

Corresponding Author:
Dr. Vijay J Patel
Assistant Professor at AMC MET
Medical College, Ahmedabad,
Gujarat, India

Clinical and radiological outcome of humerus shaft fracture treated with open reduction and internal fixation with plate

Dr. Kamalesh Kumar A Patel, Dr. Vijay J Patel and Dr. Raghav K Suthar

DOI: <https://doi.org/10.22271/ortho.2022.v8.i1a.2985>

Abstract

Background: Fractures of the humeral shaft represent 2–4% of all fractures with no obvious single best surgical method to manage this injury. Non-operative methods is also considered even in the current era with the selected patient. Operative methods curtails prolonged immobilization, provides early rehabilitation and excellent to a good outcome with due surgical complication risk. The posterior approach and internal fixation is widely used by many surgeons. To assess radiological as well as clinical results described in this study.

Methods: We did a retrospective study of 20 cases presented to our institute with shaft fracture of the humerus between January 2019 to March 2021 with closed, extraarticular shaft fracture of the humerus. Final functional results were assessed with a constant-merley scoring system.

Results: In our study, according to constant merely scoring we noted excellent results in 11 patients and fair results in 01 patients. We did not revise any fixation nor intervene for preoperative radial nerve injury. Mean union time was 16 weeks in our study.

Conclusion: Open reduction and internal fixation of humerus shaft fracture when applied with biological as well as mechanical principles fetch a excellent to good results functionally, which obviates the need of prolonged immobilization when treated with conservatively.

Keywords: Humerus shaft fracture, open reduction, posterior approach, 4.5 DCP

Introduction

Fractures of the humeral shaft represent 2–4% of all fractures. Most of these fractures occur in the elderly population and are the result of a fall; however, younger patients may sustain this injury secondary to penetrating or high-energy trauma [1].

At present, there is no consensus about the ideal treatment of shaft humerus fracture [2,3]. Many authors have shown promising results with nonoperative treatment but its associated with prolonged immobilization [4]. To overcome the problem associated with non-surgical treatment, various surgical treatment methods have been developed to improve early mobilization and predicted the restoration of anatomy [5-7].

Traditionally posterior approach is popular among surgeons for open reduction and internal fixation (ORIF) of the humerus. The posterior approach has got some biomechanical advantages, like plating can be done on the tension side of the humerus [8]. The Radial nerve crosses the humerus shaft from the posterior side between two heads of triceps in a spiral groove where it is vulnerable to injury while fixation of shaft humerus fractures from posterior approach [9].

To overcome problems of the posterior approach, many authors are now suggesting the anterolateral approach and its modifications. The advantages of this approach include supine positioning, (which is the most notable advantage for patients with multiple injuries) and relatively less direct encounter of radial nerve [10, 11] though there is a risk of secondary nerve injury to the anterolateral approach while exposing and putting a plate on the anterolateral surface [12]. To overcome that, anterior plating was delineated.

In a present study, we aimed to evaluate the operative outcome of humerus shaft fracture treated with open reduction and internal fixation with a plate in the adult population. The outcome was assessed clinically and radiologically for union time, functional recovery and complications.

Materials and Methods

We did a retrospective study of 20 cases presented to our institute with shaft fracture of the humerus between January 2019 to March 2021.

Our criteria for the selection of patients were described below:

Inclusion criteria

- Age >18 years
- Closed fracture
- Fractures with isolated radial nerve palsy
- Fractures treated with internal fixation by the dynamic compression plate

Exclusion criteria

- Age less than 18 years
- Fractures involving articular surfaces
- Open fractures
- Pathological fracture
- i/l limb fracture
- brachial plexus injury
- previous history of surgery about ipsilateral shoulder and elbow

All patients were assessed adequately with radiological, pathological as well as clinical examination. They had been taken for surgery after anesthetic clearance surgical technique:

All patients included in the study were operated with open reduction and internal fixation with a dynamic compression plate (4.5 mm) via a posterior approach. The incision was taken between the olecranon tip and proximal third of the shaft as needed for fracture. Fascia is divided in lines of incision. Radial nerve isolated and mobilized gently with utmost care. Triceps split was done distally in our routine approach. Minimal periosteal dissection and stripping was ensured in all cases. The fracture was held with k wires and or reduction clamps temporarily. 4.5 mm DCPs were applied to all cases after achieving a good reduction. Wounds were closed in a standard manner without drain.

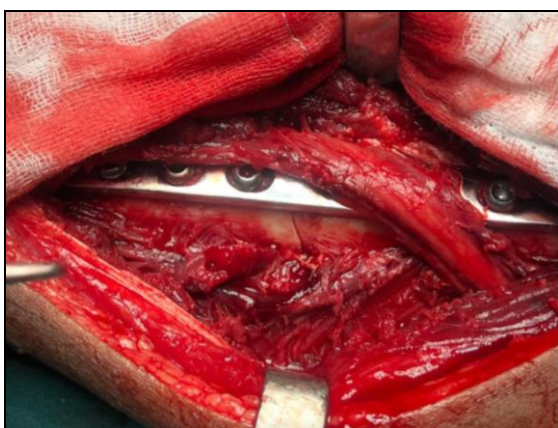


Fig 1: Meticulous dissection of the radial nerve and humerus fracture fixation with dynamic compression plate. (Note minimum periosteal stripping with compression mode of plate application)

Post-operative protocol

No patients were given slab or brace. Patients after surgery were given arm support sling. Parenteral Antibiotics were given for the first 48 hours, followed by oral antibiotics for 7 days. Regular cleaning and dressing were done at the out-patient department. Mobilization of elbow, shoulder and arm

movement started very next day under physical therapist observation. Stitches removal done at two weeks.

Follow-up visits at one month, three months and six months along with clinical and radiological examinations had been carried out. The functional assessment had been done by constant merely scoring system at the time of follow up.

We did encounter with two radial nerve injury cases along with the shaft of humerus fractures were exposure showed only contusion with intact nerve. Which recovered fully within 3 months for both cases. No extra plates other than DCP were used. We did not encounter with any postoperative radial nerve palsy in our 20 cases.

Results

We had evaluated 20 cases treated with open reduction and internal fixation with 4.5 mm DCP (stainless steel) with an average minimum follow up of 9 months and maximum follow-up of 24 months. The mean age of patients included in the study were 40 years, where patient with minimum age was 19 years old and patient with maximum age was 67 years old. In our study there were 14 male patients (70%) whereas 06 female patients (30%). The mechanism of injury was motor vehicle accident in majority of cases i.e. 15 cases (75%) followed by domestic fall in 4 cases (20%). In one case patient was fall from height (5%). The right sided fractures were noted in 14 patients (70%) and left sided fractures were noted in 06 patients (30%).

Fracture was classified by AO classification

Table 1: Shows the details regarding classification (AO classification)

S. No.	Type (AO) 12	No of patients	Percentage
1	12 A1	4	20%
2	12 A2	6	30%
3	12 A3	4	20%
4	12 B2	5	25%
5	12 B3	1	10%
6	12 C	0	0
	Total	20	100%

Most of the patients classified as A2 and B2 fractures followed by A1, A2. There were no case of type c fracture in our study.

Out of 20 patients 3 patients had associated injuries other than humerus shaft fractures. These injuries were not involving ipsilateral upper limb. One patient was having head injury with GCS 13/15 managed conservatively for contusion injury. Other patient was having abdominal injury managed conservatively by gastro surgeon and remaining had a lateral tibial condyle fracture treated with cancellous screws.

We did not encounter with radial nerve palsy post operatively in any of our cases. In one case there were superficial infection which had been treated by dressing and extended oral antibiotics for 14 days which healed uneventfully. In our study we noted two preoperative radial nerve palsy recovered fully within 3 months where cock up splint and rehabilitation protocol curtailed for them.

In our study mean union time was 4 months radiologically. Earliest union was noted on x ray at 11 weeks and latest union was noted at 20 weeks. We did not encounter with nonunion. We did not use any bone graft or bone graft substitute while index surgery. No elbow stiffness in any case.

Functional assessment had been evaluated with constant merely scoring system.

Table 2: Assessed scoring by aforementioned scoring system had been depicted in following

Sr. No.	Rating	Constant - merley score (max 100 points)	No of patients
1	Excellent	86-100	11 (55%)
2	Good	71-85	08 (40%)
3	Fair	56-70	01 (05%)
4	poor	<56	00

In our study according to constant merley scoring we noted excellent results in 11 patients and fair results in 01 patient.

(Figure 2, a-f) We did not revise any fixation in our study cases.

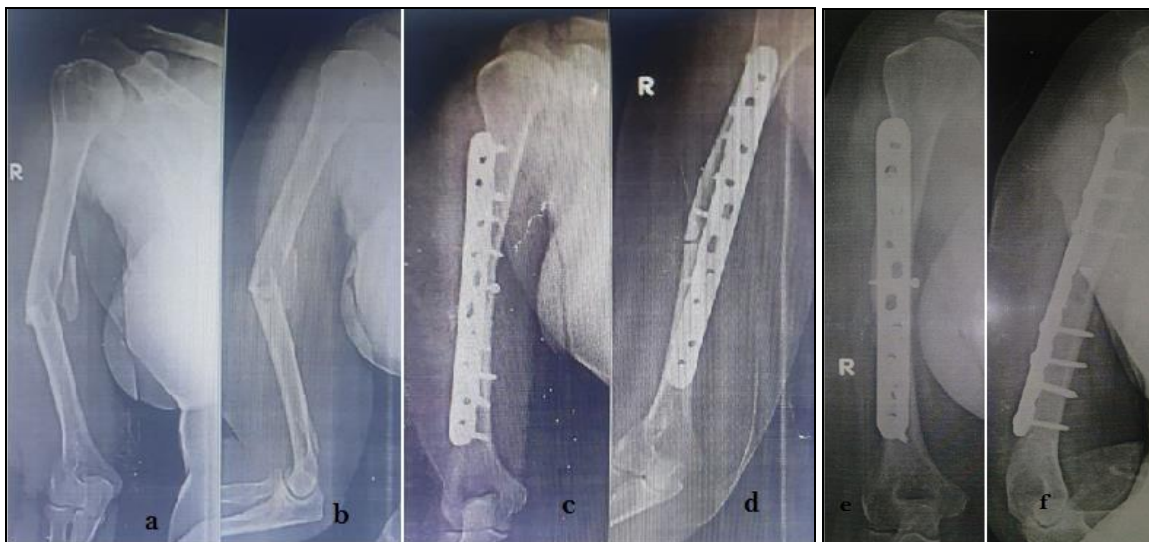


Fig 2: a, b: preoperative radiograph showing humerus shaft fracture c, d: immediate post-operative radiograph with ORIF with dynamic compression plate e, f: radiograph showing complete healing of fracture at final follow up

Discussion

Humerus shaft fracture treatment is still a debatable issue concerning many surgeons. Versatile implants as well as variable approaches to address some of the fractures may create multiple options for treatment. Nonetheless, supremacy of any method or implant is not well established as well as not generalized accepted. Conservative methods of certain humerus shaft fractures gives excellent results when applied correct principles of closed treatments. In the recent era displaced fractures of humerus treated surgically by either plate or nail. Internal fixation of humerus fractures allows early rehabilitation, curtails chances of stiffness and immobilization.

Lack uniformity of humerus intramedullary diameters along with higher side shoulder related complications such as adhesive capsulitis, proximal migration of implant, shoulder stiffness as well as distraction of fracture site due to its anatomic curvature makes intramedullary interlocking less favourable among certain mass of surgeons [13, 14].

Use of plate over nail considered more reliable with superior results as compared to IM nailing with lesser shoulder related complications [15].

We conducted this study in series of patients to evaluate clinical as well as radiological outcome of shaft humerus fracture treated with Open Reduction internal fixation with plate. In our series all humerus fracture were operated through posterior approach so outcome was assessed in terms of rate of healing, primary nerve palsy remission, iatrogenic nerve palsy and postoperative complications. Over all outcome showed a high healing rate with limited postoperative complications thus we could able to offer satisfactory results in all operated patients.

In a review by Clement and Gosler *et al.* they demonstrated paucity of literature of level one evidence for the treatment of

humeral shaft fractures with lack of consensus on ideal method [3, 5].

Many literature shows good results along with union when treated conservatively, although selection of patient and fracture geometry has paramount importance to execute such methods.

Later on in 2017 Matsunaga *et al.*, published prospective randomized trial provided level one evidence comparing functional bracing and bridge plating for humeral shaft fractures. Their result showed statistically significantly higher rate of nonunion and angular displacement in patient treated conservatively vs patients treated with bridge plating thus supporting operative management of humerus shaft fracture [7].

There is lack of recent literature that that shows strong evidence to support the use of ORIF or minimally invasive procedures (MIPO) for primary fracture treatment.

Xuqi Hu *et al.* [16] did meta-analysis of eight studies, that includes four randomized controlled trials (RCTs), two prospective cohort and presented results of a systematic review comparing various methods of treatment. They concluded that there is no significant difference in terms of the postoperative radial injury incidence, union rate or functional outcome between the two Groups. We have been using the posterior humeral approach frequently for the treatment of humeral shaft fractures by ORIF as well as for nonunion repair. ORIF offers the opportunity for the exact reduction and anatomical fixation of the fracture and can enable primary or secondary fracture healing depending on the type of osteosynthesis and fracture pattern. Currently available literature confirms our finding that open reduction and internal fixation with plating is a safe and efficacious treatment option for humeral shaft fractures.

Conclusion

There are no superior techniques or implants over one another to treat humerus shaft fractures operatively. Properly applied surgical techniques, correct application of principles of biomechanics, legitimate dissection of surrounding soft tissues and adequate fixation is an essential counterpart of surgical treatment of humerus fractures. Open reduction and internal fixation with suitable plate when applied with aforementioned factors fetch a good result.

References

1. Ekholm R, Adami J, Tidermark J, Hansson K, Tornkvist H, Ponzer S. Fractures of the shaft of the humerus. An epidemiological study of 401 fractures. *J Bone Joint Surg Br.* 2006;88(11):1469-73.
2. Ouyang H, Xiong J, Xiang P, Cui Z, Chen L, Yu B. Plate versus intramedullary nail fixation in the treatment of humeral shaft fractures: an updated metaanalysis. *J Shoulder Elb Surg.* 2013;22(3):387-95.
3. Gosler MW, Testroote M, Morrenhof JW, Janzing HM. Surgical versus nonsurgical interventions for treating humeral shaft fractures in adults. *Cochrane Database Syst Rev.* 2012;1:CD008832.
4. Sarmiento A, Kinman PB, Galvin EG, Schmitt RH, Phillips JG. Functional bracing of fractures of the shaft of the humerus. *J Bone Joint Surg Am.* 1977;59(5):596-601.
5. Clement ND. Management of Humeral Shaft Fractures; Non-Operative Versus Operative. *Arch Trauma Res.* 2015;4(2):e28013.
6. Schoch BS, Padegimas EM, Maltenfort M, Krieg J, Namdari S. Humeral shaft fractures: national trends in management. *J Orthop Traumatol.* 2017;18(3):259-63.
7. Matsunaga FT, Tamaoki MJ, Matsumoto MH, Netto NA, Faloppa F, Belloti JC. Minimally invasive Osteosynthesis with a bridge plate versus a functional brace for humeral shaft fractures: a randomized controlled trial. *J Bone Joint Surg Am.* 2017;99(7):583-92.
8. Müller ME, Bandi W, Allgöwer M, Bloch HR, Willenegger H, Mumenthaler A, Scheider R, Weber BG. *Manual der osteosynthese: AO-technik.* Berlin: Springer, 2013.
9. Zlotolow DA, Catalano LW, Barron OA, Glickel SZ. Surgical exposures of the humerus. *J Am AcadOrthop Surg.* 2006;14(13):754-65.
10. Boschi V, Pogorelic Z, Gulan G, Vilovic K, Stalekar H, Bilan K, Grandic L. Subbrachial approach to humeral shaft fractures: new surgical technique and retrospective case series study. *Can J Surg.* 2013;56(1):27-34.
11. Idoine JD, French BG, Opalek JM, DeMott L. Plating of acute humeral diaphyseal fractures through an anterior approach in multiple trauma patients. *J Orthop Trauma.* 2012;26(1):9-18.
12. Kim SJ, Lee SH, Son H, Lee BG. Surgical result of plate osteosynthesis using a locking plate system through an anterior humeral approach for distal shaft fracture of the humerus that occurred during a throwing motion. *Int Orthop.* 2016;40(7):1489-94.
13. Watanabe RS. Intramedullary fixation of complicated fractures of the humeral shaft. *Clin Orthop Relat Res.* 1993;292:255-63.
14. Brumback RJ, Bosse MJ, Burgess AR, Poka A. Intramedullary stabilization of humeral shaft fractures in patients with multiple trauma. *J Bone Joint Surg Am.* 1986;68:960-70.
15. Singiseti K, Ambedkar M: Nailing versus plating in

humerus shaft fractures: A prospective comparative study. *Int Orthop.* 2010;34(4):571-576.

16. Hu X, Xu S, Lu H, Chen B, Zhou X, He X, *et al.*. Minimally invasive plate osteosynthesis vs conventional fixation techniques for surgically treated humeral shaft fractures: a meta-analysis. *J Orthop Surg Res.* 2016;11:59.