

E-ISSN: 2395-1958  
P-ISSN: 2706-6630  
IJOS 2022; 8(1): 33-36  
© 2022 IJOS  
[www.orthopaper.com](http://www.orthopaper.com)  
Received: 19-10-2021  
Accepted: 21-12-2021

**Dr. Rushi Solanki**  
Department of Orthopaedics,  
Gujarat Adani Institute of  
Medical Sciences, Bhuj, Gujarat,  
India

**Dr. Kelvinkumar Bhagvanjibhai Sureja**  
Assistant Professor, Department  
of Orthopaedics, Gujarat Adani  
Institute of Medical Sciences,  
Bhuj, Gujarat, India

**Dr. Monil Patel**  
Department of Orthopaedics,  
Gujarat Adani Institute of  
Medical Sciences, Bhuj, Gujarat,  
India

**Dr. Parth Vasantlal Rathod**  
Department of Orthopaedics,  
Gujarat Adani Institute of  
Medical Sciences, Bhuj, Gujarat,  
India

**Corresponding Author:**  
**Dr. Kelvinkumar Bhagvanjibhai Sureja**  
Assistant Professor, Department  
of Orthopaedics, Gujarat Adani  
Institute of Medical Sciences,  
Bhuj, Gujarat, India

## Operative outcomes of decompression in degenerative lumbar canal stenosis

**Dr. Rushi Solanki, Dr. Kelvinkumar Bhagvanjibhai Sureja, Dr. Monil Patel and Dr. Parth Vasantlal Rathod**

DOI: <https://doi.org/10.22271/ortho.2022.v8.i1a.2987>

### Abstract

**Background:** Spinal canal stenosis is a condition in which the spinal cord and the nerve roots are compressed by a number of pathologic factors, leading to symptoms such as pain, numbness, and weakness. This study was undertaken to evaluate clinical, functional and radiological outcomes of surgical decompression in spinal canal stenosis.

**Material and Method:** We have included 26 adult patients with lumbar spinal canal stenosis in this prospective study who have not improved after conservative management for minimum 6 weeks. All the patients underwent standard open decompression using posterior midline approach. Patients were followed up at 6 weeks, 3 months, 6 months, and 1 year, they were assessed clinically and functionally using VAS score and ODI score.

**Results:** In this study total 26 patients, out of which, 14(54%) were females and 12(46%) were males with an average age of 58.08 years. VAS of back pain improved from 2.85 on admission to 1.08 on final follow-up and leg pain from 8.00 on admission to 1.73 on final follow-up and ODI from 63.69 on admission to 14.54 on final follow-up.

**Conclusion:** Decompression surgery is the gold standard treatment for central or lateral recess lumbar stenosis when conservative treatment fails as it provides significant clinical as well as functional improvement in term of VAS score and Oswestry Disability Index.

**Keywords:** Lumbar spinal stenosis, decompression, VAS score, Oswestry Disability Index

### Introduction

Spinal canal stenosis is a condition in which the spinal cord and the nerve roots are compressed by a number of pathologic factors, leading to symptoms such as pain, numbness, and weakness. This condition affects many individuals, especially elderly population and can have a strong impact on activities of daily living, social aspects, physical stress, and the emotional status of a patient.

The upper neck (cervical) and lower back (lumbar) areas most frequently are affected, although the thoracic spine also can be compressed most frequently by a disk herniation. Three different anatomical sites in the spine can be affected by spinal stenosis. First, the central canal, which houses the spinal cord, can be narrowed in an anterior-posterior dimension, leading to compression of neural elements and reduction of blood supply to the spinal cord in the cervical area and the cauda equine in the lumbar area. Secondly, the neural foramina, which are openings through which the nerve roots exit the spinal cord, can be compressed as a result of disk herniation, hypertrophy of the facet joints and ligaments, or unstable slippage of one vertebral body relative to the level below. Lastly, the lateral recess, which is seen in the lumbar spine only and is defined as the area along the pedicle that a nerve root enters just before its exit through the neural foramen, can be compressed from a facet joint hypertrophy<sup>[1, 2, 3]</sup>. Depending on the level of the spine affected, each type of compression can lead to different symptoms that warrant a particular treatment modality.

Degenerative Lumbar Spinal Stenosis can be treated by both conservatively as well as surgically. The objectives of non-surgical treatment are to alleviate pain and improve function. The most effective non-surgical treatment is a comprehensive combination of anti-inflammatory drugs, physical therapy and conditioning, and epidural injections.

Non-steroidal anti-inflammatory drugs (NSAIDs) and narcotic analgesics may temporarily alleviate pain, but their role is limited due to potential adverse effects, especially in the elderly population. Physical therapy was shown to improve physical function score on the Short Form-36 Health Survey at two years. In a subcategory of the SPORT study, results showed that physical therapy used in the first six weeks of enrolment was associated with a reduced requirement of surgical management. Although epidural injections of local anaesthetic have been shown to improve pain and function in Lumbar Spinal Stenosis, these benefits seem to be shortlived [4].

Operative treatment is indicated for progressive disabling pain that has failed non-operative management, and/or progressive neurological deficits. The surgical procedure depends upon the location and character of the stenosis. Decision-making in order to obtain a good surgical result is based on a careful clinical assessment of motor weakness or radicular symptoms along with specific nerve root distribution affection corresponding with the imaging location of central or lateral recess and foramen compression. The aim of the operation is to improve quality of life. There are several types of decompression surgery like laminectomy, laminotomy, foraminotomy, laminoplasty and discectomy. It can be performed by various operative techniques like Conventional open decompression, Microsurgical Tubular, or Endoscopic decompression. Although the conventional open techniques of decompression remain the gold standard of treatment, problems with paraspinal musculature denervation and resultant lumbar instability have focused attention on less invasive techniques. We have studied 26 individuals sustaining degenerative lumbar spinal stenosis treated with conventional open decompression by laminectomy and assessed clinical, radiological and functional results of the surgery.

**Material and Method**

We have done a prospective study of 26 patients with lumbar spinal canal stenosis operated during the period of November 2019 to August 2021 at GK General Hospital, Bhuj, after applying inclusion and exclusion criteria. We have included patients with age more than 40 years who were clinically and radiologically diagnosed cases of degenerative lumbar canal stenosis and not improved after conservative management for minimum 6 weeks. We have excluded Patients having mechanical and radiological instability, any previous surgical intervention for spine and stenosis due to Trauma, Malignancy and Infection.

All patients were evaluated clinically for their symptoms and detailed neurological assessment was done. Visual Analogue Scale (VAS) Score for back pain and leg pain and Oswestry Disability Index (ODI) were assessed. Radiological evaluation, in form of X-ray lumbo-sacral spine anteroposterior and lateral views (flexion and extension) and MRI of lumbar spine with whole spine screening, were done. After taking written and informed spine surgery consent, all patients were operated under general anesthesia, in prone position on a radiolucent table. Surgical field was prepared in sterile fashion after conforming appropriate level under fluoroscopic guidance. Decompression done by open technique using standard posterior midline approach. All the facetal joints were preserved along with the capsule. Closure of the wound was done in layers with negative pressure drain and sterile dressing kept. Patients were advised active mobilization of both lower limbs from the 1<sup>st</sup> post-operative

day and also allowed assisted back support sitting and standing under supervision. Urinary catheter clamping was started on the next day and once the patient was confident with bladder sensation catheter removal was done. Stitch line dressing was done on 2<sup>nd</sup> postoperative day. Drain was kept till 2 days and intravenous antibiotic coverage was continued for 48 hours. Patients were discharged on an average 3-4 post-operative days and suture removal was done 14-21 days post-surgery. Patients were followed up at 6 weeks, 3 months, 6 months, and 1 year. At each follow-up clinical assessment was done in terms of neurological improvement, VAS score and ODI score.

**Results**

Ours is the prospective study of 26 patients (12 male and 13 female) with mean age of 58.08. Out of 26 patients, 19 (73.07%) patients had an involvement of single vertebral level and 7 (26.93%) had an involvement of two vertebral level.

**Level of the stenosis (Vertebral level)**

**Table 1:** Level of Stenosis

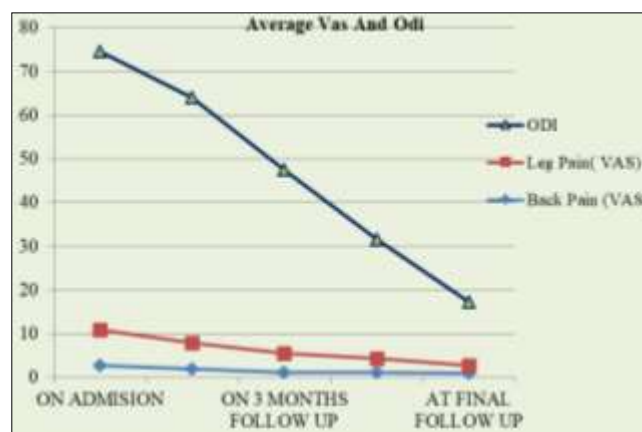
Level of stenosis	Number of patients	Percentage
L3-L4	3	11.54%
L3-L5	7	26.92%
L4-L5	11	42.31%
L5-S1	5	19.23%
<b>Total</b>	<b>26</b>	<b>100.00%</b>

On admission average VAS of back pain is 2.85 and leg pain is 8.00 and average ODI score is 63.69. In our study, all patients had stable radiologically lumbar spine, hence leg pain was more than back pain. Average operative time was 108.65 minutes; average blood loss was 114.23 ml and mean hospital stay was 5.84 days.

**Vas and ODI on follow-Ups**

**Table 2:** Average VAS score and ODI on follow up

	Vas		Odi
	Back Pain	Leg Pain	
On 6 Week Follow Up	2.00	5.96	56.08
On 3 Months Follow Up	1.19	4.30	42.04
On 6 Months Follow Up	1.12	3.26	27.31
At Final Follow Up	1.08	1.73	14.54



**Chart 1:** Average VAS score and ODI on admission and follow up

In our study, only 1 patient had a superficial infection of stitch line which was managed by regular dressing and antibiotics. Another 2 patients had dural tear intraoperatively which was

repaired by silk 4-0 and fat graft with water tight closure of wound.

## Discussion

Degenerative lumbar stenosis is a common cause of disabling back and lower extremity pain among older persons. The process usually begins with degeneration of the intervertebral disks and facet joints, resulting in narrowing of the spinal canal and neural foramina. Associated factors may include a developmentally narrow spinal canal and degenerative spinal instability. Several surgical techniques for lumbar spine decompression have been described over last few decades. The surgical aim of treatment for symptomatic lumbar canal stenosis is relief of symptoms by adequate neural decompression while preserving much of the anatomy and the biomechanical function of the lumbar spine.

Traditional treatment of spinal canal stenosis has involved wide laminectomy and undercutting of the medial facet with foraminotomy. The frequent surgical failures have been attributed to local tissue trauma and to postoperative spinal instability which has led to a dramatic increase in lumbar fusion surgery<sup>[5]</sup>. MR imaging is considered the study of choice in the diagnosis of spinal canal stenosis because disc, soft tissue, bony changes, and intra-theccal content are visualized. No imaging technology can diagnose spinal canal stenosis without a clinical history that is consistent with the diagnosis. Spinal imaging may appear worse than the patient's symptoms and do not necessarily correlate with clinical findings.

In this study out of total 26 patients, the maximum patients belong to the age group of 51-60 with an average age of 58.08 years. Out of 26 patients, 14(54%) were females and 12(46%) were males. Pearson *et al.* conducted a randomized control trial in 2013 and concluded that out of 607 patients, 31% were male and 69% were female population who underwent decompression surgery for lumbar spinal stenosis which matches with our study also had more females affected by degenerative lumbar canal stenosis than males<sup>[6]</sup>. Most commonly involved level was L4-L5 followed by L3-L4 and L5-S1 level. Donald R Murphy *et al.* reported the same involvement of level in their prospective observational cohort study<sup>[7]</sup>.

In our study, all patients were operated using conventional open operative technique using posterior midline approach with decompression done by laminectomy. The gold standard treatment for symptomatic lumbar stenosis refractory to conservative management is a facet-preserving laminectomy. New techniques of posterior decompression have been developed to preserve spinal integrity and to minimize tissue damage by limiting bony decompression and avoiding removal of the midline structures (i.e. spinous process, vertebral arch and interspinous and supraspinous ligaments). Ulf S Nerland *et al.* conducted a prospective multicenter observational study in 2015 of minimally invasive decompression versus open laminectomy for central stenosis of lumbar spine and concluded that at one year the effectiveness of microdecompression is equivalent to laminectomy in the surgical treatment of central stenosis of the lumbar spine<sup>[8]</sup>. Qingpeng song *et al.* conducted a retrospective study of full endoscopic decompression versus open decompression for lumbar spinal stenosis a 3 year follow up study in 2021 and concluded that full endoscopic lumbar decompression surgery had the same efficacy as open decompression surgery for lumbar spinal stenosis treatment. Full-endoscopic lumbar decompression surgery had the

advantages of minimal invasiveness, less surgical trauma, rapid recovery, and lower risk of degeneration of adjacent segments compared with that of open decompression surgery. But long term follow up in patient's clinical and functional outcome are same in both groups<sup>[9]</sup>.

In our study, analysis of clinical as well as functional outcome was based on VAS for pain and ODI for disability. VAS of back pain improved from 2.85 on admission to 1.08 on final follow-up and leg pain from 8.00 on admission to 1.73 on final follow-up and ODI from 63.69 on admission to 14.54 on final follow-up. Kaveh Haddadi *et al.* reported improvement of VAS from 8.22 pre operatively to 1.6 at 12 month follow up and of ODI from 75 pre operatively to 28 at 12month follow-up<sup>[10]</sup>. These findings were similar to the findings noted in our study.

**Table 3:** Comparison of our study with Kaveh Haddadi *et al* study in term of VAS and ODI

Average VAS	Pre-op	At Final follow up
Our study	8.00	1.73
Kaveh Haddadi <i>et al.</i>	8.22	1.6
Average ODI	Pre-op	At Final follow up
Our study	63.69	14.53
Kaveh Haddadi <i>et al.</i>	75	28

Weinstein *et al.* conducted a multicenter prospective study in the SPORT (Spinal Patient Outcomes Research Trial) group and concluded that in the group "according to the treatment implemented", the operated patients showed significant improvement in pain, function, and satisfaction when compared to the non-operated patients as same results are achieved in our study also<sup>[11]</sup>. Limitations of our study are small sample size, shorter duration of follow ups, no comparison groups for other methods and also our inclusion criteria were strict as we have not included those patients having mechanical or spinal instability. Strengths are study is prospective and done in a rural hospital with limited resources by only one surgeon so less chances of bias and all patients had complete follow ups.

## Conclusion

We have concluded that degenerative lumbar spinal stenosis is common among females as compared to males, mostly in 6<sup>th</sup> decade of life, at L4-5 level. Decompression surgery is the gold standard for treatment of central or lateral recess lumbar stenosis when conservative treatment fails as it provides significant clinical as well as functional improvement in term of VAS score and Oswerty Disability Index.

## References

- Tang C, Moser FG, Reveille J, Bruckel J, Weisman MH. A Review of Cauda Equina Syndrome in Ankylosing Spondylitis: Challenges in Diagnosis, Management, and Pathogenesis. *J. Rheumatol*, 2019, Apr 01.
- Glassman DM, Magnusson E, Agel J, Bellabarba C, Bransford RJ. The impact of stenosis and translation on spinal cord injuries in traumatic cervical facet dislocations. *Spine J*. 2019 Apr;19(4):687-694.
- Bindal S, Bindal SK, Bindal M, Bindal AK. Noninstrumented Lumbar Fusion with Bone Morphogenetic Proteins for Spinal Stenosis with Spondylolisthesis in the Elderly. *World Neurosurg*, 2019, Mar 21.
- Covaro A, Vilà-Canet G, García de Frutos A, Ubierna MT, Ciccolo F, Caceres E. Management of degenerative

- lumbar spinal stenosis: an evidence-based review article. *EFORT Open Rev.* 2016;1:267-274.
5. Lipson SJ. Spinal-fusion surgery-advances and concerns. *N Engl J Med* 2004;350(7):643-644.
  6. Pearson AM, Lurie JD, Tosteson TD, Zhao W, Abdu W, Weinstein JN. Who should undergo surgery for degenerative spondylolisthesis? Treatment effect predictors in Sport. *Spine (Phila Pa 1976)*. 2013;38:1799-1811.
  7. Murphy D, Hurwitz E, Gregory A, Clary R. A non-surgical approach to the management of lumbar spinal stenosis: a prospective observational cohort study. *BMC Musculoskelet Disord.* 2006;7:16. doi: 10.1186/1471-2474-7-16.
  8. Nerland US, Jakola AS, Solheim O, Weber C, Rao V, Lønne G, *et al.* Minimally invasive decompression versus open laminectomy for central stenosis of the lumbar spine: pragmatic comparative effectiveness study. *BMJ.* 2015 Apr;350:h1603.
  9. Song Q, Zhu B, Zhao W, Liang C, Hai B, Liu X. Full-Endoscopic Lumbar Decompression versus Open Decompression and Fusion Surgery for the Lumbar Spinal Stenosis: A 3-Year Follow-Up Study. *J Pain Res.* 2021 May;14:1331-1338.
  10. Haddadi K, Ganjeh Qazvini HR. Outcome after surgery of lumbar spinal stenosis: A randomized comparison of bilateral laminotomy, trumpet laminectomy, and conventional laminectomy. *Front Surg.* 2016;3:19.
  11. Weinstein JN, Tosteson TD, Lurie JD, Tosteson ANA, Blond E, Hanscom B, *et al.* Surgical versus Nonsurgical Therapy for Lumbar Spinal Stenosis. *N Engl J Med.* 2008;358(8):794-810.