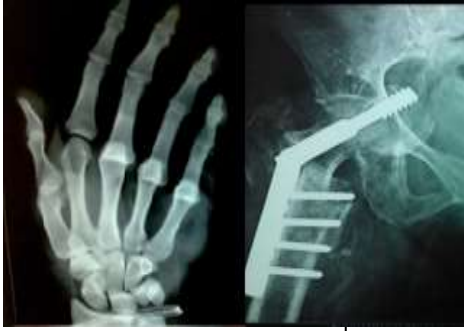



International Journal of Orthopaedics Sciences

E-ISSN: 2395-1958
P-ISSN: 2706-6630
IJOS 2021; 7(4): 677-681
© 2021 IJOS
www.orthopaper.com
Received: 11-06-2021
Accepted: 17-07-2021

Dr. Purushotham K
Professor and Head of the
Department, Department of
Orthopedics Surgery, Dr. B.R.
Ambedkar Medical College and
Hospital, Bangalore, Karnataka,
India

Dr. Krishna Murthy T
Assistant Professor, Department
of Orthopedics surgery, Dr. B.R.
Ambedkar Medical College and
Hospital, Bangalore, Karnataka,
India

Dr. Dhanunjaya Reddy
Senior Resident, Department of
Orthopedics Surgery, Dr. B.R.
Ambedkar Medical College and
Hospital, Bangalore, Karnataka,
India

Dr. Abhishek Ghavalkar
Junior Resident, Department of
Orthopedics Surgery, Dr. B.R.
Ambedkar Medical College and
Hospital, Bangalore, Karnataka,
India

Corresponding Author:
Dr. Krishna Murthy T
Assistant Professor, Department
of Orthopedics surgery, Dr. B.R.
Ambedkar Medical College and
Hospital, Bangalore, Karnataka,
India

Outcome of intertrochanteric fractures in elderly patients having comorbidities treated with proximal femoral nail: A single center observational study

Dr. Purushotham K, Dr. Krishna Murthy T, Dr. Dhanunjaya Reddy and Dr. Abhishek Ghavalkar

DOI: <https://doi.org/10.22271/ortho.2021.v7.i4j.2950>

Abstract

Background and Objectives: Intertrochanteric fractures is one of the most frequently operated injuries in the elderly. The incidence of these fractures increases with increasing age. Many studies show certain parameters have an adverse effect on functional outcome and quality of life in patients with intertrochanteric fractures treated surgically. However, very few studies have evaluated the outcome of patients treated surgically having comorbidities such as hypertension, diabetes mellitus, anaemia and asthma.

Methods: We conducted a prospective observational study of 30 patients aged 65 years or above, with at least one comorbidity (hypertension, diabetes mellitus, anaemia, asthma and cardiac dysfunction) who underwent PFN for closed intertrochanteric fractures at our hospital. Radiographs were reviewed at 1, 3, and 6 months or till fracture union, whichever came first.

Result: In our study, 33% of patients (10) belonged to ASA grade 2, 47% of patients (14) belonged to grade 3, and 20% of patients (6) belonged to grade 4. In our study, 14 patients (46.6%) had one comorbidity, while 16 patients (53.4%) had two or more comorbidities. Harris Hip Score at the end of 3 months was 73.8 and at the end of 6 months was 84.3. Five patients had excellent, 17 patients had good, 7 patients had fair, and 1 patient had a poor functional outcome. Using Cox Regression analysis for hazard ratio of poor post-surgical Hip scores, we found a significant correlation between functional outcome and age of surgery, number of comorbidities, anaemia and length of hospital stay.

Conclusion: Proximal femoral nail is a good choice for internal fixation of intertrochanteric fractures. The comorbidities and their correction should be taken into consideration before and after the operative procedure.

Keywords: Proximal femoral nail, co-morbidities, intertrochanteric fracture, Harris hip score

Introduction

Intertrochanteric fractures are the most common subtype of hip fractures undergoing surgery. They also carry high morbidity and mortality [1]. The incidence of these fractures increases with an increase in age [2]. It is estimated that the incidence of hip fractures worldwide will double by 2025 and quadruple by 2050 [3]. The complications associated with proximal femur fractures include deep vein thrombosis, malunion, non-union, soft tissue envelope damage, post-surgery infection, pulmonary embolism, neurological and cardiac complications [4]. Prompt diagnosis, thorough preoperative assessment of the bony and soft tissue trauma, adequate soft tissue monitoring and resuscitation, anatomic reduction and sound fixation allowing early joint movement and rehabilitation often over 6 months post-injury are mandatory for good clinical results [5].

The goal of treatment of these fractures is closed or open reduction and stable fixation to eventually restore and preserve normal hip function [6]. This can be accomplished by anatomical restoration of bony surfaces, maintaining the mechanical axis, and preserving a functional pain-free range of hip motion and mobilization as early as possible [7].

The advantages of operative treatment are decreased hospitalization, reduced complications of prolonged recumbency, early mobilization and weight-bearing. Walking exercise is possible with new implant and fixation technology, and it helps to achieve anatomical reduction [8].

Currently, intertrochanteric femur fractures may be repaired with either a sliding hip screw or a proximal femoral nail (PFN).

The advantage of PFN is that it is more efficient in load transferring than sliding hip screw, maintenance of controlled fracture impaction, short operating time, less soft tissue injury, less chance of screw cut out, less limb length shortening and early mobilization [9]. It also allows early fracture union and weight-bearing [10].

American Society of Anaesthesiology grade (ASA) 3 or 4, haemoglobin levels of less than 12gm/dL, erythrocyte sedimentation rate of more than 80 per hour have been associated with adverse functional outcome and quality of life in patients operated for intertrochanteric fractures [11, 12, 13]. However, very few studies have evaluated the outcome of surgically treated patients with intertrochanter fractures with comorbidities such as hypertension, diabetes mellitus (DM), anaemia, asthma, and cardiac dysfunction.

This study aims to determine the influence of comorbidities in elderly patients on the functional outcome and quality of life in patients with intertrochanteric fractures surgically treated with PFN.

Materials and methods

We conducted a prospective observational study in a tertiary hospital. The study was conducted between December 2019 and June 2021. A total of 30 patients aged 65 years or above, with at least one comorbidity (hypertension, DM, anaemia, asthma and cardiac dysfunction) who underwent PFN for closed intertrochanteric fractures at our hospital were included in this study. Informed written consent was obtained from the patients for inclusion in the study if they were found to fulfil the criteria. A detailed history was obtained, physical examination and relevant investigations were done in the same hospital. Patients who refused surgery, who did not give consent for inclusion in the study, those with open fractures, neurovascular deficit or pre-existing deformity of the hip on the same side of fracture were excluded. Evaluation of the appropriateness of an intramedullary device and estimation of nail diameter, lag screw angle, and length were performed using preoperative radiographs and templates. If there was a severe bowing of the affected femur or other associated deformity, the use of an intramedullary device was avoided. Patient data were stored and analyzed using Microsoft Excel.

A single observer reviewed all patients. Radiographs were reviewed at 1,3 and 6 months or till fracture union, whichever came first. Bony union was defined in both clinical and radiological means as when three out of four cortices healed. The functional outcome of the patients was evaluated with Harris hip score. During every review, the patient was evaluated, and a score was given from 0 to 100. Those who score on and above 90 falls in the 'excellent' category, and those below 70 are termed 'poor' outcome group. The other two categories were 'good' and 'satisfactory' if these scores were 80-89 and 70-79 respectively. The comorbidities documented were also evaluated with the help of the

physician, and appropriate treatment was given.

Descriptive statistics were presented as means, minimums and maximums. Spearman's correlation was used to investigate the association between age and deviation. Mann-Whitney U test was used to demonstrate the association between sex and deviation.

Results

The study involved 30 confirmed cases of elderly patients with intertrochanteric fractures with comorbidities from December 2019 to June 2021. All the cases were treated with intramedullary fixation using proximal femoral nail. The analysis of the patient data, intraoperative data, and the postoperative outcome are as follows.

The average age was 68.87 years (Figure 1). For our study, the age groups were divided into 2 groups of "age of 75 years or below" and "age above 75 years" to try and observe whether age as an independent factor affects the functional outcome of intertrochanteric fractures treated with PFN.

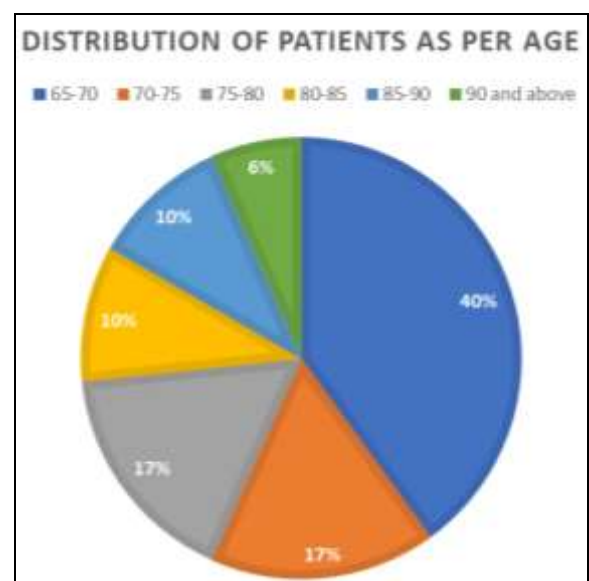


Fig 1: Age distribution among the study population.

Domestic fall and road traffic accidents were the modes of injury in all the patients. Most of the patients with domestic falls were older or had osteoporosis. In our study, 24 patients (80%) had the fracture due to domestic fall and only 6 patients (20%) had presented with a road traffic accident (RTA). The grade of osteoporosis was also calculated using the trabecular pattern of proximal femur on plain x-ray film in AP view using Singh's Index. It was found that most of our patients (13, 43%) had category III osteoporosis.

All the fractures were classified as per Orthopaedic Trauma Association (OTA) Classification System (Figure 2). The average operating time was 65mins (32min-95min) after anaesthesia. The average blood loss was 50-150 ml, and blood loss was more in cases with open reduction than closed reduction.

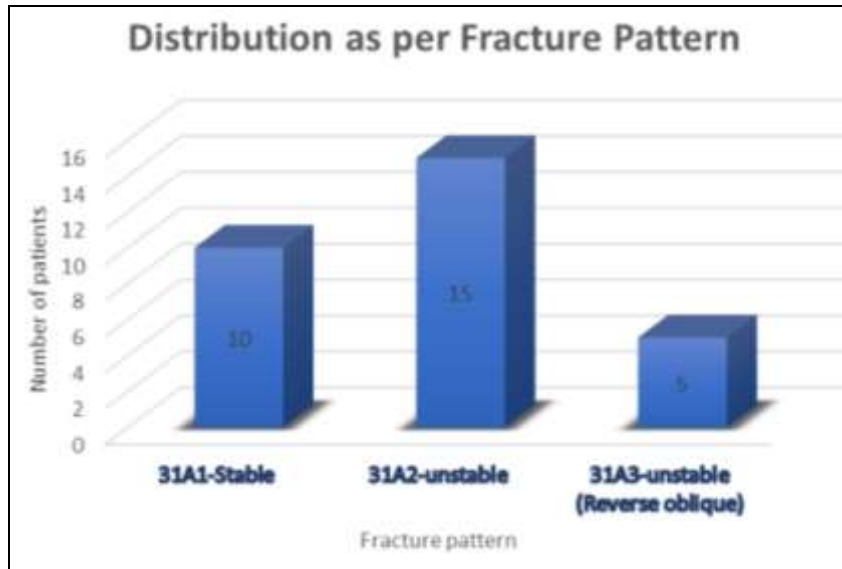


Fig 2: Distribution of patients based on the type of fracture (OTA classification)

All patients were evaluated as per the American Society of Anaesthesiologists Criteria and grouped accordingly (Figure 3).

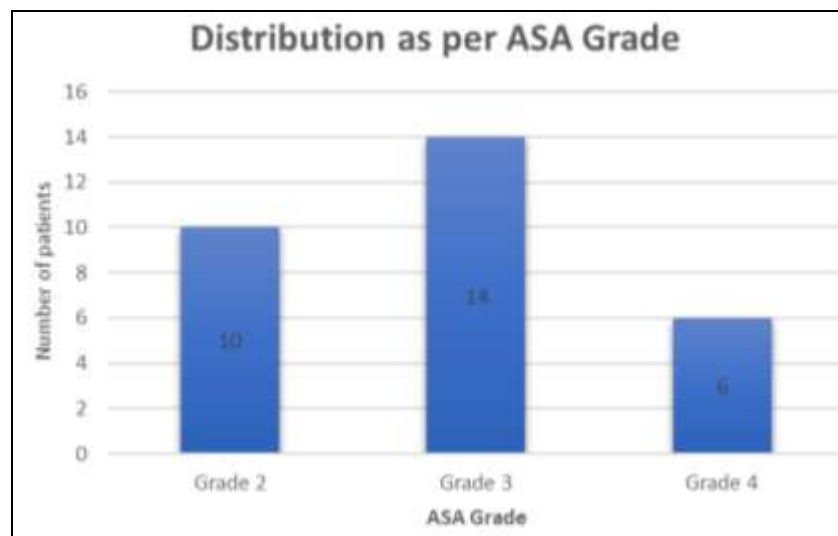


Fig 3: Distribution of patients as per ASA grade.

The average union time was 14.6 weeks. Union was delayed in all type 31A3 cases (17- 18 weeks). Harris hip score evaluation was done during every follow-up period. At 3 months follow up, the average score was 73.8(range 66-81),

and at 6 months, it was 84.3(range 72-94). In our study, we saw 5 patients with excellent, 17 patients with Good, 7 patients with Fair and 1 patient with poor functional outcome.

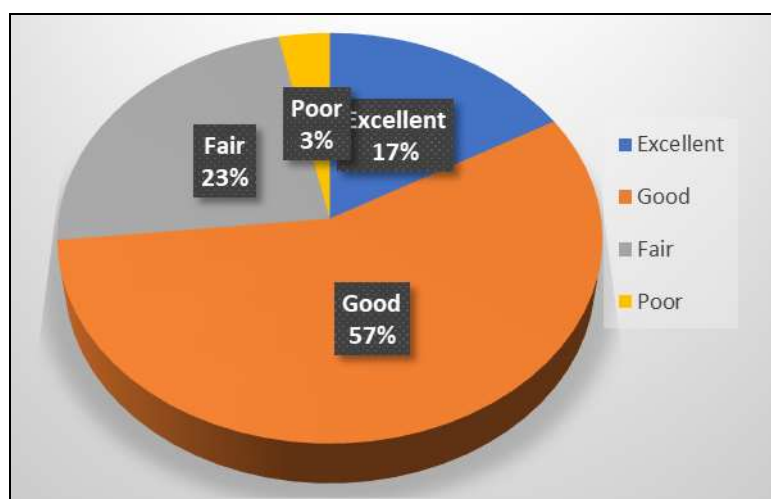


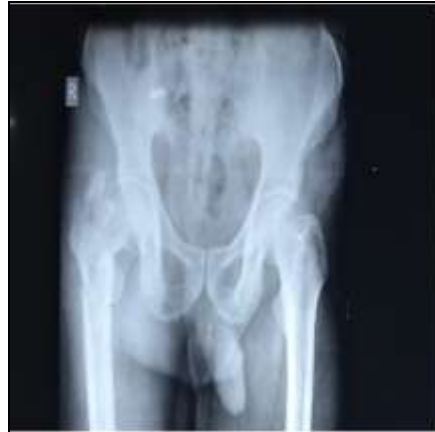Fig 4: Final functional outcome

Using Cox Regression analysis for hazard ratio of poor post-surgical Hip Scores, we found a significant correlation between functional outcome and age of surgery, the number

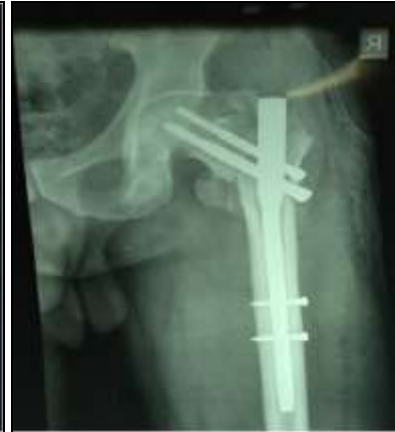of comorbidities, anaemia and length of hospital stay (Table 1).

Table 1: Cox Regression analysis for hazard ratio of poor post-surgical Hip Scores

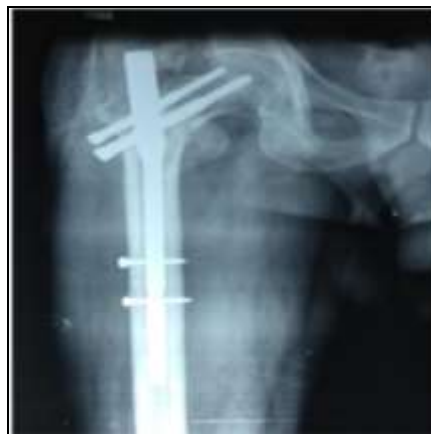Variable	Hazard Ratio*	CI 95%	p-value
Male sex	1.21	0.67-2.19	0.52
Age at surgery > 75 years	2.54	1.51-4.25	<0.001
Comorbidities > 2 types	3.32	1.93-5.72	<0.001
Type of fracture	1.40	0.81-2.44	0.231
Duration of fracture > 9 Days	0.50	0.30-0.82	0.146
Anemia	2.35	1.44-3.85	<0.001



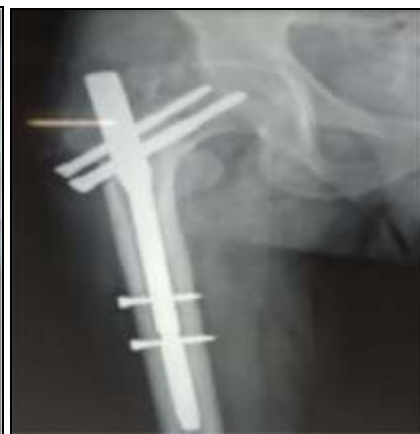X-ray 1: Pre-op



X-ray 2: Immediate Post-op



X-ray 3: One month follow-up



X-ray 4: Six months follow-up

Discussion

The increasing incidence of proximal femoral fractures, especially inter-trochanteric fractures, has been attributed to the increasing life expectancy in the general population [14]. Hip fracture incidence in elderly people in South-East Asia is expected to increase from 600,000 to 3,250,000 [14]. Most of the population with hip fractures are elderly with one or more comorbidities. As age advances, there is increased gait instability and a decrease in balance control, affecting postoperative rehabilitation and functional outcome [15].

The PFN is an effective intramedullary load-sharing device. Biomechanically PFN is stiffer. It has a shorter moment arm, i.e., from the tip of the lag screw to the centre of the femoral canal. In contrast, the DHS has a longer moment arm and hence undergoes significant stress on weight-bearing and hence higher incidence of Lag screw cut out and varus malunion [2]. The larger proximal diameter (15 mm) of the PFN gives additional stiffness to the nail. It has also been well documented that the PFN being a load-sharing device helps in

earlier mobilization and rehabilitation compared to other osteosynthesis devices available in the market.

In our study, it was seen that those patients above 75 years of age had significantly poorer functional outcome ($p < 0.05$, CI = 95) compared to those below the age of 75. This finding is consistent with the findings of Shebubakar *et al.* [14], who found age to be an independent risk factor in poor functional outcomes of elderly patients with hip fractures. In a study of functional outcome, quality of life and mortality for proximal femoral fracture by the Karolinksi Institute [15], it was found that patients above 75 years of age had poor rehabilitation, activities of daily living and quality of life as compared to those who were below 75 years of age. This can probably be explained by the fact that balance and gait are a complex interaction between the cardio-respiratory, the musculoskeletal and sensory functionality. With increasing age, the cardio-respiratory reserve decreases, the functionality of the musculoskeletal system associated with osteoporosis decreases and the sensory system response time increases,

which leads to poor rehabilitation and hence poor functional outcome.

Our study found that irrespective of the fracture pattern, all patients with ASA grade IV had a poor functional outcome (significant $p < 0.05$, CI:95%). This corresponds to the findings by Roche *et al.* [16], Donegan *et al.* [17]. We found that patients with two or more comorbidities have an increased risk of poor Harris hip score after surgery.

We find that following are the independent risk factors in elderly patients with comorbidities: age at the time of surgery, number of comorbidities, anaemia, and length of hospital stay independent of the method of fixation, the surgical procedure, the postoperative rehabilitation, and follow up.

PFN can be considered the most judicious and rational method for internal fixation of intertrochanteric fractures, especially the unstable type. The reasons to support this are that PFN can be used in all configurations of proximal femoral fractures. Closed reduction preserves the fracture hematoma and yields early healing and early union. It can be used with equally good results in all grades of osteoporosis, is a quick procedure with a small incision and significantly less blood loss. It gives good results even with the non-anatomical reduction, and nail entry is at the tip of the greater trochanter or lateral to it as medial entry will cause the distraction. Complications are minimal and comparable with other fracture systems.

Conclusion

Hence, we conclude that while PFN is a good choice for internal fixation of intertrochanteric fractures, the comorbidities and their correction should be considered before and after the operative procedure. A dedicated geriatric programme with the combined efforts of the physician, a geriatric specialist, an orthopaedic surgeon and a physiotherapist may go a long way in increasing the functional outcome and perhaps decreasing the rate of mortality as well in intertrochanteric fractures of elderly patients with comorbidities treated with PFN.

Conflict of interest: None to declare

Funding: No funding received

Acknowledgement: None

References

- Marks R. Hip fracture epidemiological trends, outcomes, and risk factors, 1970-2009. *International journal of general medicine* 2010;3:1-17.
- Kumar R, Singh RN, Singh BN. Comparative prospective study of proximal femoral nail and dynamic hip screw in treatment of intertrochanteric fracture femur. *J Clin Orthop Trauma* 2012;3(1):28-36. doi:10.1016/j.jcot.2011.12.001.
- Gulberg *et al.* Management of fractures in severely osteoporotic bones.
- Dorotka R, Schoechtner H, Buchinger W. The influence of immediate surgical treatment of proximal femoral fractures on mortality and quality of life. *J Bone Joint Surg Br* 2003;85(8):1107-13.
- Kyle RF, Gustilo RB, Premer RF. Analysis of six hundred and twenty two cases of intertrochanteric fractures of the femur. *J Bone Joint Surg Am* 1979;61:216-21.
- Kulkarni GS, Limaye R, Kulkarni M, Kulkarni S. Current concept review Intertrochanteric fractures. *Indian J Orthop* 2006;40:16-23.
- Bjørgul K, Reikerås O. Outcome after treatment of complications of Gamma nailing: a prospective study of 554 trochanteric fractures. *Acta Orthop* 2007;78(2):231-5.
- Domingo LJ, Cecilia D, Herrera A, Resines C. Trochanteric fractures treated with a proximal femoral nail. *Int Orthop* 2001;25:298-301.
- Simmermacher RK, Bosch AM, Van der Werken C. The AO/ASIF-proximal femoral nail (PFN): A new device for the treatment of unstable proximal femoral fractures. *Injury* 1999;30:327-32.
- Long-term radiographic complications following treatment of unstable intertrochanteric femoral fractures with the proximal femoral nail and effects on functional results. *Acta Orthop Traumatol Turc* 2009;43(6):457-63.
- Astrid Lunde, Grethe Tell S, Alma Pedersen B, Thomas Scheike H, Ellen M, Apalset, *et al.* The Role of Comorbidity in Mortality After Hip Fracture: A Nationwide Norwegian Study of 38,126. Women With Hip Fracture Matched to a General-Population Comparison Cohort, *American Journal of Epidemiology*, 2019;188(2):398-407.
- Menzies IB, Mendelson DA, Kates SL, Friedman SM. The impact of comorbidity on perioperative outcomes of hip fractures in a geriatric fracture model. *Geriatr Orthop Surg Rehabil* 2012;3(3):129-139, 107.
- Edelmuth SVCL, Sorio GN, Sprovieri FAA, Gali JC, Peron SF. Comorbidities, clinical interurrences, and factors associated with mortality in elderly patients admitted for a hip fracture. *Rev Bras Ortop.* 2018;53(5):543-551. Published 2018 Aug 2. doi:10.1016/j.rboe.2018.07.014
- Shebubakar, Lukman, Hutagalung, Errol, Sapardan, Subroto *et al.* Effects of older age and multiple comorbidities on functional outcome after partial hip replacement surgery for hip fractures. *Acta medica Indonesiana* 2009;41:195-9.
- Gadegone WM, Salphale YS. Proximal femoral nail - an analysis of 100 cases of proximal femoral fractures with an average follow up of 1 year. *Int Orthop.* 2007;31(3):403-408.
- Roche JJ, Wenn RT, Sahota O, Moran CG. Effect of comorbidities and postoperative complications on mortality after hip fracture in elderly people: prospective observational cohort study. *BMJ* 2005;331(7529):1374.
- Derek Donegan *et al.* Use of Medical Comorbidities to Predict Complications After Hip Fracture Surgery in the Elderly, *The Journal of Bone & Joint Surgery* 92(4):807-813.