



E-ISSN: 2395-1958
P-ISSN: 2706-6630
IJOS 2021; 7(4): 672-676
© 2021 IJOS
www.orthopaper.com
Received: 08-06-2021
Accepted: 15-07-2021

Dr. Pramod B Itagi
Professor & Head, Department of
Orthopaedics, Mahadevappa
Rampure Medical College,
Kalaburagi, Karnataka, India

Dr. Anusha S Pattanshetty
Junior Resident, Department of
Orthopaedics, Mahadevappa
Rampure Medical College,
Kalaburagi, Karnataka, India

A comparative study of plate fixation versus titanium elastic nail in treatment of displaced midshaft clavicle fractures

Dr. Pramod B Itagi and Dr. Anusha S Pattanshetty

DOI: <https://doi.org/10.22271/ortho.2021.v7.i4j.2949>

Abstract

Background: In the last few decades, there has been an increasing trend towards operative treatment for displaced midshaft clavicular fractures. These fractures are managed by plate fixation and titanium elastic nailing system, but the optimal fixation method for these types of fractures remains a topic of debate. The aim of this study is to compare functional outcome of displaced midshaft clavicle fractures treated with locking compression plate and titanium elastic nail system and its associated complications.

Material and Method: 40 patients treated with plating and titanium elastic nailing system between October 2019 and March 2021 were analyzed. They were randomized in two groups (20 in plate group and 20 in titanium elastic system group). Clinical and radiological assessments were performed at the 6th week, 3rd and 6th month postoperatively. The functional outcome was assessed by Constant- Murley score. Both surgical techniques were compared in terms of radiological union, clinical functions and complications associated.

Result: Earlier union and functional outcome scores were better for the Titanium elastic nail system group than plating group ($p < 0.01$). The rate of complications was higher in the plate group compared with the Titanium elastic nail system group.

Conclusion: In treating displaced midshaft clavicle fractures Titanium elastic nailing system is superior to clavicular plating. Titanium elastic nailing system technique is safe, minimally invasive and has better functional outcome, faster union, fewer complication and cosmetically more acceptable than plating.

Keywords: Displaced midshaft clavicle fractures, Titanium elastic nailing system, Plate fixation, Constant-Murley score

Introduction

Fractures of clavicle account for approximately 2.6% of all fractures and for 44% to 66% of fractures around the shoulder [1]. Midshaft fractures comprise 70% to 80% of all clavicular fractures where the compressive forces applied to the shoulder and the narrow cross section of the bone combine and result in bony failure; lateral fractures contribute 15% to 30% and medial fractures at 3% are relatively rare [2]. Open clavicular fractures are absolutely rare, found in only 0.1% to 1% of cases [2]. The rate of mid clavicular fractures is twice higher in men compared to women [2].

Midshaft clavicle fractures have traditionally been treated non operatively [3-5]. However displaced or comminuted fractures have a risk of symptomatic malunion, nonunion, and poor functional outcome with cosmetic deformity [6-8]. Recent studies have reported that there is 15% non-union rate in widely displaced midshaft fractures of clavicle treated nonoperatively [7]. Surgery is accepted as primary treatment for displaced mid-shaft clavicle fractures due to improved outcomes and a decreased rate of nonunion, symptomatic malunion compared with nonoperative treatment [7-9].

Operative treatment of displaced midshaft clavicle fractures can be achieved successfully using plates or intramedullary nailing [10-12]. Primary internal fixation of displaced, comminuted mid-shaft clavicle fractures leads to earlier return to function. When managed surgically both the options have better outcome than managed conservatively [13].

The purpose of this study is to compare functional outcome of displaced midshaft clavicle fractures treated with anatomically contoured locking compression plate and titanium elastic

Corresponding Author:
Dr. Pramod B Itagi
Professor & Head, Department of
Orthopaedics, Mahadevappa
Rampure Medical College,
Kalaburagi, Karnataka, India

nail system and its associated complications.

Materials and Methods

This study was conducted on 40 patients treated with plating and titanium elastic nailing system between October 2019 and March 2021 in Department of Orthopaedics, Mahadevappa Rampure Medical College, Kalaburagi. They were randomized in two groups (20 in plate group and 20 in titanium elastic nail system group). All patients with displaced midshaft clavicle fractures within the age group of 16-60 years and fractures with imminent skin perforation were included in this study. Pathological fractures, age less than 16 years, open fractures and medically unfit patients were excluded from the study. Anatomically contoured locking compression plate and titanium elastic nailing system were used for fracture fixation.

Surgical Technique for plating

After General anaesthesia, patients were operated in beach chair position. A folded towel was kept under the affected shoulder. The affected upper extremity was draped free to allow manipulation in an aseptic manner. About 7-9 cm incision was made just inferiorly to the clavicle centered over the fracture site. The skin, subcutaneous tissue and platysma were divided without undermining the edges. The overlying clavipectoral fascia and periosteum were divided next. The osseous ends were freed. Minimal soft tissue and periosteum was dissected. Fracture fragments were reduced and anatomically contoured locking compression plate was applied over the superior aspect of the clavicle and was fixed with locking screws/ cortical screws. A cortical lag screw was usually fixed across the fracture site in oblique fractures. Wound was closed in layers after ensuring hemostasis and sterile dressing was applied.

Surgical Technique for Titanium Elastic Nailing system

With similar position and draping methods as for plating, a small incision was made approximately 1cm lateral to the sternoclavicular joint. Titanium elastic intramedullary nail was introduced (the diameter varied from 2 to 2.5 mm depending on the width of the bone) after making entry using awl 1.5-2 cm lateral to the sternoclavicular joint. Before introduction, the original curvature of the small and flattened nail tip was straightened slightly to allow for better gliding in the small medullary canal. Closed reduction was performed using fluoroscopic guidance. Pointed reduction clamps were used either percutaneously or through small stab incision. If closed reduction couldn't be achieved, a small incision was taken directly over fracture site to perform open reduction. The nail was then advanced manually through fracture site and into lateral fragment until it was just medial to the acromioclavicular joint. Accurate maneuvering of the nail tip was necessary under fluoroscopic control to avoid penetration of the thin dorsal cortex. After reaching the end point, the fracture was compressed and the nail was cut close to the entry point to decrease soft tissue irritation, at the same time leaving sufficient length behind for easy extraction later on. Postoperatively patients were given a sling but were encouraged for early shoulder mobilization as tolerated, starting with pendular exercises from the 2nd day. After 2 weeks active range of movement exercises were started, however, overhead shoulder abduction was allowed only after 4 weeks. Activities of daily living were started afterwards, but those requiring lifting heavy objects were delayed until union was achieved. Patients underwent clinical and radiological evaluations at regular followup visits at the 6th week, 3rd and 6th months postoperatively to assess fracture healing, function of the arm and to record any complication. The functional outcome was assessed by Constant - Murley score at 6th month.

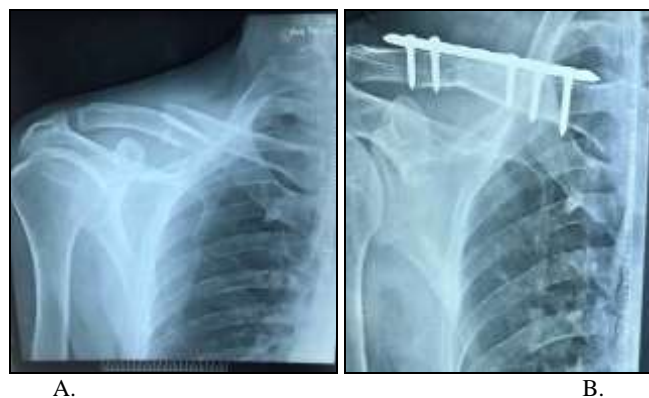

Fig 1: a) Preoperative radiograph of a 45 year old female. b) Follow up radiograph at 6th month

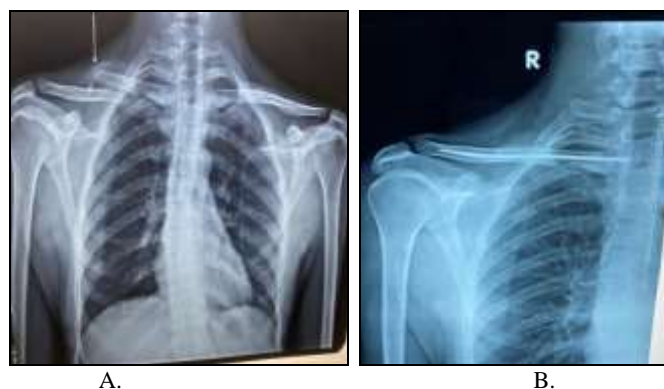

Fig 2: a) Preoperative radiograph of a 32 yr old manual labourer. b) Follow up radiograph at 6th month.

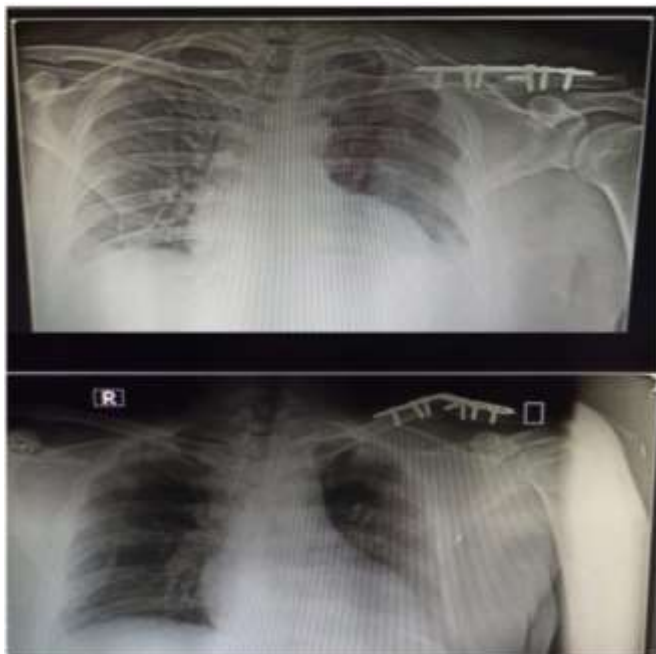


Fig 3a): Radiograph of a 45 yr male showing implant failure with delayed union

Results

This study consists of 40 patients with displaced midshaft fracture of the clavicle among which 20 patients underwent plate fixation (plating group) and 20 patients underwent titanium elastic intramedullary nail fixation (nailing group). There were 15 males and 5 females in plating group whereas nailing group had 16 males and 4 females. The Mean age for

plating group was 35.45±8.83 years and mean age for nailing group was 33.25±9.67 years (Table 1).

The mode of injury were uniformly distributed in both the groups with 42.5% of cases due to road traffic accident, 40% of cases due to self fall and 17.5% of cases were due to sports related injuries (Table 1).

Surgeries were performed at a mean of 2.65days ± 1.16 days after injury for the plate group and a mean of 2.87 ± 1.32 days after injury for the TENS group (Table 1). In 12 patients, a nail diameter of 2.5 mm was used, while in 8 patients the 2 mm nail was used.

In plating group, good union was seen at mean average of 12.30±2.34 weeks. In the nailing group, union was achieved with an average of 9.70±2.36 weeks and the difference was statistically significant with p<0.001. Union was early in nailing group compared to plate group (Table 1).

The complications noted in our study were 5 cases in plating group and 3 cases in nailing group. The complications involved in plating group were delayed union (n=3), superficial infection (n=1) and implant failure with delayed union (n=1). In nailing group complications were delayed union (n=1), nail migration (n=1), skin irritation (n=1). Complications were less in TENS group compared to plate group (Table 2).

Functional assessment was made with Constant and Murley score at 6 months, it was excellent in 7 cases (35%), good in 7 cases (35%), fair in 4 cases(20%) cases and poor in 2 cases (10%) in plating group whereas nailing group showed excellent score in 16 cases (80%) , good score in 3 cases (15%) and fair score in 1 case(5%). Nailing group showed better functional outcome compared to the plate group and was statistically significant p= 0.0098 (p<0.01) (Table 3).

Table 1: Comparison of characteristics between two groups

Character	TENS group(n=20)	Plate group(n=20)
Mean age(in years)	33.25±9.67	35.45±8.83
Gender		
Male	16(80%)	15(75%)
Female	4(20%)	5(25%)
Side affected		
Right	12(60%)	13(65%)
Left	8(40%)	7(35%)
Mode of injury		
RTA	10(50%)	7(35%)
Self fall	6(30%)	10(50%)
Sports injury	4(20%)	3(15%)
Interval between injury and surgery(days)	2.87 ± 1.32	2.65 ± 1.16
Radiological union(weeks)	9.70±2.36	12.30±2.34

Table 2: Comparison of complications between two groups

Complications	Tens group	Plate group
Delayed union	1	3
Implant failure with delayed union	-	1
Superficial infection	-	1
Nail migration	1	-
Skin irritation	1	-
Total	3	5

Table 3: Comparison of Constant- Murley scores between two groups

Constant and murley score	TENS group (No of cases)	Plate group (N0 of cases)
Excellent	16(80%)	7(35%)
Good	3(15%)	7(35%)
Fair	1(5%)	4(20%)
Poor	-	2(10%)
Total	20(100%)	20(100%)

Discussion

Although most Clavicular fractures are managed conservatively, they are associated with higher complication rates from 10-15% in the form of malunion, nonunion, decrease in shoulder power, shoulder stiffness and unfavourable cosmetic outcome [14-17]. Therefore surgical treatment for a midclavicular fracture is recommended and is considered superior to conservative treatment [18]. Open reduction with plate fixation is considered standard method for surgical fixation of clavicular fracture. Plate can be applied superiorly or antero inferiorly. Intramedullary Titanium elastic nailing has been latest addition in the fracture fixation of midshaft clavicle which has given good functional results mainly due to smaller invasive technique and is cosmetically better [19]. In our study we compared functional outcome of displaced midshaft clavicle fractures treated with anatomically contoured locking compression plate and titanium elastic nail system and its associated complications.

In our study, radiological union was seen in 12.30± 2.34 weeks in plating group which was significantly delayed compared to nailing group where union was seen in 9.70±2.36 weeks (p=0.001). The large wound size, extensive soft tissue stripping required for plate fixation and removal are disadvantages of plating techniques. Delay in union could be due to extensive periosteal stripping compared to no periosteal stripping in nailing method as it was done closed. Also, plating gives absolute stability whereas nailing results in relative stability enhancing callus formation by micromotion at fracture site [20]. Saha *et al.* in his study showed similar results with faster union seen in nailing group compared to plating group [20]. Functional outcome has been reported better in nailing group than plating group with previous studies.

Anil *et al.* reported patients treated by plating showed excellent outcome in 60% cases compared to 84% in nailing group [21]. The mean DASH score was found to be 1.87±3.4 in the TENS group and 4.8±5.9 in the plate group. Both the scoring system suggested TENS nailing was better than plate fixation. In our study, the functional outcome was measured by Constant and Murley scoring system. It showed nailing group had better functional outcome than plating group (p=0.0098). Plating group showed excellent results in 7 cases (35%), good in 7 cases (35%), fair in 4 cases (20%) cases and poor in 2 cases (10%) whereas nailing group showed excellent score in 16 cases (80%), good score in 3 cases (15%) and fair score in 1 case (5%) (p= 0.0098).

Both surgical treatment modalities have complications of their own. Complications related to plating include hardware prominence, delayed union/ non union, infections, implant breakage and refracture, implant loosening [22-24]. The complications noted in our study were 5 cases in plating group, they were delayed union (n=3), superficial infection (n=1) and implant failure with delayed union (n=1). Complications due to nailing too exist, though fewer, they include medial or lateral end of a nail protrusion, skin irritation or penetration, nail breakage and superficial skin infection [25-27]. In our study nailing group had 3 complications, they were delayed union (n=1), nail migration (n=1), skin irritation (n=1).

Conclusion

On the basis of this study we concluded that in displaced midshaft clavicle fractures Titanium elastic nailing is superior to clavicular plating. Nailing technique is simpler and quicker, minimally invasive and has better functional outcome, faster

union, fewer complications, less hospital stay, better patient comfort in terms of reduced post operative pain, and earlier return to normal day to day activities and produces an excellent cosmetic outcome than plating.

References

1. Postacchini F, Gumina S, De Santis P, Albo F. Epidemiology of clavicle fractures. *J Shoulder Elbow Surg* 2002;11(5):452-456.
2. Schiffer G, Faymonville C, Skouras E, Andermahr J, Jubel. A Midclavicular fracture: Not just a trivial injury – current treatment options. *Dtsch ArzteblInt* 2010;107(41):711-7.
3. Jeray K. Acute midshaft clavicular fracture. *J Am Acad Orthop Surg* 2007;15:239-248.
4. Neer CS. Nonunion of the clavicle. *JAMA* 1960;172:1006-1011.
5. Rowe CR. An atlas of anatomy and treatment of midclavicular fractures. *Clin Orthop Relat Res* 1968;58:29-42.
6. Canadian Orthopaedic Trauma Society. Nonoperative treatment compared with plate fixation of displaced midshaft clavicular fractures. A multicenter randomized clinical trial. *J Bone Joint Surg* 2007;89-A:1-10.
7. Hill JM, McGuire MH, Crosby LA. Closed treatment of displaced middle-third fractures of the clavicle gives poor results. *J Bone Joint Surg* 1997;79-B(4):537-539.
8. Wild LM, Potter J. Deficits following nonoperative treatment of displaced midshaft clavicular fractures. *J Bone Joint Surg* 2006;88-A:35-40.
9. McKee MD. Deficits following nonoperative treatment of displaced midshaft clavicular fractures. *J Bone Joint Surg Am.* 2006;88(1):35-40.
10. Ali KM, Lucas HK. Plating of fractures of the middle third of the clavicle. *Injury* 1978;9(4):263-267.
11. Poigenfurst J, Rappold G, Fischer W. Plating of fresh clavicular fractures: results of 122 operations. *Injury* 1992;23(4):237-241.
12. Rehm KE, Andermahr J, Jubel A. Intramedullary nailing of midclavicular fractures with an elastic titanium nail. *Eur J Traum Emerg Surg* 2005;31(4).
13. Zlowodzki M, Zelle BA, Cole PA, Jeray K, McKee MD. Evidence-Based Orthopaedic Trauma Working Group. Treatment of acute midshaft clavicle fractures: Systematic review of 2144 fractures: On behalf of the Evidence Based Orthopaedic Trauma Working Group. *J Orthop Trauma* 2005;19:504-7.
14. McKee RC, Whelan DB, Schemitsch EH, McKee MD. Operative versus nonoperative care of displaced midshaft clavicular fractures: A meta-analysis of randomized clinical trials. *J Bone Joint Surg Am* 2012;94:675-84.
15. Liu GD, Tong SL, Ou S, Zhou LS, Fei J, Nan GX *et al.* Operative versus nonoperative treatment for clavicle fracture: A meta-analysis. *Int Orthop* 2013;37:1495-500.
16. Rehn CH, Kirkegaard M, Viberg B, Larsen MS. Operative versus nonoperative treatment of displaced midshaft clavicle fractures in adults: A systematic review. *Eur J Orthop Surg Traumatol* 2014;24:1047-53.
17. Virtanen KJ, Remes V, Pajarinen J, Savolainen V, Björkenheim JM, Paavola M. Sling compared with plate osteosynthesis for treatment of displaced midshaft clavicular fractures: A randomized clinical trial. *J Bone Joint Surg Am* 2012;94:1546-53.
18. Lazarides S, Zafiroopoulos G. Conservative treatment of fractures at the middle third of the clavicle: The relevance

- of shortening and clinical outcome. *J Shoulder Elbow Surg* 2006;15:191-4.
19. Mueller M, Rangger C, Striepens N, Burger C. Minimally invasive intramedullary nailing of midshaft clavicular fractures using titanium elastic nails. *J Trauma*. 2008;64(6):1528-1534.
 20. Saha P, Datta P, Ayan S, Garg AK, Bandyopadhyay U, Kundu S. Plate versus titanium elastic nail in treatment of displaced midshaft clavicle fractures A comparative study. *Indian J Orthop* 2014;48:587-93.
 21. Sahu AK, Lenka BS, Mishra AK, Panda CK, Kar M. A comparative study between plating versus titanium elastic nail system in mid-shaft clavicle fracture management. *Int J Res Orthop* 2018;4:741-6.
 22. Wijdicks FJ, Van der Meijden OA, Millett PJ, Verleisdonk EJ, Houwert RM. Systematic review of the complications of plate fixation of clavicle fractures. *Arch Orthop Trauma Surg*. 2012;132(5):617-625.
 23. Bostman O, Manninen M, Pihlajamaki M. Complications of plate fixation in fresh displaced midclavicular fractures. *J Trauma* 1997;43(5):778-783.
 24. Assobhi JE. Reconstruction plate versus minimal invasive retrograde titanium elastic nail fixation for displaced midclavicular fractures. *J Orthop Traumatol*. 2011;12:185-92.
 25. Chen YF. Retrospective comparison of titanium elastic nail (TEN) and reconstruction plate repair of displaced midshaft clavicular fractures. *J Shoulder Elbow Surg* 2012;21(4):495-501.
 26. Jubel A, Andermahr J, Schiffer G, Tsironis K, Rehm KE. Elastic stable intramedullary nailing of midclavicular fractures with a titanium nail. *Clin Orthop Relat Res*. 2003;408:279-85.
 27. Frigg A, Rillmann P, Perren T, Gerber M, Ryf C. Intramedullary nailing of clavicular midshaft fractures with the titanium elastic nail: Problems and complications. *Am J Sports Med* 2009;37:352-9.