

E-ISSN: 2395-1958
P-ISSN: 2706-6630
IJOS 2021; 7(4): 666-668
© 2021 IJOS
www.orthopaper.com
Received: 01-06-2021
Accepted: 07-07-2021

Dr. Burhan Bhat
Senior Resident, Department of
Orthopedics, GMC, Baramulla,
Jammu and Kashmir, India

Dr. AR Badoo
Head of Department,
Department of Orthopedics,
GMC, Baramulla, Jammu and
Kashmir, India

Dr. Jabreel Muzaffar
Senior Resident, Department of
Orthopedics, GMC, Baramulla,
Jammu and Kashmir, India

Dr. Zameer Ali
Associate Professor, Department
of Orthopedics, GMC,
Baramulla, Jammu and
Kashmir, India

Dr. Ishtiaq Abdullah
Assistant Professor, Department
of Orthopedics, GMC,
Baramulla, Jammu and
Kashmir, India

Dr. Sulaiman Sath
Senior Resident, Department of
Orthopedics, GMC, Baramulla,
Jammu and Kashmir, India

Corresponding Author:
Dr. Jabreel Muzaffar
Senior Resident, Department of
Orthopedics, GMC, Baramulla,
Jammu and Kashmir, India

To compare the role of hybrid external fixation and MIPO in management of proximal tibial fracture

Dr. Burhan Bhat, Dr. AR Badoo, Dr. Jabreel Muzaffar, Dr. Zameer Ali, Dr. Ishtiaq Abdullah and Dr. Sulaiman Sath

DOI: <https://doi.org/10.22271/ortho.2021.v7.i4j.2947>

Abstract

Background: The proximity to the ankle makes the surgical treatment more complicated than midshaft tibial fractures. The present study compared hybrid external fixation and MIPO in management of proximal tibial fracture.

Materials and Methods: 64 cases of proximal tibia fracture of both genders were divided into 2 groups of 32 each. Group I patients were treated with hybrid external fixation and group II with MIPO. Parameters such as operative time, blood loss, hospital stay, healing time etc. were recorded.

Results: Group I had 18 males and 14 females and group II had 20 males and 12 females. Operative time (min) was 90.3 and 110.4, blood loss (ml) was 124.7 and 205.2, hospital stay (Days) was 10.2 and 21.0, healing time (Weeks) was 8.2 and 16.7 and time of recovery to work (Days) was 10.4 and 32.1 in group I and II respectively.

Conclusion: Hybrid external fixation found to be better than MIPO in management of proximal tibia fracture.

Keywords: Tibia, hybrid external fixation, MIPO

Introduction

Tibia fractures-because of its unique anatomy and vulnerable soft tissue envelope and contamination of the wound are very difficult to treat. Traditionally open tibial fractures have been managed by repeated debridement, external fixation, and delayed soft tissue coverage persisting with perennial complication [1]. Today we need an aggressive radical approach to the management of these devastating injuries. The management of unstable distal tibia fractures remains challenging for surgeons [2]. The proximity to the ankle makes the surgical treatment more complicated than midshaft tibial fractures [3]. Treatment selection is influenced by the proximity of the fracture to the plafond, fracture displacement, comminution and injury to the soft tissue envelope. Conventional open reduction and internal fixation (ORIF) techniques involve extensive dissection and periosteal stripping, which increase the risk of soft tissue complications [4]. Nevertheless, plate fixation is effective in stabilising distal tibia fractures. Intramedullary nailing (IMN) offers a minimally invasive option; however, concerns have been raised regarding the biomechanical stability of fixation and risk of malunion or non-union. However, when the fracture line is less than 5cm proximal to the ankle joint, intramedullary nailing (IMN) is not applicable [5]. The minimally invasive plate osteosynthesis (MIPO) technique has gained prevalence in recent years. This percutaneous plating technique uses indirect reduction methods and allows stabilisation of distal tibia fractures while preserving the vascularity of the soft tissue envelope [6]. The present study compared hybrid external fixation and MIPO in management of proximal tibial fracture.

Materials and Methods

The present study comprised of 64 cases of proximal tibia fracture of both genders. All were informed regarding the study and their written consent was obtained. Ethical clearance was obtained before starting the study.

Demographic data such as name, age, gender etc. was recorded. Radiographs were used to determine the location and AO classification of the fractures.

Patients were divided into 2 groups of 32 each. Group I patients were treated with hybrid external fixation and group II with MIPO. Parameters such as operative time, blood loss, hospital stay, healing time etc. were recorded. Results of the study were analysed statistically. P value less than 0.05 was considered significant.

Results

Table 1: Distribution of patients

Groups	Group I	Group II
Method	Hybrid external fixation	MIPO
M:F	18:14	20:12

Table 1 shows that group I had 18 males and 14 females and group II had 20 males and 12 females.

Table 2: Assessment of parameters

Parameters	Group I	Group II	P value
Operative time (min)	90.3	110.4	0.09
Blood loss (ml)	124.7	205.2	0.05
Hospital stay (Days)	10.2	21.0	0.04
Healing time (Weeks)	8.2	16.7	0.01
Time of recovery to work (Days)	10.4	32.1	0.01

Table 2, Figure 1 shows that operative time (min) was 90.3 and 110.4, blood loss (ml) was 124.7 and 205.2, hospital stay (Days) was 10.2 and 21.0, healing time (Weeks) was 8.2 and 16.7 and time of recovery to work (Days) was 10.4 and 32.1 in group I and II respectively. The difference was significant ($P < 0.05$).

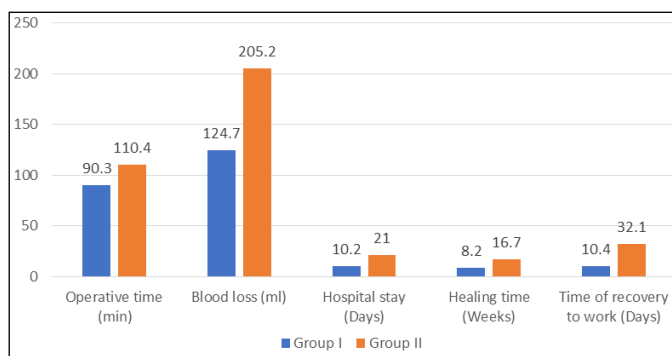


Fig 1: Assessment of parameters

Discussion

Fixation of proximal third tibia fractures with the locking plates has demonstrate excellent results. External fixation has a long history; it was first documented by Hippocrates when he used a splint for tibial fractures. The development of external fixation devices that were directly attached to the bone started in the mid-19th century [7]. Langenbeck was the first to describe a technique that offered sufficient stability to the fracture site in 1851. At the turn of the century, the concept of unilateral external fixation was invented [8]. The swiss surgeon Raoul Hoffmann introduced an external fixation system concept that was able to provide length, alignment and rotational control in a rigid construct [9]. External fixation remains a versatile option for fixation of both open and closed fractures. However, pin-track infection and malunion are frequent complications [10]. Due to its wide range of indications, such as peri-articular fractures, articular dislocation and polytrauma, external fixation stands out by its simplicity in regard to initial treatment. Recently, an

increasing rate of primary fracture treatment with spanning external fixation was observed and was explained by changes in logistics, economic aspects, or an increased use of damage-control techniques [11, 12]. The present study compared hybrid external fixation and MIPO in management of proximal tibial fracture.

In present study, we found that group I had 18 males and 14 females and group II had 20 males and 12 females. Jan *et al.* [13] carried out a study on 40 patients with proximal third tibia fractures of AO classification type 41 A2 (transverse metaphyseal) and 41 A3 (comminuted metaphyseal). Patients were divided into 2 groups depending on the surgical treatment received; observation group comprised of 20 patients treated by external fixation and the control group comprised of 20 patients treated by Open reduction internal fixation with locking compression plate. Pathological fractures, fractures due to malignancy were excluded from the study. Clinical and radiological follow-up was performed at one month, 2 months, 3 months, 6months and 12 months post operatively for both groups. Patients were systematically assessed for knee function, post-operative infections, healing time, intra operative bleeding and surgical time, state of reduction after one week. Knee function was graded using Rasmussen Knee score. 32 patients showed up for post operation check-up after one-month, 2-months, 3-months, 6-months, after 1 year 20 patients showed up. At one week post op, radiological assessment showed that 18-patients (93%) got anatomical reduction in LCP group as compared to 16-patients (80%) in the external fixation group. Average duration of bone union in external fixation was 14-weeks and that in LCP group 16-weeks. 2 cases in the external fixation group had pin tract infection, which were resolved with administration of antibiotics and local pin site care; no infection was noted in the LCP group. There were 2 cases of delayed union in LCP group and these were re operated using locking plates and auto bone grafts. No deep venous thrombosis, pneumonia or bed sores developed in any group patients. There was one case of bed sore in LCP group. There was initial knee stiffness in EF group and mean knee range of motion was 122 degree and that in LCP group as 126 degrees. Continuous passive motion was started as soon as the pain subsided. After 2-months and 6-months follow ups, no radiographic signs of osteoarthritis detected. Mean Rasmussen knee score was good 25 in EF group patients and good 24.5 in LCP group. Mean weight bearing time was 13-weeks post operatively for both groups. No cases of compartment syndrome detected in both groups. Check-up after 1-year of both group patients, all were full weight bearing with satisfactory range of motion.

We observed that operative time (min) was 90.3 and 110.4, blood loss (ml) was 124.7 and 205.2, hospital stay (Days) was 10.2 and 21.0, healing time (Weeks) was 8.2 and 16.7 and time of recovery to work (Days) was 10.4 and 32.1 in group I and II respectively. Cheng *et al.* [14] compared the results between two surgical options for distal tibia fracture, i.e. minimally invasive plate osteosynthesis (MIPO) vs. open reduction and internal fixation (ORIF), and explore the benefits and defects of these two techniques. Thirty cases of distal tibia fracture (15 pairs of ORIF and MIPO) were submitted for pair comparison with consistence of gender, age and AO fracture classification. Indexes for evaluation included operative time, blood loss, healing time, time of recovery to work, implant irritation symptoms, and union status. Mazur grading standard was introduced for functional evaluation. No malunion occurred and one case of

osteomyelitis developed in the ORIF group. In the ORIF group, ten cases were evaluated as excellent, three as good, one as fair and one as poor. In the MIPO group, ten cases were excellent and five good. Paired t-test found no significant differences between groups on the indexes for analysis. The MIPO technique is not distinctively superior to ORIF in treatment of distal tibia fracture.

Conclusion

Authors found that hybrid external fixation found to be better than MIPO in management of proximal tibia fracture.

References

1. Oh CW, Park BC, Kyung HS, *et al.* Percutaneous plating for unstable tibial fractures. *J Orthop Sci.* 2003; 8(2):166-169.
2. Kopp FJ, Banks MA, Marcus RE. Clinical outcome of tibiotalar arthrodesis utilizing the chevron technique. *Foot Ankle Int.* 2004;25(4):225-230.
3. Hasenboehler E, Rikli D, Babst R. Locking compression plate with minimally invasive plate osteosynthesis in diaphyseal and distal tibial fracture: A retrospective study of 32 patients. *Injury.* 2007;38(3):365-370.
4. Khoury A, Liebergall M, London E, Mosheiff R. Percutaneous plating of distal tibial fractures. *Foot Ankle Int.* 2002; 23(9):818-824.
5. Lau TW, Leung F, Chan CF, Chow SP. Wound complication of minimally invasive plate osteosynthesis in distal tibia fractures. *Int. Orthop.* 2008;32(5):697-703.
6. Ozsoy MH, Tuccar E, Demiryurek D, *et al.* Minimally invasive plating of the distal tibia: do we really sacrifice saphenous vein and nerve? A cadaver study. *J Orthop. Trauma.* 2009;23(2):132-138.
7. Collinge C, Kuper M, Larson K, Protzman R. Minimally invasive plating of high-energy metaphyseal distal tibia fractures. *J Orthop. Trauma.* 2007;21(6):355-361.
8. Joveniaux P, Ohl X, Harisboure A, *et al.* Distal tibia fractures: management and complications of 101 cases. *Int. Orthop.* 2010;34(4):583-588.
9. Mohammed A, Saravanan R, Zammit J, King R. Intramedullary tibial nailing in distal third tibial fractures: distal locking screws and fracture non-union. *Int. Orthop.* 2008;32(4):547-549.
10. Yang SW, Tzeng HM, Chou YJ, Teng HP, Liu HH, Wong CY. Treatment of distal tibial metaphyseal fractures: plating versus shortened intramedullary nailing. *Injury.* 2006;37(6):531-535.
11. Maffulli N, Toms AD, McMurtie A, Oliva F. Percutaneous plating of distal tibial fractures. *Int. Orthop.* 2004;28(3):159-162.
12. Borg T, Larsson S, Lindsjo U. Percutaneous plating of distal tibial fractures. Preliminary results in 21 patients. *Injury.* 2007;35(6):608-614.
13. Jan I, Li X, Alam S, Manzoor A. A Comparative Study between External Fixation Versus Locking Compression Plate in Management of Extra Articular Proximal 1/3 Tibia Fractures. *ARC Journal of Orthopedics*, 2016, 7-14.
14. Cheng W, Li Y, Manyi W. Comparison study of two surgical options for distal tibia fracture-minimally invasive plate osteosynthesis vs. open reduction and internal fixation. *International orthopaedics.* 2011 May;35(5):737-42.