



International Journal of Orthopaedics Sciences

E-ISSN: 2395-1958
P-ISSN: 2706-6630
IJOS 2021; 7(4): 231-235
© 2021 IJOS

www.orthopaper.com

Received: 10-07-2021

Accepted: 19-08-2021

Dr. Chetan SV

Department of Orthopaedics and
Department of Plastic Surgery,
Kle's Academy of Higher
Education and Research, J.N.
Medical College, Kle's Dr.
Prabhakar Kore Hospital and
Medical Research Center,
Belagavi, Karnataka, India

Dr. Sahil Kale

Department of Orthopaedics and
Department of Plastic Surgery,
Kle's Academy of Higher
Education and Research, J.N.
Medical College, Kle's Dr.
Prabhakar Kore Hospital and
Medical Research Center,
Belagavi, Karnataka, India

Dr. Raunak Pareek

Department of Orthopaedics and
Department of Plastic Surgery,
Kle's Academy of Higher
Education and Research, J.N.
Medical College, Kle's Dr.
Prabhakar Kore Hospital and
Medical Research Center,
Belagavi, Karnataka, India

Corresponding Author:

Dr. Chetan SV

Department of Orthopaedics and
Department of Plastic Surgery,
Kle's Academy of Higher
Education and Research, J.N.
Medical College, Kle's Dr.
Prabhakar Kore Hospital and
Medical Research Center,
Belagavi, Karnataka, India

Pulseless pink hand syndrome

Dr. Chetan SV, Dr. Sahil Kale and Dr. Raunak Pareek

DOI: <https://doi.org/10.22271/ortho.2021.v7.i4d.2887>

Abstract

Supracondylar humerus fracture is one of the most common elbow injuries in children, comprising 60% of all the elbow injuries in children. An elbow or forearm fracture should be suspected in a child with elbow pain or failure to use the upper extremity after a fall. The fracture typically occurs through the weak metaphyseal bone proximal to the fossae. A careful examination of the entire arm should be performed, and any area with tenderness or swelling should have radiograph as multiple fracture (such as supracondylar fracture and a radius/ulna fracture) are not uncommon. A thorough motor, sensory and vascular examinations should be performed, difficult in pediatric group but should be attempted and recorded accurately. Assessment of vascular status in supracondylar fracture of humerus is important as up to 20% of displaced fractures present with vascular compromise. Here we present a case report of 7-year-old girl who sustained extension type supracondylar humerus fracture with pulseless pink hand. Urgent manipulation was undertaken but it was unsuccessful, a posterior stab incision was taken to reduce the fracture fragments using bone spike. To our knowledge, there are various methods and flow charts regarding the treatment of the vascular compromise which accompany various associated risks and complications with no specific protocol.

Keywords: Supracondylar humerus, elbow injuries, children

Introduction

Supracondylar fracture of humerus in children are associated with morbidity due to malunion, neurovascular complications and compartment syndrome. These fractures are most common in children aged less than 10 years, with a peak incidence between ages 5 years and 8 years and these fractures often require surgery. Extension fracture account for approximately 98% of these injuries, and they usually occur as the result of fall on outstretched hand with wrist in dorsiflexion and the elbow in hyperextension or slight flexion. In hyperextension, the linear force acting along the extended elbow is converted into bending force by the interlocking tip of the olecranon into its fossa. The metaphyseal trabeculae in this area are thin hence a significant force can produce fracture. The elbow with supracondylar humerus fracture is characterized by swelling and deformity. With more displaced fracture, a S shaped deformity of the elbow develops due to the angulation and translation of the fracture fragments as anterior periosteum tears off. In the radiographs, Baumann's angle will be altered with normal being 10-20 deg., and Fat pad signs (anterior and posterior) will be seen. Careful motor and sensory examination should be documented. Vascular examination should include presence of pulse, warmth, capillary refill and color of the hand along with bedside Doppler and pulse oximeter monitoring.

Classification

Supracondylar Humerus Fractures

1. Extension type
2. Flexion type

Modified Gartland's Classification

Type 1: <2 mm displacement

Type 2: Hinged posteriorly

Type 3: Displaced

Type 4: Displaces into extension and flexion

Case Report

7-Year-old girl came to casualty around 2AM with extension type of supracondylar humerus fracture limb after she fell from an approximate height of 2.5 feet at her residence at around 6PM. She was immediately taken to a local doctor where initial assessment was done and an X-ray and CT angiography were done. Radial artery was not felt and all peripheral sensations were intact. Above elbow slab was applied and was referred to KLE Hospital for further management in view of vascular compromise. Patient was conscious and oriented to time place and person and hemodynamically stable. She presented with a closed extension type of fracture. No puckering was seen. Careful motor, sensory and vascular assessment was done in the casualty. All motor and sensory functions of radial, median and ulnar nerves were intact. Vascular examination concluded that Hand was well perfused (warm and red) with radial pulse absent. The outside CT angiogram reported non-visualization

of 61 mm segment of brachial artery just above the bifurcation suggesting transection of the brachial artery. Emergency OT was undertaken by the orthopedic and plastic surgery team. Manipulation by closed reduction was tried but was unsuccessful. Posterior stab incision was taken and with the help of spike, fracture fragments were tried to reduce but the fracture fragments were slipping. Anterior incision was taken in the cubital fossa by the plastic surgery team for fasciotomy. As the dissection was done it was found that the brachial artery was impinged between the fracture fragments along with biceps muscle, there was no transection of brachial artery. Brachial artery was released from the impingement after the release radial pulse was felt fracture fragments were reduced by cross pinning with k-wires, one each from lateral and medial side. Above elbow slab was applied and she undertook the procedure well. Patient was kept in observation for 24 hours; her motor and sensory assessment was again evaluated and was advised to follow up after 6 weeks.

Pre-Op X-ray

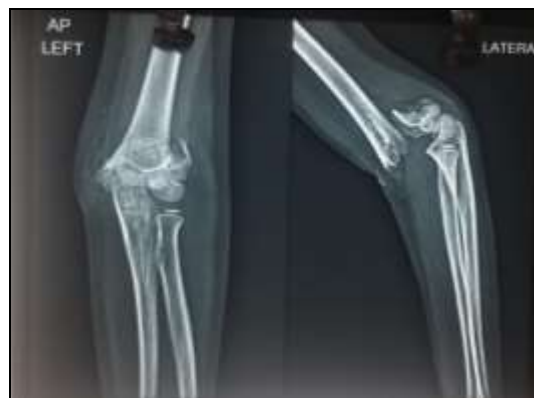

Fig 1: X-ray Left elbow AP and Lateral.

CT Angiogram with 3D Reconstruction

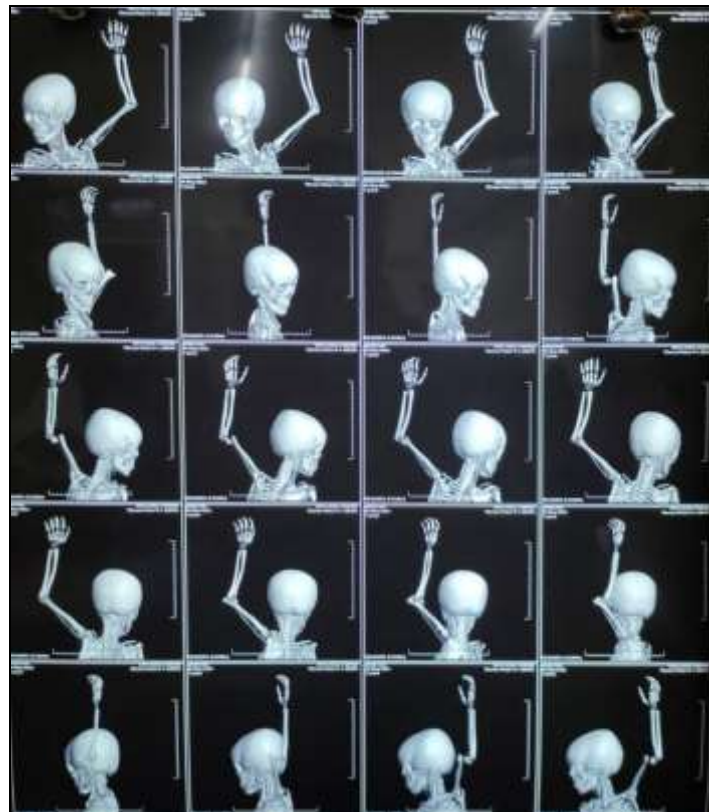

Fig 2A: Shows in X-ray CT Angiogram with 3D Reconstruction

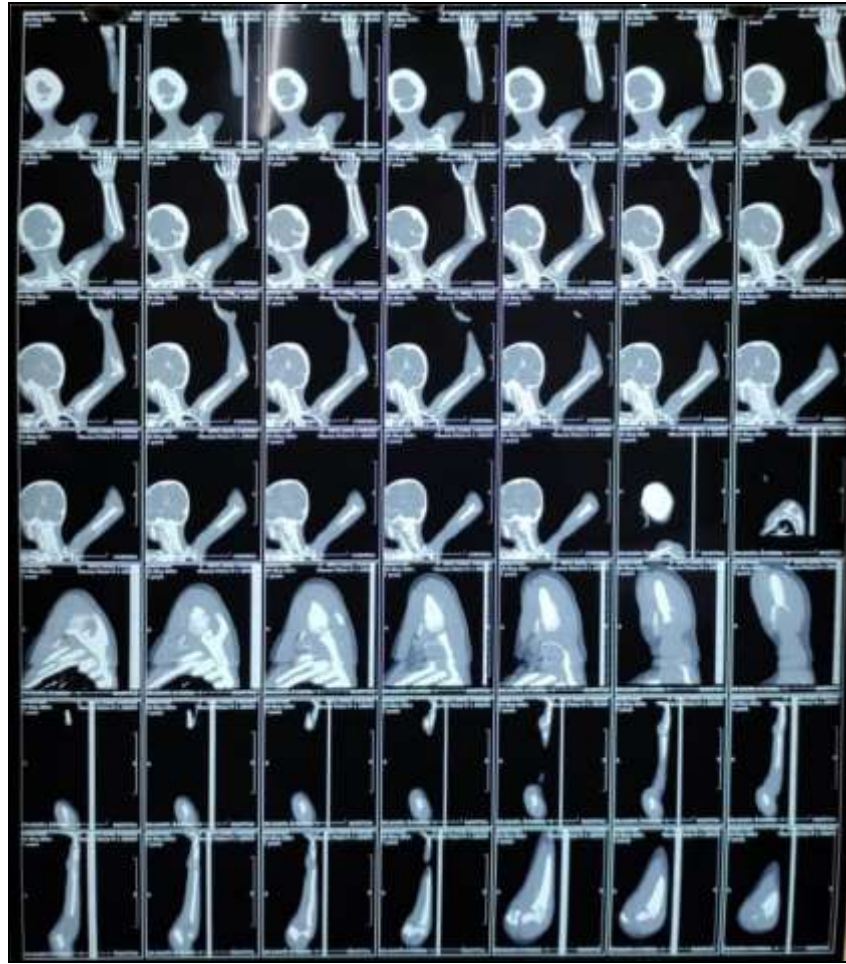


Fig 2B: CT films showing supracondylar fracture humerus

Clinical Images

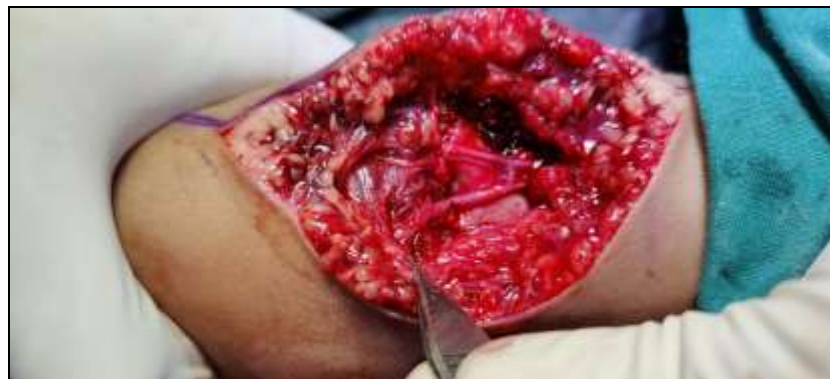

Fig 3A: Kinking of the brachial artery

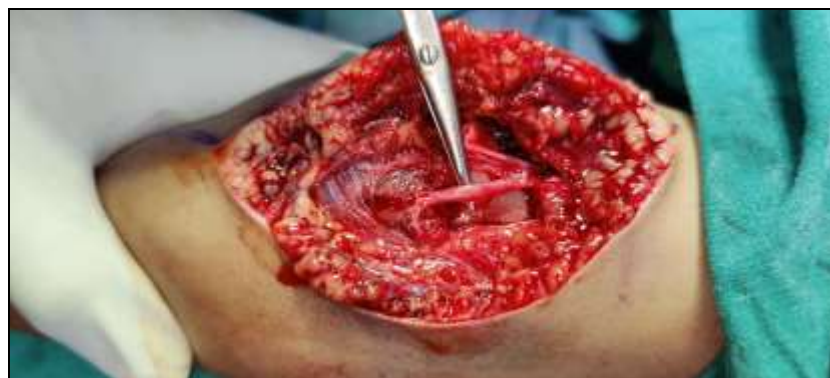

Fig 3B: Released brachial artery

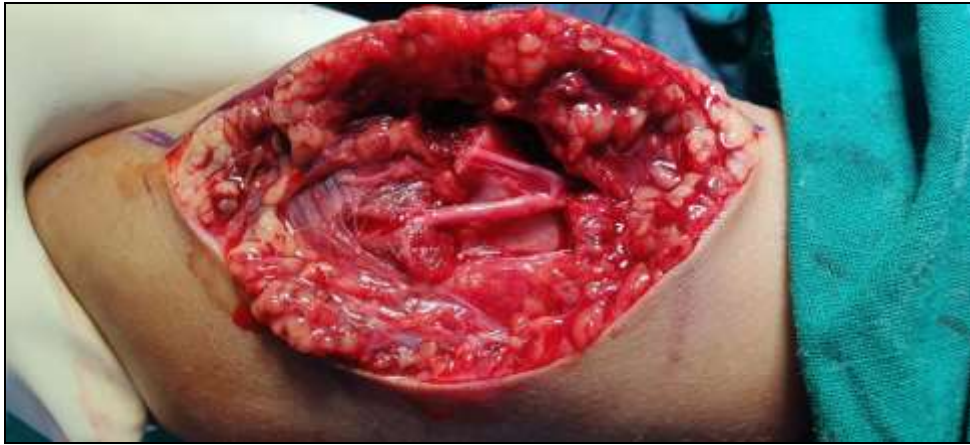

Fig 3C: Patent brachial artery in the cubital fossa

Intra-Operative Images

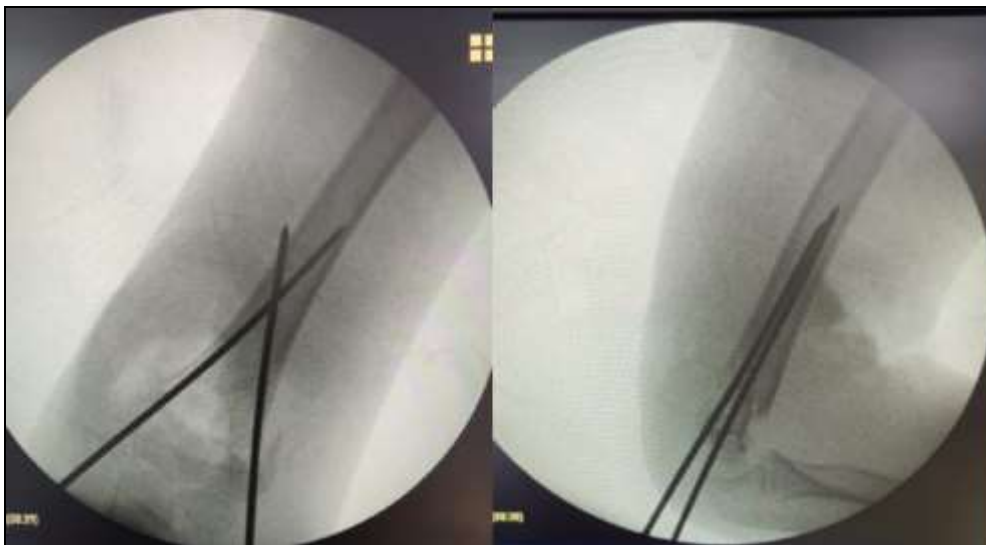

Fig 4: C-arm images in AP and Lateral views of elbow joint showing cross pinning with K-wires

Post-Op X-ray

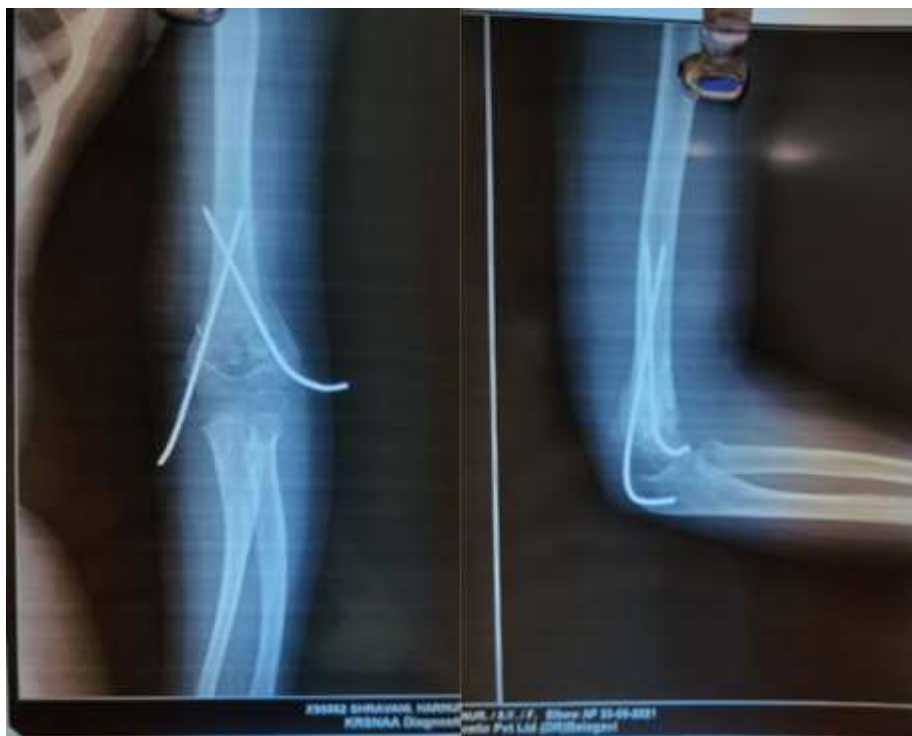
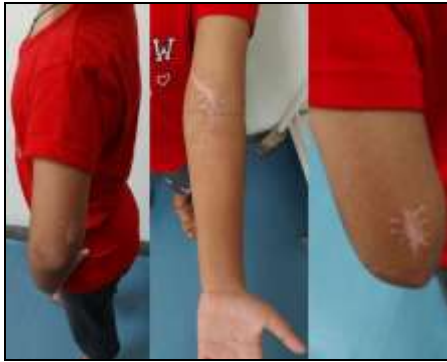
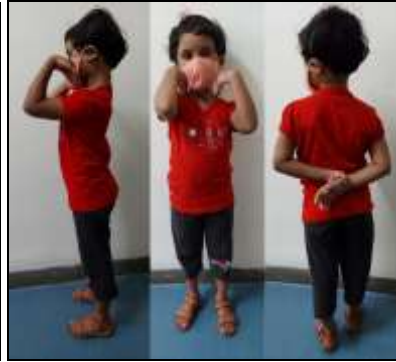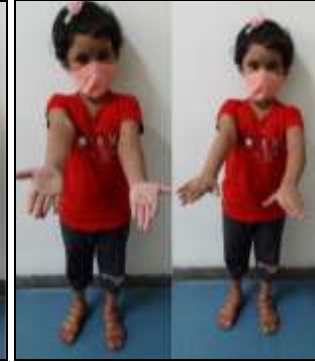Fig 5: Post operative Xray of the elbow joint

Clinical Images**Fig 6A:** Suture Scars**Fig 6: B.** Flexion At The Elbow Joint**Fig 6C:** Supination and Pronation**Result**

The radial artery was immediately felt as soon it was released from the impingement and fracture was reduced. Immobilization of the left upper limb was advised. Patient was followed up after 6 weeks, repeat Xray was taken which was satisfactory and K-wires were removed. Physiotherapy started and patient regained full range of movement at the left elbow joint with all neurovascular status intact and no deformity.

Discussion

Brachial artery injury is highly at risk in displaced supracondylar humerus fractures as it often gets stretched/kinked/transected by the displaced fracture fragments or between the bicep brachii or the fracture fragments. Due to the ulnar side tethering of the supratrochlear artery the brachial artery is at a higher risk. The collateral circulation around the elbow joint helps in maintaining the vascularity of the limb and hence patients are often managed without any vascular exploration. Radial recurrent artery arising distally to elbow anastomoses with radial collateral branch of the profunda brachii. Superior ulnar collateral artery, descending collateral, arising from brachial artery anastomoses with the posterior ulnar recurrent and inferior ulnar collateral arteries. Impaired blood supply or neglected vascular compromise may land into troublesome complications like Volkmann's ischemia. Neurovascular compromise may complicate displaced supracondylar fractures in 10% to 20% of cases. Gartland type III injury requires attention regarding vascular injury with median and anterior interosseous nerves are most frequently injured in extension types. Majority surgeons manage by closed reduction of the fracture, followed by stabilization with crossed Kirschner (K)-wires and often the radial artery pulse returns back immediately. In the patient, the edges of the proximal fracture fragment and bicep brachii caused a kinking of the brachial artery, leading to a pulseless limb. There was formation of multiple collateral blood vessels, bypassing the major artery to supply the distal hand, and thus preventing ischemic gangrene of the upper limb. Apart from the clinical assessment, various tools and imaging methods such as Doppler ultrasound and angiography could aid in a detailed vascular assessment. Doppler ultrasound could be performed rapidly at the bedside for vascular assessment and estimation of the severity of the vascular injury. Hence, we believe that before proceeding further for any modality these three points should be noticed likewise, presence of radial artery Doppler signals, presence of good pulse oximeter waveforms and oxygen saturation >95% and intact Median Nerve function. Computed tomography (CT) angiography done showed a

report about transection with turned out to be an impingement which was later identified and located at the fracture site intraoperatively. CT angiography still played a role in cases where pre-operative planning was needed, such as in complicated injuries with comminuted fractures or suspected segmental artery injuries. In patient with vascular compromise due to a displaced supracondylar humeral fracture, the consensus was to track and reduce the fracture gently. The maneuver of flexing the elbow up to 45 degree and gentle traction could relieve the pressure from the anterior structures, potentially separating the sharp edges of the proximal fracture fragment from the neurovascular structures, hence improving the perfusion. If the fracture was not reduced, and there was a vascular compromise, an open reduction and exploration of the brachial artery would be indicated. Similarly, if the vascular assessment showed a pale and pulseless upper limb, an open reduction and exploration of the artery would also be indicated. In the patient, a trial of manipulation was done but the fracture fragments were slipping and not reducing which later on turned out that a good stretch of brachial artery was struck at the fracture site and bicep brachii. Hence, we believe that a trial of manipulation should be given along with a posterior stab incision could be useful in cases where the reduction is not sustained as it'll be helping even if the upper limb is going further in compartment syndrome and vascular compromise depending upon the time of patient's presentation to ER.

References

1. Schoenecker PL, Delgado E, Rotman M, Sicard GA, Capelli AM. Pulseless arm in association with totally displaced supracondylar fracture. *J Orthop Trauma* 1996;10:410-415.
2. Robb JE. The pink, pulseless hand after supracondylar fracture of the humerus in children. *J Bone Joint Surg Br* 2009;91(11):1410-2.
3. Badkoobehi H, Choi PD, Bae DS, Skaggs DL. Management of the pulseless pediatric supracondylar humeral fracture. *J Bone Joint Surg Am* 2015;97(11):937-43.
4. Korompilias AV, Lykissas MG, Mitsionis GI, Kontogeorgakos VA, Manoudis G, Beris AE. Treatment of pink pulseless hand following supracondylar fractures of the humerus in children. *Int Orthop* 2009;33(1):237-241.
5. Matuszewski Ł. Evaluation and management of pulseless pink/pale hand syndrome coexisting with supracondylar fractures of the humerus in children. *Eur J Orthop Surg Traumatol* 2014;24(8):1401-6.