



# International Journal of Orthopaedics Sciences

E-ISSN: 2395-1958  
P-ISSN: 2706-6630  
IJOS 2021; 7(4): 92-96  
© 2021 IJOS  
[www.orthopaper.com](http://www.orthopaper.com)  
Received: 10-08-2021  
Accepted: 12-09-2021

**Sumit Chawla**  
Consultant, Department of  
Orthopaedics, Maharaja Agarsen  
Hospital, New Delhi, Delhi,  
India

**Mallika Gupta**  
Consultant, Department of  
Radiology, Pentamed Hospital,  
New Delhi, Delhi, India

**Vaishali Grover**  
Division head, Department of  
Marketing, GPC Medical Ltd.,  
New Delhi, Delhi, India

**Garima**  
In-Charge, Department of  
Research and Product  
Development, GPC Medical Ltd.,  
New Delhi, Delhi, India

**Corresponding Author:**  
**Sumit Chawla**  
Consultant, Department of  
Orthopaedics, Maharaja Agarsen  
Hospital, New Delhi, Delhi,  
India

## Functional and clinical evaluation of intramedullary osteosynthesis with intraheal™ proximal femoral nail, advanced in unstable peritrochanteric fractures

**Sumit Chawla, Mallika Gupta, Vaishali Grover and Garima**

**DOI:** <https://doi.org/10.22271/ortho.2021.v7.i4b.2869>

### Abstract

**Background:** Cephalomedullary nailing for peritrochanteric femoral fractures is widely popular owing to low risk for perioperative morbidity. The evaluation of outcomes of peritrochanteric fracture fixation has usually relied upon objective measures. The purpose of the present study is functional and clinical evaluation including complications after intraHeal™ Proximal Femoral Nail Advanced for fixation of peritrochanteric fractures.

**Methods:** We conducted a single center study through our post market surveillance project including 468 patients (range 26-93 years, mean age 81 years) with unstable peritrochanteric fractures (AO/OTA 31-A2, 31-A3) treated with intraHeal™ Proximal Femoral Nail Advanced. Functional evaluation was done using Harris hip score, parker score, range of motion, leg length, body mass index, neck-shaft angle and grade of osteoarthritis hip at various stages of follow up. Clinical assessment of bony union and complications in perioperative and postoperative period was also considered.

**Results:** Radiographic union was achieved at an average 3 months in 94.5% of cases, with satisfactory reduction in 84.6% of cases. According to the Harris Hip Score 83% had excellent or good results. Parker score averaged 6 (between 6 and 8). In 36 cases postoperative complications were recorded, of which 13 required major or minor surgical procedure. 38 Patients were excluded from study due to death within 1 year of surgery.

**Conclusion:** The intraHeal™ Proximal Femoral Nail Advanced is an excellent alternative in treatment of all types of unstable peritrochanteric fractures. This study emphasizes the importance of acceptable anatomical reduction in anteroposterior and the lateral projection in reducing the risk of cut-out failure.

**Keywords:** trochanteric fracture, nailing, complications, functional results

### Introduction

Peritrochanteric fracture is one of the most commonly encountered fracture in geriatric population with 90% result from a simple fall [1]. Trochanteric fractures represent 60% of proximal femur fractures [2]. The incidence of these fractures has increased significantly during the last few decades and they remain one of the major causes of mortality, morbidity and loss of function among the elderly [3, 4]. Approximately 50-60% of all trochanteric fractures are classified as unstable. This represents a great challenge to the operating surgeon, as the rate of failure for these kinds of fractures vary from 8 to 25% [5].

Since its introduction in the late 1970's, the Dynamic Hip Screw (DHS) had become a standard device for the fixation of all trochanteric fractures of the femur [6].

The intraHeal™ Proximal Femoral Nail Advanced provides an intramedullary construct with the advantages of a reduced level arm compared to extra medullary fixation, and early postoperative weight bearing due to weight sharing by nail leading to faster recovery of function [5].

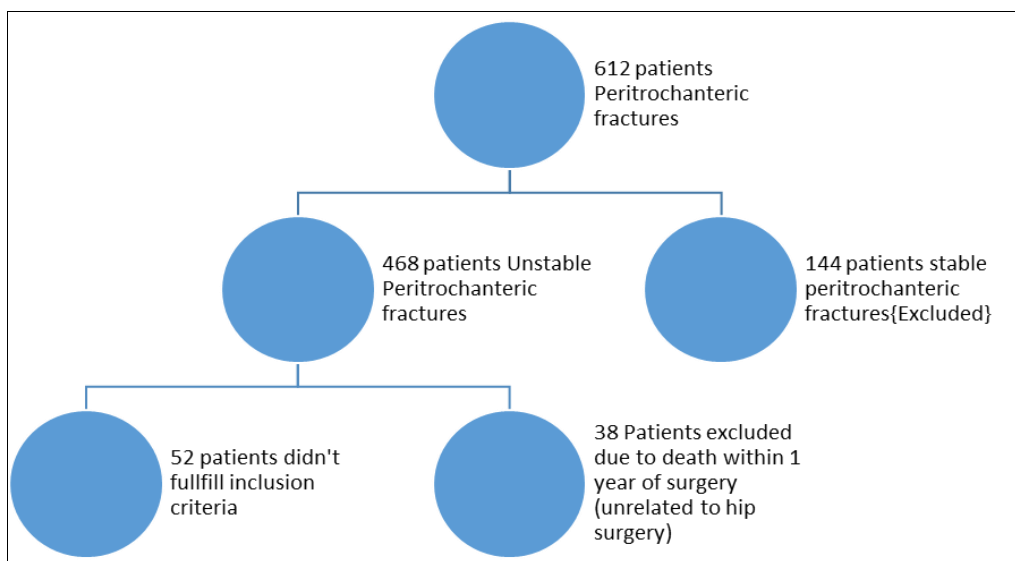
The intraHeal™ Proximal Femoral Nail Advanced being close to weight bearing axis has shorter lever arm with reduction in bending stress and lower implant failure rate. The nail occupies the medullary canal, preventing excessive sliding and medicalization of the shaft even in A3 fractures [7]. The short intraHeal™ Proximal Femoral Nail Advanced is a superior implant for stable and unstable trochanteric fractures in terms of operating time, surgical

exposure, blood loss, and complications, especially for patients with relatively small femur [8]. In spite of the numerous theoretical advantages several studies have reported complications associated with the use of such nailing systems and the study also highlights issues to prevent such outcomes.

**Methods**

**Patients**

We carried out a descriptive retrospective study involving 468 patients with unstable peritrochanteric fractures (AO/OTA 31-A2, 31-A3) treated with after intraHeal™ Proximal Femoral Nail Advanced by GPC Medical Ltd at the department of Orthopedics, KK Hospital Delhi, India between January 2011 and January 2020.



**Inclusion criteria for the study**

Unstable peritrochanteric fractures (AO/OTA 31-A2, 31-A3)  
 Closed reduction and internal fixation by intraHeal™ Proximal Femoral Nail Advanced

**Exclusion criteria**

Patients with pathological fractures  
 Poly trauma.  
 Pre-operative Parker score <3  
 Post-operative Follow-up < 1 year  
 Preoperative assessment and data collection involved: patient

demographics, affected side, pre-injury ambulatory status by parker function score (Table 1), pre-existing Osteoarthritis changes at hip joint, fracture classification and morbidity assessment using American Society of Anaesthesiology Score (Table 2), and Harris hip score

Follow up was done regularly with physical examination and x-rays at monthly intervals up to 6 months/ bony union and yearly afterwards. Functional outcome was evaluated according to Parker’s score & Harris hip score for comparison as well as implant related complications were assessed in the course of follow-up.

**Table 1:** Parker score for mobility (0-9 scale) - score calculated preoperatively and postoperatively at 1 year follow up

Mobility	No Difficulty and No Aid	With a walking aid	With help from another person	Not at all
Able to get about the house (Indoor Walking)	3	2	1	0
Able to get out of the house (Outdoor Walking)	3	2	1	0
Able to go shopping to a restaurant or to visit family	3	2	1	0

**Table 2:** American Society of Anesthesiology (ASA) score for preoperative morbidity assessment

	Score ASA	N=	%
Healthy patient	1	56	14.81
Mild pathology	2	103	27.24
Moderate pathology	3	182	48.14
Severe pathology	4	37	9.78

**Operative technique**

All surgeons had over 10 years of experience of intramedullary nailing with helical blade systems and received training to implant specifics by GPC medical Ltd for using intraHeal™ Proximal Femoral Nail Advanced. The Surgeon were blinded to study and have role in data collection for post market surveillance projects by GPC Medical Ltd. Fracture reduction and fixation was performed on a traction table. Standard reduction manoeuvres were performed and limb remained in adducted position to facilitate entry through the tip of greater trochanter. The whole operative procedure

was performed under fluoroscopic guidance. Acceptable reduction was achieved prior to commencement of surgery.

Proximal part is manually overreamed by Entry reamer to accommodate broader proximal diameter of nail. The femur shaft was overreamed by 2 mm compared to distal diameters of the nail. Nail is inserted gently with manual pressure without hammering.

Ensure positioning of the helical blade in central portion of neck in both anteroposterior and lateral views. The tip of the screw should lie in the subchondral bone of the femoral head with a combined tip-apex distance less than 25 mm on anteroposterior and lateral radiographs as postulated by Baumgaertner *et al.* [9], Distal locking was done in all cases. Fractures which could not be acceptably reduced by a closed manoeuvre were managed by open reduction. All patients were allowed to walk with full weight-bearing with walker under supervision of a trained physiotherapist as soon as patient consents for gait training.

## Results

The patients were followed clinically and radiographically at monthly intervals till 6 months/bony union postoperatively, later on at 6 monthly interval. Range of motion was measured for both limbs with a goniometer. Functional assessment was done by parker scoring system and Harris Hip Score (HHS). Demographic data for the patient in study group is compiled in Table 3.

**Table 3:** Patient Demographic data

	Male	Female
Patients (n=378)	117	261
Age (years)	76 (26-93)	84 (65-91)
Average Parker score	8	6
Average Harris Hip score	87.2	78.9
low energy falls (n=364)	104	260
high energy trauma (n=14)	13	1
body mass index	29 ± 4	26 ± 4
AO/OTA 31-A2	89	216
AO/OTA 31-A3	28	45
Pre-existing OA changes	12	7

Co- author M.G assessed the patients radiographically, and was blinded to the clinical history and outcome of study group patients. Plain x-ray (anterior posterior and lateral view) of the pelvis and the injured hip were taken to assess bony union, deformity, post-operative complications, and osteoarthritis (Kellgren and Lawrence).

The study was performed after approval by the Ethics committee of the hospital fully abiding to Helsinki declaration. All the patients who agreed to participate in the study signed a written consent form.

### Range of motion

At one year follow up, significant difference was seen in range of hip motion among the injured and contralateral side as highlighted in Table 4.

**Table 4:** Range of Motion at Hip joint at one year of age

	Operated Limb	Normal Contralateral limb	P value
Flexion	111° ± 12	118° ± 11	p=0.001
Extension	8° ± 3	8° ± 4	p=0.002
Abduction	26° ± 5	30° ± 3	p<0.001
Adduction	18° ± 3	19° ± 5	p=0.001
Internal Rotation	23° ± 7	24° ± 8	p=0.002
External Rotation	30° ± 8	34° ± 6	p=0.003

### Imaging evaluation

Radiographic union was achieved at an average 3 months (8-14weeks) in 94.5% of cases, with satisfactory reduction in 84.6% of cases. The average neck-shaft angle was 122° ± 5° of the affected side and 124° ± 4° of the contralateral side at the final follow-up with no significant difference(p=0.326). No statistically significant difference was noted between the affected and the contralateral hip at the time of injury or at final follow-up.

Functional assessment using Parker score and Harris hip score parameters

### Parker score

Parker score was assessed by filling a questionnaire to determine patient's postoperative level of activity.

Harris Hip scoring was done on following parameters

**Pain:** Pain score was also assessed on 0-10 score with maximum pain scored at 10. Pain was constantly decreasing with time and was non-significant at three months post operatively. Pain was also compared to the pre fracture level due to pre-existing osteoarthritis and osteoporosis.

**Limping:** Apparent limp was observed in 34 patients of which 16 patients had varus deformity and 11 had femoral neck shortening. 2 patients had satisfactory reduction but limping persisted for 8 months and was considered due to intraoperative trauma to the hip abductors (failure to use soft tissue protection instruments during surgery). 4 patients had helical blade cut-out and required revision. One case developed haematoma at the nail entry site which got infected and required wound lavage and debridement. Limping persisted in this patient even at 1 year follow-up.

**Support:** At one year follow up, 191 patients used support for only for long distance walking, while 130 patients used support even for short distance walking and 57 patients did not require any support for walking.

**Walking distance:** 52 patients could walk pre-injury distance without any discomfort and it was decreased mildly in the 286 patients and 40 patients reported decrease in distance walked as compared with the pre fracture distance.

**Stairs:** 52 patients could ascend one flight of stairs without any handrail or support. Rest all the patients used handrail support to climb a flight of stairs.

**Sitting:** 305 patients could sit comfortably in ordinary chair. 73 patients needed high chair to sit comfortably. They were able to sit on normal hospital examination stool but felt discomfort on prolonged sitting.

**Wearing shoes:** 291 patients could wear their shoes without any discomfort. 69 patients reported difficulty in wearing their shoes.18 patients were unable to wear their shoes alone or did with discomfort.

**Deformity:** No cases of flexion, abduction deformity was seen. 27 patients developed leg length discrepancy up-to 2 cm that was treated by shoe modification.

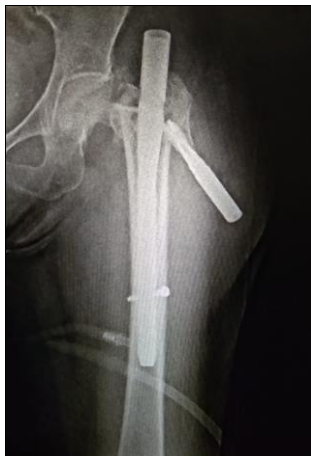**Range of motion:** The range of motion was assessed for each motion and record in the table. For purpose of Harris hip score the sum of degrees of flexion, abduction, adduction, internal and external rotation was calculated. Range of motion score was not decreased in 228 patients (score between 211-300 degrees). In 108 patients it was found to be decreased (between 161-210 degrees) and it was decreased in 42 patients (between 100-160 degrees).

Final Harris hip score was excellent in 91 patients (24%) as it ranged between (90-100), while it was good in 223 patients (59%) as it ranged 80- 89. It was fair in 27 patients (7%) as it ranged (70-79) and it was poor in 37 patients (10%) as it ranged less than 70.

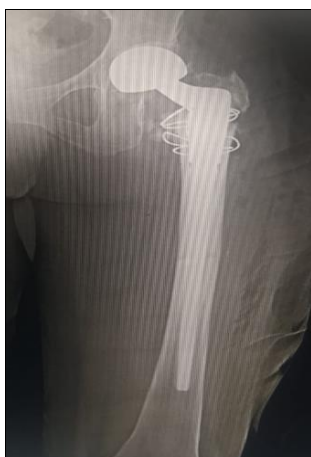### Complications

In 55 cases postoperative complications were recorded, of which 13 required major or minor surgical procedure. 9 patients had superficial infection for which they received intravenous and oral antibiotics. One patient had developed deep infection and required opening of surgical site, wound

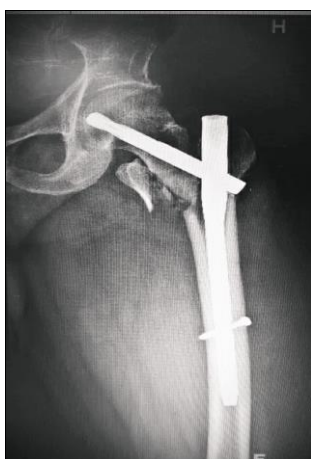lavage, debridement followed by prolonged antibiotic medication. No implant was changed, union was achieved at 4 months and no episode of infection was seen during 2 year follow-up. 3 cases of helical blade back out were observed at 2 months (Figure 1). On further evaluation it was observed that there were multiple attempts at insertion of helical blade. 2 of these cases underwent revision surgery with removal of implant and insertion of 1mm broader nail and insertion of newer generation implant with bone cement and helical blade. One case underwent total hip replacement as a revision procedure (Figure 2).



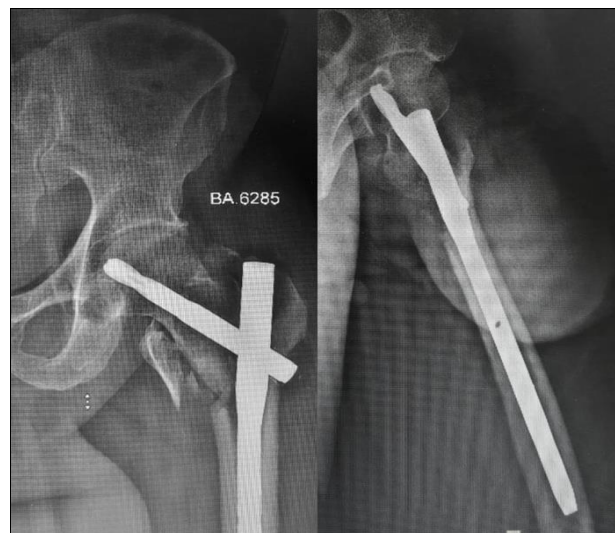
**Fig 1:** Back out of helical blade in early postoperative period



**Fig 2:** failure of nailing leading to revision with Total Hip Arthroplasty



**Fig 3:** Improper fracture reduction with failure to maintain medial calcar and inferior placement of helical blade (immediate post-op xray)



**Fig 4:** Three month follow up showing Varus malunion of the trochanteric fracture

4 cases with cervical screw cut-out were observed in early postoperative period. These cases the principles of fracture reduction were not followed. Cervical screw placement in superior or posterior region was considered as primary cause. 2 cases helical blade was 25mm short from subchondral bone in AP view and poor reduction hindered accurate assessment in lateral views.

5 patients suffered fracture in distal femoral region in early or late post-operative period. Peritrochanteric fracture had healed by the time of distal femoral fracture. These patients underwent open reduction and internal fixation with Intraheal™ distal femur locking plates by GPC Medical Ltd with locking screws in distal segment and unicortical screws and circlage wires for fixation of proximal fracture fragment. 32 patients had malunion of which 16 cases with varus malunion (figure 3 and figure 4), 5 in valgus and 11 cases with femoral neck shortening.

There were no incidence of intraoperative complications related to surgery or anesthesia in the present study. No adverse event from anaesthesia in the post-operative period was reported. All patients received prophylaxis for Deep Vein Thrombosis (DVT) with oral Ecospirin 75mg once a day for 3 weeks. Patients with pre-existing cardiac disease on clopidogrel were restarted the same after surgery. One patient developed DVT inspite of prophylaxis and was treated with low dose heparin.

### Discussion

Trochanteric fractures have been fixed using a variety of implants ranging from the Smith-Petersen nail in 1930 to Muller's (AO) blade-plate of the 1950's and Kuntscher's "Y" nail and Ender's nails as early as 1964. With introduction of Dynamic Hip Screw by Synthes, it changed the philosophy of trochanteric fracture fixation. Over the years the philosophy of cephalomedullary nailing with various nailing implants is considered superior fixation modality for trochanteric fractures including unstable variety. The intraHeal™ Proximal Femoral Nail Advanced forms a stable construct allowing early weight bearing, reducing morbidity and mortality associated with such injuries.

Various other studies (10) found favorable results with such nailing devices in managing a greater variety of hip fractures with a less invasive technique and with better results. Other studies have reported favorable results with in terms of

shorter operation time, less blood loss, shorter hospital stay, decreased wound infection and reduced complication rate [11].

The results regarding postoperative weight-bearing, operative time, fracture union time and functional results were also comparable to other studies [12, 13].

The ideal entry point of the nail is at the tip of or slightly medial to the greater trochanter, which is located posteriorly and laterally to the piriformis fossa. Anteriorly or posteriorly deviated helical blade position has been reported to be another factor for cut-out failure in several fixation devices. In our study, helical blade were placed more posteriorly and or superior and were shorter in the cut-out group than in the non-cut-out group. In unstable intertrochanteric fractures, there can be a posterior sagging of proximal fragments. To correct this displacement either raise the foot on a fracture-traction table or lift the proximal fragment by manual lifting in closed manoeuvre or open methods and use of Hohmann retractor. Reduction should be assessed prior to initiation of surgery. For Unstable fractures with posteromedial comminution, derotational K-wires can be placed away from the insertion trajectory of helical blade.

This study has some limitations. Firstly, it is a retrospective analysis of results of single centre for an unstable peritrochanteric fracture using single type of implant. Surgeons have expertise both in fracture reduction and fixation. Study lacked a control group with fixation using other implants. No scope of randomization as study is retrospective study. Secondly, since it's a single centre study, no data is available for varying geographical demography. Thirdly, due to few complications, no statistical tools could be applied to obtain meaningful results from these complications. This study gives a future guidelines to follow surgical steps to prevent complications and need of prospective trials with randomization and comparison with other nailing systems.

### Conclusions

Osteosynthesis with intraHeal™ Proximal Femoral Nail Advanced in unstable peritrochanteric fractures is a safe fixation method with extraordinary results. The main advantage of this procedure includes minimal invasive, less tissue damage, shorter operative time and better operative outcomes. intraHeal™ Proximal Femoral Nail Advanced is a load-sharing implant allowing early weight bearing and early return of functional status. Malunion is fairly common if initial reduction is not appropriate, however these radiographic outcomes have little to no functional implications on long term outcomes. All types of peritrochanteric fractures can be fixed with. intraHeal™ Proximal Femoral Nail Advanced. Careful evaluation of pre-operative x-rays, anatomical reduction and meticulous following of operative technique steps effectively reduce the incidence of complications.

### Acknowledgements

This study is funded by GPC medical Ltd. in terms of data collection, and statistics. Author S.C is an independent Orthopaedic Consultant who have received grants in past financial year by GPC Medical Ltd. for conducting workshops, implant and instrument related research and consultation. For writing of this original research, no financial assistance was given to Author S.C or any other Co-authors. Surgeons associated with surgical procedures have attended various workshops by GPC Medical Ltd GAITs academy. The study was done by retrospective analysis of data.

### References

1. Koval JK, Cantu RV. Trochanteric fractures. In: Bucholz RW, Heckman JD, Court-Brown CM, Rockwood and Green fractures in adults. (6th edn), Lippincott Williams & Wilkins, Philadelphia 2010, 1793-1825.
2. Isida R, Bariatsky V, Kern G *et al.* Prospective study of the reproducibility of X-rays and CT scans for assessing trochanteric fracture comminution in the elderly: a series of 110 cases. *Eur J Orthop Surg Traumatol* 2015;25(7):1165-1170.
3. Hommel A, Ulander K, Bjorkelund KB *et al.* Influence of optimised treatment of people with hip fracture on time to operation, length of hospital stay, reoperations and mortality within 1 year. *Injury* 2008;39(10):1164-1174.
4. Haleem S, Lutchman L, Mayahi R *et al.* Mortality following hip fracture: trends and geographical variations over the last 40 years. *Injury* 2008;39(10):1157-1163.
5. Rogerio Naim Sawaia, William Dias Belangero. The treatment of trans-trochanteric fractures of the femur with a minimally invasive technique using an extramedullary implant MINUS system. *Int Orthop* 2008;32:159-165.
6. Kyle RF. Fractures of the proximal part of the femur. *J Bone Joint Surg Am* 1995;76:924-950.
7. Saudan M, Liibbeke A, Sadowski C, Riand N, Stern R *et al.* Pertrochanteric fractures: is there an advantage to an intramedullary nail? A randomized, prospective study of 206 patients comparing the dynamic hip screw and proximal femoral Nail. *J Orthop Trauma* 2002;16:386-393.
8. Gadegone WM, Salphale YS. (Hong Kong) Short proximal femoral nail fixation for trochanteric fractures. *J Orthop Surg (Hong Kong)* 2010;18:39-44.
9. Baumgaertner MR, Curtin SL, Lindskog DM, Keggi JM. The value of the tipapex distance in predicting failure of fixation of pertrochanteric fractures of the hip. *J Bone Joint Surg Am* 1995;77:1058-1064.
10. Landolt M. Comparison and presentation of technique and results of the gamma nail and dynamic hip screw. *Helv Chir Acta (Switzerland)* 1993;59:965-969.
11. Miedel R, Ponzer S, Tornkvist H, Soderqvist A, Tidermark J. The standard Gamma nail or the Medoff sliding plate for unstable trochanteric and subtrochanteric fractures. A randomised, controlled trial. *J Bone Joint Surg Br* 2005;87:68-75.
12. Goldhagen PR, O'Connor DR, Schwarze D, Schwartz E. A prospective comparative study of the compression hip screw and the Gamma nail. *J Orthop Trauma* 1994;8:367-372.
13. Baumgaertner MR, Chrostowski JH, Levy RN. Inter trochanteric hip fractures. In: Browner BD, Levine AM, Jupiter JB, Trafton PG, Skeletal trauma. WB Saunders, Philadelphia 1998, 1833-1881.