



E-ISSN: 2395-1958  
P-ISSN: 2706-6630  
IJOS 2021; 7(4): 97-100  
© 2021 IJOS  
www.orthopaper.com  
Received: 12-08-2021  
Accepted: 15-09-2021

**Dr. Arul kumar**  
Nallakumarasamy  
Senior Resident, AIIMS  
Bhubaneswar, Odisha, India

**Dr. Rahul Yadav**  
Deptt of Orthopaedics, Junior  
Resident IMS BHU, Varanasi,  
Uttar Pradesh, India

**Dr. Birju Manjhi**  
Associate Professor IMS BHU,  
Varanasi, Uttar Pradesh, India

**Dr. Deepak Rai**  
Assistant Professor, Heritage  
institute of Medical Sciences  
Varanasi, Uttar Pradesh, India

**Corresponding Author:**  
**Dr. Arul kumar**  
Nallakumarasamy  
Senior Resident, AIIMS  
Bhubaneswar, Odisha, India

## A rare case of osteoblastoma of calcaneum with secondary aneurysmal cyst like changes and its management: A case report

**Dr. Arul Kumar Nallakumarasamy, Dr. Rahul Yadav, Dr. Birju Manjhi and Dr. Deepak Rai**

**DOI:** <https://doi.org/10.22271/ortho.2021.v7.i4b.2870>

### Abstract

**Background:** Osteoblastoma is a rare bone forming neoplasm and it is very rare to present with secondary cystic changes that too in the heel bone. The incidence is <0.6 % among all and its prevalence is yet to be reported in our population owing to its rare presentation the early diagnosis of Osteoblastoma of Calcaneum with secondary aneurysmal cyst like changes are difficult and hence affects the outcome.

**Material:** In this report we detailed the diagnostic methods and surgical management of osteoblastoma of calcaneum associated with secondary aneurysmal cyst like changes in a 12year old boy with 2 year follow up.

**Result:** It shown that the expansile lytic lesion was healed at appropriate time period and ankle & subtalar range of movements were satisfactory with no limitation in inversion and eversion.

**Conclusion:** Benign expansile bone tumors in heel bone are difficult to find in the literature. This study addresses the diagnostic modality, proper surgical management in terms of approach and using sandwich bone grafting technique to improve the long term functional outcome.

**Keywords:** Osteoblastoma of calcaneum, secondary aneurysmal cyst like changes, curettage and bone grafting

### Introduction

Osteoblastoma is a rare bone forming neoplasm. It accounts for about 1 to 2% of all the bone tumors <sup>[1]</sup>. Most cases presented as intra-osseous, well circumscribed lytic lesion in the adolescent bone mostly spinal elements <sup>[2]</sup>.

It is rare for this benign tumor to present in small bones with bone cyst like changes. Hence these lesions cause considerable diagnostic challenge. This report presents a rare case of osteoblastoma of the calcaneum which was initially diagnosed clinically, radiologically and grossly to be either an aneurysmal bone cyst or a giant cell tumor.

### Case Report

A 12year old boy hailing from north-east India presented us with pain and swelling in the right heel and ankle of about 5 months duration. The pain started insidiously and progressive in nature with no history of any trauma. The pain was dull aching, progressive, aggravated while standing and walking, localised to right heel and ankle, there is no nocturnal variations. The diffuse swelling localised around the lateral aspect of the heel developed subsequently after 2 months and it is not associated with any constitutional symptoms like fever or loss of weight. There was no history any other localised mass, no other medical co-morbidities and no history of any previous surgeries. He was prescribed analgesics for a month, but the pain was not subsided. On general examination the boy was moderately built, mild pallor, no oedema, no generalised lymphadenopathy. He was afebrile with stable vitals.

On local examination there was a diffuse swelling around the lateral aspect of the heel. There was no redness, scars, sinuses but dilated veins are seen as shown in fig1. No gross bony deformity noted. The region was tender, not warmth, it has smooth surface, well defined margin, uniform firm to hard in consistency, immobile, irreducible and non-pulsatile oval swelling measuring about 5x3cm.

No proximal lymphadenopathy and distal neurovascular deficit. There is no restrictions in the range of movements in tibio-talar, sub-talar joint and no limb length discrepancy noted.

### Investigations

1. All biochemical parameters are within normal limits.
2. Imaging:

X-ray heel lateral and axial view shows a well-defined lytic lesion at initial diagnosis and with 3 months of conservative treatment the lesion was expanded as shown in fig2.

CT calcaneum shows expansile osteolytic peripherally enhancing lesion extending up to medial, lateral and anterior sub-cortical regions with medial cortical breach. Superiorly extending into subarticular region of anterior and mid facet joints as shown in fig3.

### Operative management

Under the effect of spinal anaesthesia patient shifted to operative table in supine position with tourniquet support, painting and draping of the region and ipsilateral iliac region done. An oblique incision started just anterior and an inch proximal to the insertion of Achilles tendon passed downwards toward base of 5<sup>th</sup> metatarsal bone. Dissection proceeded further to make a full thickness flap and by detaching the fibulo-calcaneal and talocalcaneal ligaments from the bone. The peroneal tendons and the sural nerve are within the flap and are retracted superiorly and the bone is exposed.

The lateral wall is found to be thinned out, membranous in nature. An incision of about 2cm given in the lateral wall to open the cortex and grossly the tissue is found to be haemorrhagic, granular, and friable and the consistency resembles that of cancellous bone as shown in fig4. It is found that there is a breach in the medial cortex, the lesion is completely curetted out meticulously without any further breach and the contents sent for histopathological examination as shown in fig5. The cavity is filled with bone graft harvested from ipsilateral iliac crest and with Chron OS (synthetic bone graft substitute) in a sandwich manner.

Wound closure done in layers and sterile dressings made. Immediate postoperative x-ray shows well implanted graft in the specified region as shown in fig 6, below knee slab support was given for 6 weeks and he was followed up for 2 years, the results were shown improved clinical and radiological outcome as shown in fig7.

### Discussion

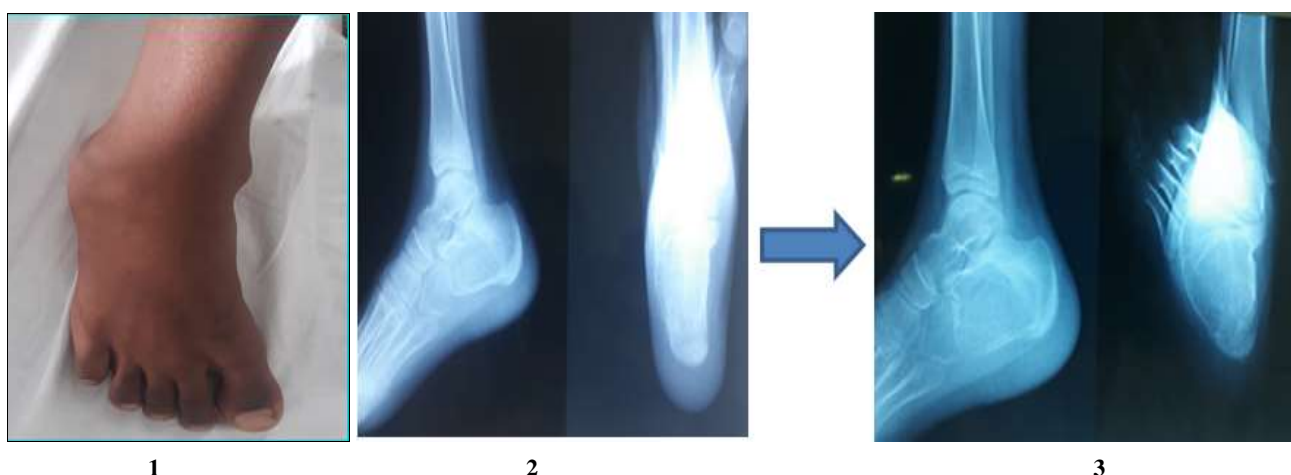Osteoblastoma is a rare bone forming primary benign bone tumor predominantly seen in first and second of life<sup>3</sup>, with a ratio of M:F-2.5:1. It is most commonly seen in posterior elements of spine and rarely diagnosed in small bones. Diagnosis is confirmed when the size of the lesion is more than 2cm and histologically by the presence of haphazardly arranged osteoblasts<sup>4</sup>.

Aneurysmal bone cysts are primary benign bone lesions usually seen in second decade of life affects most commonly femur, humerus and rarely small bones. Secondary aneurysmal bone cysts are seen in conditions such as osteoblastoma, giant cell tumor, fibrous dysplasia and so on<sup>5</sup>.

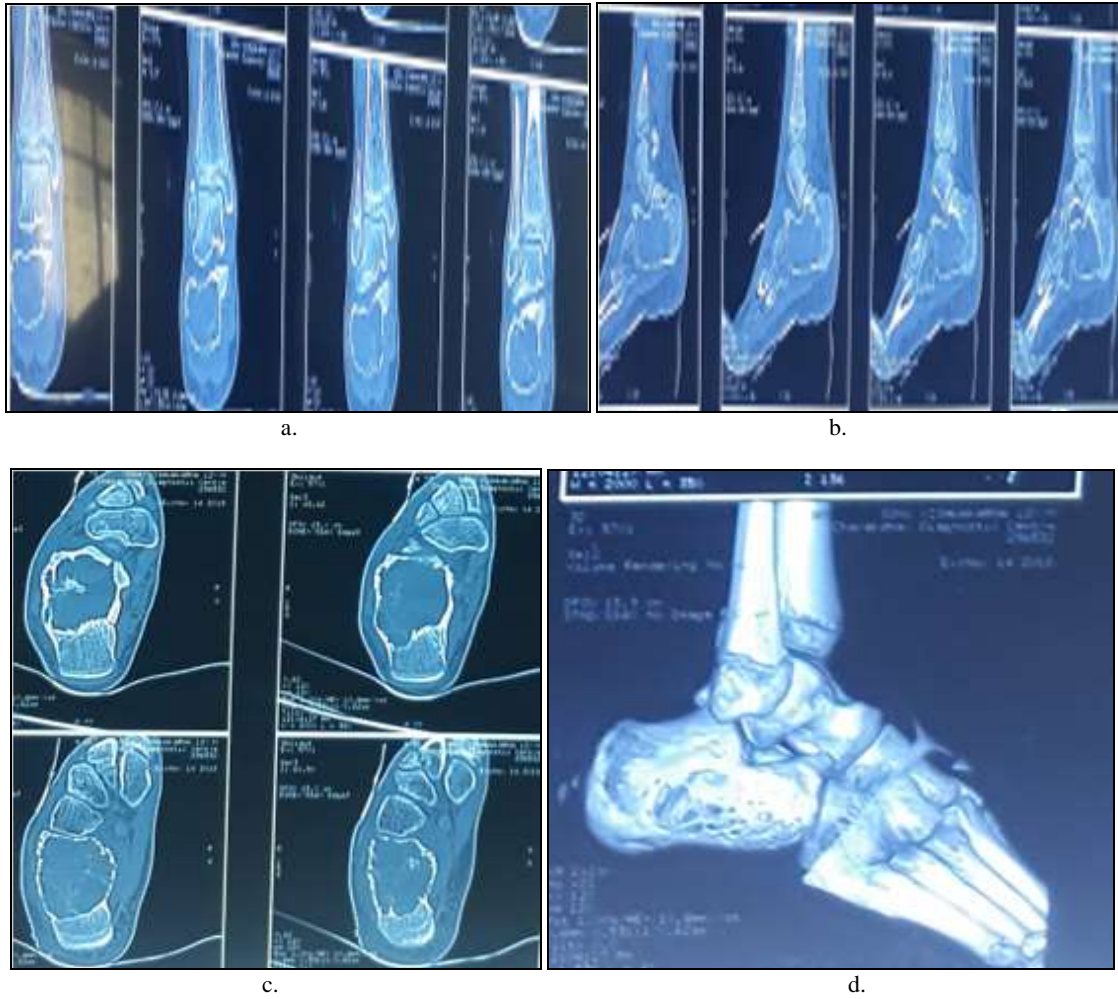
Hangtaou *et al.*<sup>6</sup>. Described a case of 11year-old child diagnosed with destructive osteoblastoma with secondary aneurysmal bone cyst involving C4 vertebra which was managed with surgical fusion, histologically it showed meshwork of osteoid trabeculae rimmed by osteoblasts embedded in fibro-vascular stroma.

Pavanello *et al*<sup>7</sup>., described a case of 2year old child diagnosed with osteoblastoma with secondary aneurysmal bone cyst affecting lumbar vertebra with its pathogenesis and surgical management.

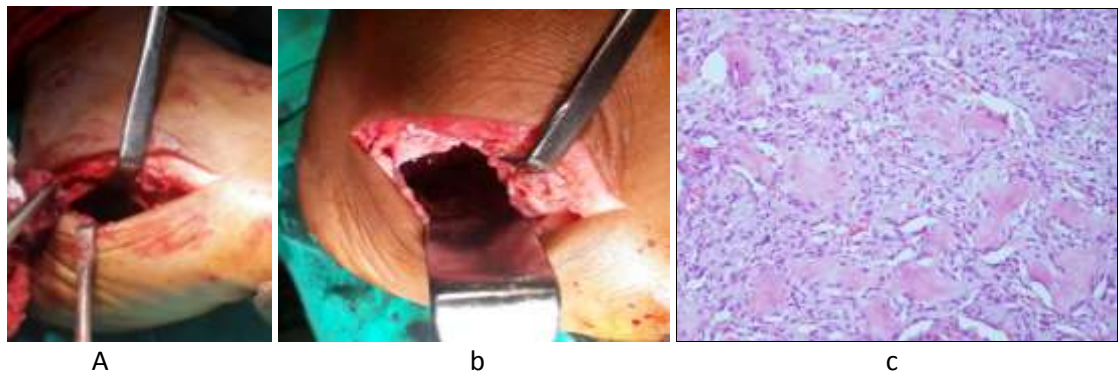
Some reports have been found in literature describing osteoblastoma of the spine with secondary aneurysmal cystic like changes, however our report shows a rare case of expansile lytic lesion of the calcaneum which makes a differential diagnosis of either an aneurysmal bone cyst or a giant cell tumor on initial clinical and radiological evaluation. But final histological diagnosis was proven to be osteoblastoma with secondary aneurysmal cyst like changes with no mitosis or nuclear pleomorphism.



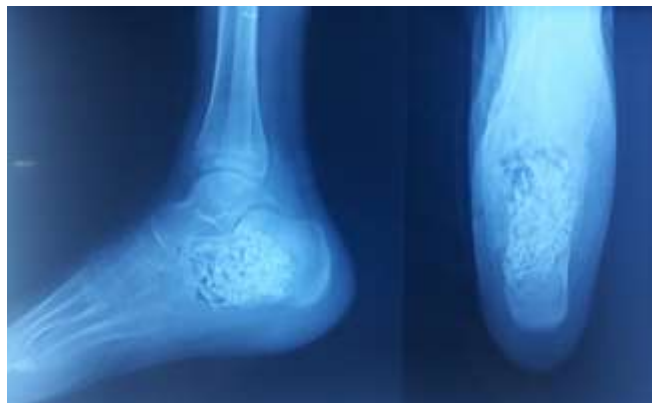
**Fig 2:** well-defined, expansile, lytic lesion on the entire calcaneum sparing the tuberosity with disease progression at 3 months interval.



**Fig 3:** Coronal (a), Sagittal (b), Axial (c), 3D (d) CT images of the calcaneum

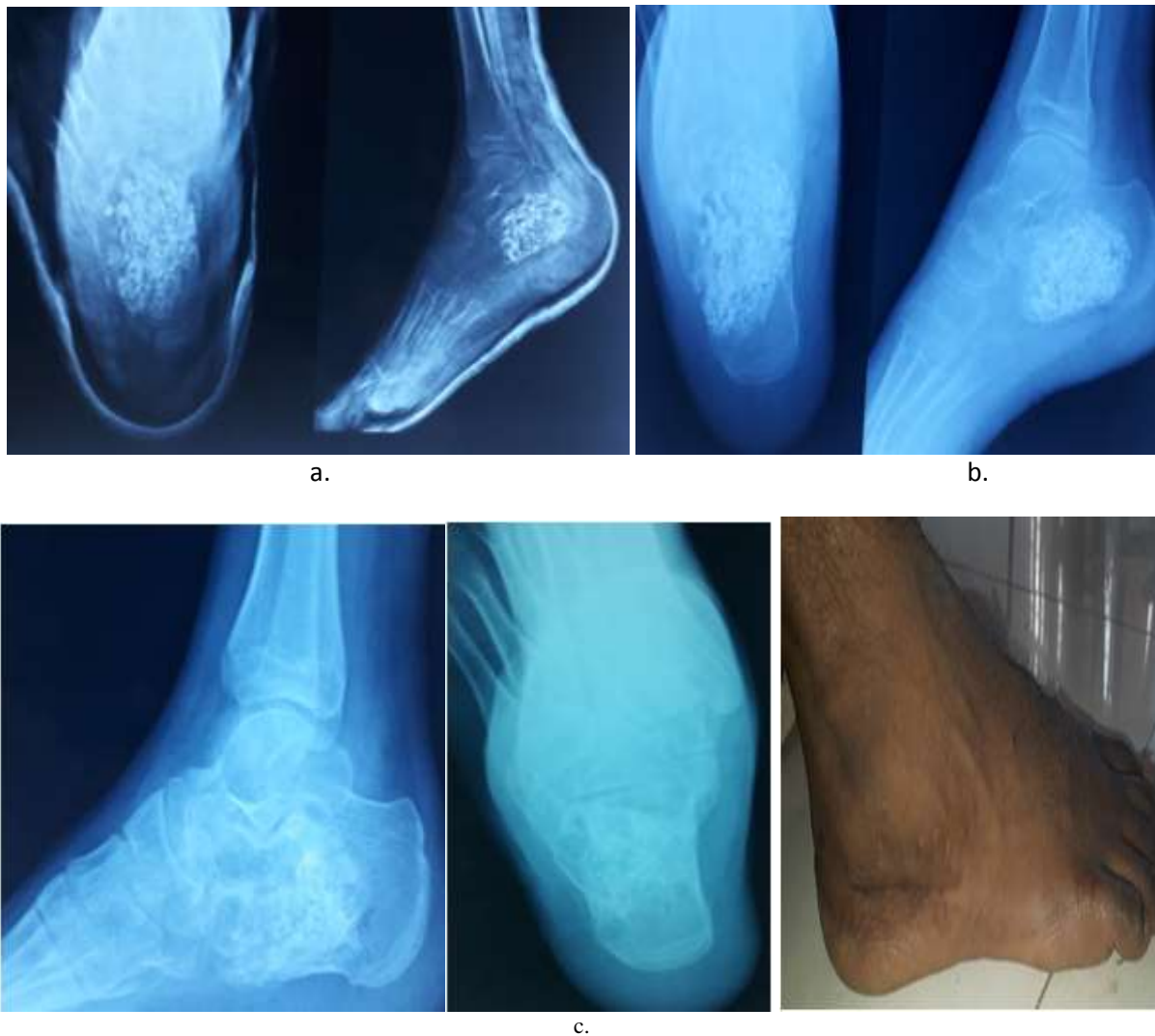


**Fig 5:** It shows single layer of benign activated osteoblasts with numerous osteoclast giant cell and loose fibrovascular stroma with intralesional haemorrhage.



**Fig 6.**





**Fig 7:** Follow up at 6 weeks (a), 8 months (b) and 2 years (c).

### Conclusion

Bone tumors when presented as expansile lytic lesion in small bones makes diagnostic difficulties. Our case report guide readers that a rare entity of osteoblastoma of calcaneum can present with such a feature and associated with aneurysmal cyst like changes histologically. It helps us to overcome the diagnostic challenge and to plan appropriate management earlier, which further augments the functional outcome.

**Conflict of interest:** The author declares no conflict of interest involved in this study.

**Consent:** Informed written consent has been obtained from the parent.

### References

1. McLeod RA, Dahlin DC, Beabout JW. The spectrum of osteoblastoma. *AJR Am J Roentgenol* 1976;126(2):321-5.
2. Amacher AL, Eltomey A. Spinal osteoblastoma in children and adolescents. *Childs Nerv Syst* 1985;1:29-32.
3. Huvos AG. Bone tumors: Diagnosis, treatment and prognosis. Philadelphia: W.B Saunders Co 1979, 33-46.
4. Zileli M, Cagli S, Basdemir G, Ersahin Y. Osteoid osteomas and osteoblastomas of the spine. *Neurosurg Focus* 2003;15:E5.
5. Saccomanni B. Aneurysmal bone cyst of spine: a review of literature. *Arch Orthop Trauma Surg* 2008;128:1145-7.
6. Marco Pavanello, Ilaria Melloni, Pietro Fiaschi, Alessandro Consales, Gianluca Piatelli, Marcello Ravegnani *et al.* A rare case of osteoblastoma associated to aneurysmal bone cyst of the spine. Case report. *Br J Neurosurg* 2016;30(1):106-9.
7. Hongtao Hu, Jianxin Wu, Liang Ren, Xianze Sun, Feng Li, Xiaojian Ye. Destructive osteoblastoma with secondary aneurysmal bone cyst of cervical vertebra in an 11-year-old boy: case report. *Int J Clin Exp Med* 2014;7(1):290-5.
8. Mishra A, Pruthi N, Nandeesh BN, Shukla D. Cervical Spine Osteoblastoma with an Aneurysmal Bone Cyst in a 2-Year-Old Child: A Case Report. *Pediatr Neurosurg*. 2019;54(1):46-50.
9. Balancing spinal stability and future mobility in the cervical spine: surgical treatment of a case of osteoblastoma with secondary aneurysmal bone cyst. Ramme AJ, Smucker JD. *Spine J*. 2011;11(5):e5-12.
10. Tarantino R, Piccirilli M, Anichini G, Delfini R. Benign osteoblastoma of the odontoid process of the axis with secondary aneurysmal bone cyst component: a case report. *Neurosurg Rev* 2008;31:111-5.