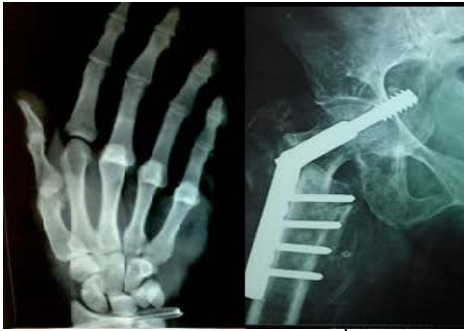



# International Journal of Orthopaedics Sciences

E-ISSN: 2395-1958  
P-ISSN: 2706-6630  
IJOS 2021; 7(3): 801-805  
© 2021 IJOS  
[www.orthopaper.com](http://www.orthopaper.com)  
Received: 07-05-2021  
Accepted: 09-06-2021

**Anand Gupta**  
Fellow National Board (FNB),  
Department of Orthopaedics,  
PGIMS, Rohtak, Haryana, India

**Abhishek Garg**  
Senior Resident, Department of  
Orthopaedics, PGIMS, Rohtak,  
Haryana, India

**Ankur Sahu**  
Senior Resident, Department of  
Orthopaedics, PGIMS, Rohtak,  
Haryana, India

**Umesh Yadav**  
Associate Professor, Department  
of Orthopaedics, PGIMS,  
Rohtak, Haryana, India

**Manmeet Malik**  
Junior Resident, Department of  
Orthopaedics, PGIMS, Rohtak,  
Haryana, India

**Aditya Seth**  
Junior Resident, Department of  
Orthopaedics, PGIMS, Rohtak,  
Haryana, India

**Nishan Yadav**  
Junior Resident, Department of  
Orthopaedics, PGIMS, Rohtak,  
Haryana, India

**Rahul Kumar**  
Junior Resident, Department of  
Orthopaedics, PGIMS, Rohtak,  
Haryana, India

**Corresponding Author:**  
**Abhishek Garg**  
Senior Resident, Department of  
Orthopaedics, PGIMS, Rohtak,  
Haryana, India

## A rare case of Symptomatic Bipartite Patella in an adolescent male with review of literature and our experience

**Anand Gupta, Abhishek Garg, Ankur Sahu, Umesh Yadav, Manmeet Malik, Aditya Seth, Nishan Yadav and Rahul Kumar**

**DOI:** <https://doi.org/10.22271/ortho.2021.v7.i3l.2838>

### Abstract

A bipartite patella results from the failure of the ossification centres to unite, resulting in a fibrocartilaginous union between the bipartite fragment and patella body. Fibrocartilaginous interface is present between the accessory and main patella. A bipartite patella is usually an incidental finding and can be hard to distinguish from a patella fracture. Here, we present a case of bipartite patella in 16 year old male and its further management.

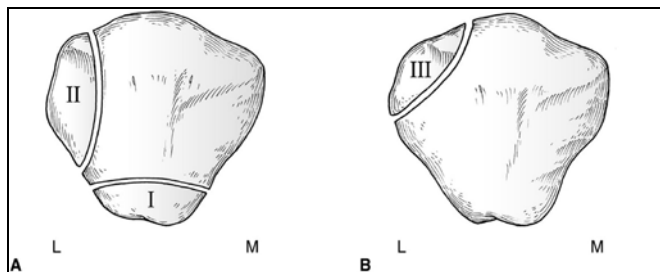
**Keywords:** patella, bipartite, fibrocartilaginous, surgery

### Introduction

The patella is the largest sesamoid bone in human body, positioned longitudinally in the quadriceps muscle fascia, between the quadriceps and patellar tendons. It plays an important role in knee biomechanics and provides anterior coverage of the knee joint. It develops initially as an expanding mass of cartilage with ossification beginning between the ages of 3 and 5 years and continuing until 9–10 years. It usually develops from a single ossification center. It is hypothesized that if this fusion does not occur, two or more ossification centers remain. In some cases it develops two (bipartite) or more ossification centers. A bipartite patella therefore results from the failure of the ossification centres to unite, resulting in a fibrocartilaginous union between the bipartite fragment and patella body. Fibrocartilaginous interface is present between the accessory and main patella<sup>[5,6]</sup>.

Bipartite patella is considered a normal variant of the patella and is present in 1-2% of the population<sup>[2]</sup>. The anomaly is bilateral in approximately 50% of individuals<sup>[3]</sup>. Bipartite patella is considered a developmental variation of ossification and may be an asymptomatic, incidental finding<sup>[4]</sup>. Symptomatic bipartite patella usually occurs in adolescent males or young athletes and may be a cause of anterior knee pain<sup>[2]</sup>. Only 2% of patients have symptoms. These usually comprise of anterior knee pain and tenderness on palpation of the accessory fragment. Two basic mechanisms are accepted as the triggering factors for symptoms: a single, direct trauma and repetitive minor injuries. A commonly accepted hypothesis is that the traumatic effect of either of the two mechanisms on this fragile interface causes the symptomatic form of bipartite patella causing pain and discomfort<sup>[7]</sup>. Painful nonunion may develop because cartilage has only limited ability for repair, and repair from the adjacent bone is generally inadequate. Batten and Menelaus suggested that fragment separation may be a further form of traction osteochondritis of the attachments of the quadriceps mechanism<sup>[8]</sup>. It has been proposed that continued traction forces on the fractured fragment also may prevent union<sup>[9]</sup>.

Saupe<sup>[2]</sup> described the most frequently used classification of bipartite patellae, which is based on the position of the accessory ossification centre. Type I (5%) is characterised by a transverse split and the accessory centre at the inferior pole, in type II (20%) there is a longitudinal split and the accessory centre is found at the lateral margin of the patella, and in type III (75%) the accessory centre is found at the superolateral pole of the patella. However, Saupe's classification has been criticised as it is only based on location of the accessory fragment. It does not take into account aetiology and does not cater for the tripartite patellae or the rare medial bipartite patella<sup>[2]</sup>.



**Fig 1:** Saupé's classification of Bipartite patella

### Saupé's classification of Bipartite patella

A bipartite patella is usually an incidental finding and can be hard to distinguish from a patella fracture. Weight-bearing skyline views taken with the patient in a squatting position may demonstrate further separation of the accessory fragment from the main patella compared with non-weightbearing skyline views [5] In questionable cases, scintigraphy may be helpful in the diagnosis of symptomatic bipartite Patella [10, 11] Increased localized radiotracer uptake around the fragment represents stress caused by mobility along the chondroosseous junction [12].

Magnetic resonance imaging (MRI) has been described by Kavanagh *et al.* [13] as an appropriate method of assessing a patient with bipartite patella and anterior knee pain. They suggested that identification of edema at or adjacent to the bipartite fragment by MRI may indicate that bipartite patella is the primary cause of symptoms.

The large majority of cases are successfully managed with conservative treatments, such as rest, non-steroidal anti-inflammatory medication, immobilisation and physiotherapy, although there is no literature base to support this method of treatment. Local steroid injection may provide sufficient relief of pain to avoid surgery in the patient with symptomatic bipartite patella [14] In general, nonsurgical management should be tried for a minimum of 6 months. However, surgery may be justified earlier in cases in which a reduction of the displaced fragment is necessary, the onset of pain is related to

direct trauma, and daily activity is not tolerated [15, 16]. Several surgical methods for the treatment of the most common supero-lateral bipartite patella have been described. The most commonly used are: vastus lateralis release, lateral retinacular release technique or excision of the painful accessory fragment, and all these methods can be done either by open procedure or using arthroscopic technique.

### Case Report

#### Subject Presentation

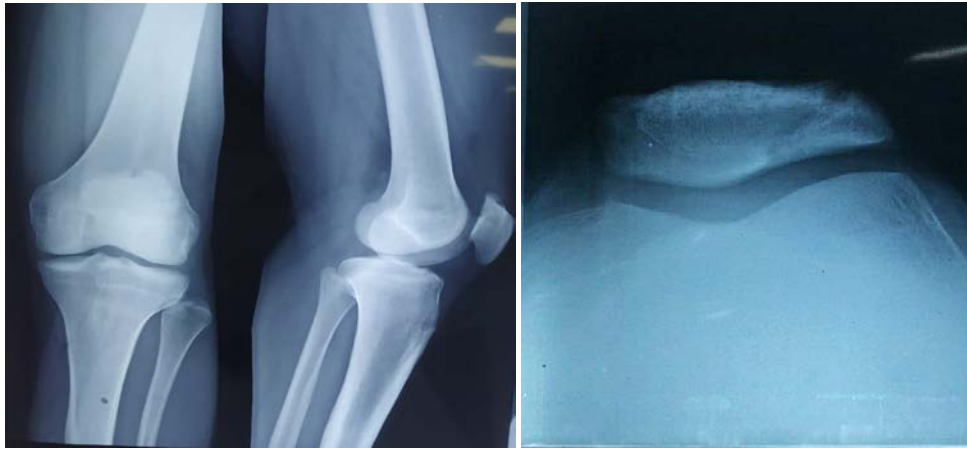A 16 year male complains of pain in left knee since 2 years. Pain was non progressive dull aching type of moderate intensity, non radiating. There was no history of trauma or injury. Pain intensified with activities like running, jumping, climbing stairs, squatting and other sports activities. He also complained of appreciable swelling in left knee after strenuous activities. He consulted doctor and had been prescribed Non steroidal anti inflammatory drugs with Hot fomentation following which pain subsided for few days and reappeared.

#### Examination

Physical examination of left knee revealed tenderness over the supero-lateral patellar pole. Based on negative tests including the Lachman, pivot shift, anterior and posterior drawer, Apley, McMurray, and varus/valgus stress tests meniscal and ligaments injuries were ruled out. A visible deformity and thickening over the supero- lateral patellar pole was present. This was the most painful area of the knee. The subject scored 66 in Left knee on the Kujala Scoring Questionnaire [23] for patient reported outcomes related to patellofemoral dysfunction. This scoring system is designed to evaluate subjective symptoms and functional limitations in patients with patellofemoral pain and dysfunction. Minimum score is 0 and maximum is 100, the higher the score the better the function of the knee [23]. Examination of Right knee was normal with 100 Kujala score.

**Table 1:** Kujala Score Before and After Surgery

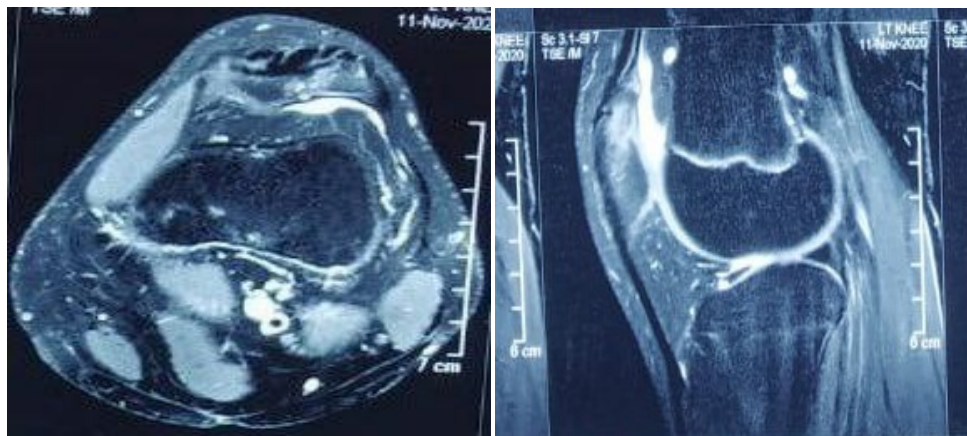
Parameter	Before surgery		At 6 months after surgery		Maximum score possible
	Right knee	Left knee	Right knee	Left Knee	
Limp while walking	5	3	5	5	5
Support	5	5	5	5	5
Walking	5	3	5	5	5
Using stairs	10	8	10	10	10
Squatting	5	4	5	5	5
Running	10	8	10	8	10
Jumping	10	2	10	10	10
Prolonged sitting	10	8	10	10	10
Knee pain	10	6	10	10	10
Knee swelling	10	6	10	10	10
Subluxations	10	6	10	10	10
Tight muscle atrophy	5	3	5	5	5
Flexion deficiency	5	3	5	5	5
Total score	100	66	100	98	100



**Fig 2:** Standard radiographic examination (Anterior-posterior and skyline views) revealed a bipartite patella at the supero-lateral pole of the patella in Left knee.

Further imaging techniques were scheduled to assess soft tissue structures around the knee joints. Left Knee MRI examination shows patchy PD/ SPIR hyper intensity involving superolateral aspect of patella with similar signal in adjacent bony fragments suggesting bipartite patella with subchondral edema. The gaps between bony fragments and

the bodies of the patella were filled by dense fibrous, heterogeneous tissue. The hyaline cartilage beneath the lateral poles of the patellae appeared heterogeneous with increased width. No other abnormalities of soft tissue structures around the patellae and knee were reported.

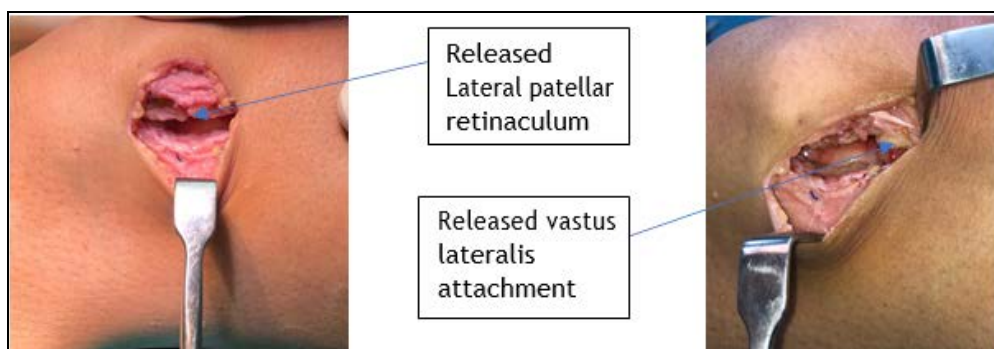


**Fig 3:** MRI Left Knee Axial and Saggital Sections Showing Superolateral Bipartite Patella with Subchondral Edema

**Management**

A trial of conservative treatment given in form of rest, ice packs, NSAIDs & physiotherapy which included stretching & strengthening exercises of quadriceps & hamstrings. But the symptoms did not improve. The operative treatment was discussed with the patient, consent was taken for surgery. Under Spinal anaesthesia, 3 cm longitudinal lateral skin incision taken over middle and superolateral aspect of patella, subcutaneous plane was reached. Lateral patella retinaculum identified. A strip of 0.5 to 1 cm wide and 6 cm long lateral

retinaculum was excised subcutaneously. Superolaterally thickened Vastus lateralis tendon was splitted along its middle fibres and its insertion to painful patellar fragment was detached subperiosteally. Heamostasis was maintained. Surgical wound closed in layers with sutures. Postoperatively patient was immediately allowed to walk its full weight bearing and was encouraged to do Knee ROM exercises. Sutures were removed after 2 weeks. Sports activity was allowed by 6 weeks. Follwup was done for 6 months.



**Fig 4:** Shows Released lateral patellar retinaculum and released vastus lateralis attachment

## Results

As a result of surgery, pain and tenderness around lateral patellofemoral joint and lateral aspect of the patella disappeared after surgery. Kujala score of Left knee improved to 98 at 6 months. After improvement patient was tested with single leg squat, leg crossover hop, vertical jump and four hop double leg jump with no pain and discomfort during exercises. Full painless range of motion was achieved in Left knee. Patient returned to his sport activity with no pain during squats, cycling and jumping.

## Discussion

A bipartite patella results from the failure of the ossification centres to unite, resulting in a fibrocartilaginous union between the bipartite fragment and patella body. This avascular fibrocartilaginous tissue in the gap may prevent an accessory ossification center from allowing unification with the main portion of the patella.

Additionally, the accessory fragment may be pulled aside by soft tissue structures like lateral patella retinaculum & vastus lateralis; mechanism which also inhibits bony union like in avulsion type fractures.

In painful bipartite patella the lateral retinaculum and part of attachment of the vastus lateralis to the patella exert a sustained lateral force on the patella, including the separated fragment. To compound this condition, sports activities exert a lateral traction force on the separated fragment of an otherwise indolent bipartite patella, thus causing abnormal motion of the separated fragment.

Some authors report initial onset of clinical symptoms like pain in those with bipartite patellae after trauma or overuse activities, which may be explained by "overstretching" of the fibrous gap<sup>[17]</sup>.

Several surgical techniques were advocated. The most widely advocated surgical treatment of painful bipartite patella is excision of the fragment<sup>[17-20]</sup> Bourne and Bianco<sup>17</sup> evaluated the results of surgical excision in 16 patients with symptomatic bipartite patella. Ishikawa *et al.*<sup>[5]</sup> reported excellent results following excision in a series of nine patients. A criticism of open excision has been the invasiveness of the technique, which requires an incision down to the quadriceps tendon along with patellofemoral incongruity in the long term in case of relatively longer accessory fragment.

Lateral retinacular release has been advocated as a method of releasing the persistent traction forces of the vastus lateralis muscle and lateral retinaculum on the accessory fragment. The goal with this technique is to alleviate the abnormal motion at the fibrocartilaginous interface between the fragment and the main patella. Mori *et al.*<sup>[22]</sup> performed a longitudinal incision on the lateral aspect of the midpatella with an extension to the proximal attachment of the separated fragment. The authors reported excellent clinical results and bony union of the separated fragment in 11 of 15 patients (16 knees).

Adachi *et al.*<sup>[9]</sup> demonstrated that the traction force of the vastus lateralis muscle can be reduced by releasing only the attachment of the vastus lateralis to the fragment without performing a long lateral retinacular release. In all patients, they observed the disappearance of tapping pain over the fragment within 4 weeks and return to preoperative level of sports activities within an average of 3 months.

In our case study, the patient's symptoms were relieved postoperatively with lateral retinaculum release along with vastus lateralis release. The Kujala scoring for patellofemoral

syndrome has increased from 66 preoperatively to 98 at 6 months postoperatively which shows excellent result.

Often, surgery is not seriously considered in the treatment of painful bipartite patella since patients do not experience intolerable pain or limitation of their daily living activities. However, many of the patients are athletes and their pain may arise not only from a bipartite patella but also from excessive lateral pressure Syndrome or Patellofemoral syndrome. Judicious use of surgery may warranted. In this sense a modified-lateral retinaculum release along with vastus lateralis release to deserve recommendation as a surgical technique for early relief of pain and early bone union after surgery.

## Limitations

There were few limitations regarding this case report. The findings from a case report cannot be generalized to all subject populations. High quality randomized control trials are needed to document lateral patella retinacular and vastus lateralis release in treatment of bipartite patella pain. The subject was treated with conservative treatment before the described procedures, which could also have had some effect on the presentation or resolution of knee pain over time.

## Conclusion

Bipartite patella should be considered as a possible source of anterior knee pain in the adolescent patient. Clinical history, physical examination, and a squatting skyline view of the knee should be combined with MRI to differentiate between symptomatic and asymptomatic bipartite patella. Modified lateral retinacular and vastus release gave excellent result in our case with 98 points on Kujala scoring and it must be considered for bipartite patella patients for whom nonsurgical treatment fails.

## References

1. Zabierek S, Zabierek J, Kwapisz A *et al.* Bipartite patella in 35 years old fitness instructor; a case report. *Int J Sports Phys Ther* 2016;11(5):777-783.
2. Saupé H. Primäre Krochenmark serelung der kniescheibe. *Deutsche Z Chir* 1943;258:386-392.
3. Insall J. Current concepts review: Patellar pain. *J Bone Joint Surg Am* 1982;64:147-152.
4. Ogden JA, McCarthy SM, Jokl P. The painful bipartite patella. *J Pediatr Orthop* 1982;2:263-269.
5. Ishikawa H, Sakurai A, Hirata S *et al.* Painful bipartite patella in young athletes: The diagnostic value of skyline views taken in squatting position and the results of surgical excision. *Clin Orthop Relat Res* 1994;305:223-228.
6. Puddu G, Mariani P, Alzani R. Detachment of the accessory fragment in "patella partita." *Ital J Orthop Traumatol* 1978;4:197-203.
7. Green WT Jr: Painful bipartite patella: A report of three cases. *Clin Orthop Relat Res* 1975;110:197-200.
8. Batten J, Menelaus MB. Fragmentation of the proximal pole of the patella: Another manifestation of juvenile traction osteochondritis? *J Bone Joint Surg Br* 1985;67:249-251.
9. Adachi N, Ochi M, Yamaguchi H, Uchio Y, Kuriwaka M. Vastus lateralis release for painful bipartite patella. *Arthroscopy* 2002;18:404-411.
10. Canizares GH, Selesnick FH. Bipartite patella fracture. *Arthroscopy* 2003;19:215-217.

11. Iossifidis A, Brueton RN. Painful bipartite patella following injury. *Injury* 1995;26:175-176.
12. Collings CL. Scintigraphic findings on examination of the multipartite patella. *Clin Nucl Med* 1994;19:865-866.
13. Kavanagh EC, Zoga A, Omar I, Ford S, Schweitzer M, Eustace S. MRI findings in bipartite patella. *Skeletal Radiol* 2007;36:209-214.
14. Marya KM, Yadav V, Devagan A, Kundu ZS. Painful bilateral bipartite patella: Case report. *Indian J Med Sci* 2003;57:66-67.
15. Okuno H, Sugita T, Kawamata T, Ohnuma M, Yamada N, Yoshizumi Y. Traumatic separation of a type I bipartite patella: A report of four knees. *Clin Orthop Relat Res* 2004;420:257-260.
16. Weaver JK. Bipartite patellae as a cause of disability in the athlete. *Am J Sports Med* 1977;5:137-143.
17. Bourne MH, Bianco AJ Jr. Bipartite patella in the adolescent: Result of surgical excision. *J Pediatr Orthop*. 1990;10:69-73.
18. Iossifidis A, Brueton RN. Painful bipartite patella following injury. *Injury* 1995;26(3):175-176.
19. Green WT Jr. Painful bipartite patellae. A report of three cases. *Clin Orthop* 197-12000;1:975
20. Ogden JA, McCarthy SM, Jokl P. The painful bipartite patella. *J Pediatr Orthop* 1982;263-:269,
21. Tietjens BR, Aitken GK, Walsh SJ. Symptomatic bipartite patella. *J Bone Joint Surg* 1992;74B(Suppl)III:267,
22. Weaver JK. Bipartite patellae as a cause of disability in the athlete. *Am J Sports Med* 1977;5:137-143.
23. Mori Y, Okumo H, Iketani H, Kuroki Y. Efficacy of lateral retinacular release for painful bipartite patella. *Am J Sports Med* 1995;23:13-18.
24. Kujala UM, Jaakkola LH. Nelimarkka Scoring of patellofemoral disorders. *Arthroscopy* 1993;9(2):159-63.