



# International Journal of Orthopaedics Sciences

E-ISSN: 2395-1958  
P-ISSN: 2706-6630  
IJOS 2021; 7(3): 794-798  
© 2021 IJOS  
[www.orthopaper.com](http://www.orthopaper.com)  
Received: 01-05-2021  
Accepted: 03-06-2021

**Dr. G Anvesh**  
Associate Professor,  
Department of Orthopaedics,  
Narayana Medical College and  
Hospital Chinthareddypalem,  
Nellore, Andhra Pradesh, India

**Dr. K Lahari**  
Postgraduate, Department of  
Orthopaedics Narayana medical  
College and Hospital  
Chinthareddypalem, Nellore,  
Andhra Pradesh, India

## A comparative analytical study of efficacy of platelet rich plasma and corticosteroid injections in the management of partial supraspinatus tear

**Dr. G Anvesh and Dr. K Lahari**

**DOI:** <https://doi.org/10.22271/ortho.2021.v7.i3l.2833>

### Abstract

**Background:** Partial supraspinatus tendon tears have frequently been treated using a subacromial corticosteroid injection or surgery. The clinical use of a platelet-rich plasma (PRP) injection is an alternative treatment method for the condition, despite the paucity of evidence of its efficacy.

**Aim:** To compare pain relief, functional improvement, and complications after an intratendinous PRP injection versus a subacromial corticosteroid injection for partial supraspinatus tears.

**Study Design:** Prospective comparative study

**Materials and Methods:** A total of 36 patients with partial supraspinatus tears were selected to receive a leukocyte-poor PRP (LPPRP) injection or a corticosteroid injection, taking 18 patients in the PRP group and 18 patients in the corticosteroid group. The ultrasound-guided procedures were performed by a single experienced pain physician. Pain relief and functional improvement were evaluated using the Visual analog scale (VAS) and the Oxford Shoulder Score (OSS), respectively. Treatment efficacy and complications were documented, and the 2 groups were compared at 1-and 6-month follow-up.

**Results:** There were no differences in VAS and OSS scores between the PRP and corticosteroid groups at 1-month follow-up. However, the PRP group had better scores than the corticosteroid group had on both the VAS and OSS at 6-month follow-up (VAS:  $14.5 \pm 15.4$  vs  $37.5 \pm 24.9$ , respectively; OSS:  $16.2 \pm 3.9$  vs  $25.0 \pm 10.2$ , respectively;  $P < .01$  for both). Both groups showed significant improvement in VAS and OSS scores from before treatment to 1-month follow-up (mean difference, 35.67 and 11.47 points, respectively, for the PRP group; mean difference, 29.69 and 11.13 points, respectively, for the corticosteroid group;  $P < .01$  for all). The VAS and OSS scores did not change significantly at 6-month follow-up in the corticosteroid group; however, the PRP group showed continued improvement in both VAS and OSS scores between 1-and 6-month follow-up (mean difference, 15.87 and 7.40 points, respectively;  $P < .01$  for both). There were no complications in either group.

**Conclusion:** An injection using either a corticosteroid or LP-PRP resulted in a similar reduction in pain and improvement in function at 1 month in patients with a partial supraspinatus tear. However, PRP showed superior benefits over the corticosteroid at 6-month follow-up.

**Keywords:** platelet rich plasma and corticosteroid injections, partial supraspinatus tear

### Introduction

With its wide range of motion, the shoulder is one of the most complex joints in the body, and pain from trauma or degeneration is common. Rotator cuff tendinopathy is a frequent cause of shoulder pain, and the progression to a partial-or full-thickness supraspinatus tendon tear can occur. Because of poor vascularization, the tendons have a limited ability to regenerate. This failure to heal is considered a principal cause of chronic shoulder pain and hinders successful outcomes from both nonoperative and surgical treatment. A subacromial corticosteroid injection is an option used widely for patients with inadequate responses to nonoperative procedures, although clinical evidence of its efficacy is conflicting. Most studies have shown pain relief and functional improvement from a corticosteroid injection in the short term but no clear benefit in the long term. Recently, the use of orthobiologics, such as platelet-rich plasma (PRP), has been proposed to promote regeneration of the tendon. PRP is an autologous concentration of human platelets in a small volume of plasma produced by centrifuging a patient's own blood. Platelets contain a milieu of growth factors and mediators in their alpha granules, including transforming growth factor-beta1, platelet derived growth factor, basic

**Corresponding Author:**  
**Dr. G Anvesh**  
Associate Professor,  
Department of Orthopaedics,  
Narayana Medical College and  
Hospital Chinthareddypalem,  
Nellore, Andhra Pradesh, India

fibroblast growth factor, vascular endothelial growth factor, epidermal growth factor, and insulin-like growth factor-1,6,19 which are concentrated using the centrifugation process and can then be delivered to an injured site to augment the body's natural healing process. In contrast to leukocyte-rich PRP, leukocyte-poor PRP (LP-PRP) eliminates some problems caused by leukocytes such as oxygen free radical release during inflammation, which causes endothelial and subendothelial damage and leads to fibrosis that will disrupt the expected healing process while providing a sustained release of growth factors from endogenously activated platelets. There is convincing evidence of the efficacy of PRP in the treatment of lateral epicondylitis, patellar tendinopathy, and knee osteoarthritis. However, there is little evidence, mostly in the form of small clinical trials, that shows the efficacy of PRP for rotator cuff injuries. The purpose of this study was to compare pain relief, functional improvement, and complications after an intratendinous PRP injection versus a subacromial corticosteroid injection for partial supraspinatus tears.

### Materials and Methods

This is a prospective comparative study done in Narayana medical college and hospital Chinthareddypalem, Nellore from August 2019 and September 2020. Before enrollment, all patients provided written informed consent. Patients with shoulder pain who visited the outpatient orthopaedic clinic were examined to ascertain their eligibility after clinical and radiological assessments

### Inclusion Criteria

1. Age between 18 and 80 years and no serious systemic diseases such as uncontrolled diabetes, hyperthyroidism, or end-stage renal failure.
2. Partial supraspinatus tendon tears confirmed using magnetic resonance imaging (MRI).
3. Natural history of tears from repetitive trauma or overuse only.
4. Failed non-operative treatment, including physical therapy and oral medication, for at least 3 months.
5. Ability to participate for a minimum follow-up period of 6 months.

### Exclusion Criteria

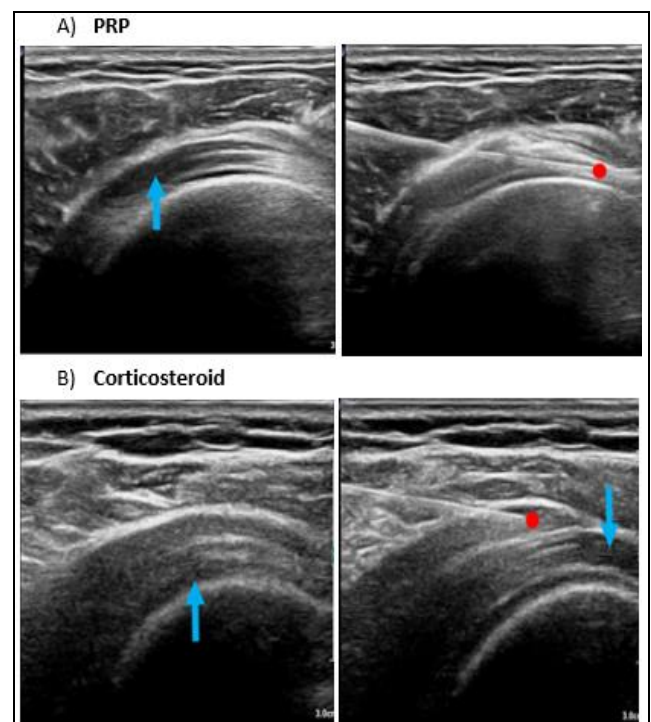
1. Severe arthritis or other complications related to supraspinatus tears, such as generalized inflammatory arthritis and infections.
2. History of previous shoulder surgery.
3. Other concurrent shoulder conditions such as impingement from an MRI diagnosis.
4. Malignancy.
5. Current treatment using anticoagulant or antiplatelet medication.
6. Immunocompromised status.

A total of 36 patients were included in the study with 18 patients in the PRP group and 18 patients in the corticosteroid group. Characteristic information including underlying diseases was recorded. No patients were lost to follow-up in both groups. All procedures were performed in the operating theater. All injections were administered by a single experienced physician. Patients sat in the modified Crass position, and the area to be injected was disinfected using strict aseptic precautions. The posterolateral approach was used for all the patients in both groups. Real-time ultrasound

guidance was provided during the injections under sterile conditions. The ultrasound probe was placed on the affected shoulder. The supraspinatus tendon and the subacromial-subdeltoid bursa were identified

In the PRP group, PRP was prepared using 15 mL of blood aspirated in the double syringe and centrifuged at 1500 rpm for 5 minutes. This yielded around 5 mL of LP-PRP ready for an injection. Using a 25-gauge needle, 5 mL of PRP was infiltrated into the supraspinatus tendon tear site 5 seconds after being centrifuged (Figure 2A).

In the corticosteroid group, 1 mL of triamcinolone acetonide (40 mg/mL), together with 4ml of 1% lidocaine, was prepared using a 5-mL syringe with a 25-gauge needle. The mixture was injected into the subacromial bursa (Figure 2B). After the injection, the patients rested without moving the shoulder for 30 minutes in the recovery room. Arm slings were used to immobilize the injected shoulders of all patients for 3 days. After that, the patients were allowed to move their shoulders and instructed to follow a light exercise program at home as advised. Exercise included passive range of motion, such as wall climbing in the scapular plane, abduction, and forward flexion and towel suspension in internal rotation and adduction, as well as active range of motion, such as forward flexion, scapular-plane abduction, and external rotation. Additionally, exercise included periscapular strengthening, scapular retraction, and wall planking with scapular protraction and shoulder depression. Physical therapy was not prescribed. Patients were advised to avoid sports activities for 6 weeks. Use of nonsteroidal anti-inflammatory drugs was not allowed for 6 months, and patients were prescribed acetaminophen or acetaminophen/tramadol (325/37.5 mg) for pain control. Visual analog scale (VAS) for pain scores, Oxford Shoulder Score (OSS) results, and complications were assessed before the injection and at 1 and 6 months after the injection in the outpatient clinic



**Fig 1:** (A) Platelet-rich plasma (PRP) was injected into the supraspinatus tendon tear site. The blue arrow indicates a partial tear of the supraspinatus tendon; the red dot indicates the needle tip. (B) A corticosteroid was injected into the subacromial bursa. The blue arrows indicate partial tears of the supraspinatus tendon; the red dot indicates the needle tip.

## Outcome Measures

The primary outcome measure was the 100-mm VAS, which is the most common tool for validating pain, including shoulder pain. The participants were told to choose a number between 0 and 10 marked on a 100-mm line, with 0 indicating no pain and 10 indicating the worst pain possible. Secondary outcome measure was the OSS to assess function, with 12 indicating good function and 60 indicating the worst function. Baseline characteristics were also collected from all participants. Outcome scores were obtained at baseline and at 1 and 6 months after the injection. Patients were requested to report any adverse effects at each visit.

## Results

Table 1 shows the characteristics of the study groups. The PRP group was significantly younger than was the corticosteroid group ( $P = .006$ ), but the other characteristics

were similar between the groups. A comparison of outcome scores between the PRP and corticosteroid groups showed that there were no statistically significant differences in the VAS and OSS scores at baseline or at 1-month follow-up (Tables 2 and 3). At 6-month follow-up, both the VAS and OSS scores were significantly different: the PRP group had a VAS score of 14.5 compared to a VAS score of 37.5 in the corticosteroid group ( $P < .01$ ) and an OSS score of 16.2 versus 25.0, respectively ( $P < .01$ ) (Tables 2 and 3). Both groups showed significant improvements in the VAS and OSS scores at all-time points compared to baseline (before treatment), with a large mean reduction or mean difference ( $P < .01$ ). The corticosteroid group had no significant change in VAS or OSS scores between the 1-and 6-month time points; however, the PRP group showed continued improvement in both VAS and OSS scores at the 6-month time point (Tables 4 and 5). There were no complications in either group.

**Table 1:** Descriptive Data

	PRP Group (n=18)	Corticosteroid Group (n=18)	p
Age, y	51.3 ± 10.3	62.4 ± 10.5	0.006
Male sex, n (%)	3 (20.0)	3 (18.8)	>.999
Body mass index	25.1 ± 4.1	24.6 ± 3.6	0.719
Pain duration	8.3 ± 11.6	13.5 ± 12.5	0.901
Some Strenuous work (lifting in daily routine), n (%)	9 (60.0)	10 (62.5)	0.88
Underlying diseases, n (%)	4 (26.7)	3 (18.8)	0.613
Hypertension	3 (20.0)	3 (18.8)	0.933
Dyslipidemia	1 (6.7)	2 (12.5)	0.598
Migraine	1 (6.7)	0 (0.0)	0.31
Benign prostate hyperplasia	1 (6.7)	0 (0.0)	0.31
Nondominant arm, n (%)	3 (20.0)	2 (12.5)	0.585

**Table 2:** (Between-Group Comparison of VAS Scores)

	PRP Group	Corticosteroid Group	Mean Difference (95% CI)	P
Before Treatment	66.0±14.6	64.1±21.1	1.94(-11.45to15.32)	0.76
1-mo follow-up	30.3±20.6	34.4±27.6	-4.04(-22.00to13.92)	.64
6-mo follow-up	14.5±15.4	37.5±24.9	-23.03(-38.37to-7.69)	<.01

**Table 3:** (Between-Group Comparison of OSS Scores)

	PRP Group	Corticosteroid Group	Mean Difference (95% CI)	P
Before Treatment	35.1±7.6	36.6±7.2	-1.50(-6.94to3.95)	.58
1-mo follow-up	23.6±6.5	25.4±10.5	-1.84(-8.31to4.63)	.57
6-mo follow-up	16.2±3.9	25.0±10.2	-8.84(-14.57to-3.03)	<.01

**Table 4:** (Within-Group Comparison of VAS Scores)

	Mean Difference (95% CI)	P
<b>PRP group</b>		
Before treatment vs 1-mo follow-up	35.67 (25.69 to 45.64)	<.01
Before treatment vs 6-mo follow-up	51.53 (39.56 to 63.51)	<.01
1- vs 6-mo follow-up	15.87 (4.31 to 27.42)	<.01
<b>Corticosteroid group</b>		
Before treatment vs 1-mo follow-up	29.69 (12.22 to 47.16)	<.01
Before treatment vs 6-mo follow-up	26.56 (12.64 to 40.48)	<.01
1- vs 6-mo follow-up	-3.13 (-20.28 to 14.03)	0.7

**Table 5:** (Within-Group Comparison of OSS Scores)

	Mean Difference(95% CI)	P
<b>PRP group</b>		
Before treatment vs 1-mo follow-up	11.47 (6.65 to 16.28)	<.01
Before treatment vs 6-mo follow-up	18.86 (14.51 to 23.22)	<.01
1- vs 6-mo follow-up	7.40 (4.00 to 10.80)	<.01
<b>Corticosteroid group</b>		
Before treatment vs 1-mo follow-up	11.13 (6.40 to 15.85)	<.01
Before treatment vs 6-mo follow-up	11.56(6.63 to 16.49)	<.01
1- vs 6-mo follow-up	0.44 (-5.13 to 6.00)	0.87

## Discussion

The results from the current study showed that both PRP and a corticosteroid had beneficial effects for the treatment of partial supraspinatus tears. However, the corticosteroid effects plateaued after 1 month, with no significant change between the 1- and 6-month assessments in this group. A comparison of the 2 groups at the 1-month time point indicated that there was no significant difference between them in terms of pain and function. However, at the 6-month time point, the differences were statistically significant, reflecting the extended effects of PRP compared to the corticosteroid. Many studies have shown similar results on the relative efficacy of PRP, but others have found no overall significant effects of PRP on functional outcomes and repair integrity. A review by Chen et al reported that LP-PRP appeared to significantly reduce the retear rate compared with the control and may improve tendon-to-bone healing based on significant differences in the failure-to-heal rate along with improving patient pain scores. It has been hypothesized that the primary cause of chronic tendinopathy is not related to the inflammatory process but to an insufficient body healing process. From these concepts, PRP as a regenerative substance has its role in promoting tissue healing because platelets are known to release growth factors, cytokines, and chemokines to modulate inflammation and tissue regeneration. In our study, as we used pain as a primary outcome, our evidence on PRP injections supports a beneficial effect on long pain reduction for rotator cuff injuries.

In contrast to other studies, which have suggested a return to baseline over time using corticosteroid injections, our results showed a sustained improvement in pain and OSS scores in the corticosteroid group. Partial supraspinatus tears are considered a chronic overuse disease in which inflammation is not characterized pathologically; hence, a corticosteroid as an anti-inflammatory drug might not be able to exhibit long-term effects. Previous studies reported a significantly better functional outcome, sustained for 6 months, with exercise therapy compared with placebo in rotator cuff diseases. Part of the prolonged pain control without returning to baseline for both groups in our study might be a consequence of patients following an early, long-term light shoulder exercise program at home. The pathogenetic mechanisms of partial rotator cuff tears should be considered, although these are not fully understood. In the initial phase, inflammation is prevalent, whereas in the later phase, degeneration varying according to the intensity and duration of overuse and individual predisposing factors is commonly seen. During relapses, inflammation is frequently superimposed over degeneration. Because there are several aspects in the pathogenesis of tears, we selectively included patients with a natural history of tears from repetitive trauma due to daily work/activities, excluding sports injuries and accidents. All participants had unsuccessful non-operative treatment for at least 3 months, so improvement should be from the effects of PRP or the corticosteroid. The non-operative management of partial rotator cuff tears for at least 6 weeks to 3 months is recommended; prolonged non-operative management in symptomatic patients can have negative consequences. These include an increase in tear size, tear retraction, difficulty in repair, and muscle atrophy with fatty infiltration, all of which can result in a diminished outcome. A Local corticosteroid injection counteracts the inflammatory and immune cascades, so it is beneficial in the early phase of the disease, corresponding to our current results. However, its efficacy is

limited or absent in the late phase when degeneration is prevalent, which corresponded to our results. In the corticosteroid group, results showed significant improvement from baseline at 1 and 6 months but no improvement from 1 to 6 months (Tables 4 and 5). The rationale for sustained improvement at 6 months from baseline might be the anti-inflammatory effects of the corticosteroid at the first time of treatment. However, definite verification should be performed in a future study. Platelets are known for their importance in clotting. Furthermore, platelet products represent an enriched autologous source of platelets containing growth factors at higher concentrations than normal physiological levels. These factors augment revascularization of the injury areas and promote tendon healing, resulting in the improvement of pain and function. Many animal models have proven the beneficial effects of growth factors in PRP on tendon healing. Clinical reports have been inconclusive on the details of different PRP formulations, injection techniques, and tear sizes, and many have uncontrolled biases. The concentrations and activities of the platelet components may vary according to the volume and timing of application. Both LP-PRP and leukocyte-rich PRP promote the regeneration of many kinds of injured tissue, including tendons. Owing to these regenerative benefits of PRP and the detrimental effects of repetitive steroid injections to tendons, PRP seemed to be an interesting option for injured tendons. According to the basic biological knowledge of PRP and corticosteroids, injection techniques had to be performed differently. Treatment modalities and injection sites may have influenced the response outcomes. Corticosteroids may have detrimental effects on tendons, including an impairment of fibroblast viability, arrest of cell proliferation, and depletion of the tenocyte stem cell pool, leading to decreased collagen synthesis. The release of metalloproteinase after a corticosteroid injection has been associated with tendon degeneration and ruptures. Therefore, it is preferable to perform a peritendinous corticosteroid injection into the subacromial bursa rather than directly into the supraspinatus tendon. On the other hand, PRP should be injected directly into the injured tendon, where released growth factors can promote the healing process. PRP injections are generally safe and cost effective. The platelets are harvested from the patient's own blood; thus, the risk of any incompatible blood reactions or disease transmission is extremely low. Reactions from additives are also rarely reported. PRP therapy is quick with no downtime from daily activities.

## Conclusion

An injection of either a corticosteroid or LP-PRP resulted in a similar reduction of pain and improvement of function at 1 month in patients with partial supraspinatus tears. At 6 months after the injection, continued improvement was seen in the PRP group, whereas no further improvement was seen in the corticosteroid group. A PRP injection showed superior benefits over a corticosteroid injection for partial supraspinatus tears at 6-month follow-up.

## References

1. Abate M, Salini V, Schiavone C, Andia I. Clinical benefits and drawbacks of local corticosteroids injections in tendinopathies. *Expert Opin Drug Saf* 2017;16(3):341-349.
2. Akan O, Mete B, Koc, yig̃it H, Bayram KB, Yilmaz HE, Tosun A. Efficacy of ultrasound guided platelet-rich plasma in the repair of partial and full-thickness supraspinatus tears. *Int J Clin Exp Med* 2019;12(9):11.

3. Alfredson H. Chronic midportion Achilles tendinopathy: an update on research and treatment. *Clin Sports Med* 2003;22(4):727-741.
4. Andia I, Latorre PM, Gomez MC, Burgos-Alonso N, Abate M, Maffulli N. Platelet-rich plasma in the conservative treatment of painful tendinopathy: a systematic review and meta-analysis of controlled studies. *Br Med Bull* 2014;110(1):99-115.
5. Balasubramaniam U, Dissanayake R, Annabell L. Efficacy of platelet rich plasma injections in pain associated with chronic tendinopathy: a systematic review. *Phys Sportsmed* 2015;43(3):253-261.
6. Boswell SG, Cole BJ, Sundman EA, Karas V, Fortier LA. Platelet-rich plasma: a milieu of bioactive factors. *Arthroscopy* 2012;28(3):429-439.
7. Chen X, Jones IA, Togashi R, Park C, Vangsness CT. Use of platelet-rich plasma for the improvement of pain and function in rotator cuff tears: a systematic review and meta-analysis with bias assessment. *Am J Sports Med*. 2020;48(8):2028-2041.
8. Clement ND, Nie YX, McBirnie JM. Management of degenerative rotator cuff tears: a review and treatment strategy. *Sports Med Arthrosc Rehabil Ther Technol* 2012;4(1):48.
9. Coombes BK, Bisset L, Vicenzino B. Efficacy and safety of corticosteroid injections and other injections for management of tendinopathy: a systematic review of randomised controlled trials. *Lancet* 2010;376(9754):1751-1767.
10. Dawson J, Fitzpatrick R, Carr A. Questionnaire on the perceptions of patients about shoulder surgery. *J Bone Joint Surg Br* 1996;78(4):593-600.
11. Gialanella B, Prometti P. Effects of corticosteroids injection in rotator cuff tears. *Pain Med* 2011;12(10):1559-1565.
12. Gutierrez-Espinoza H, Araya-Quintanilla F, Pinto-Concha S, *et al.* Effectiveness of supervised early exercise program in patients with arthroscopic rotator cuff repair: study protocol clinical trial. *Medicine (Baltimore)* 2020;99(4):e18846.
13. Hart L. Corticosteroid and other injections in the management of tendinopathies: a review. *Clin J Sport Med* 2011;21(6):540-541.
14. Ho LK, Baltzer WI, Nemanic S, Stieger-Vanegas SM. Single ultrasound-guided platelet-rich plasma injection for treatment of supraspinatus tendinopathy in dogs. *Can Vet J* 2015;56(8):845-849.
15. Hutton B, Salanti G, Caldwell DM, *et al.* The PRISMA extension statement for reporting of systematic reviews incorporating network meta-analyses of health care interventions: checklist and explanations. *Ann Intern Med* 2015;162(11):777-784.
16. Jinming W, Caiyue L, Baojin W, *et al.* Effects of platelet-rich plasma on tissue expansion in rabbits. *Aesthetic Plast Surg* 2017;41(2):454-460.
17. Kesikburun S, Tan AK, Yilmaz B, Yasar E, Yazicioglu K. Platelet-rich plasma injections in the treatment of chronic rotator cuff tendinopathy: a randomized controlled trial with 1-year follow-up. *Am J Sports Med* 2013;41(11):2609-2616.
18. Lange S. Are Platelet-Rich Plasma Injections a Better Choice Compared to Glucocorticoid Injections for the Treatment of Rotator Cuff Tendinopathy in Adult Patients? Thesis. Augsburg University; 2018. Accessed August 24 2021.
19. Le ADK, Enweze L, DeBaun MR, Dragoo JL. Platelet-rich plasma. *Clin Sports Med* 2019;38(1):17-44.
20. Lewis J. Rotator cuff related shoulder pain: assessment, management and uncertainties. *Man Ther* 2016;23:57-68.
21. Lin MT, Chiang CF, Wu CH, Huang YT, Tu YK, Wang TG. Comparative effectiveness of injection therapies in rotator cuff tendinopathy: a systematic review, pairwise and network meta-analysis of randomized controlled trials. *Arch Phys Med Rehabil* 2019;100(2):336-349.e15.
22. Littlewood C, Ashton J, Chance-Larsen K, May S, Sturrock B. Exercise for rotator cuff tendinopathy: a systematic review. *Physiotherapy* 2012;98(2):101-109.
23. Mautner K, Colberg RE, Malanga G, *et al.* Outcomes after ultrasound-guided platelet-rich plasma injections for chronic tendinopathy: a multicenter, retrospective review. *PM R* 2013;5(3):169-175.
24. Mei-Dan O, Carmont MR. The role of platelet-rich plasma in rotator cuff repair. *Sports Med Arthrosc Rev* 2011;19(3):244-250.
25. Mohamadi A, Chan JJ, Claessen FM, Ring D, Chen NC. Corticosteroid injections give small and transient pain relief in rotator cuff tendinosis: A meta-analysis. *Clin Orthop Relat Res* 2017;475(1):232-243.
26. Rha DW, Park GY, Kim YK, Kim MT, Lee SC. Comparison of the therapeutic effects of ultrasound-guided platelet-rich plasma injection and dry needling in rotator cuff disease: a randomized controlled trial. *Clin Rehabil* 2013;27(2):113-122.
27. Schwitzgebel AJ, Kolo FC, Tirefort J, *et al.* Efficacy of platelet-rich plasma for the treatment of interstitial supraspinatus tears: a double-blinded, randomized controlled trial. *Am J Sports Med* 2019;47(8):1885-1892.
28. Shams A, El-Sayed M, Gamal O, Ewes W. Subacromial injection of autologous platelet-rich plasma versus corticosteroid for the treatment of symptomatic partial rotator cuff tears. *Eur J Orthop Surg Traumatol* 2016;26(8):837-842.
29. Tantisiriwat N, Wongmatikul V, Jaroenarpornwatana A, Janchai S. Validation and reliability of the Thai version of the Oxford Shoulder Score. *J Med Assoc Thai* 2018;101(4):7.
30. Unlu MC, Kivrak A, Kayaalp ME, Birsal O, Akgun I. Peritendinous injection of platelet-rich plasma to treat tendinopathy: a retrospective review. *Acta Orthop Traumatol Turc* 2017;51(6):482-487.
31. Von Wehren L, Blanke F, Todorov A, Heisterbach P, Sailer J, Majewski M. The effect of subacromial injections of autologous conditioned plasma versus cortisone for the treatment of symptomatic partial rotator cuff tears. *Knee Surg Sports Traumatol Arthrosc* 2016;24(12):3787-3792.
32. Waldman S. Ultrasound-guided injection techniques for supraspinatus. In: *Comprehensive Atlas of Ultrasound-Guided Pain Management Injection Techniques*. 1st ed. Saunders Elsevier 2014;234-240.