



E-ISSN: 2395-1958  
P-ISSN: 2706-6630  
IJOS 2021; 7(3): 679-688  
© 2021 IJOS  
[www.orthopaper.com](http://www.orthopaper.com)  
Received: 22-05-2021  
Accepted: 24-06-2021

**Dr. V Chaya Phani Nandini**  
Resident Doctor, Department of  
Orthopaedic Surgery, District  
Government Hospital, Eluru,  
West Godavari, Andhra Pradesh,  
India

**Dr. AVR Mohan**  
(M.S Ortho), Head of  
Department, Department of  
Orthopaedic Surgery, District  
Government Hospital, Eluru,  
West Godavari, Andhra Pradesh,  
India

**Corresponding Author:**  
**Dr. V Chaya Phani Nandini**  
Resident Doctor, Department of  
Orthopaedic Surgery, District  
Government Hospital, Eluru,  
West Godavari, Andhra Pradesh,  
India

# International Journal of Orthopaedics Sciences

## Functional outcome of clavicular fractures managed surgically in adults: A clinical study

**Dr. V Chaya Phani Nandini and Dr. AVR Mohan**

DOI: <https://doi.org/10.22271/ortho.2021.v7.i3j.2820>

### Abstract

The purpose of this study is to assess the functional outcome of displaced clavicular fractures which were managed surgically. The results show that the functional outcome assessment according to Constant-Murley score showed excellent functional outcome in 16 patients (80%) and good functional outcome in 3 patients (15%) and 1 fair functional outcome in 1 patient (5%).

**Keywords:** clavicle, fractures, locking compression plate, reconstruction plate, screws

### Introduction

The Clavicle is one of the most frequently fractured bones in the body, comprising 2.6% to 4% of all adult fractures and accounting for 35% of shoulder girdle injuries [1]. The clavicle is an S-shaped bone and is the only osseous link between the upper extremity and the trunk. It also has a suspensory function to the shoulder girdle. Incidence in males is usually highest and more common with road traffic accidents. Nowak *et al.* ascertained the incidence of clavicle fractures to be 70% for 1, 00,000 in males and 30% for 1, 00,000 in females [3]. The peak incidence occurs in the third decade of life [4].

Allman, classified clavicle fractures into three groups based on their location along the bone into medial third, middle third, lateral third. Further, Robinson modified Allman classification based on the degree of displacement and comminution. Robinson *et al.* reported that middle third clavicle fractures comprise for 69%- 82%, lateral fractures account for 21%-28% and medial fractures are relatively rare, account for 2%-3% [6]. Historically, non operative methods were used to treat clavicular fractures, as they were seen to have low rates of non-union [7, 8, 9]. However, some studies have shown unsatisfactory results with such treatments, including pain, cosmetic complaints, and brachial plexus irritation [10, 11]. Recent studies have suggested that surgery shows certain benefits, such as a quicker return of function, increased patient satisfaction, fewer complications [12, 13, 14]. The prevalence of non-union or mal-union in dislocated midshaft clavicular fractures after conservative treatment is also higher than previously presumed and fixation methods have evolved. Persistent wide separation of fragments with interposition of soft tissue may lead to failure of closed reduction and all fractures with initial shortening of more than 2cm resulted in non-union. Several studies have examined the safety and efficacy of primary open reduction and internal fixation for completely displaced midshaft clavicular fractures and have noted high union rate with a low complication rate [15]. In a large number of complex clavicle fractures a satisfactory outcome is possible with a low complication rate using a locked compression plate [16]. Primary internal fixation of displaced comminuted mid-shaft clavicular fractures leads to predictable and early return to function.

The present consensus that great majority of clavicular fractures heal with non-operative treatment is no longer valid. There are various surgical methods for treating clavicle midshaft fractures, such as intramedullary fixation using K-wires, Knowles pin, Rockwood pin and Titanium elastic nails and plate fixation. In particular, plate fixation can help obtain firm anatomical reduction in severe displaced and comminuted fracture. There are various plates including Sherman Plates, Dynamic Compression Plates and semi-tubular Plates. Among them, A Reconstruction Plate which can be bent to the S-shaped curvature of the clavicle and

pre-contoured Locking Compression Plate (LCP), are the most preferred. We have taken up this study to understand and interpret the results and problems associated and to evaluate the functional outcome after fixation of displaced clavicular fractures by surgical management.

### Methods and Methodology

The present study was carried out from July 2019 to June 2020 in Orthopaedics Department at DISTRICT GOVERNMENT HOSPITAL, ELURU. During this period 20 patients of clavicular fractures were treated surgically. In our hospital we have done open reduction internal fixation by plating in all 20 cases of which pre-contoured locking compression plates are used in 14 cases and reconstruction plates in 6 cases.

### Inclusion criteria

Adult male and female patients above 18 years who require surgical intervention for displaced and comminuted clavicular fractures were included for this study after taking written consent from them.

### Exclusion criteria

1. Age < 18 years
2. Open fractures
3. Pathological fractures
4. Undisplaced fractures
5. Associated head injury
6. Associated with neuro vascular injury
7. Established non-union from previous fracture
8. Associated acromio clavicular joint dislocation. Any medical contraindication to surgery or general anaesthesia (heart diseases, renal failure or active chemotherapy)
9. Unable to provide consent

Demographic information such as name, age, sex, occupation and address were noted. Then a detailed clinical history such as mode of injury like fall on the shoulder, Road traffic accident, direct injury to shoulder and fall on outstretched hand was noted. Enquiry was made to note site of pain and swelling over the affected clavicle. Past medical illness and family history were also recorded.

General condition of the patients was examined.

### Aims and Objectives

1. To study the functional outcome of displaced clavicular fractures managed surgically in terms of duration of union both clinically and radiologically.
2. To study the merits and demerits encountered in the surgical management of clavicle fractures and to interpret conclusions out of overall study.

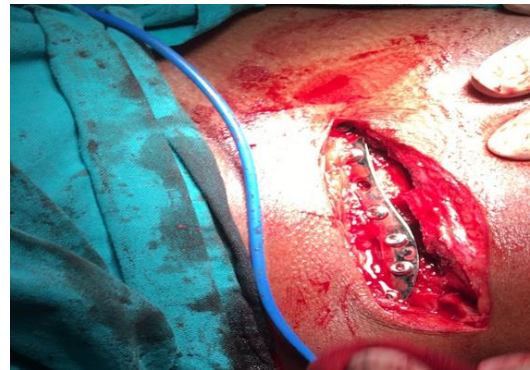### Surgical Technique

1. Patient in supine position with one towel in between the scapula. Entire upper limb was prepared and draped.
2. About 7-9cms, incision was made in the anterior aspect of clavicle over the fracture site.
3. The skin, subcutaneous tissue and platysma were divided without undermining the edges.
4. The overlying fascia and periosteum were next divided. The osseous ends were freed from surrounding tissue.
5. Minimal soft tissue and periosteum dissection was done.
6. Fracture fragments were reduced and plate was applied

over the superior aspect of the clavicle.

7. At the junction of the medial and middle third of the clavicle, the inferior surface is exposed so that a protective instrument can be inserted during drilling to prevent injury to neurovascular structure underneath it.
8. The locking compression plate was fixed to the medial and lateral fragment with locking screws/ cortical screws and at least three screws on both fragment were applied.
9. Wound was closed in layers after ensuring meticulous hemostasis and sterile dressing was applied.

### Operative Photograph



**Fig 1:** Final view after fixation with three screws medially and laterally.

### Follow up

Regular follow up for every 4 weeks up to 3 months was done. Local examination of the affected clavicle for tenderness, instability, deformity and shoulder movements were assessed. X-rays were taken at each follow up visits to know about progressive fracture union and implant position. Rehabilitation of the affected extremity were done according to the stage of fracture union and time duration from day of surgery.

Patients were followed up till radiological union. The functional outcome was assessed by Constant - Murley Score [19, 20].

### Constant- Murley Scoring

It is a 100 points scale composed of a number of individual parameters. The Constant-Murley score was introduced to determine the functionality after the treatment of a shoulder injury. The higher the score, the higher the quality of the function. The test is divided into 4 subscales: Pain (15 points), Activities of daily living (20 points), Strength (25 points), Range of motion (40 points).

### Results and Observations

The present study consists of 20 patients of fresh clavicle fractures which were treated surgically with open reduction internal fixation with plate & screws, between July 2019 to June 2020. All the patients were treated at DISTRICT GOVERNMENT HOSPITAL, ELURU. All the patients were available for follow-up and they were followed every 4 weeks. Results were analyzed both clinically and radiologically.

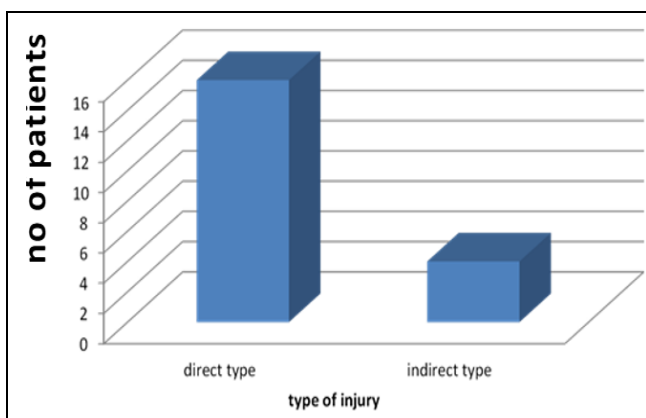
Direct injury occurred in 16 patients (80%) among them 7 patients (35%) were due to fall on shoulder from two-wheeler, 6 patients (30%) were due to road traffic accident, 3 patients (15%) were due to fall on the shoulder after slipping. Indirect injury occurred in 4 patients (20%).

**Mode of Injury**

**Table 1:** Mode of Injury

Mode of Injury	No.of clavicle fractures	%
Fall on shoulder from two- wheeler	7	35
Road traffic accident	6	30
Simple fall on shoulder	3	15
Fall on out stretched hand	4	20
Total	20	100

Direct injury occurred in 16 patients (80%) among them 7 patients (35%) were due to fall on shoulder from two-wheeler, 6 patients (30%) were due to road traffic accident, 3 patients (15%) were due to fall on the shoulder after slipping. Indirect injury occurred in 4 patients (20%) due to fall on outstretched hand.



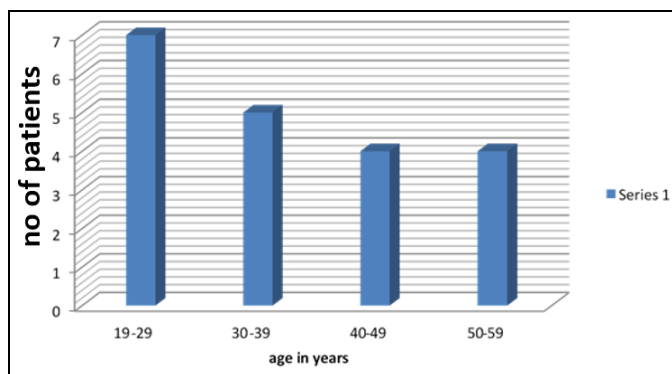
**Graph 1:** Mode of Injury

**Age Incidence**

**Table 2:** Age incidence

Age in	No. of clavicle fractures	Percentage
19-29	7	35
30-39	5	25
40-49	4	20
50-59	4	20
Total	20	100

Majority of the patient with clavicle fracture i.e. 7 patients (35%) were in the age group of 19-29 years. The youngest patient was 20 years and oldest patient was 56 years. The average patient age was 33 years.



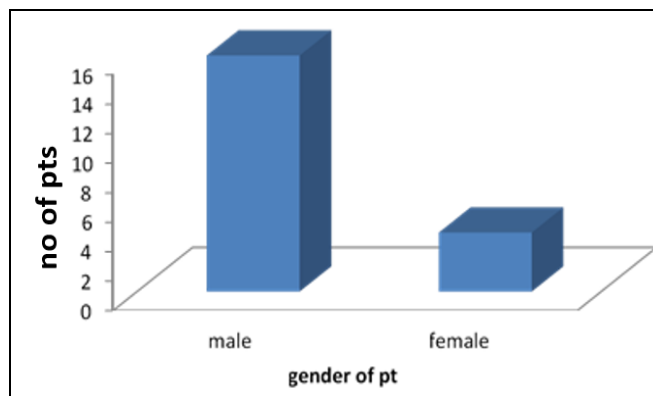
**Graph 2:** Age Incidence

**Gender Incidence**

**Table 3:** Gender incidence

Sex	No. of clavicle #	%
Male	16	80
Female	4	20
Total	20	100

In our study out of 20 patients 16 were male and 4 were female patients.



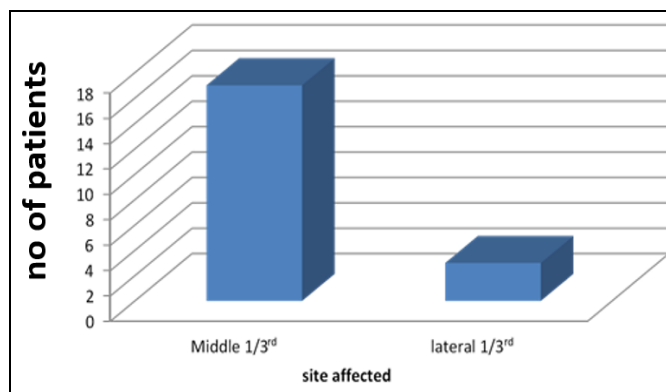
**Graph 3:** Gender incidence

**Site Affected**

**Table 4:** Site Affected

Site of fracture of clavicle	Number	Percentage (%)
middle third fractures	17	85
Lateral third fractures	3	15

In our study out of 20 patients with clavicle fractures 17 patients i.e 85% are with middle third fractures and 3 patients i.e 15% are of lateral third. We didn't encounter any fractures with medial third during our period of study.



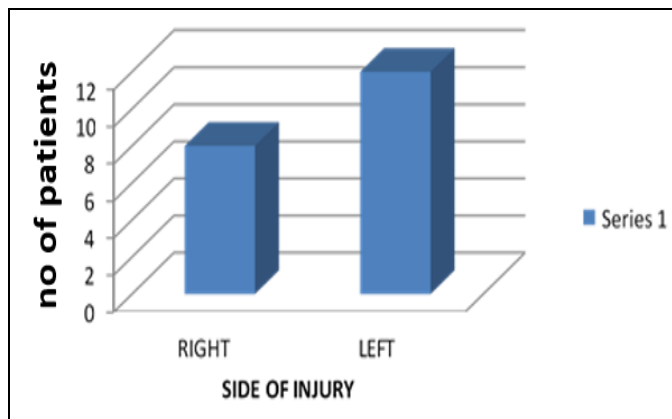
**Graph 4:** Site Affected

**Side Affected**

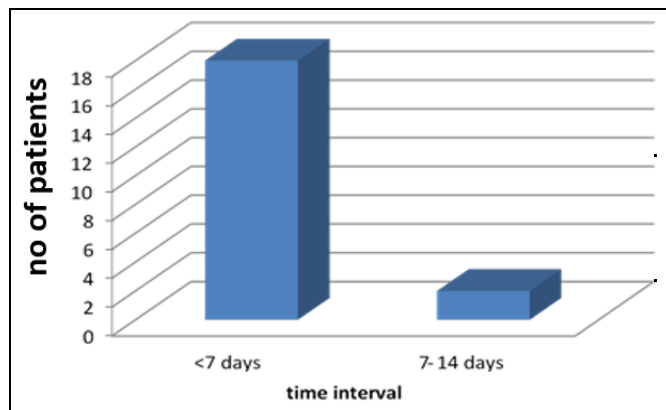
**Table 5:** Side Affected

Side	No. of clavicle #	Percentage %
Right	8	40
Left	12	60
Total	20	100

In this study, there were 12 patients (60%) of Left sided fracture and 8 patients (40 %) of Right sided fracture.



Graph 5: Side Affected



Graph 7: Time interval for

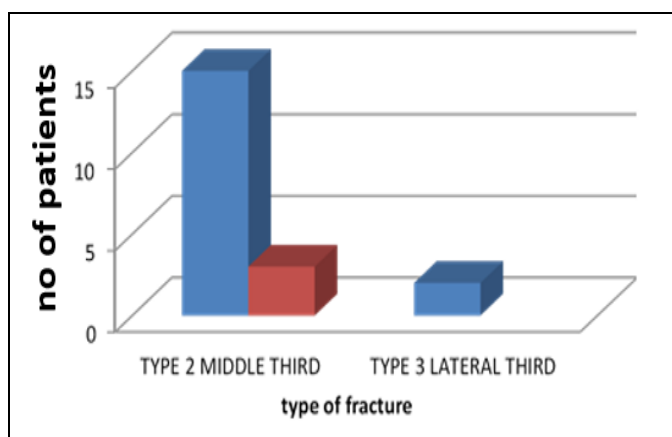
**Classification**

Plain radiograph of clavicle with shoulder is taken in anteroposterior view to assess the site of fracture and the type of fracture (like Displacement, Angulation, Comminution). In this study Robinson classification was followed.

Table 6: Robinson classification table

Type		No. of cases
Type-2 Middle third	B1	15 (75 %)
	B2	2 (10%)
Type-3 lateral third	B1	3(15%)

Out of 20 clavicle fractures Type-2 middle third fracture type-2 B1 (displaced with simple or single butterfly fragment) occurred in 15 patients (75%) and type-2 B2 (displaced with comminuted or segmental) fracture occurred in 2 patients (10%) In type 3 lateral clavicle fractures B1 (displaced fracture and extra articular) seen in 3 patients (15%).



Graph 6: Robinson classification

**Time Interval for Surgery**

All the patients were operated as early as possible once the general condition of the patients was stable.

Table 7: Time interval for surgery

Time of surgery	No. of clavicle #	Percentage %
< 7 days	18	90
7-14 days	2	10

In this study, 18 patients (90 %) were operated in the first week and 2 patients (10%) were operated in the second week due to associated fracture and late patient visit after trauma. All the patients were operated under general anaesthesia.

**Type of Surgery**

All patients in our study are operated using open reduction internal fixation by plating of which 14(70%) fractures are treated with pre-contoured locking compression plate and 6(30%) fractures using reconstruction plates. In all the 3 lateral third clavicle fractures we have used pre-contoured LCPS as the distal cortex purchase was satisfactory. In the 17 middle third clavicle fractures we have used reconstruction plating in 6 cases and LCPs in 11 cases. Decision on plate selection was random and was not affected by any indications. The aim was to place at least 3 screws in the medial and lateral fragments through bone cortices.

Table 8: Type of surgery

Type of Plate	No. of patients	Percentage %
Locking compression plate	14	70%
Reconstruction plate	6	30%
Total	20	100%

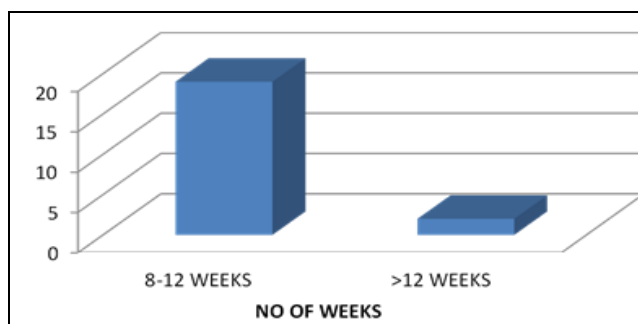
**Duration of Union**

The fracture was considered to be united when clinically there was no tenderness, radiologically the fracture line was not visible and full unprotected function of the limb was possible.

Table 9: Duration of union

Time of union	No. of clavicle fracture	Percentage%
8-12 week	19	95
>12 weeks	1	5

In middle third clavicle fracture 19 patients (95%) united at the end of 12 weeks. In 1 patient (5%) delayed union occurred. In this patient it was due to large butterfly fragment at fracture site which united at 16 weeks each. We advice the patient for removal of the plate at the end of 1 year. No patient has turned up for implant removal. So, Implant removal was not done in any patient till the end of this study.



Graph 8: Duration of Union

**Complications**

Major complication: A complication requiring inpatient treatment and resulting in an additional morbidity of 2 months or more was regarded as a major complication.

**Table 10:** Complications

	Types	No. of cases	%
Minor	Hypertrophic skin scar	2	10
	Plate prominence	1	5
	Delayed union	1	5
	Plate loosening	0	0
Major	Plate breakage	0	0

In this study 2 patients (10 %) had hypertrophic skin scar and in 1 patient (10%) had plate prominence and in another 1 patient (5 %) delayed union occurred

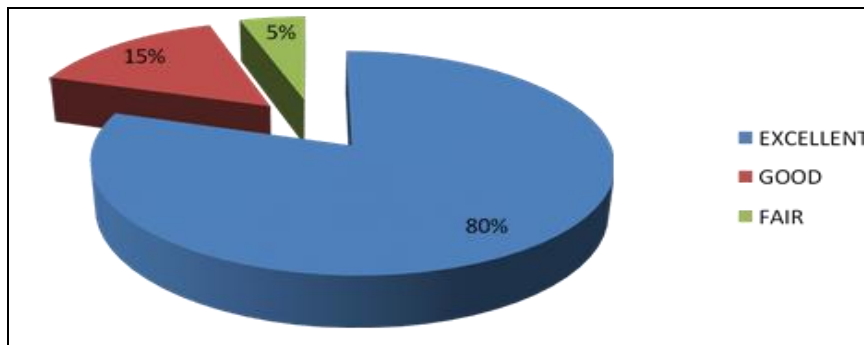
**Functional Outcome**

The functional outcome is assessed by Constant - Murley Score.

**Table 11:** Functional outcome

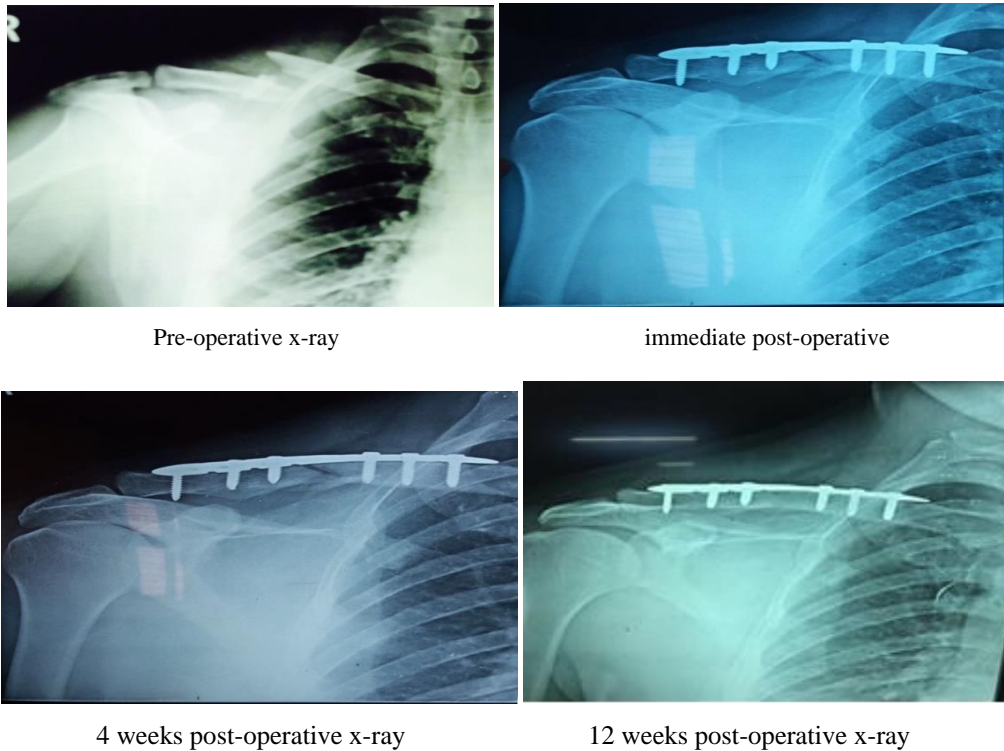
Functional Outcome	No. of clavicle fractures	Percentage%
Excellent	16	80
Good	3	15
Fair	1	5
Poor	0	0
Total	20	100

In this study 16 patients (80 %) had excellent functional outcome, good functional outcome in 3 patients (15 %) and fair in 1 patient (5 %).

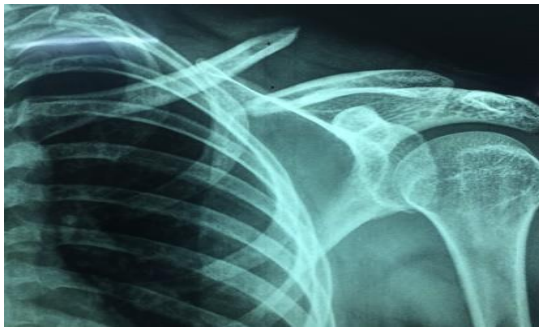

**Graph 9:** functional outcome

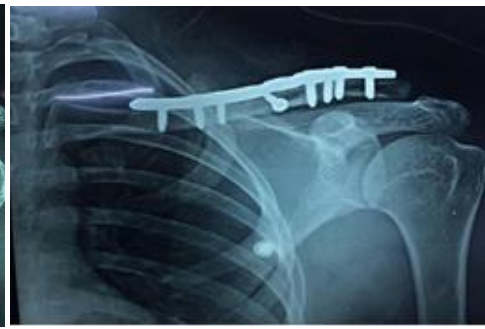**Case 1.**



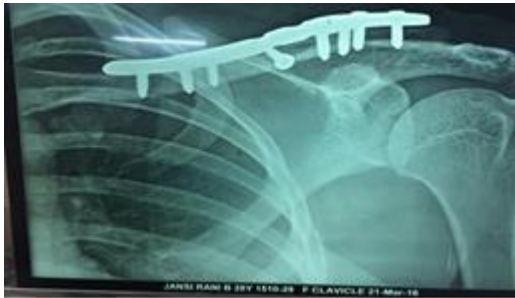Case-2



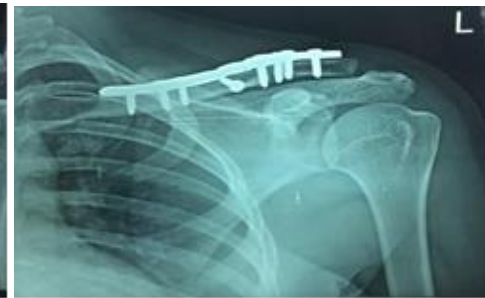Pre-operative x-ray



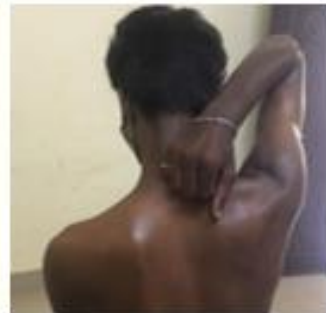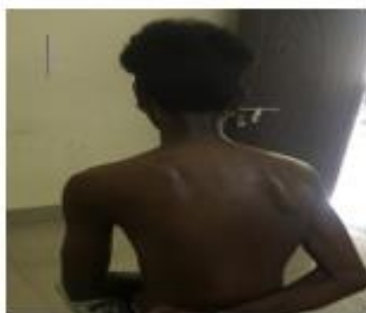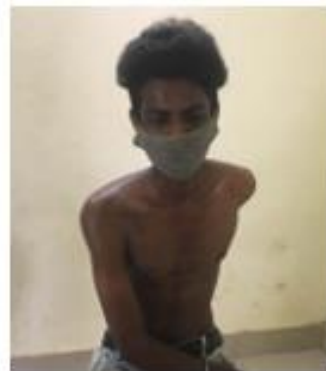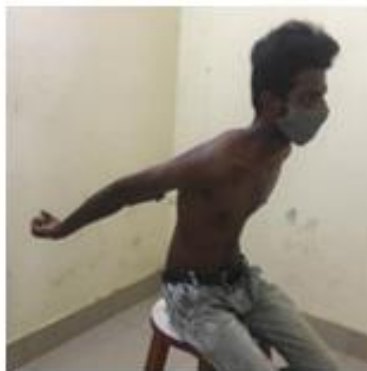Immediate post-operative



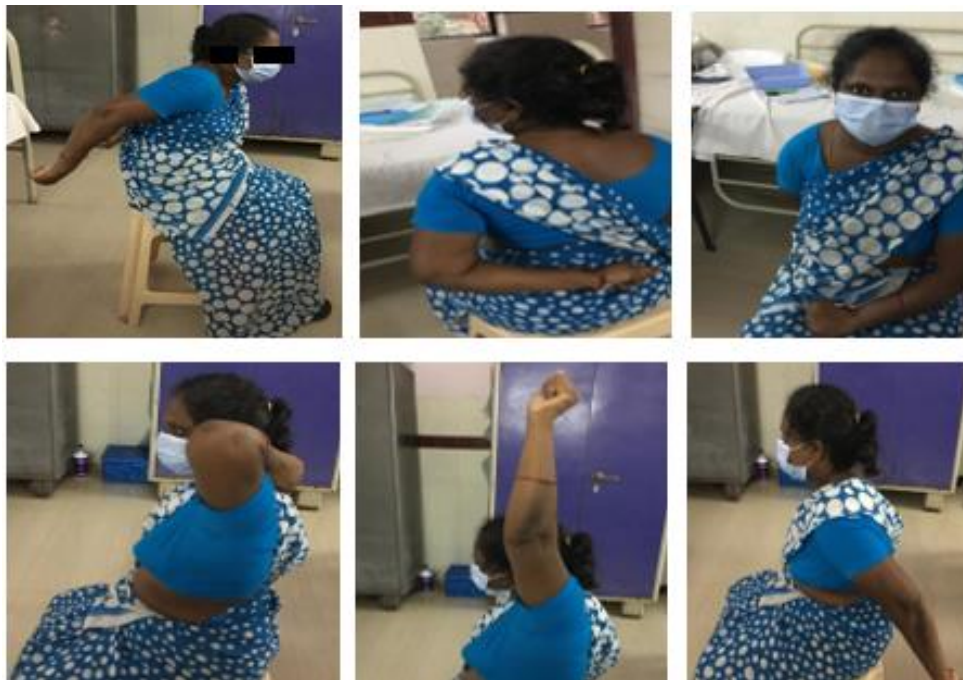4 weeks post-operative



12 weeks post-operative x-ray



Movements: flexion, extension, adduction, abduction, internal rotation, external rotation



Range of movements: flexion, extension, abduction, adduction, internal rotation, external rotation.

## Complications

### Plate Prominence

### Discussion

The clavicle is S-shaped bone with medial convexity and lateral concavity. The middle third is the thinnest part and is located directly under the skin

Thus, it is vulnerable to direct and indirect trauma. This explains the high frequency of fractures in the middle third.

Most clavicle fractures are treated conservatively, the extent of fragment displacement is closely associated with fracture union [21, 22] and anatomical restoration of the displacement is considered essential for rapid recovery. Hence, there has been increasing interest in surgical treatment with open reduction and internal fixation. In particular, surgical treatment is performed in clavicle fractures which are severely displaced and comminuted fractures.

Shen *et al.* [23] obtained satisfactory outcomes in 94% of the 232 cases by open reduction and plate fixation in 2007, the Canadian Orthopaedic Trauma Society reported that internal fixation with plates resulted in more rapid union, excellent clinical outcomes, and lower complication rates with displaced clavicle fractures than non-operative treatments.

The operative methods for the treatment of clavicle fractures are intramedullary K-wire fixation, Steinmann pin fixation and plate fixation. The former two procedures, carry risk of pin loosening and infection, and require a long-term fixation period [24, 25] In addition, Elastic stable intramedullary nailing gives good cosmetic and functional results. Patients postoperatively have less pain and good range of motion in the shoulder joint [26-28]. Elastic stable intramedullary nailing is only recommended for simple or displaced wedge fractures [29].

Open reduction and internal fixation with plates, such as Sherman plates, dynamic compression plates, and semi tubular plates are effective in obtaining anatomical reduction and compression at fracture site and producing resistance to torque. However, it is disadvantageous in severely comminuted fractures as it is difficult to get good reduction [30].

In contrast, reconstruction plates can be manipulated to fit

contour of the clavicle and fracture pattern to obtain firm fixation, they are durable to multidirectional mechanical stress imposed on the fracture site [23, 31].

In this study with use of reconstruction plate no complications like subclavian artery injury or brachial plexus injury were their found and no cases of any screw loosening. The advantages of reconstruction LCPs include strong fixation due to locking between the screw and plate, and blood supply preservation due to minimal contact between plate and cortical bone [27, 28] when an LCP is used, an external force is transmitted from the cortical bone through the conically threaded plate hole to the plate because the screw head is locked firmly in the threaded plate hole. Therefore, the plate does not need to be compressed onto the cortical bone for stability, which results in good preservation of the blood supply, and the plate thread is also helpful in preventing screw loosening or instability [29, 32]. Even though the sample of our study is small we did not observe any differences between reconstruction plate cases and LCP plate cases.

Nevertheless, a reconstruction LCP can be an effective replacement for are construction plate considering that complications, such as screw loosening and plate failure, were not observed in the reconstruction LCP group.

For lateral third fractures we have got a sample of only 3 cases in our entire study period and we have used locking compression plates for all 3 cases as the distal purchase was adequate. Tan *et al.* [34] revealed that locking plate fixation exhibited excellent results in daily activities, no shoulder pain, ROM are good. Tan *et al.* [34] described that 74% of patients with hook plate developed shoulder pain.

Unfortunately, surgical treatments for clavicle fractures leave distinct scars on the shoulder. Ali Khan and Lucas *et al.* [33] suggested in 1978 that patients with clavicle midshaft fractures could suffer from hypertrophic scarring after surgical treatments with plates. Surgical scars are currently considered major complications due to the increasing demand for aesthetics. Six of our patients had hypertrophic scarring after surgery and complained of discomfort in carrying out their daily activities. However, the patients should be informed of the possible appearance of surgical scars preoperatively.

The present study of patients with clavicle fractures is compared with Bostman *et al.* [18] study which treated middle third clavicle fractures, 103 patients were treated by early open reduction and internal fixation with plate and screws. It was also compared with Cho *et al.* [17, 7] study where 41 patients with a clavicle midshaft fracture were treated by internal fixation with a reconstruction plate (19 patients) or reconstruction LCP (22 patients). It was also compared with H. Jiang *et al.* [35] study, where 64 cases of open reduction and internal fixation were performed for clavicle mid shaft fractures. MIPPO and conventional open reduction surgery procedures with locking compression plate were used in 32 and 32 cases respectively.

### Mechanism of injury

In this study the patients with middle third clavicle fracture the mechanism of injury was due to fall on the shoulder from two-wheeler in 7 patients (35%), Road traffic accident in 6 patients (30%), simple fall on the shoulder in 3 patients (15%), Fall on outstretched hand in 4 patients (20%). In Bostman *et al.* [18] study the mechanism of injury was due to fall from the two-wheeler in 38 Patients (36.8%), slipping and fall in 24 Patients (23.30%), motor vehicle accident in 19 patients (18.45%) and sports injuries in 22 patients (21.36%). This shows direct injury to the shoulder is the common cause of this fracture.

### Age Incidence

Clavicle fracture commonly occurred between the age group of 19 to 29 years in 7 patients (40%). The youngest patient age was 20 years and oldest patient age was 56 years. The average patients age was 33 years. In Bostman *et al.* [18] study patients average age was 33.4 years. In Cho *et al.* [17] study, in reconstruction plate group the mean age was 45 (range 22-70) and that of the locking compression plate was 46 (range 19-69). From this we can infer that clavicle fractures occur in young and active patients.

### Sex Incidence

The patients in this study were 16 males and 4 females. In Bostman *et al.* [18] series also commonly males are affected 76 Patients (73.79%) compared to females 27 Patients (26.21%). In Cho *et al.* [17] study, the reconstruction plate groups it was 12 male and 7 female Patients and in the locking compression plate group it was 17 male and 5 female patients. Male predominance can be drawn from this inference.

### Associated injuries

In this study 2 patients had associated injury in the form of tibial plateau fracture and floating elbow. This was caused by Road traffic accident. In Cho *et al.* [17] study, an associated injury was found in 16 Cases: hemothorax and rib fracture in 5 cases, scapular fracture in 3 cases and rotator cuff tear in 1 Case.

### Type of fracture

In this study all Patients with clavicle fractures were of closed type. This is comparable to Bostman *et al.* [18] and Cho *et al.* [17] which also showed all their patients were closed fractures.

### Fracture classification

In this present study, Robinson Type-2 B1 (Displaced with simple or butterfly fragment) were more common and there were 15 Patients (75 %). Type-2 B2 (displaced with comminution) occurred in only 2 Patients (10 %) and lateral

third type-3 B1 in 3 Patients (15%). In a study by Nordqvist *et al.* [80] fractures of midshaft clavicle are 76% and fracture of lateral third clavicle are 21%. In Bostman *et al.* [18] study also Robinson type-2B1 was common in 81 patients (78.64%), Robinson type-2 B2 occurred only in 22 patients (21.36%). In Cho *et al.* [17] study, in reconstruction plate group there were 7 Patients with B1 type and 12 Patients with B2 type and that of the locking compression group had 9 Patients with B1 type and 13 Patients with B2 type. In H. Jiang *et al.* [35] study, in MIPPO group there were 18 patients with B1 type and 14 patients with B2 type and that of conventional open reduction group had 15 Patients with B1 type and 17 Patients with B2 type. In a recent multicentral study by Caroline *et al.* [36] they classified 2422 clavicle fractures by Robinsons classification out of which 358 (14.8%) are of type 3 B1 which is similar to our study.

### Time interval for surgery

Most of the patient in our study were operated in the first week i.e. 18 patients (90%). 2 patients (10%) were operated in the second week due to associated injuries.

In Bostman *et al.* [18] study all the patients were operated within 3 days of injury. In Cho *et al.* [17] study, the reconstruction plate group was operated within 4 days and that of locking compression plate was 9 days. In H. Jiang *et al.* [35] study, the MIPPO group was operated within 7 days (1-15 days) and in conventional open reduction group was operated within 7 days.

### Type of surgery

In this study 14 cases were treated by using locking compression plates and in 6 cases reconstruction plates were used. In Cho *et al.* [17] out of 41 cases reconstruction plate was used in 19 cases and LCPs were used in 22 cases. In this study at least 3 cortices were fixed on either side of fracture. In Bostman *et al.* [18] study, plate length was above 6 holes, to fix at least three screws in each fragment. Plate length also depends upon the amount of comminution.

### Duration of union

In this study majority of the middle third clavicle fracture cases united between 8 to 12 weeks i.e. 19 Patients (95%). In 1 Patient (5%) delayed union occurred as there was a displaced butterfly fragment which united with the main fragment at the end of 16 weeks.

Lazarus MD *et al.* [37] stated radiological union occurred between 6 to 12 weeks. In Cho *et al.* [17] study, bony union with reconstruction plate was 14.6 weeks and that of locking compression plate was 13.2 weeks. In H. Jiang *et al.* [35] study, mean time of union in conventional open reduction group was 13 weeks compared to 12 weeks in MIPPO group.

### Complications

#### A. Major Complications

There were no major complications in this study. Bostman *et al.* [18], Cho *et al.* [17] and H. Jiang *et al.* [35] study didn't have any major Complications.

#### B. Minor Complication

##### Delayed union

Delayed union occurred in 1 Patient (5 %) due to a large butterfly fragment with union at the end of 16 weeks. In Bostman *et al.* [18] study, delayed union occurred in 3 Patients (2.91 %).



### Skin complications

There was hypertrophic skin scar in 2 Patients (10 %). Plate prominence through the skin was reported in 1 Patient (5%). In H. jiang *et al.* [35] study, in conventional open reduction dysesthesia in area of skin incision and directly below occurred in 10 cases, hypertrophic skin scar occurred in 5 cases, painful shoulder in 2 cases, limitation of shoulder movement in 1 case. The total complications in MIPPO study were 10 % excluding skin related minor complications. The total complication rate in Bostman *et al.* [18] study was 23%.

### Functional outcome

The functional outcome according to Constant -Murley Score [19, 20] in this study, total 20 Patients of fresh middle third clavicle fracture fixed with locking compression plate and screws showed excellent results in 16 Patients (80%) and good functional outcome in 3 Patients (15%), fair functional outcome in 1 Patient (5%) where plate prominence occurred and the patient had some shoulder pain.

The advantage of rigid internal fixation and early mobilization of fresh displaced comminuted middle third clavicle fractures is that it gives early pain relief, prevents the development of shoulder stiffness and non-union.

### Conclusion

The clavicle is frequently fractured bone. Clavicle shaft fractures were traditionally treated conservatively with good results. Modern studies proposed operative approach as procedure of choice when dealing with comminuted, displaced middle third and lateral third clavicles fractures. Anatomical reduction and articular congruence is essential in all fractures. Open reduction and internal fixation restores the congruity. Primary open reduction and internal fixation with plate and screws for middle third and lateral third clavicle fractures provides a more stable fixation.

In this study reconstruction plates and locking compression plates were used for middle third fractures. Both of them gave good functional outcome. Locking compression plates are pre contoured and side specific provides strong and stable fixation and minimal contact between plate and bone helps in preservation of blood supply.

Reconstruction plates are lighter and thinner and can be manipulated to fit the contour of the clavicle to obtain firm fixation. It is necessary to put the plate superiorly, fixed with at least three screws each side.

In case of lateral third clavicle fractures open reduction internal fixation with pre-contoured locking plate or hook plate can be used. In our study few cases of lateral third clavicle fractures were treated with pre-contoured locking compression plates gave good functional outcome.

In conclusion, bony union was good and functional outcomes were satisfactory with use of reconstruction plates and locking compression plates in middle third clavicle fractures and lateral third clavicle fractures. In all 20 cases fractures united and showed good functional outcome and there were no non-union cases.

### Summary

Twenty patients with clavicular fractures were treated surgically with primary open reduction and internal fixation with plate and screws between JULY 2019 to JUNE 2020 at DISTRICT GOVERNMENT HOSPITAL, Eluru. Patients above 18 years were included in this study. Clavicle fractures are common between 19 to 29 years. RTA with two-wheelers was common cause of fractures in most of the patients, 16

male and 4 female patients, 60 % of the fractures were left sided and 10 % of the patients had associated injury like tibial plateau fracture and floating elbow which were treated surgically. Out of 20 cases of clavicle fractures 17 cases are middle third and 3 cases are lateral third clavicle fractures. Middle third clavicle fracture were Robinson type-2B1 in 15 Patients, type-2 B2 in 2 patients and in lateral third fractures type-3 B1 in 3 patients. In 18 cases surgery was done within 1<sup>st</sup> week. All our patients were operated under general anesthesia with locking compression plate and screws in 14 patients (11 middle third and 3 lateral third fractures) and reconstruction plates in 6 patients all are middle third fractures).

All our patients are immobilized in an arm sling pouch for 4 weeks. Average duration of stay in the hospital was 10-14 days. All the patients were mobilized at the end of 2<sup>nd</sup> week with the sling.

The functional outcome assessment according to Constant-Murley score showed excellent functional outcome in 16 patients (80%) and good functional outcome in 3 patients (15%) and 1 fair functional outcome in 1 patient (5%).

### Reference

1. Khan L, Bradnock TJ, Scott C, Robinson CM. Fractures of the clavicle. *J Bone Jt Surg Am* 2009;91(2):447-460
2. Robert Buchholz, James D Heckman, Charles Court-Brown, Rockwood Green's Fractures In Adults 6th Edition 2006;1:1213- 1216.
3. Nowak J, Mallmin H, Larsson S. The aetiology and epidemiology of clavicular fractures. A prospective study during a two-year period in Uppsala, Sweden. *Injury*. 2000;31(5):353-358.
4. Schiffer G, Faymonville C, Skouras E, Andermahr J, Jubel A: Midclavicular fracture: Not just a trivial injury – current treatment option, *Dtsch Arztebl Int* 2010;107(41):711-7.
5. Stanley D, Trowbridge EA, Norris SH. The mechanism of clavicular fracture. A clinical and biomechanical analysis. *J Bone Joint Surg Br* 1988;70(3):461-464
6. Robinson CM. Fractures of the clavicle in the adult. Epidemiology and classification. *J Bone Joint Surg Br*. 1998;80(3):476-484.
7. Neer CS. II Nonunion of the clavicle, *JAMA*, 1960;172:1006-1011.
8. Rowe CR. An atlas of anatomy and treatment of midclavicular fractures *Clin Orthop Relat Res* 1968;58:29-42
9. Van der Meijden OA, Gaskill TR, Millett PJ. Treatment of clavicle fractures: current concepts review *J Shoulder Elbow Surg* 2012;21:423-429.
10. Hill JM, McGuire MH, Crosby LA. Closed treatment of displaced middle-third fractures of the clavicle gives poor result *J Bone Joint Surg Br*, 1997;79:537-539.
11. Lazarides S, Zafiroopoulos G. Conservative treatment of fractures at the middle third of the clavicle: the relevance of shortening and clinical outcome *J Shoulder Elbow Surg* 2006;15:191-194.
12. McKee RC, Whelan DB, Schemitsch EH, McKee MD. Operative versus nonoperative care of displaced midshaft clavicular fractures: a meta-analysis of randomized clinical trials *J Bone Joint Surg Am* 2012;94:675-684.
13. Smekal V, Irenberger A, Struve P, Wambacher M, Krappinger D, Kralinger FS. Elastic stable intramedullary nailing versus nonoperative treatment of displaced midshaft clavicular fractures-a randomized, controlled,

- clinical trial J Orthop Trauma 2009;23:106-112.
14. Zlowodzki M, Zelle BA, Cole PA, Jeray K, McKee MD. Treatment of acute midshaft clavicle fractures: systematic review of 2144 fractures: on behalf of the Evidence-Based Orthopaedic Trauma Working Group, J Orthop Trauma 2005;19:504-507.
  15. Stegeman *et al.* Displaced Midshaft Fractures of the Clavicle: Non-Operative Treatment Versus Plate Fixation (Sleutel-TRIAL). A Multicentre Randomised Controlled Trial. BMC Musculoskeletal Disorders 2011;12:196.
  16. Modi N, Patel AD, Hallam Norfolk P. Norwich University Hospital NHS Foundation Trust, Norwich, UK. Outcome Of 62 Clavicle Fracture Fixations With Locked Compression Plate: Is This The Right Way To Go? doi:10.1016/j.injury.2011.06.266
  17. Chul-Hyun Cho, Kwang-Soon Song, Byung-Woo Min, Ki-Cheor Bae, Kyung-Jae Lee. Reconstruction Plate versus Reconstruction Locking Compression Plate for Clavicle Fractures. Clinics in Orthopedic Surgery 2010;2:154-159.
  18. Bostman O, Manninen M, Pihlajamaki H. Complications of plate fixation in fresh displaced mid clavicular fractures. J Trauma 1997;43:778-783.
  19. Constant CR, Murley AHG. A clinical method of functional assessment of the shoulder. Clinical orthopaedics and related research 1987;214:160-164.
  20. Labler L, Platz A, Weishaupt D, Trentz O. Clinical and functional results after floating shoulder injuries J Trauma 2004;57:595-602.
  21. Robinson CM, Court Brown CM, McQueen MM, Walkefield AE. Estimating the risk of non union following non operative treatment of a clavicular fracture. J Bone Joint Surgery (Am) 2004;86:1359-1365.
  22. Kim SK, Kwon KW, Lee SW, Chung YS. The statistical analysis of factors influencing union of clavicle fractures. J Korean Fracture Soc 1992;5(1):37-42.
  23. Shen WJ, Liu TJ, Shen YS. Plate fixation of fresh displaced midshaft clavicle fractures. Injury 1999;30(7):497-500.
  24. Neer CS. 2nd Fractures of the distal third of the clavicle. ClinOrthop Relat Res. 1968;(58):43-50.
  25. Post M. Current concepts in the treatment of fractures of the clavicle. ClinOrthopRelat Res 1989;(245):89-101.
  26. Lee YS, Lin CC, Huang CR, Chen CN, Liao WY. Operative treatment of mid clavicular fractures in 62 elderly patients: knowles pin versus plate. Orthopedics 2007;30(11):959-964.
  27. Iannotti MR, Crosby LA, Stafford P, Grayson G, Goulet R. Effects of plate location and selection on the stability of midshaft clavicle osteotomies: a biomechanical study. J Shoulder Elbow Surg 2002;11(5):457-462.
  28. Howard FM, Shafer SJ. Injuries to the clavicle with neurovascular complications: a study of fourteen cases. J Bone Joint Surg Am 1965;47(7):1335-1346
  29. Ring D, Perey BH, Jupiter JB. The functional outcome of operative treatment of ununited fractures of the humeral diaphysis in older patients. J Bone Joint SurgAm 1999;81(2):177-190.
  30. Haidukewych GJ. Innovations in locking plate technology. J Am AcadOrthop Surg.2004;12(4):205-212.
  31. Perren SM. Evolution and rationale of locked internal fixator technology: introductory remarks. Injury. 2001;32(2):B3-B9.
  32. Wagner M General principles for clinical uses of LCP. Injury. 2003;34:B31-B42
  33. Tan HL, Zhao JK, Qian C. clinical results of treatment using clavicular hook plate vs a Locking plate in neer type 2 distal clavicle fractures 2012;35:e11- 97.
  34. Klein SM, Badman BL, Keating CJ. Results of surgical treatment of unstable lateral Clavicle fractures 2010;19:1049-1055
  35. H.Jiang. W. Qu. Comparison between MIPPO and Coventional open reduction, Orthopedics and Traumatology: Surgery and Research 2012;98(6):666-671.
  36. Carolinekihlstrom, Michael Moller, Katarina lonn, ol of wolf. Clavicle fractures: Epidemiology, classification and treatment of fractures in Swedish fracture register 2017;10:1186.
  37. Shen WJ, Liu TJ, Shen YS. Plate fixation of fresh displaced mid shaft clavicle fractures. Injury 2000;31(3):175-179.