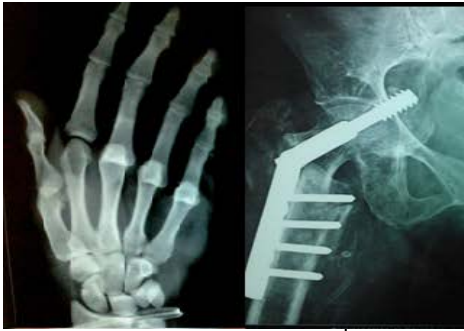



International Journal of Orthopaedics Sciences

E-ISSN: 2395-1958
P-ISSN: 2706-6630
IJOS 2021; 7(3): 612-615
© 2021 IJOS
www.orthopaper.com
Received: 28-05-2021
Accepted: 30-06-2021

Dr. Ravi GO
Associate Professor, Bapuji
Hospital and JJM Medical
College, Davangere, Karnataka,
India

Dr. Rahul Jain
Junior Resident, Bapuji Hospital
and JJM Medical College,
Davangere, Karnataka, India

Dr. Pradeep Hullatti
Junior Resident, Bapuji Hospital
and JJM Medical College,
Davangere, Karnataka, India

A prospective study on surgical management of neer's two-part and three-part proximal humerus fractures by philos plating and its functional outcome

Dr. Ravi GO, Dr. Rahul Jain and Dr. Pradeep Hullatti

DOI: <https://doi.org/10.22271/ortho.2021.v7.i3i.2812>

Abstract

Background and Objectives: Fractures of proximal humerus are the second most common fracture of upper limb accounting 4% to 5% of all fractures. There are different modalities of surgical treatment like multiple k-wire fixation, proximal humeral nailing, locking plate osteosynthesis, TBW and Hemiarthroplasty of shoulder. The mode and type of fracture fixation depends on the fracture pattern, bone quality, age and activity of patient. The goal is to achieve near anatomical reduction and stable fixation so as to achieve early mobilization.

Method: A Prospective study of 30 cases of surgically managed fractures of Proximal Humerus Using Proximal Humerus (PHILOS) Locking Compression Plates undertaken at Department of Orthopaedics, JJM. Medical College, Davangere from 1st August 2019 to 31st July 2021 who follow Inclusion and Exclusion criteria. Post operative functional outcome was assessed by using Constant And Murley Scoring.

Result: The most common age group included in our study was between 50-60 years (50%) with mean age group being 47.66 years. 20 patients had a fracture of right proximal humerus and 10 had of the left side. Our study included 14 (47%) patients with 2 part surgical neck fracture, 12 (40%) with 3 part surgical neck with greater tuberosity, 3 (10%) with 3 part surgical neck with lesser tuberosity and 1 (3%) patient with 2 Part greater tuberosity fracture. Functional results were 6 (20%) patients had excellent result. 18 (50%) patients had good, 4 (13.33%) patients had moderate and 2 (6.66%) patients had poor result at 1 year follow up. The average Constant And Murley Score being 76.9.

Conclusion: PHILOS plate appears to be a new generation promising implant for the internal fixation of proximal humerus fractures. The design provides stable fixation even in osteoporotic bone and allows early mobilization of the joint. It is suitable for two-part, three-part fractures in young and in elderly patients providing that the correct surgical technique is used.

Keywords: proximal humerus fracture, PHILOS, Neer's classification

Introduction

Fractures of proximal humerus are the second most common fracture of upper limb accounting 4% to 5% of all fractures [1]. The third most commonly occurring fracture in among non vertebral fractures is proximal humerus fracture (PHF) next only to distal end radius and hip fractures especially in elderly osteoporotic bones. The incidence is on the rise due to the increase in the aging population and osteoporosis [2, 3].

According to Neer's classification proximal humerus fracture was classified in to type I, II, III and IV in which type I constitutes undisplaced or minimally displaced fractures. These minimally or undisplaced fractures constitutes about 85% which can be treated conservatively and 15% of displaced fractures require surgery According to recent recommendations, the fractures of proximal humerus that have been displaced greater than 45 degrees or 1 cm should be managed with closed or open reduction and operative fixation [4, 5].

There are different modalities of surgical treatment like multiple k-wire fixation, proximal humeral nailing, locking plate osteosynthesis, TBW (Tension Band Wiring and Hemiarthroplasty of shoulder. However, complications have been reported using these techniques including cutout or backout of the screws and plates, avascular necrosis, nonunion, malunion, nail migration, rotator cuff impairment, and impingement syndrome.

Corresponding Author:
Dr. Rahul Jain
Junior Resident, Bapuji Hospital
and JJM Medical College,
Davangere, Karnataka, India

The rate of these complications can be as high as 100% for elderly patients. The proximal humeral internal locked system plate is intended to avoid the high complication rate related to the fixation of proximal humerus fractures. But no consensus is available on the ideal treatment modality.

The mode and type of fracture fixation depends on the fracture pattern, bone quality, age and activity of patient. The goal is to achieve near anatomical reduction and stable fixation so as to achieve early mobilization. The present study was undertaken to highlight the experience of treating Neer's 2 part and 3 part PHF (Proximal Humerus Fractures) with PHILOS locking plate and analysing its functional outcome.

Material and Methods

This prospective study is an analysis of functional outcome of 30 cases of surgically managed fractures of Proximal Humerus Using Proximal Humerus (PHILOS) Locking Compression Plates undertaken at Department of Orthopaedics, J.J.M. Medical College, Davangere from 1st August 2019 to 31st July 2021. The Inclusion Criteria are Age group 18 years to 60 years age, patients presenting with Neer's two part, three part fracture of proximal humerus. The exclusion criteria are undisplaced fractures, patients age less than 18years, open fractures, polytrauma, head injury, neurovascular injury.

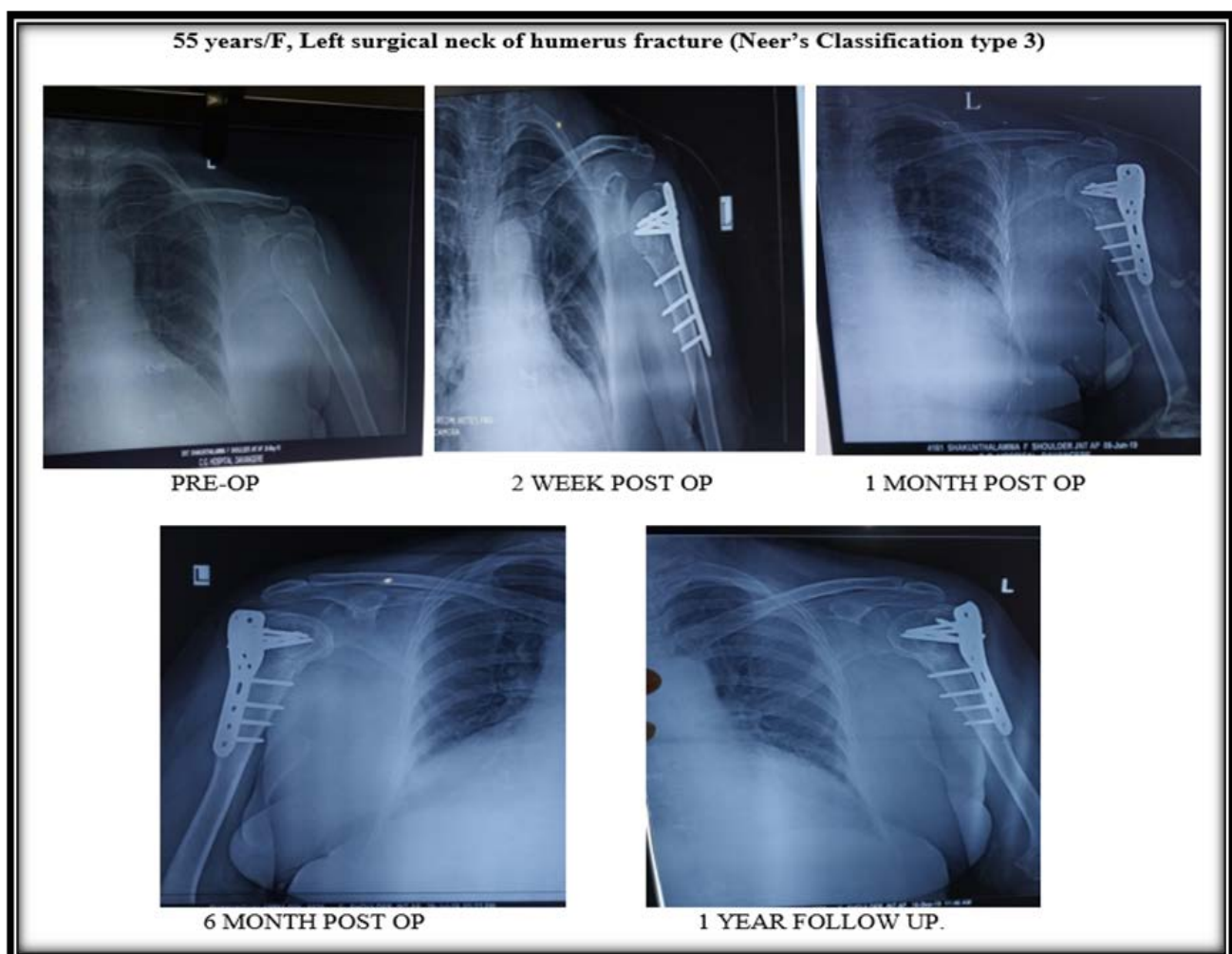
Surgical Technique

Routine investigations like complete haemogram, blood sugar, renal function tests, serum electrolytes, blood grouping and typing, bleeding time, clotting time, chest x ray PA view, ECG were done. Radiographs of the affected shoulder were

taken in AP, Lateral and Axillary views and fractures were classified according to Neer's classification. CT pictures were taken in selected patients with complex fracture patterns to know the articular involvement. Anaesthetic fitness was obtained for all the patients before surgery.

The proximal humerus internal locking operating system plate is pre contoured to the proximal humerus. Patient was placed in a supine position with a sand bag under the scapula of operating arm to push up the operation side for allowing arm to fall backward. Deltopectoral approach was used and the plates are anatomically pre contoured to the lateral aspect of proximal humerus. No bending is required, the plates are low profile for low risk of subacromial impingement. The PHILOS plate has 9 proximal locking screw head in different orientation to ensure good distribution of forces across the screw and 10 suture holes. The plate has 3 types of holes 2mm suture holes where suture passed through rotator cuff and knotted to the plate. These help to maintain and neutralize muscle tension. Locked head screw in proximal part in different orientation gives angular stability and increases buttressing providing better pull out strength.

Negative suction drain removed after 48 hours. Intravenous antibiotics continued for 7th post operative day, sutures removed on 10th post operative day. X-rays are taken in the immediate post-operative period to document the fracture alignment, reduction and fixation. There after at 6 weeks, 12 weeks, 6 months and 1 year to detect signs of fracture union and to identify any implant loosening, deviation, screw penetration, screw backout, impingement and failure. Post operative functional outcome was assessed by using Constant and Murley Scoring.



CLINICAL PICTURE: - RANGE OF MOVEMENTS**Results**

The most common age group included in our study was between 50-60 years (50%) followed by 40-49 years (30%), 30-39 years (13%) and remaining 7% with mean age group being 47.66 years. In our study majority of the patient were females (60%) and males contributed (40%). In our study mode of injury in 19 patients was self fall at ground which included slip and fall with outstretched hand, 8 patients had road traffic accident, 2 patients fall from height and 1 patient had epilepsy. In our study 20 patients had a fracture of right proximal humerus and 10 had of the left side.

The study included 14(47%) patients with 2 part surgical neck fracture, 12(40%) with 3 part surgical neck with greater tuberosity, 3(10%) with 3 part surgical neck with lesser tuberosity and 1(3%) patient with 2 Part greater tuberosity fracture. The average interval between fracture and surgery was 3.5 days. The average hospital stay in our study was 9.5 days. Complications were encountered in 4(13%) patients. 1 patient had shoulder joint stiffness which gradually improved partially over a span of 8-12 months with passive and active Range of motion exercise physiotherapy. 1 patient developed superficial infection with wound gaping which resolved with intravenous antibiotics and later secondary suturing. 1 patient (3.3%) had impingement of the implant with restriction of movements beyond 90 degrees of abduction. 1 patient (3.3%) has varus malunion.

Among 30 cases 15 cases were 2 part fractures among which 4(26.6%) cases showed Excellent result, 10(66.6%) cases Good result and 1 (6.6%) case showed moderate result. Among 15 cases of 3 part fractures 2(13.3%) cases showed Excellent result 8(53.3%) cases Good result, 3(20%) cases showed Moderate result and 2(13.33%) cases showed Poor result. Overall functional results were 6(20%) patients had excellent result, 18(50%) patients had good, 4 (13.33%) patients had moderate and 2(6.66%) patients had poor result at 1 year follow up. The average Constant And Murley Score

being 76.9.

Discussion

The PHILOS (proximal humerus internal locked system) developed by the AO-ASIF group is the latest generation of locking compression plates [6, 7]. The stability is provided by the locking screws and hence better results are obtained in porous bones [8]. The development of locking plates for the treatment of proximal humerus fractures has brought a new dimension to the treatment especially for the three-part, four-part, epiphyseal fractures in young patients and fractures in bone that have become fragile [9].

The main aim of surgical treatment of displaced proximal humerus fractures is to restore the functional status of the patient as far as possible to the pre-fracture state. In the present study, the fractures were classified radiologically according to Neer's classification.

In our study, we found the right side was involved in the n=20 (66.6%) and left side in n=10(33.3%) of cases. The average duration of the interval between the injury and time of surgery was 3.5 days whereas a study by Vijay *et al*; found the average time lag to be 6.24 days whereas Resch *et al* have found the interval between 2 to 10 days [10, 11]. The average time for the radiological union in the present study was between 8-12 weeks in all cases, it was in accordance to similar studies done by Ebraheim *et al*, Klitscher *et al* Kilic *et al*. [12, 13].

In the present study, 20% had excellent results and 50% had good results. Hirschmann *et al*, in their study with 64 patients with a minimum follow-up of four years, treated with locking plate, and have reported 75% excellent and good results [13]. They also concluded that these results continued to improve even one year after the surgery. Fankhauser *et al* found good pain relief with an average constant pain score of 13.9 after one year of follow up. Secondary varus 8°-11° displacement of the proximal fragment was seen in one case of the present

study Acklin *et al*, observed secondary varus displacement in only one out of 29 patients, using the same implant. This is in agreement with the results of the present study [14, 15]. Fankhauser *et al*, observed three cases of secondary varus displacement of the proximal fragment in their series of 29 patients.

The results in our study were comparable to those reported in the literature. The overall complication rates were lower in the present study due to standard surgical intervention and proper post operative follow up done.

Conclusion

PHILOS plate appears to be a new generation promising implant for the internal fixation of proximal humerus fractures. However, there are certain limitations which should be mentioned. The PHILOS plate overcomes most of the main hardware problems such as early failure, screw backout and impingement syndrome. The design provides stable fixation even in osteoporotic bone and allows early mobilization of the joint. It is suitable for two-part, three-part fractures in young and in elderly patients providing that the correct surgical technique is used.

Reference

1. Neer CS II, Rockwood CA. Fractures and dislocations of the shoulder, in Rockwood and Green: Fractures in adults, Philadelphia, PA: Lippincott 1984, 675-621.
2. Zyto K. Non-operative treatment of comminuted fractures of the proximal humerus in elderly patients. *Injury*. 1998;29:349-52.
3. Lind T, Kroser K, Jensen J. The epidemiology of fractures of the proximal humerus. *Arch Ortho Trauma Surg* 1989;108:285-87.
4. Kilic B, Uysal M, Cinar BM, Ozkoc G, Demirors H, Akpinar S. Early results of treatment of proximal humerus fractures with the PHILOS locking plate. *Acta Orthop Traumatol Turc* 2008;42(3):149-53.
5. Codman EA. Fractures in relation to the subacromial bursa. In: Codman EA (editor), *The Shoulder: Rupture of the Supraspinatus Tendon and Other Lesions in or About the Subacromial Bursa*. Boston MA: Thomas Todd; 1934, 313-333.
6. Shahid R, Mushtaq A, Northover J, Maqsood M. Outcome of proximal humerus fractures treated by PHILOS plate internal fixation. Experience of a District General Hospital. *Acta Orthop Belg* 2008;74(5):602-8.
7. Björkenheim JM, Pajarinen J, Savolainen V. Internal fixation of proximal humeral fractures with a locking compression plate. A retrospective evaluation of 72 patients followed for a minimum of 1 year. *Acta Orthop Scand* 2004;75(6):741-45.
8. Clavert P, Adam P, Bevort A, Bonnomet F, Kempf JF. Pitfalls and complications with locking plate for proximal humerus fracture. *J Shoulder Elbow Surg* 2010;19:489-94.
9. Lungershausen W, Bach O, Lorenz CO. Locking plate osteosynthesis for fractures of the proximal humerus. *Zentralbl Chir* 2003;1289(1):28-33.
10. Sharma V, Singh B, Khare S. Management of Proximal Humeral Fractures with Proximal Humerus Locking Plated A Prospective Study. *J Orthop Trauma Rehab*. 2014;18:89-93.
11. Resch H, Povacz P, Fröhlich R, Wambacher M. Percutaneous fixation of three- and four part fractures of the proximal humerus. *J Bone Joint Surg Br*.

1997;79:295-300.

12. Ebraheim NA, Vishwas P, Adeel H. Mini-external fixation of two- and three- part proximal humerus fractures. *Acta Orthop Belg* 2007;73:437-42.
13. Hirschmann MT, Fallegger B, Amsler F, Regazzoni P, Gross T. Clinical longer-term results after internal fixation of proximal humerus fractures with a locking compression plate (PHILOS). *J Orthop Trauma* 2011;25(5):286-93.
14. Fankhauser F, Boldin C, Schippinger G *et al*. A new locking plate for unstable fractures of the proximal humerus. *Clin Orthop Relat Res* 2005;430:176-81.
15. Acklin YP, Jenni R, Walliser M, Sommer C. Minimal invasive PHILOS-plate osteosynthesis in proximal humeral fractures. *Eur J Trauma Emerg Surg*. 2009;35:35-9.