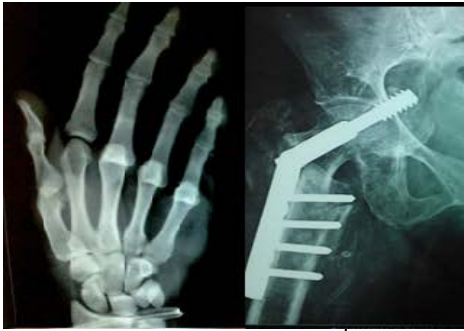



International Journal of Orthopaedics Sciences

E-ISSN: 2395-1958
P-ISSN: 2706-6630
IJOS 2021; 7(3): 334-339
© 2021 IJOS
www.orthopaper.com
Received: 23-05-2021
Accepted: 25-06-2021

Dr. Dulal Saikia
Senior Resident, Department of
Orthopaedics and Trauma,
Assam Medical College and
Hospital Dibrugarh, Assam,
India

Dr. Herman C Frank
Professor, Department of
Orthopaedics and Trauma,
Gauhati Medical College and
Hospital, Guwahati, Assam,
India

Dr. Sudhanshu Kesarwani
Senior Resident, Department of
Orthopaedics and Trauma,
Fakhrudin Ali Ahmed Medical
College and Hospital, Barpeta,
Assam, India

Outcomes of shoulder hemiarthroplasty in non-salvageable proximal humerus fracture: A prospective study

Dr. Dulal Saikia, Dr. Herman C Frank and Dr. Sudhanshu Kesarwani

DOI: <https://doi.org/10.22271/ortho.2021.v7.i3e.2769>

Abstract

Background: Proximal humerus fractures are 5% of all fractures and 80% of all humerus fractures in elderly. Arthroplasty is generally reserved for comminuted Neer's 3 or 4 part fractures, head split fractures or fracture with significant underlying arthritic changes. The aim of the study is to analyse clinical, radiological and functional outcome of shoulder hemiarthroplasty in non-salvageable proximal humerus fracture.

Materials and Methods: This prospective study was carried out in 20 cases of non-salvageable proximal humerus fracture aged above 50 years irrespective of sex. Standard Modular cemented prosthesis were used in all 20 patients. The study was conducted for a period of 15 months and cases were followed up for a period of 6 months.

Results: The average age of patient was 62 years with 12 female and 8 were male. Anterior Deltopectoral approach was used as the standard approach for hemiarthroplasty. Modular Hemiarthroplasty prosthesis was inserted with cement. 13 of the 20 patients has shown good results. The range of movement in all 17 patients are satisfactory except for 3 who had poor results but had satisfactory relief of pain. In 3 patients the greater tuberosity failed to unite.

Conclusion: Outcome of Hemiarthroplasty is quite satisfactory in elderly if done for fresh traumatic non salvageable proximal humerus fracture without involvement of glenoid and without any unreparable major rotator cuff injury. Hemiarthroplasty if done within 2 weeks gives better results as there will be less adhesion of soft tissue thus soft tissue repair and their reattachment can be done meticulously. Hemiarthroplasty shoulder done for non-salvageable proximal humerus fractures will provide better stability, early mobilization, lesser stiffness and satisfactory range of motion (ROM) in elderly.

Keywords: Hemiarthroplasty shoulder, no salvageable proximal humerus fracture, neer's classification, constant-murley score, DASH score.

Introduction

Proximal humerus fractures are 5% of all fractures and 3rd most common fracture after hip and distal humerus fractures ^[1]. Its incidence increases with age ^[1], especially among older osteoporotic women ^[2]. Treatment should focus on maximizing a patient outcome and minimizing pain ^[2]. In the vast majority of cases proximal humerus fractures treated nonoperatively ^[2]. In the cases of displaced fractures the proximal humerus locking plate is the most widely used ^[2]. Arthroplasty is generally reserved for comminute 3 or 4 part fractures, head split fractures or fracture with significant underlying arthritic changes ^[2]. The shoulder hemiarthroplasty indicated in those complex proximal humerus fractures where head is non salvageable or there is avascular necrosis of humerus head after any injury ^[3]. Indications depend on some factors especially age and fracture pattern³. The purpose of this prospective study is to evaluate the functional outcomes of shoulder hemiarthroplasty in non-salvageable proximal humerus fracture.

Material and Methods

This prospective study was carried out in 20 cases of non-salvageable proximal humerus fracture aged above 50 years irrespective of sex attending the OPD and emergency of department of Orthopaedics, Gauhati Medical College and Hospital who met the inclusion and exclusion criteria mentioned below.

Corresponding Author:
Dr. Dulal Saikia
Senior Resident, Department of
Orthopaedics and Trauma,
Assam Medical College and
Hospital Dibrugarh, Assam,
India

All patients were undergone through Hemiarthroplasty of shoulder. Standard Modular cemented prosthesis were used in all 20 patients. The study was conducted for a period of 15 months from 1st June 2018 to 31st August 2019. Of the 20 patients, 12(60%) were females and 8(40%) were males. The mean age of the patients was 62 years. All the cases were followed up for a minimum period of 6 months.

Inclusion Criteria

- Patients age above 50 years.
- Neer's part 2 fracture with AVN of humeral head and with intact glenoid.

- Neer's part 3 and part 4 fractures with or without avascular necrosis of head of humerus with intact glenoid.

Exclusion Criteria:

- Compound fractures of proximal humerus.
- Pathological fractures.
- Neurovascular injury of the limb.

Previous history of seizure, epilepsy, convulsion disorder, alcohol withdraw l.

Table 1: Patients particulars included in the study

| S. No | Age group | No. of Patients | Percentage | Males | Females | Days elapsed between trauma and surgery |
|-------|-----------|-----------------|------------|-------|---------|---|
| 1 | 51-60 | 10 | 50 | 4 | 6 | 0-5 days=16patients |
| 2 | 61-70 | 6 | 30 | 2 | 4 | 6-10days=4patients |
| 3 | >70 | 4 | 20 | 2 | 2 | 11-15days=2patients |

Operative Technique: All 20 patients in our study were operated using anterior approach to the shoulder joint with standard deltopectoral approach.

Step 1. Dissection and exposure: Skin incision is given over deltopectoral groove starting from tip of the coracoid process and subcutaneous tissue retracted. Cephalic vein is identified and retracted laterally and an internervous plane is developed between deltoid (laterally) and pectoralis major (medially) (Fig 1.1). After that conjoint tendon is identified and retracted medially. Clavipectoral fascia is incised vertically under which subscapularis muscle can be seen. A vertical incision is given over subscapularis lateral to conjoint tendon to gain access to shoulder joint along with its capsule. Capsule is incised longitudinally to open the shoulder joint [11]. Head is removed and size is measured with a head gauge. The measured head size is compared with the available prosthetic heads on the back table [12]. Glenoid articular surface is inspected for any damage and wear [12]. Long head of bicep tendon is identified in bicipital groove and following it proximally. Greater tuberosity and lesser tuberosity are identified and both tuberosities are mobilized along with their rotator cuff muscle attachment, sometimes an osteotomy is necessary (in case of part 3 fracture) to complete the fracture [12]. Two 3 sets of number 5 nonabsorbable ethibond are placed superiorly, middle and inferiorly from outside-in at the bone-tendon junction of greater tuberosity and lesser tuberosity (Fig. 1.2). The suture ends with the needles are grasped using small artery forceps and are isolated for later use. In this way rotator cuff muscle are protected for future attachment [12].

Step 2. Shaft preparation and prosthesis placement: Humeral preparation is done using sequential reamer. Reaming is done until mild resistance is met and there is a snug cortical fit. Reaming is performed up to the proper size as determined by cortical chatter, rotational control and preoperative templating [12]. As we have used cemented prosthesis so we use the same size prosthesis stem as with the final size reamer [12]. After this trial of prosthesis stem is done the appropriate humeral height is determined pre- and intraoperatively and then passed by trial reduction [12]. About 20 degree of retroversion is optimum and this can be achieved by external rotation of the arm to 30 degree and cementing the component in neutral position, the lateral fin of the prosthesis should lie about 1 cm behind the distal bicipital groove [12]. We have used 2 drill holes in the humeral shaft, medial and lateral to bicipital

groove, approximately 2 cm distal to proximal aspect of the humeral shaft. One number 5 nonabsorbable ethibond is passed through this hole from medial to lateral which will be used later as figure-of-eight tension band. The end of the suture with the needle is grasped with small artery force p and is isolated [12]. A cement restrictor is placed 1 cm distal to the final resting position of the prosthesis stem. Cement is injected into the medullary canal and final size prosthesis stem is inserted into medullary canal through the cement (Fig.1.3). Excess cement from surrounding soft tissue is removed and prosthesis stem is hold in position to prevent rotation and movement into malposition [12].

Step 3. Tuberosity reduction and fixation: Tuberosity Reattachment is the most important part of the whole surgery. Rigid fixation of the greater tuberosity in proper position, below the humeral head and to the shaft, with transverse and longitudinal number 5 nonabsorbable ethibond which we have attached previously with greater tuberosity and was isolated. Similarly lesser tuberosity is also fixed to the shaft and to the greater tuberosity with the previously attached number 5 non absorbable ethibond [12] (Fig.1.4). The sutures are passed through the holes present on the proximal part of the prosthesis stem. Autogenous bone graft from excised head is placed. Finally this whole construct is reinforced with figure-of-eight tension band suture which we have previously passed through the holes of humeral shaft.

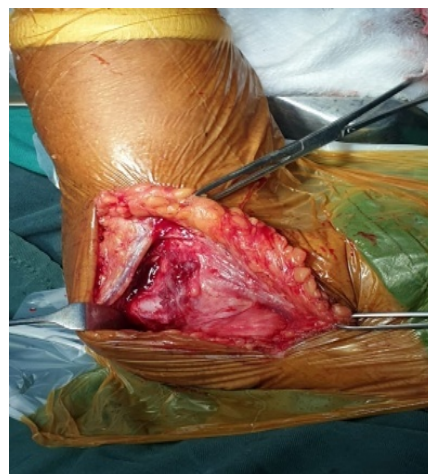

Fig 1.1: Shows in plane is developed between deltoid (laterally) and pectoralis major (medially)

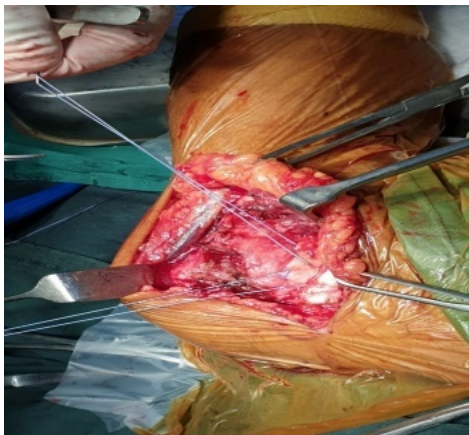


Fig 1.2: Shows in the bone-tendon junction of greater tuberosity and lesser tuberosity

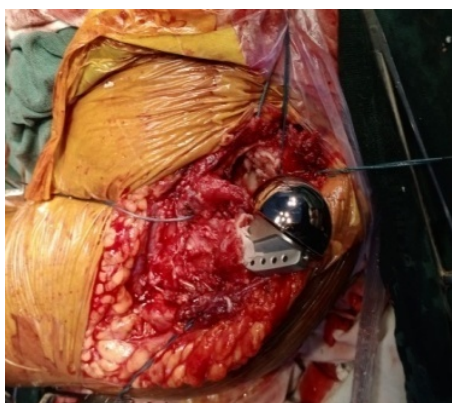


Fig 1.3: Cement is injected into the medullary canal and final size prosthesis stem is inserted into medullary canal through the cement

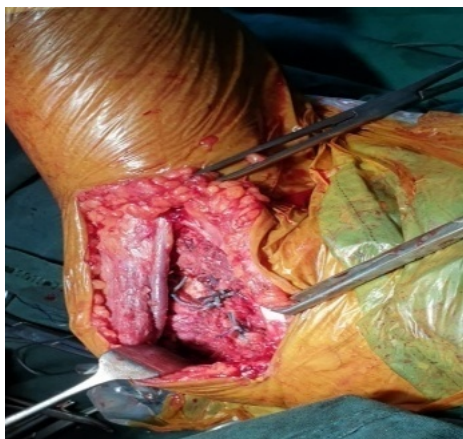


Fig 1.4: Shows in fixed to the shaft and to the greater tuberosity with the previously attached number 5 non absorbable ethibond

Follow up: The patients were followed up after 2 weeks when the suture removal was done. Thereafter patients were followed up on a monthly basis and the functional outcome using Constant-Murley scores at 3,6 and 12 months.

Functional Outcome Assessment: Post-operative functional outcome was assessed by using Constant-Murley Score, DASH score, in every follow up [10].

1. Radiological Evaluation: Post-operative radiological outcome is evaluated by taking serial X rays at every follow up from 4th week onwards documenting on tuberosity union, prosthesis alignment, restoration of articular congruity and failure.

Result

20 shoulder hemiarthroplasty were performed in 20 patients for the treatment of part 3 and 4 part 4 non salvageable proximal humeral fractures with or without osteoporosis. The average age were 62 years and average follow up period was 1 year. The fracture were classified according to Neer classification. There were 11 four parts fractures without osteoporosis, 8 three parts fracture with osteoporosis and 1 patient with 2 part fracture. Out of 20 patient 8 were male and 12 were female and all were above 50 years of age. Deltopectoral approach was used as the standard approach for hemiarthroplasty shoulder in all 20 patients. Modular Hemiarthroplasty prosthesis was inserted with cement. All patients were kept in a sling for a minimum of 2 weeks before physiotherapy was started. All of the patients participated in a supervised program of rehabilitation. Outcome was assessed radiologically and clinically (pain relief, activity of daily living, range of motion, strength). Serial radiographs were taken in every follow up to evaluate the union of the greater tuberosity. 13 of the 20 patients has shown good results. The range of movement in all 17 patients are satisfactory with active flexion range 60-80, Abduction range 50-80 and external rotation range of 30-50 degree. All of the patients except for 3 who had poor results but had satisfactory relief of pain. The greater tuberosity failed to unite in those 3 patients who have showed poor results. Postoperative immobilization did not result in excessive stiffness and satisfactory functional outcome have seen in those patients younger than 55 years of age. However tuberosity union could not be guaranteed in very old patients. Standard rehabilitation regime following hemiarthroplasty for trauma patients with early mobilization done to prevent the development of a stiff shoulder, However it is seen that an aggressive early rehabilitation may lead to nonunion of greater tuberosity. Thus we conclude that a moderate delay in rehabilitation will result in a good union rate without undue risk of shoulder stiffness.

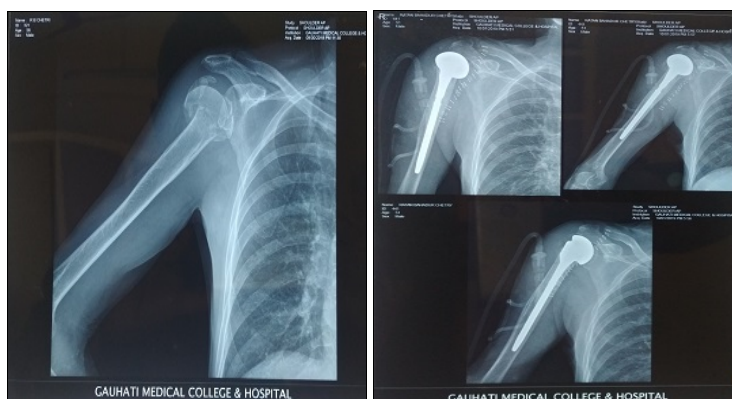


Fig 2.1: Preoperative and postoperative x-rays of a 65 years male patient with 3 part proximal humerus fracture.

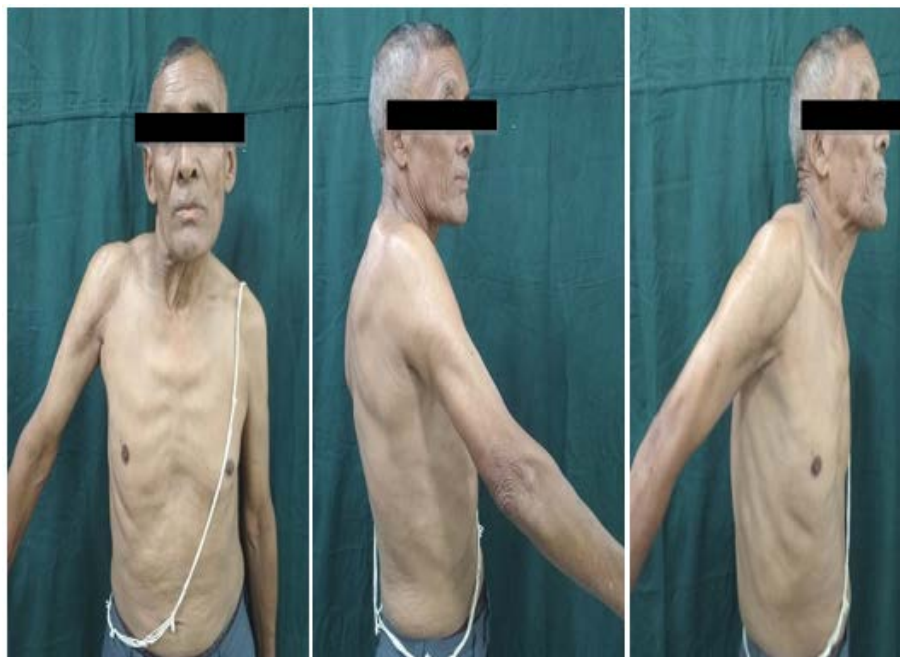

Fig 2.2: Clinical images of range of movement at 3 months

Fig 2: Post-operative range of movement at 6 months

| S. No. | Age/Sex | Flexion | Extension | Abduction | Internal Rotation | External rotation |
|--------|---------|---------|-----------|-----------|-------------------|-------------------|
| 1 | 54/M | 90 | 40 | 90 | 70 | 60 |
| 2 | 55/F | 90 | 30 | 90 | 60 | 60 |
| 3 | 56/F | 80 | 45 | 80 | 60 | 50 |
| 4 | 56/M | 100 | 45 | 90 | 70 | 60 |
| 5 | 56/F | 80 | 30 | 80 | 60 | 50 |
| 6 | 57/M | 80 | 30 | 70 | 50 | 50 |
| 7 | 58/F | 90 | 30 | 80 | 60 | 60 |
| 8 | 58/F | 80 | 30 | 80 | 60 | 50 |
| 9 | 58/F | 90 | 40 | 90 | 60 | 60 |
| 10 | 59/M | 80 | 40 | 90 | 60 | 50 |
| 11 | 60/F | 90 | 40 | 90 | 60 | 60 |
| 12 | 61/F | 80 | 40 | 90 | 50 | 50 |
| 13 | 64/F | 90 | 40 | 90 | 60 | 60 |
| 14 | 65/M | 90 | 40 | 90 | 60 | 60 |
| 15 | 66/M | 90 | 40 | 80 | 60 | 50 |
| 16* | 67/F | 50 | 20 | 30 | 30 | 30 |
| 17 | 72/M | 80 | 40 | 90 | 60 | 50 |
| 18 | 74/M | 80 | 45 | 90 | 50 | 50 |
| 19* | 72/F | 50 | 25 | 20 | 30 | 30 |
| 20* | 72/F | 50 | 30 | 30 | 30 | 30 |

Fig 3: Outcome measures using 2 scores and comparison between 2 score at 6 months

| Constant-Murley Score | | | Dash Score | | |
|-----------------------|-----------------|------------|------------------|-----------------|------------|
| Rating | No. of Patients | Percentage | Rating | No. of Patients | Percentage |
| Excellent(86- 100) | 2 | 10% | Excellent(0- 20) | 3 | 15% |
| Good(71-85) | 11 | 55% | Good(21- 40) | 10 | 50% |
| Moderate(56-70) | 4 | 20% | Fair(41-60) | 4 | 20% |
| Poor(0-55) | 3 | 15% | Poor(>60) | 3 | 15% |

Discussion

Proximal humerus fractures are 5% of all fractures in elderly and 3rd most common fracture after hip and distal humerus fractures¹. It comprises 80% of all humerus fractures and its incidence increases with age¹. Proximal humerus fractures are common injuries especially among older osteoporotic women². In the vast majority of cases proximal humerus fractures treated nonoperatively^[2]. In the cases of displaced fractures the proximal humerus locking plate is the most widely used^[2]. Arthroplasty is generally reserved for

comminuted 3 or 4 part fractures, head split fractures or fracture with significant underlying arthritic changes². Shoulder hemiarthroplasty indicated in those complex proximal humerus fractures where head is non salvageable or there is avascular necrosis of head of humerus after any injury³. Fresh trauma cases where there is no osteoarthritic changes in the joint are to be chosen for hemiarthroplasty shoulder. The purpose of this prospective study is to evaluate the functional outcomes of shoulder hemiarthroplasty in non-salvageable proximal humerus fracture.

Per Wretenberg and Anders Ekelund (1997) ^[14] *et al.* in their study done in 18 patients they have found that acute hemiarthroplasty in elderly patients following 3 or 4 part fractures of the proximal humerus results in good pain relief ^[14], similarly in our study 80% patients show excellent pain relief postoperatively after few weeks.

Eketerina (2012) ^[21] *et al.* In their study they have found arthroplasty is reserved for fractures that cannot be reconstructed, such as comminuted 4 part fractures, head split fractures.

Simon S. Jameson (2013) ^[5] in their study found that shoulder

hemiarthroplasty is in general reserved for those patients who will not look to exceed the post-operative function that the implant is capable of. In our study we have also found that postoperatively full range of movement cannot be achieved in elderly but they can do their day to day activities.

P. Clavert (2014) ^[22] *et al.* in their anatomic study they have found that priority should be given to the precise positioning of the prosthesis with regard to height and version. In our study also we have found that proper positioning of prosthesis gives better result with good postoperative range of movement.

Functional outcome in various studies.

| Studies | Total number of patients | Outcome Constant-Murley Score | |
|---|----------------------------------|-------------------------------|--------------|
| | | Excellent | Satisfactory |
| Rouin Amirfeyz, Partha Sarangi <i>et al.</i> (2008) ^[87] | 40 patients out of which 1 died. | 20(51.3%) | 13(33.3%) |
| Panagopoulous (2013) ^[7] | 38 patients | 9(23%) | 21(55%) |
| Present study (2018) | 20 patients | 2(10%) | 11(55%) |

Average Constant-Murley Score of various studies.

| Studies | Total number of patients | Average Constant- Murley Score |
|---|----------------------------------|--------------------------------|
| Rouin Amirfeyz, Partha Sarangi <i>et al.</i> (2008) ^[87] | 40 patients out of which 1 died. | 73 |
| Hiroshi Satoshi (2015) ^[88] Hashiguchi, Iwashita <i>et al.</i> | 35 patients | 82 |
| Present study (2018) | 20 patients | 68 |

Analysis of various studies shows comparable results. Overall functional outcome of hemiarthroplasty shoulder in various studies (based on Constant-Murley score) including our studies varies from 65% to 84% excellent to good/satisfactory outcome.

We have found in our study that the main reasons of poor functional outcome are nonunion of tuberosities, major rotator cuff injury, malposition of hemiarthroplasty prosthesis, non-compliance of rehabilitation program. The proper selection of patient (normal glenoid anatomy, no major ir repairable rotator cuff injury), proper positioning of hemiarthroplasty prosthesis, and better fixation of tuberosities and timely initiation of rehabilitation program gives best outcome of hemiarthroplasty shoulder if done for non-salvageable proximal humerus fracture in elderly.

Conclusion

Outcome of shoulder hemiarthroplasty when done for non-salvageable proximal humerus fractures are quite satisfactory especially in elderly. However one cannot do his/her full shoulder range of movement but can able to do the necessary amount of movement for day to day activity. Cemented hemiarthroplasty prosthesis will lead to more stable fixation, better stability and early mobilization of the patients. Hemiarthroplasty if done within 2 weeks gives better results as there will be less adhesion of soft tissue and soft tissue repair and reattachment can be done meticulously. Hemiarthroplasty outcome is better if proximal humerus fractures fracture not associated with major rotator cuff tear. Optimum results in terms of range of movements can be obtained if limited passive and active range movement started after 2 weeks postoperatively. Hemiarthroplasty functional outcome of 3 part fractures is better than 4 part fractures. Finally, we concluded that hemiarthroplasty shoulder done for non-salvageable proximal humeral fractures provide better stability and early mobilization, lesser stiffness and satisfactory range of movement.

Conflict of interest: None

Fund received for the study: None

References

1. Michal Laszczyca, Domain Kusz, Katowice, Grudnia, Polish shoulder club meeting, Shoulder hemiarthroplasty for treating proximal humerus fracture.
2. Eketerina Khmelritskaya, Lauren Lamont E, Samuel Taylor A, Dean Lorich G, David Dines M, Joshnua S. Dines. "Evaluation and management of proximal humerus fractures." *Advances in Orthopaedics Sports Medicine and Shoulder Service, Orthopaedics Trauma Service*, article ID861598 2012, 10. DOI:10.155/2012/861598
3. Hamdi Kaziz, Mohamed Amine Triki, Sofien Benzari, Wajdi Chermiti, Nadar Naouar, Mohamed Laziz Ben Ayeche. "Comparision of reverse shoulder arthroplasty and hemiarthroplasty for proximal humeral fractures; what about functional outcome? Reverse versus hemiarthroplasty in shoulder fractures. *Open Journal of Orthopaedics* 2019;9:112-122.
4. Per Wretenberg, Anders Ekelund "Acute hemiarthroplasty after proximal humerus fracture in old patients." *Acta Orthopaedica Scandinavica* 1997;68:2,121-123, DOI:10.3109-17453679709003992.
5. Simon S Jameson. "Total shoulder arthroplasty or hemiarthroplasty; A comparision6 of complication rates in the English National Health Service." 2012 *British Elbow and Shoulder Society, Shoulder and Elbow* 2013;5:56-59.
6. Clavert P, Gilbert M, Gerber A, Jip Warner. "Technique of accurate humoral length restoration for hemiarthroplasty of the shoulder." *Harverd Shoulder service, Department of Orthopaedic Surgery, Boston* 2014, MA02114
7. Panagopoulos A, Tsoumpas P, Evangelou K, Christas Georgiou, Triantafillopoulos I. "Lateprosthetic shoulder hemiarthroplasty after failed management of complex proximal humeral fractures." *Advances in orthopaedics* Article ID 403580, 2013, 9.
8. Amirfeyz R, Sarangi P. Shoulder hemiarthroplasty for fracture with a conservative rehabilitation regime. *Archives of orthopaedic and trauma surgery*

2008;128(9):985-8.

9. Hashiguchi H, Iwashita S, Ohkubo A, Takai S. The outcome of hemiarthroplasty for proximal humeral fractures is dependent on the status of the rotator cuff. *International Orthopaedics* 2015;39(6):1115-9.
10. Wylie JD, Beckmann JT, Granger E, Tashjian RZ.” Functional outcomes assessment in shoulder surgery.” *World journal of orthopedics* 2014;5(5):623.
11. Stanley Hoppenfeld, Piet de Boer, Richard Buckley, the text book of “Surgical exposure in Orthopaedics” *The Anatomic Approach*. 5th edition 2016;(1):4-20.
12. Louis U Bigliani, Evan L Flatow. *The text book of “Shoulder Arthroplasty”* 1st edition 2005;(1):12-35.