

E-ISSN: 2395-1958
P-ISSN: 2706-6630
IJOS 2021; 7(3): 236-241

www.orthopaper.com
Received: 11-05-2021
Accepted: 15-06-2021

Dr. Pradeep E
MS Ortho Associate Professor, Department of Orthopaedics, Chettinad Hospital and Research Institute, Kelambakkam, Tamil Nadu, India

Dr. Arun Kumar KV
MS Ortho, Associate Professor, Department of Orthopaedics, Chettinad Hospital and Research Institute, Kelambakkam, Tamil Nadu, India

Dr. Dinesh Kumar S
Second Year Postgraduate, Department of Orthopaedics, Chettinad Hospital and Research Institute, Kelambakkam, Tamil Nadu, India

Corresponding Author:
Dr. Arun Kumar KV
MS Ortho, Associate Professor, Department of Orthopaedics, Chettinad Hospital and Research Institute, Kelambakkam, Tamil Nadu, India

A study of management of nonunion of tibia by ilizarov method

Dr. Pradeep E, Dr. Arun Kumar KV and Dr. Dinesh Kumar S

DOI: https://doi.org/10.22271/ortho.2021.v7.i3d.2753

Abstract
Background: FDA Panel definition of nonunion ---- "Established when a minimum of 9 months has elapsed since injury and fracture shows no visible progressive signs of healing for 3 months". Tibial nonunion is most frequently met while considering the other long bone nonunion. This is mostly due to increase in the number of tibial fractures both close and open and in high-speed Road Traffic Accident (RTA) injuries. Failure of union may be due to an inappropriate mechanical environment or infection and in some cases, there is no apparent reason.
The Ilizarov method relies on distraction osteogenesis and is used not only for segmental defects, but also to complex malalignment with minimal surgery. Ilizarov technique has the additional advantage of efficient fixation, early ambulation, elimination of bone grafting with minimal complications. Ilizarov provides stability and at the same time allow micro movements with axial loading with neo vascularization due to distraction, giving an excellent biological environment for fracture healing.
Methods: Sample size of twenty (20) patients fulfilling the inclusion criteria admitted to Department of Orthopaedics, Chettinad Hospital and Research Centre, Kelambakkam. Study period from to November 2020.

Keywords: nonunion, Ilizarov, external fixator, distraction osteogenesis

1. Introduction
Tibial nonunion is most frequently met while considering the other long bone nonunion. This is mostly due to increase in the number of tibial fractures both close and open and in high-speed Road Traffic Accident (RTA) injuries. Nonunion in closed tibial fractures is either due to prolonged immobilization in long leg plaster or faulty technique adopted in Open Reduction and Internal Fixation. Even the best treatment of fractures some time results in, non-union often complicated by infection particularly after fractures of tibia. The basic cause often being high-energy injury, in some of these cases early amputation may be seen retrospectively to have been more appropriate. Failure of union may be due to an inappropriate mechanical environment or infection and in some cases, there is no apparent reason.
Whatever the cause, complicated non-union is a disaster for patient and may give severe clinical symptoms. Resistant nonunion may be treated by nailing or other form of internal fixation in which the main aim is provision of mechanical stability. Sometimes bone graft may be added and surgical disturbance of indolent fracture site, as in exchange nailing is itself regarded as biological stimulus. A high proportion of untitled fractures can be induced to heal by these means and malunion can be often being corrected at the same time. These methods are however limited in their ability to deal with infection, segmental loss of bone, or shortening, compromised soft tissue envelope and they involve extensive dissection around the fractures site for realignment of severe malunion.
More advanced techniques such as vascularized bone transfer and diffraction osteogenesis can be used to treat segmental defects, including those created by excision of infected bone. The Ilizarov method relies on distraction osteogenesis and is used not only for segmental defects, but also to complex malalignment with minimal surgery. Shortening and joint contracture can be corrected by gradual stretching of soft tissues. It can also restimulate bone in most quiescent nonunion, often by distraction alone.

Ilizarov technique has the additional advantage of efficient fixation, early ambulation, elimination of bone grafting with minimal complications. Ilizarov provides stability and at the same time allow micro movements with axial loading with neo vascularization due to distraction, giving an excellent biological environment for fracture healing.

Materials and Methods

This study was carried out in Department of Orthopaedics, Chettinad Hospital and Research Centre, Kelambakkam, Chennai. During the period of 12 months from December 2018 to December 2020.

Inclusion criteria

1. Infected nonunion tibia
2. Non-union with varying degree of limb shortening.
3. Non-union with varying degree of deformity at fracture site.

Exclusion criteria

1. Congenital pseudarthrosis of tibia

Metaphyseal nonunion.

Surgical Technique

After, institutional review and ethical clearance, all the patients who met the terms of inclusion criteria, were proposed for surgery after pre op assessment and informed and written consent.

Epidural anesthesia is used in all our cases. Depending on clinical assessment and radiographs, appropriate Ilizarov frame, assembled prior to surgery. To avoid expected wound closure problem, an oblique skin incision was used. Non-union site is debrided and ends freshened, until the punctate cortical bleeding in- seen. (Paprika sign). When nonunion is associated with infection, treatment was planned in two stages. As first stage, radical debridement of the nonunion site followed by fixation, and corticotomy performed in second stage. Tourniquet was used until debridement and freshening of the edges. And wires introduced after removal of tourniquet. Wires tensioned up to 110Kgs. Wires used De Bestiani technique for corticotomy in all our cases. We opened and freshened the edges of hypertrophic nonunion to exclude the possibility of pseudarthrosis. Whenever union is delayed, we augmented non — union site with Bone marrow injection or bone grafting.



Fig 1: Instruments and Implants

Fig 2: Basic Ilizarov Construct

Fig 3: Pre-Operative

Fig 4: Sequestrectomy

Fig 5: Sequestrum

Fig 6: Immediate Post Operative

Data Collection

Evaluation:

Final results of all patients were analyzed and evaluated according to criteria laid down by ASAMI for

1. Bone results
2. Functional results

Criteria for bone results

- **Excellent:** Union, no infection, deformity and leg length inequality of Q. 5cm
- **Good :** Union and any two of other three criteria
- **Fair :** Union and one of other criteria.
- **Poor :** Nonunion or union but none of the remaining three criteria required for excellent result.

Criteria for functional results

Based on five criteria

a. Noteworthy limb
b. Stiffness of either knee or the ankle with loss of > 15^0 of full extension of knee or 15^0 of dorsiflexion of ankle in comparison with normal.
c. Soft tissue sympathetic dystrophy
d. Pain
e. Pain that reduced activity or disturbed sleep and inactivity

(unemployment or inability to return to daily activities because of injury

Excellent	: If patient was active and none of the other criteria were applicable.
Good	: If the patient was active but three or four of the other criteria were applicable
Poor	: If the patient was inactive regardless of whether

other criteria were applicable

Results

Results were assessed according to classification by ASAMI.

In our study, we had excellent results in 80% cases, good in 15% and fair in 5% cases.

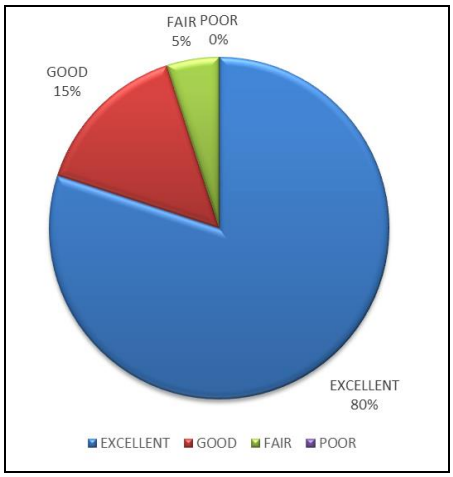

Fig 7: No of cases

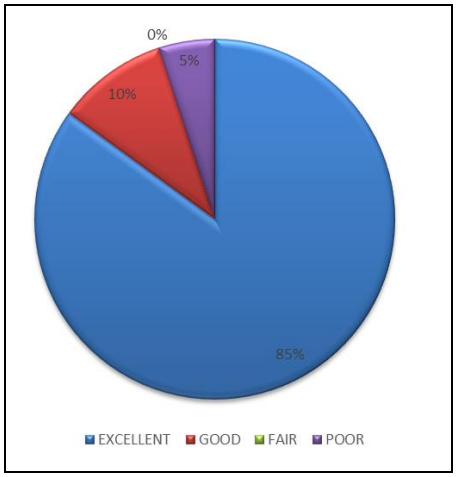

Fig 8: Functional Results

Table 1: Type of non-union of external fixation

Type of Nonunion	No. of cases	Percentage
Atrophic	2	10
Hypertrophic	2	10
Septic	16	80
Total	20	100

Table 2: Duration

Duration in months	No. of cases	Percentage
5-6	7	35
7-8	7	35
9-10	5	25
11-12	1	5
Total	20	100

Table 3: Limb Lenthening Achieved

Length cm	No. of cases	Percentage
4 to <6	16	80
>6 to 8	2	10
>8 to 10 cm	-	-
Total	18/20	90

Table 4: Associated Complications

Treatment		No. of cases
Problems	Pin tract infection	8
	Pain	6
	Edema	2
Obstacle	Delayed Union	3
	In growing toe nail	1
	Premature consolidation	1
	Wire cut through	1
True Complications	Equinus at ankle	1
	Axial deviations	2
	Knee stiffness	1
Total		27/20

Discussion

In the study period of two years, 20 patients with non-union shaft tibia were treated with Ilizarov technique and along with percutaneous Bone marrow injection and bone grafting in selected cases. Patient ranged from 15 years to 62 years and the mean age for 37.55 yrs. The incidence of nonunion in our study had a male predominance 19/20 (95%). In 75% of our cases, lower 1/3rd tibial bone fracture non union was involved. The cause of non-union in 90% of the cases were due to combined mechanical and biological failure of the fracture management. the remaining were due to mechanical instability due to hypertrophic nonunion, 80% of the patients were having septic nonunion. Mean duration of the external fixator was 7.4 months. 90% of the patients had defect after the debridement, mean defect was 5cm. Majority of the patients were treated with bifocal osteosynthesis. The average limb lengthening achieved was 4.6cm. The mean limb length discrepancy was 0.75cm. the duration of the follow up varied with patients, with a mean follow up of 7 months. Majority of the complications (8 cases) were pertaining to pin tract infection and delayed union were seen in 3 cases. 85% of the cases were having excellent function results.

IMAGES:

Clinical Photographs Case No.10

Fig 9: Coloured facets for distraction.

Fig 10: Weight bearing walking with apparatus.

Fig 11: After apparatus romoval.

Radiological Pictures

Fig 12: Pre-Operative

Fig 13: Immediate Post-Operative

Fig 14: Docking of fracture site.

Fig 15: After Radiological union.

Complication Picturfes

Fig 16: Pin tract infection.

Fig 17: Soft tissue interposition.

Fig 18: Ankle equinus and leg

Fig 19: Knee Stiffness

Conclusion

Tibial nonunion continues to be the most commonly encountered nonunion by orthopedic surgeons. In the present light of advances in understanding the path physiology of nonunion, better classification methods and newer modalities of treatment, the older conventional methods are losing their

validity.

In the light of these results, we conclude that Ilizarov technique, in addition to bony union in management in tibial nonunion fracture with bone loss defect, also corrects deformities and limb length deficiencies. Success of the technique includes meticulous pre op planning and selection of cases and focus on cardinal principles of ilizarov.

References

1. Egol KA, Zuckermann JD. Handbook of Fracture. LWW. 4 th edition Handbook of Fracture 2013, 477.
2. Standring S, The Anatomical Basics of Clinical Practice, Grays Anatomy, 40th edition. New Delhi, Elsevier 2014, 1394-444.
3. Campbell's Operative Orthopaedics, 10th ed, 3, 3032.
4. Lister J. A new operation for fracture of Patella. Br Med J 1877;2:850.
5. Cameron HC. Transverse fracture of patella, Glasgow Med J 1878;10:289-94.
6. Benjamin J, Bried J, Dohm M, McMurtry M. Biomechanical evaluation of various forms of fixation of transverse patellar fractures. J Orthop Trauma 1987, 219-222.
7. Levack B, Flannagan JP, Hobbs S. Results of surgical treatment of patellar fractures. JBJS 1985;67B:416-419.
8. Burvant JG, Thomas KA, Alexander R *et al*. Evaluation of methods of internal fixation of transverse patella fractures: a biomechanical study. J Orthop Trauma 1994; 8:147-153.
9. Carpenter JE, Kasman RA, Patel N. Biomechanical evaluation of current patella fracture fixation techniques. J Orthop Trauma 1997;11:351-356.