

E-ISSN: 2395-1958
P-ISSN: 2706-6630
IJOS 2021; 7(3): 194-197

www.orthopaper.com
Received: 25-05-2021
Accepted: 27-06-2021

Dr. Hemjit Das
MS Orthopaedics, Assistant Professor at Assam Medical College and Hospital, Dibrugarh, Assam, India

Dr. Harikrishnan NG
3RD Year PGT MS Orthopaedics at AMCH, Dibrugarh, Assam, India

Dr. Siddharth Kumar
MS, DNB Orthopaedics, Assam Medical College and Hospital, Dibrugarh, Assam, India

Corresponding Author:
Dr. Harikrishnan NG
3RD Year PGT MS Orthopaedics at AMCH, Dibrugarh, Assam, India

Correction of long standing severely flexed ankylosed knee deformity using Ilizarov's technique: A case report

Dr. Hemjit Das, Dr. Harikrishnan NG and Dr. Siddharth Kumar

DOI: https://doi.org/10.22271/ortho.2021.v7.i3c.2747

Abstract
A 25 years old female with limp and a gradually progressive flexion deformity at the knee, being able to walk only on crutches, following septic arthritis of the knee joint during childhood had a fixed flexion deformity of 70 degrees at the knee with a limb shortening of 7cm with evidence of multiple healed previous sinuses and secondary deformities of spine, pelvis and ankle. The soft tissue over the posterior aspect of knee joint was scarred with a degenerated and ankylosed knee joint. A supracondylar anteriorly based closing wedge osteotomy of the femur at the CORA was done to correct the deformity gradually using a long spanning Ilizarov's ring external fixator with corticotomy and sequential lengthening done later. At final follow up at 12 months after completion of treatment apart from pin tract infections the patient had no other complications like residual or recurrence of deformity, delayed consolidation, non-union, refracture, peroneal nerve injury or hardware failure. Also with satisfactory hip and ankle range of motion and a limb that was pain free and in functional position unaided ambulation was possible. Hence, wedge resection and gradual correction with Ilizarov's technique can achieve desired results without causing any neurovascular complications or soft tissue procedure requirement in a chronic severely flexed ankylosed knee.

Keywords: longstanding fixed knee flexion deformity, ankylosed knee, supracondylar femoral wedge resection osteotomy, Ilizarov correction

Introduction
Progressive uniplanar deformity of the knee can be a sequelae of inappropriately managed septic arthritis of knee joint. Such a joint destroying pathology may lead to extremely disabling deformities like flexion contractures, ankylosis, limb length discrepancies and secondary deformities elsewhere. The aim of our treatment in such a condition is to correct the deformity and regain the function, as much as possible. Corrective strategies, either acute or gradual, should take care of the associated contracted soft tissues situated posteriorly along with coexistent infection and painful ankylosis. Strategies such as serial manipulation and casting and soft tissue procedures [1] may not be successful in severe deformities [1-3]. Arthroplasty with or without skeletal traction has also been used to deal with bony ankylosis with flexion deformities but carries the risk of recurrence of infection [4, 5]. Distal femoral wedge resection osteotomy with gradual correction using Ilizarov's external ring fixator can address all these problems with mobilization of the patient at the same time [6-8].

Case report
Our patient, a 25 years old female presented to us in Orthopaedics OPD of Assam medical college and Hospital, Dibrugarh with pain and a flexion deformity of the knee for 12 years. She had developed septic arthritis of the knee joint at the age of 13 years. Her condition was then managed by multiple incision and drainage of the joint at a local centre. The patient did well initially but by one year after the initial episode she developed recurrent episodes of pain, swelling and on and off discharging sinuses from around the knee joint. She also developed a limp and a gradually progressive flexion deformity at the knee.
On presentation at our centre she could only walk with two crutches and had a fixed flexion deformity of 70 degrees at the knee with a limb shortening of 7cm (Figure 1).

She also had a flexion deformity of 10 degrees at the hip and an equinus deformity at the ankle. These deformities were probably because of the habit of placing a pillow below the knee as a method of resting the joint. She also had a compensatory lordosis of the lumbar spine secondary to a short limb and pelvic tilt. There was evidence of multiple healed previous sinuses around the knee though there was no actively discharging sinus at presentation. The skin and soft tissues over the posterior aspect of knee joint were scarred. Xrays of the involved joint revealed a degenerated and bony ankylosed joint making the deformity fixed (Figure 2).

We decided that an osteotomy and a gradual correction using Ilizarov's method for her single plane deformity would be the most ideal method to manage her condition which would also prevent tension at the posterior soft tissue structures. She underwent a supracondylar anteriorly based wedge resection osteotomy of the femur at the CORA (centre of rotation and angulation). The CORA was determined preoperatively using full length orthogonal Xray views of both the lower limbs. The site of osteotomy was taken as close to the CORA possible in the metaphyseal region. The Ilizarov frame that was constructed had a femoral part consisting of an Italian arch with 5mm Schanz pins passed at the level of lesser trochanter and a distal ring fixed with Schanz pin and 1.8mm Ilizarov wire placed about 2.5 cm from the osteotomy site. The tibial part consisted of 2 rings fixed with wires, one at the proximal tibial metaphysis and the other at distal tibial metaphysis. Both parts were perpendicular to respective anatomical axes. Two hinges were placed between the two frame components [9], one medial and one lateral at the CORA so that no translation of the fragments takes place. The distractor was placed posteriorly, midway between the hinges (Figure 3). Gradual correction of angular deformity at the rate of 3 degree per day at the osteotomy site was initiated seven days after osteotomy. The rate of distraction at the distractor was estimated using the *law of similar triangles*. We achieved the correction in 1 month (Figure 4).

The next problem addressed was limb shortening. The hinges were replaced by solid threaded rods. Corticotomy was done at proximal femoral metaphysis through the normal uninfected bone and an additional ring was incorporated for greater stability. Lengthening was initiated at 1mm per day and osteotomy site was compressed simultaneously at ¼ mm every alternate day (Figure 5 A,B,C). The corticotomy site healed by 3 months. The patient was encouraged to bear weight throughout the duration. Once length was attained and satisfactory regenerate had formed by end of 7 months, the fixator was removed and the limb was put in a protective POP cast for 6 weeks. The equinus deformity at the ankle was addressed subsequently by multiple level Z tenotomy and an Ilizarov foot frame application for gradual correction. Lumbar scoliosis gradually improved during the course of treatment. At final evaluation done at 12 months after completion of treatment the hip had flexion ROM of 0 to 90 degrees with satisfactory internal, external rotation, extension, abduction and adduction. The ankle had a dorsiflexion of 10 degrees and plantar flexion of 30 degrees. The patient had attained the ability to walk unaided without any pain with the Xray showing a well remodelled bone (Figure 6).

Pin tract infections (grade 1 and 2, Paley classification) were the only complications seen. It was managed with oral antibiotics and dressings [10].

Discussion

Long standing progressive uniplanar deformity of the knee following inappropriately managed septic arthritis of knee joint with extremely disabling deformities like flexion contracture, ankylosis and limb length discrepancy is a difficult condition to manage with very limited options. Flexion deformity of the knee may be tolerated up to a certain degree but severe degrees of fixed deformities lead to disabling shortening of the limb along with secondary deformities at the ankle, hip and spine. These secondary changes are initially reversible and correctable with correction of primary deformity but later may become permanent further exacerbating the disability and ambulatory disadvantage [7]. Flexion contractures have been managed by physiotherapy, corrective plaster casts, soft tissue releases and corrective osteotomies with variable success rates [6]. While attempting correction, the coexistent infection, painful ankylosis and the contracted soft tissues, especially the neurovascular bundle situated posteriorly which may get tensioned during correction also needs to be tackled.

Our case presented such a scenario along with secondary deformities at ankle, hip and spine, and due to the longstanding nature of the disease process the limb was already fixed into a position not compatible with unsupported ambulation. Only a few studies (Demir *et al* [7], Damsin *et al* [6]) have dealt in detail with management of such a condition. Osteotomy and gradual correction using Ilizarov's external ring fixator can tackle all these problems while mobilising the patient at the same time. The aim of treatment in such a case was to correct the primary deformity and provide bipedal locomotion with a limb in a functional position [6] before other deformities become permanent, even though the joint function might not be regained. Also the amount and rate of deformity correction in such a case should not produce any neurovascular complications especially traction injury to nerves. This was avoided by an anterior based wedge osteotomy at distal femur and gradual closing of the osteotomy using Ilizarov's technique. This technique allowed gradual lengthening of the soft tissues and the vital neurovascular structures situated posteriorly. The correction was stopped and restarted at a slower rate if the patient complained of paraesthesia over the limb distally. Thirdly, severe contracture of surrounding soft tissues and long lever arms, due to long bones like femur and tibia, result in high moment of forces which resist correction and lengthening and also threaten frame stability. To avoid these complications the fixator's proximal and distal components were made as long spanning as possible, extending upto the trochanteric area in the femur and up to distal tibia. Finally another advantage of our technique was that it obviated the need for any extensive soft tissue reconstruction procedures such as tendon transfers.

Complications we encountered were pin tract infections managed non operatively. Direct injury to neurovascular structures was prevented by careful placement of pins and wires. The secondary deformities disappeared by 3 months post correction of knee deformity and did not recur during 12 month follow up. We did not encounter any delayed consolidation, non-union, refracture, peroneal nerve injury or hardware failure.

Fig 1: Clinical appearance of deformity

Fig 2: AP and lateral radiograph of the deformity showing COR A

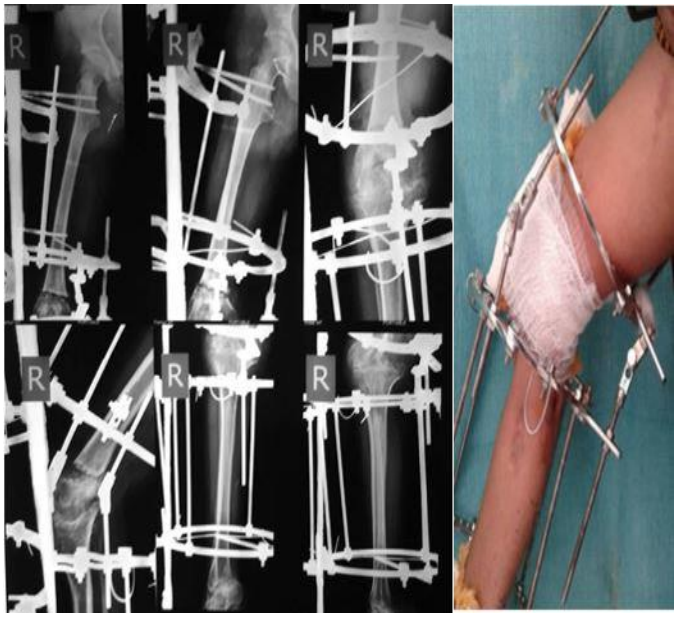

Fig 3: Radiographs of thigh, knee and ankle showing distal femoral osteotomy and hinge placement with clinical picture showing the llizarov frame construct and hinge position.

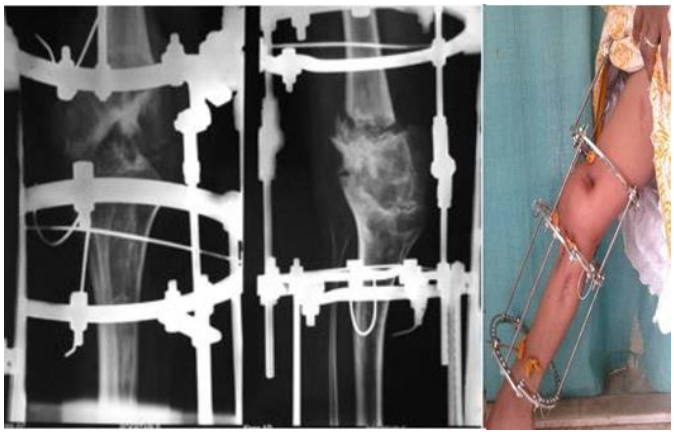

Fig 4: Radiograph and clinical picture after correction of flexion deformity.

Fig 5A: Radiograph after 10 days of distraction **Fig 5B:** Radiograph after 2 months of distraction and healing osteotomy site **Fig 5C:** Radiograph showing good regenerate at the end of 6 months

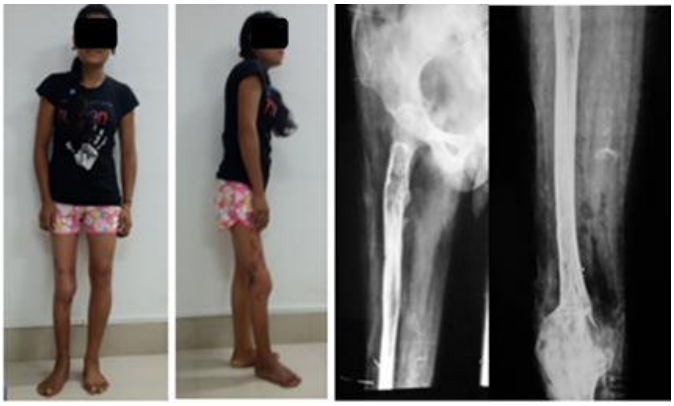

Fig 6: Clinical and radiograph picture at final evaluation

Conclusion

Correction of longstanding fixed flexion deformity of the knee using an anterior wedge osteotomy and gradual correction with Ilizarov's technique can achieve desired results without causing any traction injury to neurovascular structures. However, frame stability should be kept in mind and appropriate spanning of the fixator should be done. Such a technique may also do away with the need of any soft tissue procedure.

Abbreviations

CORA - centre of rotation and angulation

References

1. Pathania VP, Sharma AK, Joshi GR, John JT. Correction of Lower Limb Deformities Using Ilizarov's technique. Medical journal armed forces India. 2005;61(4):322-25.
2. Parekh PK. Flexion contractures of the knee following poliomyelitis. Int Orthop 1983;7(3):165-172.

3. Zimmerman MH, Smith CF, Oppenheim WL. Supracondylar femoral extension osteotomies in the treatment of fixed flexion deformity of the knee. Clin Orthop Relat Res. 1982;(171):87-93.
4. Kim YH, Cho SH, Kim JS. Total knee arthroplasty in bony ankylosis in gross flexion. Journal of Bone and Joint surgery (Br) 1999;81(2):296-300.
5. Camanho GL. Total arthroplasty in ankylosed knees: a case series. Clinics (Sao Paulo). 2009;64(3):183-187.
6. Damsin JP, Ghanem I. Treatment of severe flexion deformity of the knee in children and adoloscents using the Ilizarov technique. The journal of bone and joint surgery 1996;78-B(1).
7. Demir B, Oke R, Ozturk K, Aydin K, Gursu S, Sahin V. Correction of a major flexion deformity developed after knee arthrodesis in child age a case report. Acta Orthop. Belg 2008;74:424-428.
8. Herzenberg JE, Davis JR, Paley D, Bhave A. Mechanical Distraction for Treatment of Severe Knee Flexion Contractures. Clinical Orthopaedics & Related Research. 1994;(301):80-8.
9. Ullmann Y, Fodor L, Soudry M, Lerner A. The Ilizarov Technique in joint contractures and dislocations. Acta Orthop. Belg 2007;73(1):77-82.
10. Paley D. Problems, obstacles, and complications of limb lengthening by the Ilizarov technique. Clinical Orthopaedics & Related Research 1990;(250):81-104.