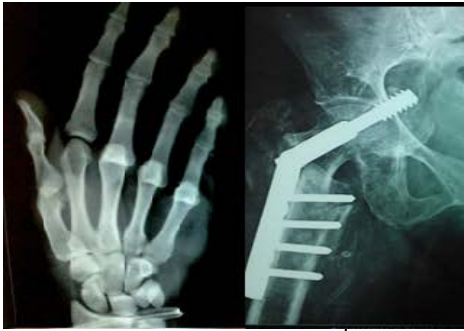



# International Journal of Orthopaedics Sciences

E-ISSN: 2395-1958  
P-ISSN: 2706-6630  
IJOS 2021; 7(3): 92-95  
© 2021 IJOS  
www.orthopaper.com  
Received: 10-04-2021  
Accepted: 13-05-2021

**Dr. Miodrag Vranjes**  
Teaching Assistant At  
University of Novi Sad, Medical  
Faculty, Clinic For Orthopaedic  
Surgery And Traumatology,  
Clinical Centre of Vojvodina,  
Hajduk Veljkova 1, Novi Sad,  
Serbia

**Dr. Mile Bjelobrk**  
University of Novi Sad, Medical  
faculty, Clinic for orthopaedic  
surgery and traumatology,  
Clinical centre of Vojvodina,  
Novi Sad, Serbia

**Dr. Vladimir Losonci**  
University of Novi Sad, Medical  
Faculty, Novi Sad, Serbia

**Dr. Filip Pajcic**  
University of Novi Sad, Medical  
faculty, Clinic For Neurosurgery,  
Clinical Centre Of Vojvodina,  
Novi Sad, Serbia

**Corresponding Author:**  
**Dr. Miodrag Vranjes**  
Teaching assistant at  
University of Novi Sad, Medical  
faculty. Clinic for orthopaedic  
surgery and traumatology,  
Clinical centre of Vojvodina,  
Hajduk Veljkova 1, Novi Sad,  
Serbia

## Metacarpal canal occlusion: A rare contraindication in intramedullary pinning

**Dr. Miodrag Vranjes, Dr. Mile Bjelobrk, Dr. Vladimir Losonci and Dr. Filip Pajcic**

DOI: <https://doi.org/10.22271/ortho.2021.v7.i3b.2731>

### Abstract

**Introduction:** Intramedullary fixation with K-wires is one well-known surgical intervention for the management of metacarpal bone fractures. There are numerous papers dealing with metacarpal canal measurements but there is no research on anatomical occlusion. We used postero-anterior X-ray images to measure the frequency and the bone affected with metacarpal canal occlusion.

**Materials and Methods:** A total of 1000 subjects (564 male, 436 female) were included. The frequency of intramedullary canal occlusion from the second to fifth metacarpal where evaluated by age and gender.

**Results:** Subject age ranged from 18 to 88 years (male  $28.8 \pm 6.7$  years, female  $32.6 \pm 7.3$  years). Intramedullary canal occlusion was observed in 24 metacarpal bones of 21 subject. The second, third, and fourth intramedullary canal was occluded in 8, 7 and 9 metacarpal bones, respectively.

**Conclusion:** MC intramedullary canal occlusion is a anatomical variation that is an absolute contraindication for intramedullary stabilization with K-wires. We recommend paying greater attention to these detail in specific age groups.

**Keywords:** intramedullary fixation, intramedullary pinning, K- wire, metacarpal, X-rays

### 1. Introduction

One third of all fractures of the hand are metacarpal (MC) fractures <sup>[1]</sup>. The treatment goal is early restoration of function. In surgery, the goal is to achieve stable reduction and retention so that early functional treatment can begin <sup>[2]</sup>. Fixation techniques involve the use of K-wires, intramedullary nails, circlage wires, plating, lag screws, tension band wires, and external fixators <sup>[3, 4]</sup>. Intramedullary fixation with K-wires is one well-known surgical intervention for the management of MC bone fractures. A large number of papers have been published on the indications and techniques for performing the said procedure <sup>[5-7]</sup>. These papers mention real and potential contraindications. In the literature available to us, only in the works of Balfour <sup>[8]</sup> and Mirza *et al.* <sup>[9]</sup> is the physiological occlusion of the intramedullary canal mentioned as a contraindication. There are numerous papers <sup>[10-12]</sup> dealing with MC canal measurements but no research on anatomical occlusion in terms of K-wire fixation. The aim of this study is to measure the frequency and bone affected with MC intramedullary canal occlusion by using X-ray imaging and, moreover, to establish an age and gender representation.

### Material and methods

A retrospective analysis was performed analyzing hand X-ray images from the PACS (Carestream Vue Motion version 11.4.1.0) database of the Clinical Centre of Vojvodina, a tertiary type facility in in the southern Bačka district of Serbia.

A total of 1122 digital hand X-rays were analyzed between January the 1st, 2018 till November the 10th, 2018. The X-ray images originate from patients who admitted for trauma of the hand of any nature during the mentioned period. Good quality posteroanterior (PA) X-ray images, with the wrist in neutral flexion and deviation, were analyzed. X-ray images who were not adequately technically performed or had an unclear endosteal margin were excluded from the study. The number of excluded X-ray images was 122. The intramedullary canal of the second, third, fourth and fifth MC bone was observed. The thumb MC bone was not measured because of anatomically significantly greater diaphysis width.

Patients younger than 18 years were not included in the study. The MC canal occlusion was determined by two independent study members, one board certified orthopedic surgeon and one senior resident. They were educated on radiographic analysis and reviewed the X-rays one month apart. All X-ray images were acquired by a Shimadzu sonialvision safire (Japan) under the standardised conditions: filter with 1.0 mm thickness related to aluminium, tube average voltage 44 kV, exposure level 5.6 mAs, film focus distance 100 cm. The digital images were analyzed using the Lenovo ThinkVision monitor at a resolution of 1920x1200 pixels.

Additional baseline characteristics were collected: gender, age at imaging, and date of examination. Information regarding the type of trauma necessitating X-ray diagnostics was not recorded.

### Ethical approval

This study was authorized by the institutional ethical committee (approval no. 00-4; January 16, 2020). Required consent was waived since the analysis was considered a non-human subject study.

### Statistical analysis

The Statistical Package for the Social Sciences (ver. 25; IBM Corporation, Armonk, NY, USA). Results were statistically significant at  $p < 0.05$ . Descriptive statistics and Fisher's exact test as correction for  $\chi^2$  test was used for determine whether there was a risk group due to sample size in which MC bone occlusion occurred.

### Results

There were 1000 hand X-rays analyzed, of which were 564 male and 436 female, with an average age of 41.3 years (range 18-88 years). MC intramedullary canal occlusion was found on 24 bones and the number of subjects with this anatomical variation was 21 (2.1%) (Figure 1, 2 and 3). Occlusion of only one bone was found in 18 (1.8%) and in two adjacent bones in three (0.3%) of the analyzed subjects. There was no occlusion in more than two bones.

The youngest subject with MC canal occlusion was 19 years and the oldest 43 years. Female subjects had an average of  $32.6 \pm 7.3$  years and male  $28.8 \pm 6.7$  years. In the group of 21 subjects with MC canal occlusion 13 (61.9%) was female and 8 (38.1%) male (Table 1).

Isolated occlusion of the second MC bone was seen in 6 (28.57%) subjects, of the third in 4 (19.04%) subjects and of the fourth in 8 (38.09%) subjects. There was no MC occlusion of the fifth bone. Combined occlusion of the second and third MC bone was seen in two (9.52%) and of the third and fourth in only one (4.06%) subject (Figure 4). The fourth MC bone was the most occluded and recorded on 9 subjects.

We divided the 21 subject into three groups (Figure 5). The first group was <20 years of age, the second group was 21-35 years and the third group was 36-50 years. The first group consisted of 2 (9.5%), the second of 13 (61.9%) and the third of 6 (28.6%) subjects.

The youngest age group had only occlusion of the fourth MC bone. The 21-35 year age group consisted of 15 occlusions, where the second MC was occluded in 6 (40%) subjects, occlusion of the third MC was seen in also 6 (40%) subjects and occlusion of the fourth was seen in 3 (20%) subjects. The third year age group consisted of 7 occlusions. In this group, the second MC was occluded in 2 (28.5%) subjects and the third MC was occluded in one (14.2%). Occlusion of the fourth MC bone was seen in 4 (57.1%) subjects (Figure 4).

The calculated Fisher's exact test values are  $\chi^2 (2) = 0.532$ ,  $p > 0.05$ . There is no statistically significant difference in the frequency of subjects. However, when the  $\chi^2$  tests is performed on individual variables, we get the following case: a statistically significant difference occurs in the age groups of the subjects, the value is  $\chi^2 (2) = 8.857$ ,  $p < 0.01$ . The 21-35 age group occurs more in the sample. There is no statistically significant gender difference, the value of  $\chi^2$  test is  $\chi^2 (1) = 1.19$ ,  $p > 0.05$ . A profile of a patient who is more likely to have occlusion of MC bones does not exist, but therefore there is an age group at risk, that is, the 21-35 year group.

### Discussion

Understanding the anatomy of MC is essential for surgical fixation and reconstruction [13]. The results of this study provide an overview of how often we can encounter occlusion of the MC intramedullary canal. To the best of our knowledge, this is the only study in literature to examine the MC canal occlusion of second through fifth MC using X-ray imaging.

Boonyasirikool and Niempoog stated that extreme small (less than 3 mm) medullary canal was found in index, middle, ring and small MC [14]. Their study consisted of 50 cadavers, which is rather small number with the possibility that they did not encounter complete occlusion at all. Their results show the average medullary canal width from the second through fifth MC was 3.61 mm, 3.47 mm, 3.02 mm, and 4.15 mm respectively. Similarly, our results show no occlusion of the fifth, which is the widest and mostly occlusion in the fourth, which is the narrowest intramedullary canal.

One other study has reported that special attention needs to be paid to the width of the medullary canal, which in some cases, can be narrow and prevent the passage of 1.2-mm or 1.6-mm implants [9]. No further explanation is given in this surgical outcome study.

Sephen *et al.* [15] first measured MC with in a cadaveric study of 145 MC bones. They did not measure the intramedullary canal diameter or mention occlusion. These authors measured, in the same year [12], the medullary canal width from the second to fifth MC using X-ray imaging and discovered the smallest diameter ( $3.02 \pm 0.08$ mm) in the fourth MC bone. The results are similar to our findings with the highest percent of MC occlusion in the fourth MC bone. Sephen *et al.* did not mention occlusion, only average canal width measures of their 572 MC study. Furthermore, they discovered the greatest width in the fifth MC ( $4.15 \pm 0.08$ mm). Neither did we encounter occlusion of these MC bone.

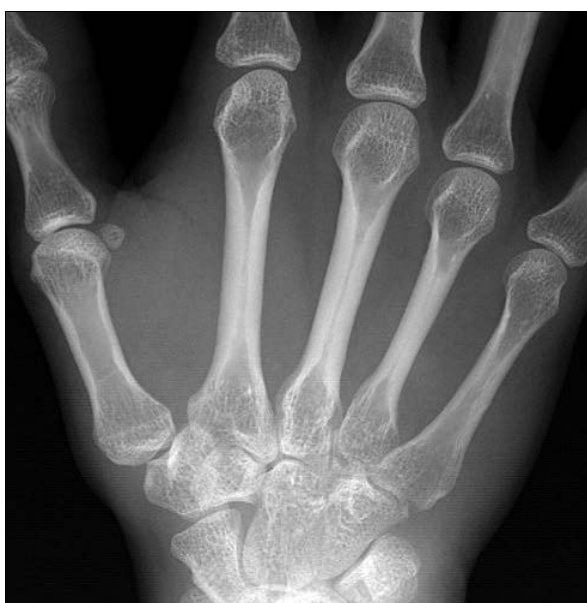Most of our analysed subjects (61.9%) were in the 21-35 year age group. Furthermore, in this group, mostly the fourth MC canal occlusion was seen (66.7%). In our opinion there are two reasons for this. Firstly, the fourth MC bone is the narrowest MC bone as stated by previous authors [12, 16]. And secondly, this age group has the strongest cortices, meaning, their MC index is high [10, 11]. This would also explain why no MC occlusion was seen in subjects older than 43 years.

There are several limitation of the study. Firstly, being the nature of a retrospective study. However, we do not believe a prospective study that evaluates anatomical differences would yield different results. The study did not include subjects younger than 18 years and the 18-20 age group is rather small. Furthermore, the number of 21 subjects in whole of the study is not big enough for quality statistics. As this paper is concentrating on a particular surgical contraindication there was no measurement of every MC canal width, these morphology measurements would bring more accurate data.

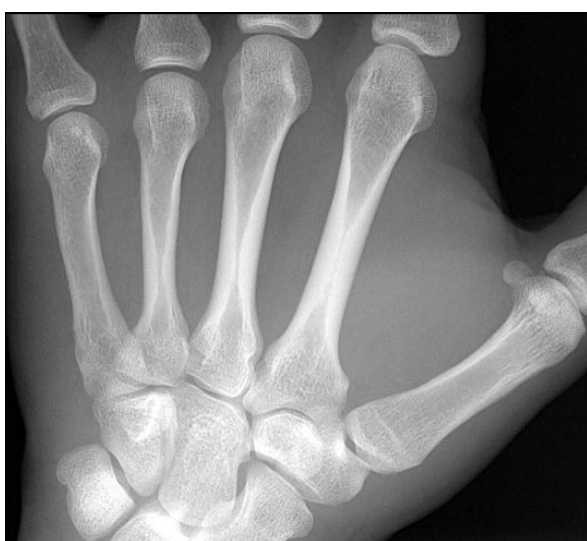Information regarding the type of profession or sport was not obtained. Taking into account that more female subjects had MC canal occlusion, this information would bring a better insight or even explain female predominance. Contrary to the belief that strong cortices are rather in male and manual workers. Another limitation is that examiner consistency was not assessed. However, our observations are similar to MC studies reported in literature, we believe inaccurate measurement of our observers was minimal. The observers did not collect race differences. We don't believe this measurement would be useful giving the fact of a society that comprises only of caucasians.

**Table 1:** Age and gender distribution of the study group

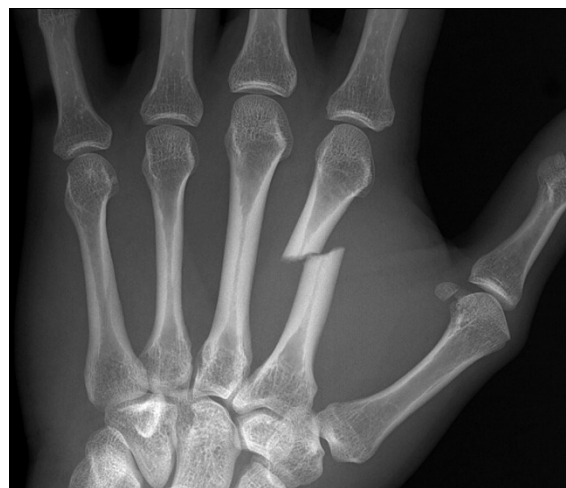Gender	Age groups			Total
	18-21 age	21-35 age	36-50 age	
Male	1 (50%)	5 (38.4%)	2 (33.3%)	8 (38.1%)
Female	1 (50%)	8 (61.5%)	4 (66.6%)	13 (61.9%)
Total	2 (9.5%)	13 (61.9%)	6 (28.5%)	21 (100%)



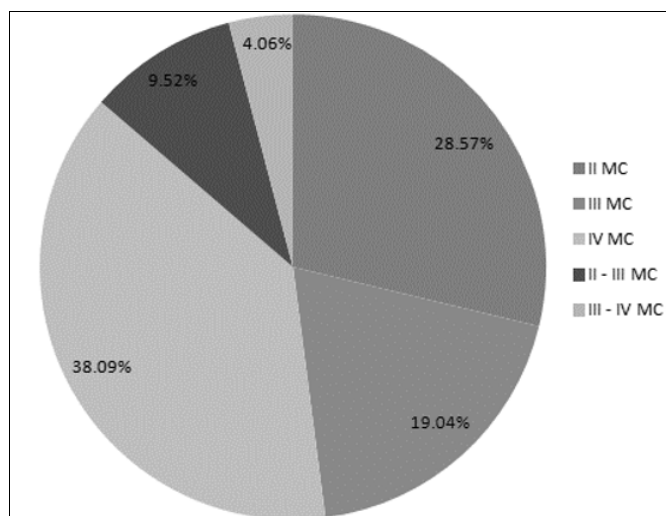
**Fig 1:** PA hand X-ray showing a fourth MC canal occlusion



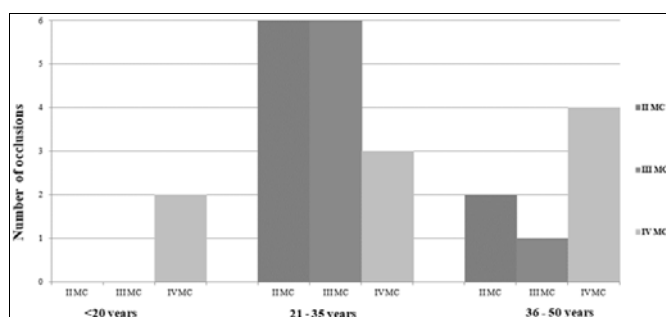
**Fig 2:** PA hand X-ray showing a second MC canal occlusion



**Fig 3:** PA hand X-ray showing a second MC canal occlusion and diaphyseal fracture



**Fig 4:** Percentage of MC occlusions. The fourth MC was the most occluded



**Fig 5:** Number of occlusions distributed in study groups. Most of the analysed subjects were in the 21-35 year group

**Conclusions**

The frequency of MC canal occlusion is 2.1%, two MC canal occlusions in one subjects is extremely rare. Considering our sample, the fourth MC bone is affected at most. We have not seen occlusion of the fifth MC bone or occlusion in older than 43 years. Occlusion is mostly seen in the 21-35 years age bracket. Also, MC canal occlusion is more often in female. Intramedullary canal occlusion is an anatomical variation that

is an absolute contraindication for intramedullary stabilization with K-wires. We recommend paying greater attention to these detail in order not to expose the patient and surgeon to prolonged intervention and additional soft tissue dissection by modifying surgery.

**Author Conflict of Interest:** None to declare

**Financial support:** None to declare

**Conflict of Interest:** The authors declare that they have no conflict of interest.

**Funding:** There is no funding source.

## References

1. Van Onselen EBH, Karim RB, Hage JJ, Ritt MJPF. Prevalence and Distribution of Hand Fractures. *J Hand Surg* 2003;28(5):491-5.
2. Geissler WB. Operative Fixation of Metacarpal and Phalangeal Fractures in Athletes. *Hand Clin* 2009;25(3):409-21.
3. Black D, Mann RJ, Constine R, Daniels AU. Comparison of internal fixation techniques in metacarpal fractures. *J Hand Surg* 1985;10(4):466-72.
4. Kawamura K, Chung KC. Fixation choices for closed simple unstable oblique phalangeal and metacarpal fractures. *Hand Clin* 2006;22(3):287-95.
5. Greeven APA, Bezstarosti S, Krijnen P, Schipper IB. Open reduction and internal fixation versus percutaneous transverse Kirschner wire fixation for single, closed second to fifth metacarpal shaft fractures: A systematic review. *Eur J Trauma Emerg Surg Off Publ Eur Trauma Soc* 2016;42(2):169-75.
6. Rocchi L, Merendi G, Mingarelli L, Fanfani F. Antegrade Percutaneous Intramedullary Fixation Technique for Metacarpal Fractures: Prospective Study on 150 Cases. *Tech Hand Up Extrem Surg* 2018;22(3):104-9.
7. Wong VW, Higgins JP. Evidence-Based Medicine: Management of Metacarpal Fractures. *Plast Reconstr Surg* 2017;140(1):140e-51e.
8. Balfour GW. Minimally Invasive Intramedullary Rod Fixation of Multiple Metacarpal Shaft Fractures: *Tech Hand Up Extrem Surg* 2008;12(1):43-5.
9. Mirza A, Mirza J, Healy C, Mathew V, Lee B. Radiographic and Clinical Assessment of Intramedullary Nail Fixation for the Treatment of Unstable Metacarpal Fractures. *HAND* 2018;13(2):184-9.
10. Nielsen SP. The Metacarpal Index Revisited. *J Clin Densitom* 2001;4(3):199-207.
11. Rico H, Revilla M, Fraile E, Martin FJ, Cardenas JL *et al.* Metacarpal cortical thickness by computed radiography in osteoporosis. *Bone* 1994;15(3):303-6.
12. Saphien A, Bethel CF, Doyle CM, Gulick D, Smith CJ *et al.* Morphometric analysis of the second through fifth metacarpal through posteroanterior X-Rays. *Clin Anat* 2019;ca.23528. <https://doi.org/10.1002/ca.23528>
13. Rivlin M, Kim N, Lutsky KF, Beredjikian PK. Measurement of the radiographic anatomy of the small and ring metacarpals using computerized tomographic scans. *HAND* 2015;10(4):756-61.
14. Boonyasirikool C, Niempoog S. Locked intramedullary nail: metacarpal geometry study in adults. *J Med Assoc Thai Chotmaihet Thangphaet* 2014;97(8):S194-198.
15. Saphien A, Bethel CF, Gulick D, Nairn C, Ourn F *et al.*

- Inter-relationships of Metacarpals 1 to 5, Regarding Their Length, Metaphyseal Midshaft Width, Articular Surface Area of Head and Base, Age, and Sex: A Cadaveric Study. *HAND* 2019;155894471988002. <https://doi.org/10.1177/1558944719880026>
16. Lazar G, Schuller-Ellis FP. Intramedullary structure of human metacarpals. *J Hand Surg* 1980;5(5):477-81.