



E-ISSN: 2395-1958  
P-ISSN: 2706-6630  
IJOS 2021; 7(3): 96-98  
© 2021 IJOS  
[www.orthopaper.com](http://www.orthopaper.com)  
Received: 14-04-2021  
Accepted: 20-06-2021

**Dr. Sagar V Kakatkar**  
Assistant Professor, Department  
of Orthopaedics, DVPMC,  
Nashik, Maharashtra, India

**Dr. Aditya P Apte**  
Senior Registrar, Department of  
Orthopaedics, Rajawadi  
Hospital, Mumbai, Maharashtra,  
India

**Dr. Akshaj Sharma**  
Resident, Department of  
Orthopaedics, DVPMC, Nashik,  
Maharashtra, India

**Corresponding Author:**  
**Dr. Aditya P Apte**  
Senior Registrar, Department of  
Orthopaedics, Rajawadi  
Hospital, Mumbai, Maharashtra,  
India

## Functional outcome of medial meniscus root repair in medial compartment osteoarthritic knee and it's correlation with preexisting comorbidities

**Dr. Sagar V Kakatkar, Dr. Aditya P Apte and Dr. Akshaj Sharma**

**DOI:** <https://doi.org/10.22271/ortho.2021.v7.i3b.2732>

### Abstract

**Objective:** The knee joint is one of the most commonly affected joints of the body and this can be attributed to its exposure to external forces and the high functional demands placed on the joint. Meniscal root tears have conventionally been treated with meniscectomy and in this study we evaluate the effects of repairing the torn posterior medial meniscal root. We also study the effects of age and body mass index on the postoperative outcome of the patient.

**Methods:** 35 patients with posterior horn medial meniscus root tear were operated with root repair with either a fibre wire/ fibre tape or their pre and post-operative tegner lysholm scores were evaluated.

**Results and Conclusions:** The evaluation was suggestive that medial meniscus root repair improved outcomes. Additionally, a relationship was established between the body mass index and patient age with that of the post-operative function.

**Keywords:** Knee joint, meniscus root, repair, body mass index

### Introduction

The knee joint is one of the most commonly affected joints of the body and this can be attributed to its exposure to external forces and the high functional demands placed on the joint. Medial meniscus tears have conventionally been treated with meniscectomy. This leads to loss of cushioning effect of the meniscus and rapid progression of arthritis. In this study, we evaluate the effects of repair of medial meniscus root and its impact on progression of arthritis.

### Methodology

35 patients with clinical and radiological evidence of medial meniscus root tear were evaluated pre and post operatively on the basis of the following parameters-

- Age (Figure.2)
- Sex
- Time interval between onset of pain and surgery
- Body mass index (Figure. 3)
- Co-morbidities
- Pre-operative Tegner Lysholm score <sup>[1, 2]</sup>.
- Post-operative Tegner Lysholm score at 3m, 6m, 12m, 24m follow up

### Meniscus root repair procedure

The patient is operated in the standard leg-hanging position and the menisci visualized through the anterolateral and anteromedial portals. Meniscal root attachment site prepared with a curette. Trans-tibial tunnel is drilled and mediolateral or anteroposterior suture configurations were used for root repair. The site of attachment of the root is medialized approximately 2mm to the anatomical site. A suture post was then used to secure the sutures.

### Post-operative Protocol

All patients were kept partial weight bearing and knee range of motion exercises from 0° to 60° were started, for the first 4 weeks post operatively.

Closed chain exercises and cryotherapy was also advised. Full weight bearing was only allowed after a period of 6-8 weeks post operatively, and full knee flexion was allowed at 3 months.

**Discussion**

The menisci have been attributed various functions like rotational stabilization, joint fillers and shock absorption. Most of the weight bearing is done by the posterior horn, so evidently, injuries of the posterior horn are more common. Diagnosis of Medial Meniscus Root Tears.

**Clinical Examination**

Clinically, it is somewhat difficult to specifically differentiate meniscus root tears from tears of the posterior horn. A clinical test was described by Seil *et al.* [3] but data regarding the sensitivity of the test is not yet available.

**Imaging**

Even with advanced imaging techniques, the diagnosis of medial meniscus root tears poses a challenge. A general consensus is that MRI should be considered the Gold Standard for diagnosis of these lesions. Conventionally, two MRI signs have been described that are diagnostic of meniscus root injuries: (Fig. 1)

1. Ghost sign: In sagittal cuts of the MRI, there is absence of the posterior horn of the meniscus
2. Meniscal Extrusion: It is external displacement of the meniscus from the tibial articular cartilage. It is not specific to meniscus root tears as it is also seen in joint effusion and degenerative joint disease [4].

A study stated that medial meniscus posterior root tears are commonly seen in places where kneeling and squatting are part of common everyday activities [5] Other factors that show a possible correlation with meniscus root tears are [6]:

- Increased Body Mass Index(BMI)
- Female sex
- Low activity level
- Varus mechanical axis

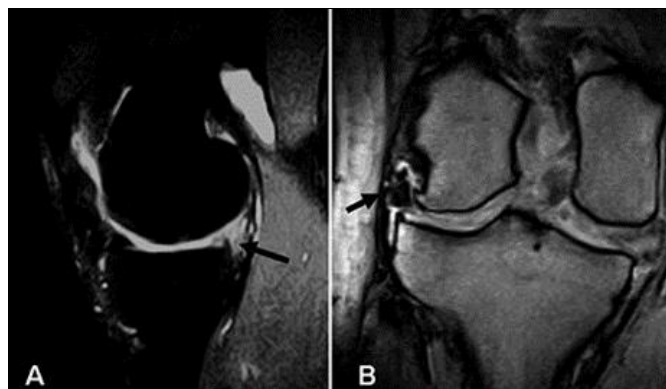
Most commonly, these tears are associated with chronic injuries having meniscal extrusion, reduced shock absorption, and degenerative osteoarthritis of the knee. Less commonly, it is due to an acute traumatic event. The biomechanics of knees with medial meniscus root tear have been found to be similar to that of knees after meniscectomy [7, 8] Up to 80% of patients with medial meniscus root tears tend to have spontaneous osteonecrosis of the knee [9].

All patients were followed up post operatively up to 24months. Resolution of preoperative symptoms was documented and good range of motion was observed in all patients. Tegner Lysholm scores were calculated at 3m, 6m, 12m, 24m and compared with preoperative scores.

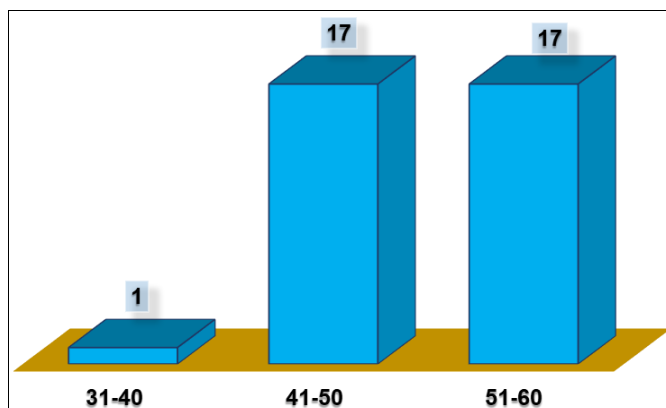
Post-operative grading of osteoarthritis was also done as per the Kellgren Lawrence grading system.

- Medialization of the root decreased the chances of suture cut out and helped in restoration of meniscal footprint.

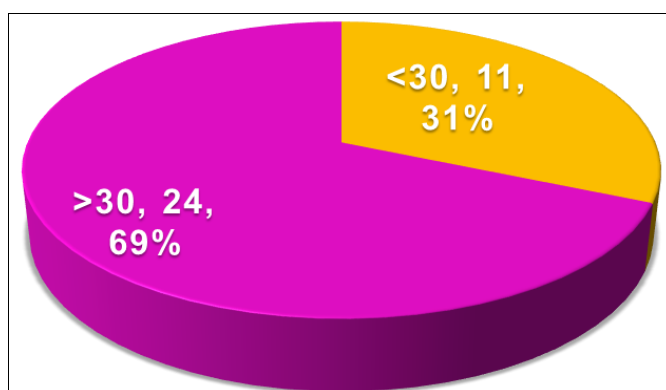
- There was a significant improvement between the pre-operative and post-operative TL scores of all patients. (Figure 4)
- We also found an inverse correlation between age of the patient and post-operative outcome.
- The BMI of the patient also had a significant effect on the post-operative outcome i. e. patients with BMI less than 30 had a slightly better post-operative outcome than patients with BMI more than 30. (Figure 5)
- Suture nature fibre tape/fibre wire had no effect on clinical outcome.



**Fig 1:** MRI signs of meniscal root tear. A – Ghost sign. B – Meniscal extrusion.



**Fig 2:** Distribution of cases according to age group



**Fig 3:** Distribution of cases according to body mass index

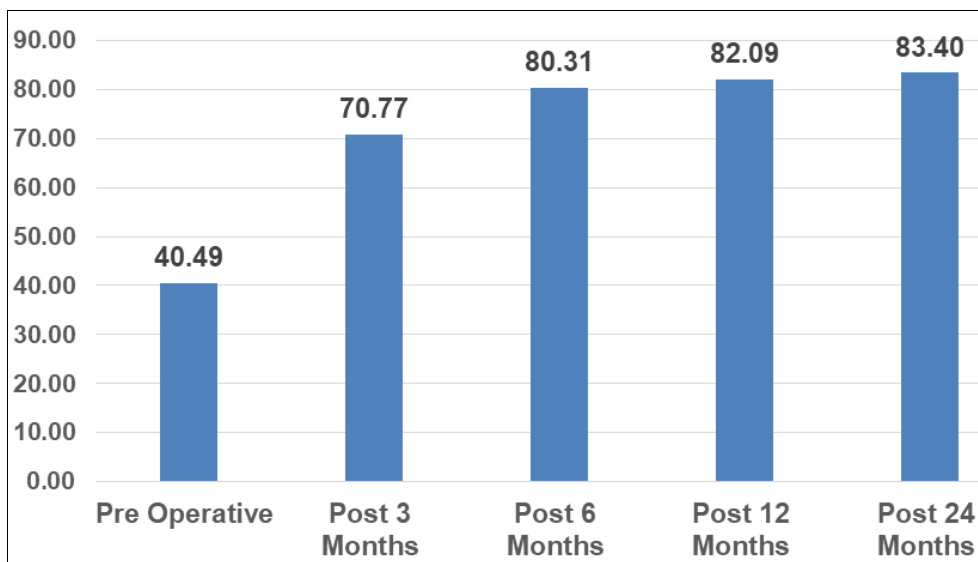


Fig 4: Comparison of tegner lysholm scores

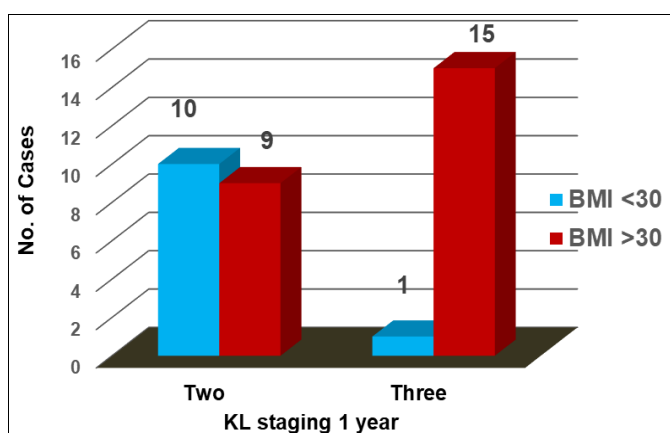


Fig 5: Association of BMI to K-L staging

8. Guermazi A, Hayashi D, Jarraya M *et al.* Medial posterior meniscal root tears are associated with development or worsening of medial tibiofemoral cartilage damage: the multicenter osteoarthritis study. *Radiology* 2013;268:814-21.
9. Robertson DD, Armfield DR, Towers JD *et al.* Meniscal root injury and spontaneous osteonecrosis of the knee - an observation. *J Bone Joint Surg Br* 2009;91:190-5.

**Conclusion**

Thus, we conclude that the torn medial meniscus root should be repaired as it helps in preserving the joint anatomy and delays the progression of osteoarthritis.

**Funding:** None

**Conflict of interest:** None declared

**References**

1. Campbell’s Operative Orthopaedics, Thirteenth Edition.
2. Tegner Y, Lysholm J. Rating systems in the evaluation of knee ligament injuries. *Clin Orthop Relat Res* 1985;(198):43-9.
3. Seil R, Duck K, Pape D. A clinical sign to detect root avulsions of the posterior horn of the medial meniscus. *Knee Surg Sports Traumatol Arthrosc* 2011;19:2072-5.
4. Bin SI, Kim JM, Shin SJ. Radial tears of the posterior horn of the medial meniscus. *Arthroscopy* 2004;20:373-8.
5. Bin SI, Kim JM, Shin SJ. Radial tears of the posterior horn of the medial meniscus. *Arthroscopy* 2004;20:373-8.
6. Hwang BY, Kim SJ, Lee SW, *et al.* Risk factors for medial meniscus posterior root tear. *Am J Sport Med* 2012;40:1606-10.
7. Allaire R. Biomechanical consequences of a tear of the posterior root of the medial meniscus similar to total meniscectomy. *J Bone J Surg Am* 2008;90:1922-31.