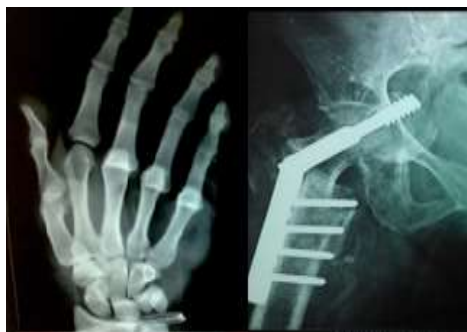



International Journal of Orthopaedics Sciences

E-ISSN: 2395-1958
P-ISSN: 2706-6630
IJOS 2021; 7(3): 75-78
© 2021 IJOS
www.orthopaper.com
Received: 05-04-2021
Accepted: 09-05-2021

Dr. Roshan Kumar BN
HOD & Professor, Department
of Orthopedics, RRMCM,
Bangalore, Karnataka, India

Dr. Prasanna TY
Assistant Professor, Department
of Orthopedics, RRMCM,
Bangalore, Karnataka, India

Dr. Neel Pasrija
Junior Resident, Department of
Orthopedics, RRMCM, Bangalore,
Karnataka, India

Meniscal tears associated with complete vs partial anterior cruciate ligament injury

Dr. Roshan Kumar BN, Dr. Prasanna TY and Dr. Neel Pasrija

DOI: <https://doi.org/10.22271/ortho.2021.v7.i3b.2728>

Abstract

Purpose: To investigate the incidence and location of meniscal tears in relation to complete vs partial anterior cruciate ligament (ACL) injury.

Subjects and Methods: We collected MRI of 114 patients (114 knees) diagnosed with combined ACL and meniscal injury at a follow up 3 months to 2 years of knee injury at our center in last 3 years. The subjects comprised 68 males and 46 females ranging in age from 20 to 55 years. The patients were divided into two groups: Meniscal tears with Partial ACL injury and Complete ACL injury and the results were compared between this two groups.

Results: The incidence of complete ACL injury diagnosed with MRI was 52.63% (60 of 114 knees) and partial ACL injury was 47.36% (54 of 114 knees). Regarding the locations of meniscal tears, in complete ACL injury (60 knees), medial meniscal tear was found in 60% (36 of 60 knees), lateral meniscal tear in 31.66 % (19 of 60 knees), and bilateral meniscal tears in 8.33 % (5 of 60 knees). In Partial ACL injury (54 knees), medial meniscal tear was found in 46.29 % (25 of 54 knees) and lateral meniscal tear in 42.59 % (23 of 54 knees) and bilateral (including medial and lateral) meniscal tears in 11.11 % (6 of 54 knees). Bucket handle tear was observed in 11 knees (medial: 8 knees, lateral: 3 knees) in complete ACL injury, and 4 knees (medial: 3 knees, lateral: 1 knee) in partial ACL injury.

Conclusion: Incidence of medial meniscus tear was more than 50% in complete ACL injury. Lateral meniscus tear was more associated with partial ACL injury compared to complete ACL injury.

Keywords: Anterior Cruciate Ligament (ACL), Meniscal tear, Magnetic resonance Imaging (MRI)

Introduction

There is relatively high incidence of meniscal injuries (40% to 68%) in association with Acute ACL tears and upto 96% in chronic ACL tears [1-3]. The lateral meniscus is injured more often in acute ACL tears and medial meniscus more likely in chronic ACL tears [1, 4-7]. Meniscal tears which are horizontal, oblique, radial, bucket handle are more commonly associated with Acute ACL injuries whereas peripheral tears occurring at meniscocapsular junction are more common in conjunction with chronic ACL deficient knees [8-11]. The presence of associated meniscal tears increases the risk of subsequent degenerative secondary osteoarthritis [12].

In the present study we investigated the incidence of occurrence of primary and secondary meniscal tears associated with complete vs partial ACL injuries. We also aimed to evaluate the location of meniscal tears associated with complete vs partial ACL injuries.

Subjects and methods

We collected MRI of 114 patients (114 knees) diagnosed with combined ACL and meniscal injury with a follow up 3months to 2 years of knee injury at our center in last 3 years. The subjects comprised 68 males and 46 Females with mean age of 29.1 (range 20–55) years.

The patients were divided into two groups: Complete ACL injury group; 60 knees, mean age 28.2 years) and partial ACL injury group; 54knees, mean age 23.7 years).

We compared the two groups with respect to the location of tear. In documenting the location of the tear, we used the classification system described by Cooper *et al.* [13] This system divides each meniscus into thirds radially. The radial zones are denoted as A, B, and C (A being the posterior third) for the medial meniscus and D, E, and F (F being the posterior third) for the lateral meniscus. A p value less than 0.05 was considered to indicate a significant difference.

Corresponding Author:
Dr. Roshan Kumar BN
HOD & Professor, Department
of Orthopedics, RRMCM,
Bangalore, Karnataka, India

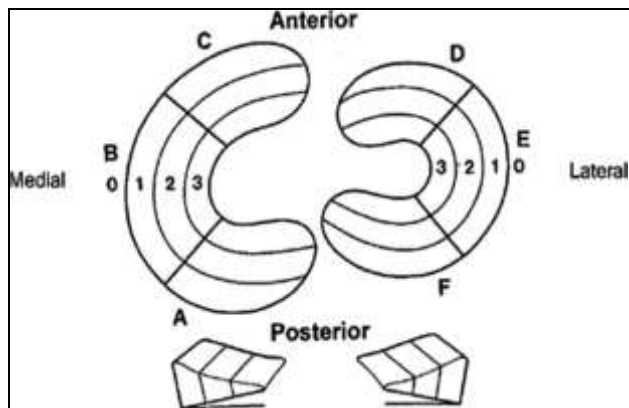


Fig 1: Meniscal zones of the knee according to Cooper's classification system [6]. The radial (A–F) zones of the medial and lateral meniscus

found in 46.29 % (25 of 54 knees), lateral meniscal tear in 42.59 % (23 of 54 knees), and bilateral meniscal tears in 11.11 % (6 of 54 knees). Medial meniscal tear was commonly associated with complete ACL injury and lateral meniscal tear was commonly associated with partial ACL injury. Bucket handle tear was observed in 11 knees (medial: 8 knees, lateral: 3 knees) in complete ACL injury, and 4 knees (medial: 3 knees, lateral: 1 knees) in partial ACL injury, and was more common in the complete ACL group.

Results

The incidence of complete ACL injury was diagnosed with MRI which was 52.63 % (60 of 114 knees) and partial ACL injury 47.36% (54 of 114 knees). Regarding the locations of meniscal tears, in complete ACL injury (60 knees), medial meniscal tear was found in 60 % (36 of 60 knees), lateral meniscal tear only in 31.66 % (19 of 60 knees), and bilateral (including medial and lateral) meniscal tears in 8.33 % (5 of 60 knees).

In partial ACL injury (54 knees), medial meniscal tear was

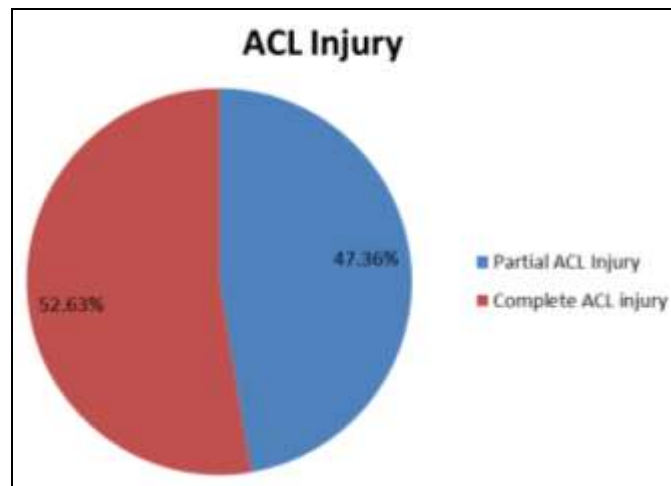


Fig 2: Incidence of Partial and Complete ACL injury

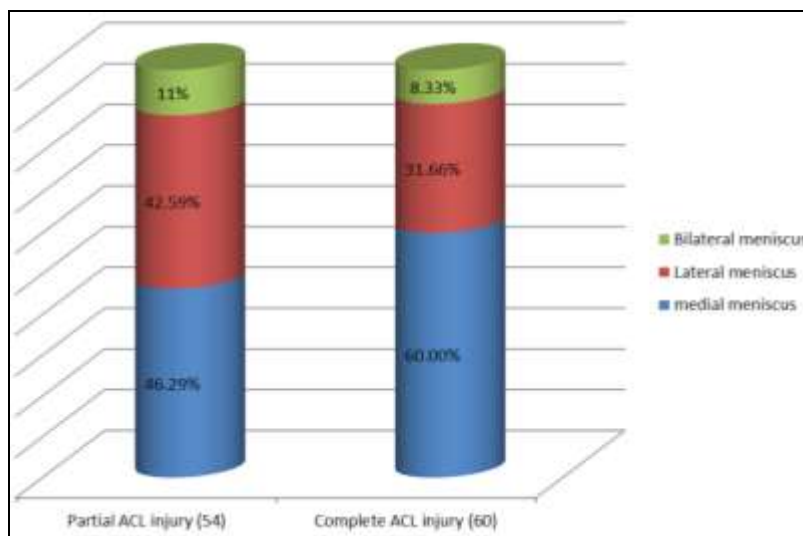


Fig 3: Distribution of meniscal tears in ACL-deficient knees

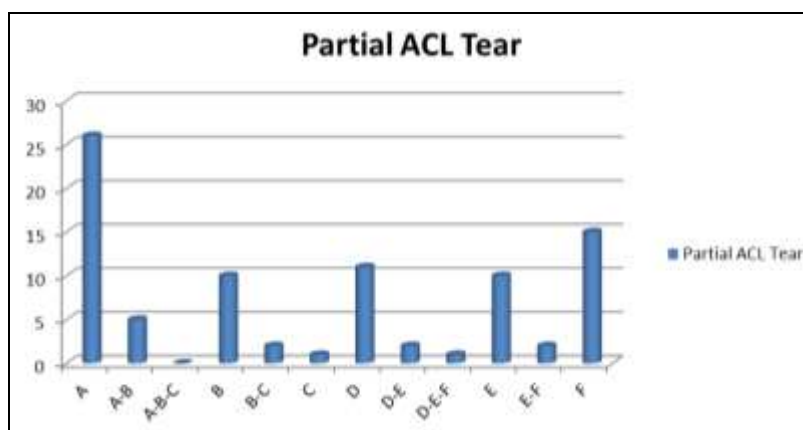


Fig 4: Zone distribution of meniscal tears in Partial ACL injury

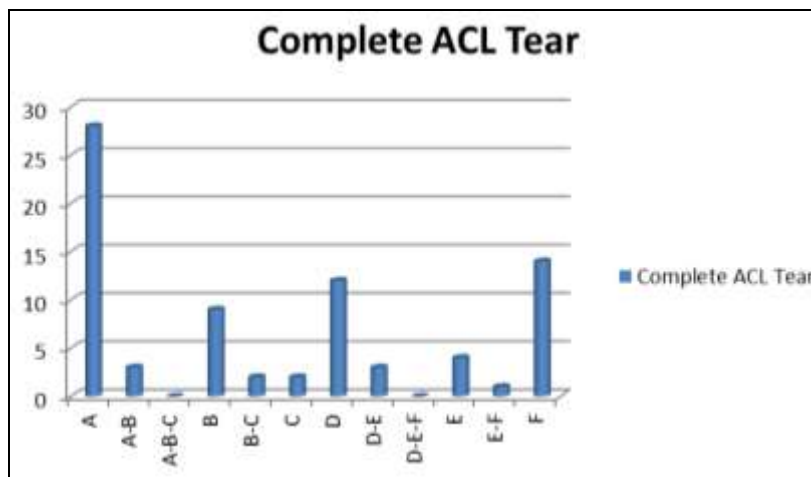


Fig 5: Zone distribution of meniscal tears in complete ACL injury

When meniscal tear locations were classified according to Cooper, the tears in the partial ACL group were frequently located in zones E and F; that is, middle to posterior region of the lateral meniscus (Fig.4). In the complete ACL group, however, there was an increase of tears in zones A and B; that is, middle to posterior region of the medial meniscus (Fig.5). Bucket handle tear was observed in a total of 4 knees (lateral: 1 knees, medial: 3 knees) in the partial ACL group, and 11 knees (lateral: 3 knees, medial 8: knees) in the Complete ACL group, with significantly more bucket handle tears in the complete ACL.

Discussion

The biomechanics of knee during and after ACL injury may help to explain the occurrence of meniscal tears. The most likely combination injury involves external rotation and valgus force on a flexed knee resulting in anteromedial knee instability [14]. The tibia moves forward and rotates laterally with respect to femur. While portion of medial complex and medial tibial plateau are pull forward by these forces. The medial meniscus is held by contraction of semimembranosus causing stress at the periphery of medial meniscus leading to tears at medial meniscocapsular junction [15]. As valgus displacement occurs there is impingement of posterior or middle portion of lateral meniscus between the femur and tibia which may lead to longitudinal meniscal tears. It is also likely that combination of mechanism contribute to sometimes complex injuries of the knee. In 1997 meta-analysis Bellabarba *et al.* reported that meniscal tears were seen in 41-82% of acute ACL ruptures and 58-100% of chronic ACL injuries [16]. It is also postulated that majority of peripheral meniscal lesions are associated with some degree of ACL laxity. In our study, incidence of medial meniscus tear was more than 50% in complete ACL tear probably because of primary meniscal tears during injury and also secondary meniscal tear caused by increased knee joint laxity causing peripheral tears of posterior horn of medial meniscus. Lateral meniscus tear was more associated with partial ACL tear compared to complete ACL tears because of index complex knee injuries and decreased knee translation.

In 2001 Smith and Barrete described meniscal tear pattern in ACL deficient knees based on locations of 575 prospectively evaluated ACL tears. They found no statistically significance difference in medial vs lateral tears. However tears involved the medial meniscus significantly involve the posterior horn and in the peripheral meniscocapsular junction [17]. Thompson and Fu in analysis of multiple papers found that peripheral

posterior horn tears accounted for more than half of meniscal tears seen in patients with acute or chronic ACL injuries [18]. Many papers have also pointed out that peripheral location of these lesions in vascularized portion of meniscus gives them potential to heal and make them amenable to repair rather than removal.

In relation to complete ACL tear, the location of medial meniscus tear was more common in posterior horn compared to middle horn, whereas the incidence in lateral meniscus tear was almost equal in anterior and posterior horn because of increased knee translation due to complete ACL deficiency. In relation to partial ACL tear, the location of medial meniscus tear was more common in posterior and middle horn, whereas the incidence in lateral meniscus was almost equal in anterior and middle horn and more in posterior horn due to relative knee translation.

The current study has limitations that should be considered while interpreting the results having a small sample size, inter observer variation while interpreting the MRI and also we could not assess the morphology of meniscal tears in all patients. Large multicentric studies may be required to definitively answer some of these questions.

Conclusion

Incidence of medial meniscus tear was more than 50% in complete ACL tear. Lateral meniscus tear was more associated with partial ACL tear compared to complete ACL tear.

In relation to complete ACL tear, the location of medial meniscus tear was more common in posterior horn compared to middle horn, where as the incidence in lateral meniscus tear was almost equal in anterior and posterior horn. In relation to partial ACL tear, the location of medial meniscus tear was more common in posterior and middle horn, where as the incidence in lateral meniscus was almost equal in anterior and middle horn and more in posterior horn.

References

1. Bellabarba C, Bush-Joseph CA, Bach BR Jr. Patterns of meniscal injury in the anterior cruciate-deficient knee: a review of the literature. *Am J Orthop (Belle Mead NJ)* 1997;26:18-23.
2. Shoemaker SC, Markolf KL. The role of the meniscus in the anterior-posterior stability of the loaded anterior cruciate-deficient knee. Effects of partial versus total excision. *J Bone Joint Surg Am* 1986;68(1):71-79.
3. Warren RF, Levy IM. Meniscal lesions associated with

- anterior cruciate ligament injury. *Clin Orthop Relat Res.* 1983;(172):32-37.
4. Cerabona F, Sherman MF, Bonamo JR, Sklar J. Patterns of meniscal injury with acute anterior cruciate ligament tears. *Am J Sports Med.* 1988;16:603-609.
 5. Thompson WO, Fu FH. The meniscus in the cruciate-deficient knee. *Clin Sports Med* 1993;12:771-796.
 6. Noyes FR, Bassett RW, Grood ES, Butler DL. Arthroscopy in acute traumatic hemarthrosis of the knee. Incidence of anterior cruciate tears and other injuries. *J Bone Joint Surg Am.* 1980;62:687-695, 757.
 7. Spindler KP, Schils JP, Bergfeld JA, *et al.* Prospective study of osseous, articular, and meniscal lesions in recent anterior cruciate ligament tears by magnetic resonance imaging and arthros arthroscopy. *Am J Sports Med.* 1993;21:551-557.
 8. Zanetti M, Pfirrmann CWA, Schmid MR, Romero J, Seifert B, Hodler J. Patients with suspected meniscal tears: prevalence of abnormalities seen on MRI of 100 symptomatic and 100 contralateral asymptomatic knees. *AJR Am J Roentgenol* 2003;181:635-641.
 9. Helms CA. The meniscus: recent advances in MR imaging of the knee. *AJR Am J Roentgenol* 2002;179:1115-1122.
 10. De Smet AA, Graf BK. Meniscal tears missed on MR imaging: relationship to meniscal tear patterns and anterior cruciate ligament tears. *AJR Am J Roentgenol* 1994;162:905-911.
 11. Smith JP, Barrett GR. Medial and lateral meniscal tear patterns in anterior cruciate ligament-deficient knees. *Am J Sports Med* 2001;29:415-419.
 12. Haute Autorité de Santé. Prise en charge thérapeutique des lésions méniscales et des lésions isolées du ligament croisé antérieur du genou chez l'adulte. *Recommandations professionnelles* 2008.
 13. Cooper DE, Arnoczky SP, Warren RF. Arthroscopic meniscal repair. *Clin Sports Med* 1990;9(3):589-607.
 14. Nicholas JA. The five-one reconstruction for anteromedial instability of the knee. *J Bone Joint Surg Am* 1973;55:899-922.
 15. Hughston JC. *Knee ligaments: injury and repair.* St Louis, MO: Mosby 1993.
 16. Bellabarba C, Bush-Joseph CA, Bach BR Jr. Patterns of meniscal injury in the anterior cruciate-deficient knee: a review of the literature. *Am J Orthop* 1997;26:18-23.
 17. Smith JP, Barrett GR. Medial and lateral meniscal tear patterns in anterior cruciate ligament-deficient knees. *Am J Sports Med* 2001;29:415-419.
 18. Thompson WO, Fu FH. The meniscus in the cruciate-deficient knee. *Clin Sports Med* 1993;12:771-796.