

E-ISSN: 2395-1958
P-ISSN: 2706-6630
IJOS 2021; 7(2): 889-892

www.orthopaper.com
Received: 03-02-2021
Accepted: 08-03-2021

Dr. Mahesh Khandelwal
Associate Professor, Department of Orthopaedics, GMERS Medical College, Vadnagar, Mehsana, Gujarat, India

Dr. Hitendra Prahaladbhai Patel
Ex Assistant Professor, Department of Orthopaedics, GMERS Medical College, Vadnagar, Mehsana, Gujarat, India

Dr. Prajapati Sumit Pravinbhai
Senior Resident, Department of Orthopaedics, GMERS Medical College, Vadnagar, Mehsana, Gujarat, India

Corresponding Author:
Dr. Hitendra Prahaladbhai Patel
Ex Assistant Professor, Department of Orthopaedics, GMERS Medical College, Vadnagar, Mehsana, Gujarat, India

A clinical study for the comparison of volar plate versus external fixation in distal radius fractures surgery

Dr. Mahesh Khandelwal, Dr. Hitendra Prahaladbhai Patel and Dr. Prajapati Sumit Pravinbhai

DOI: https://doi.org/10.22271/ortho.2021.v7.i2l.2765

Abstract
Background: Distal radius fractures (DRFs) are the most common fractures in the upper extremity and cause major healthcare concerns.
Objective: This study compares surgical outcomes of volar locking plates (VP) versus external fixation (EF) for AO-type distal radius C2 and C3 fractures.
Methods: Patients (n=55) with AO-type C2 or C3 DRFs are recruited in this prospective, randomized study comparing volar plate fixation with external fixation. We have evaluated wrist range of motion, grip strength, and Michigan Hand Questionnaire at each patient visit and measured radiographic assessment (radial inclination, volar tilt, ulnar variance, and articular congruity) at 3-, 6- and 12-months post-surgery.
Results: Both 3 and 6 months after trial, the VP group had significantly greater grip strength than the EF group but not at 12 months. At the 3 and 6-month follow-up did the VP group display a significantly greater range of motion than the EF group ($P < 0.05$). Only at 3 and 6 months did the VP and EF groups score significantly differently on the functional assessment. As measured by ulnar variance, the VP group showed superior radiologic results after 12 months. During the 12-month follow-up, there were 5 complications (22%) in the VP group and 7 (31%) in the EF group. No statistically significant differences were observed between complication rates by treatment or complication types.
Conclusion: The functional outcomes for comminuted intra-articular distal radius fractures as observed following distal radius surgery offer insight into treatment decisions and interpretations of treatment outcomes.

Keywords: Distal radius fractures, complex articular fracture, volar plating, external fixation, functional outcome

Introduction

Approximately 70% of fractures in the upper extremity are distal radius fractures (DRFs), a health concern that poses a significant threat to the general population [1]. Ageing population, increasing life expectancy and subsequent increases in osteoporosis have resulted in the rising incidence of DRFs, with reports of 17% to 100% increases over the past 3 to 4 decades [2]. There are no noticeable differences between the surgical and nonsurgical treatment of patients over the age of 65, but surgical fixation of the DRF enables patients to resume daily activities earlier and more independently [3]. Anatomic reduction and stable fixation are difficult for comminuted and displaced intraarticular DRFs, and they often lead to poor functional outcomes [4].

Distal radius fractures are treated with nonbridging external fixation. The external fixation (EF) technique has been used for many years, with or without the adjuvant pins. For simple fractures, pin fixation has a high rate of success, and its effectiveness has been documented even for more difficult configurations of fracture [5]. External fixation has been an important method for treating distal radius fractures, but ligamentotaxis and closed reductions are required for the reduction of intra-articular fragments during this treatment. During the past decade, however, flying locking plates have become more popular.

Unstable distal radius fractures are commonly treated with volar locking plates because of their low complication rates and high stability in osteoporotic bone without joint distraction [6]. However, fractures with distal articular fragments that are too small or comminuted may not allow fragment reduction and stable fixation with open reduction. Several studies have shown that even open reduction internal fixation (ORIF) fails to produce anatomic reductions in some complex fractures [7].

In this randomized, controlled trial, we wanted to determine whether VLPs were superior to EF with adjuvant pins in the treatment of unstable distal radius fractures in terms of subjective and objective outcomes

Materials and Methods

Patient selection

On the basis of plain radiographs and computed tomography scans, 55 consecutive patients with complex articular DRFs were enrolled for 2 years. These patients were recruited from a tertiary care hospital serving as a regional emergency-trauma center. Inclusion criteria were patients with AO-type C2 or C3 DRFs confirmed by computed tomography scans (determined by 2 orthopedic hand surgeons), treated less than 2 weeks after injury and aged <70 years. Patients with systemic, multiorgan, or head injuries; bilateral fractures; concomitant wrist or upper extremity injuries and open fractures or associated nerve lesions were excluded. Of 55 eligible subjects, 5 were excluded owing to these criteria and 3 were lost to follow-up: 2 at 6 months and 1 more at 12 months. One patient died before 12-month follow-up from causes unrelated to the fracture; the others did not respond to phone calls or letters. Thus, 45 subjects formed the basis for all subsequent analyses. All patients provided informed consent before participating in the study, and the protocol was approved by the institution's ethics committee. Using a random number generator, each patient was assigned to one of the VP or EF groups.

Surgical procedures

All surgical procedures were performed by orthopedic hand surgeons with >10 years of orthopedic experience. By using the flexor carpi radialis strategy, open reduction was performed on the VP group. Synthes 2.4 LCP distal radius systems and Medartis Aptus Radius 2.5 plates were used. EF group images were reduced using image intensification with open or limited reduction. In cases of incomplete reduction (eg, stepoff deformity greater than 2 mm, dorsal tilting, or radial shortening greater than 2 mm) after closed manipulation, we used a percutaneous K-wire or a small elevator, which was inserted through a small incision, to manipulate the fragments. Typically, 31.6-mm (0.062-in) K-wires and a few additional 1.1-mm subchondral K-wires were used to secure the intra-articular fragments, including lunate facet fragments. One uniplanar bridging EF system was used throughout the study. Short arm Orthoses were provided for 2 weeks to patients undergoing VP, followed by removable short arm Orthoses for another 2 weeks. Patients undergoing closed reduction and EF (with or without intra-focal K-wire fixation) were treated with a short arm orthosis for 2 weeks. The external fixator was removed 5 to 6 weeks after surgery, followed by a removable orthosis as required. Removal of the external fixator was performed in the outpatient clinic.

Immediately following surgery, patients were advised to elevate the affected limb and perform finger exercises. Exercises for wrist range of motion were initiated immediately after removal of the orthosis in the case of VP and after removal of the frame in the case of EF. We offered formal physiotherapy for two weeks (twice/week) and gave each patient an exercise program emphasizing passive and active range of motion and control of hand and wrist swelling. They were instructed to perform the exercises at home for a minimum of 5 times/day and were offered oral nonsteroidal anti-inflammatory drugs.

Functional assessment post-surgery

Patients were called for a functional assessment 3, 6 and 12 months after surgery. In each visit, a trained nurse assessed wrist range of motion and grip strength and administered the Michigan Hand Questionnaire (MHQ) after the clinical examination. At the 12-month follow-up, using a software tool in PACS, an independent radiologist evaluated volar tilt, radial inclination, ulnar variance, and articular incongruity. Grip strength was measured using the Jamar dynamometer with the elbow flexed at 90 and the forearm in neutral rotation. Grip strength was recorded in kilograms and then the values were changed as a percentage of the injured side relative to the uninjured side. In this study, wrist flexion extension and pronation-supination were measured using a standard goniometer, and the results were expressed as a percentage of the injured side relative to the uninjured side. We selected the ratios of injured/uninjured (side of the wrist) MHQ scores at each measurement time for the functional state of the patients.

Results

In both groups, age, sex, affected side, ulnar involvement, and time to surgery were similar. VP patients' time for surgery was more prolonged than that of EF patients ($P< 0.05$), and the period of immobilization for EF patients was longer ($P< 0.01$) (Table 1).

Table 1: Demographic and Clinical Characteristics of Patients.

	Volar plate group	External fixation group
Patients, n	23	22
Gender (M/F)	14/9	13/9
Age (Years)	51±8	51.6±7
Affected side, R/L	12/11	10/12
Fracture type		
C2	10	15
C3	13	7
Ulnar involvement	12	13
Time to surgery (Day)	3.1	2.4
Operation time (Min)	64	56
Immobilization (week)	4.6	6.1

Both 3 and 6 months after trial, the VP group had significantly greater grip strength than the EF group (both $P< 0.05$), but not at 12 months (Fig. 1A). Only at the 3-month follow-up did the VP group display a significantly greater range of motion than the EF group ($P< 0.01$) (Flexion/Extension Fig. 1B and Pronation/Supination, Fig. 1C). There was a significant difference in functional score between the VP and EF groups only at 3 months ($P< 0.05$) (Fig. 1D).

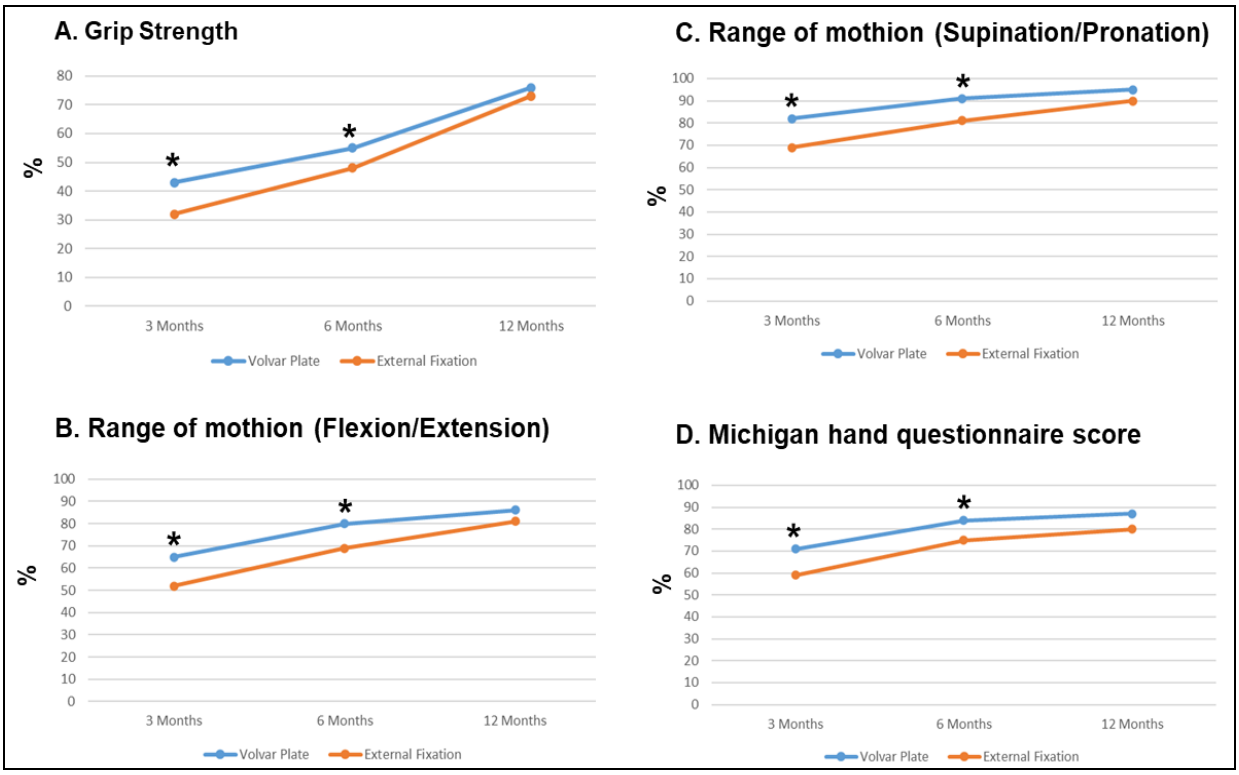

Fig 1: A. Grip strength, B. Range of motion in a flexion-extension, C. Range of motion in a pronation-supination, D. MHQ scores between the VP and EF groups at months 3, 6 and 12 months. *P< 0.05. %, Percentage of the injured side relative to the uninjured side.

At 12 months, the VP group showed superior radiologic outcomes in terms of ulnar variance (P< 0.05) (Table 2). Ulnar variance greater than 2 mm was found in 4 of 23 patients (17.39%) in the EF group and 2 of 22 patients in the VP group (9%). There were no significant differences in terms of volar tilt or radial inclination between the VP and EF groups. One patient in the VP group (4.4%) and 2 in the EF group (8.5%) showed an intra-articular deformity greater than 2 mm, but it was not statistically significant.

Table 2: Final Radiologic and Functional Outcome after Distal Radius Surgery

	Volar plate group	External fixation group	P
	n=23	n=22	
Ulnar Variance (MM)			
Injured side	0.8±0.02	1.6±0.08	<0.05
Uninjured side	0.6±0.03	0.76±0.05	NS
Volar tilt (degree)	6±4	5±3	NS
Radial inclination (degree)	31±5	28±4	NS
Articular incongruity stepoff (mm)			
0-1	8	9	NS
1-2	13	10	NS
2-3	1	2	NS
>3	0	1	NS

During the 12-month follow-up, there were 5 complications (22%) in the VP group and 7 (31%) in the EF group. No statistically significant differences were observed between complication rates by treatment or complication types. Complications included 3 cases of the late development of carpal tunnel syndrome (1 in each group), which resolved after a corticosteroid injection; 1 case of complex regional pain syndrome type I (CRPS I) (1 each group), which were managed by physiotherapy and medication; and 2 cases of adhesive capsulitis of the shoulder (1 in each group), which were treated with exercise. There were 3 cases of superficial pin-track infection in the EF group and 1 of superficial wound site infection in the VP group, which was treated with local wound care and oral antibiotics. Other complications were neuritis of the sensory branch of the radial nerve, ulnar impaction syndrome. Two plates were removed because of extensor tendon irritation by screws at 6 and 7 months after surgery, respectively.

Discussion

The VP group showed superior short-term results for functional recovery. The VP group showed superior radiological outcome in terms of the ulnar variance. However, there were no significant differences in grip strength, motion, or functional scores between the VP and EF groups at 12 months, but this outcome had no effect on functional outcomes at 12 months.

Previous studies indicated that VP patients resume daily activity more quickly than EF patients [8]. This remains uncertain whether this is because VP is better adapted to younger patients with simpler fractures, whereas EF may have been used more often for less active (older) patients with more complex fractures. EF treatment has been shown to be effective, according to the results associated with delayed

functional recovery up to 3 months after distal radius surgery. Similarly, the arm, shoulder, and hand disability score improved only 3 months after EF or radial column plating was used, while all groups by 6 months were fully functional [9].

In the current study, VP fixation had an overall decreased incidence of complications compared with external fixation similar to previous reports [10] which have tended to show decreased complications in patients treated with VP. Some studies suggested that CRPS I is more likely to occur after EF than after other surgical procedures [11]. CRPS I was not significantly different between groups in the present study, which is consistent with other studies [12].

Our results are in accordance with the findings of previously reported studies of randomized comparisons of ORIF and EF for intra-articular displaced fractures of distal radius [13]. An assessment of intra-articular comminuted or displaced fractures without significant differences in step off between ORIF and EF did not have any significant effects on patient symptoms, impairments, and disabilities over the long term [14].

Conclusion

The current study showed that VP resulted in superior radiographic results with respect to ulnar variance, but these radiographic outcomes did not affect functional outcomes.

References

1. Chung KC, Shauver MJ, Birkmeyer JD. Trends in the United States in the treatment of distal radial fractures in the elderly. J Bone Joint Surg Am. 2009;91(8):1868e1873.
2. Melton LJ III, Amadio PC, Crowson CS *et al*. Long-term trends in the incidence of distal forearm fractures. Osteoporos Int 1998;8(4):341e348.
3. Ring D, Jupiter JB. Treatment of osteoporotic distal radius fractures. Osteoporos Int 2005;16(2):S80eS84.
4. Knirk JL, Jupiter JB. Intra-articular fractures of the distal end of the radius in young adults. J Bone Joint Surg Am 1986;68(5):647e659.
5. Glickel SZ, Catalano LW, Raia FJ, *et al*. Long-term outcomes of closed reduction and percutaneous pinning for the treatment of distal radius fractures. J Hand Surg Am 2008;33(10):1700-1705.
6. Orbay JL, Fernandez DL. Volar fixation for dorsally displaced fractures of the distal radius: a preliminary report. J Hand Surg Am 2002;27(2):205-215.
7. Bini A, Surace MF, Pilato G. Complex articular fractures of the distal radius: the role of closed reduction and external fixation. J Hand Surg Eur 2008;33(3):305e310.
8. Grewal R, MacDermid JC, King GJ, *et al*. Open reduction internal fixation versus percutaneous pinning with external fixation of distal radius fractures: a prospective, randomized clinical trial. J Hand Surg Am 2011;36(12):1899e1906.
9. Rozental TD, Blazar PE, Franko OI, *et al*. Functional outcomes for unstable distal radial fractures treated with open reduction and internal fixation or closed reduction and percutaneous fixation: a prospective randomized trial. J Bone Joint Surg Am 2009;91(8):1837e1846.
10. Wright TW, Horodyski M, Smith DW. Functional outcome of unstable distal radius fractures: ORIF with a volar fixed-angle tine plate versus external fixation. J Hand Surg Am 2005;30(2):289e299.
11. Hegeman JH, Oskam J, Vierhout PA, *et al*. External fixation for unstable intra-articular distal radial fractures in women older than 55 years: acceptable functional end results in the majority of the patients despite significant secondary displacement. Injury 2005;36(2):339e344.
12. Zollinger PE, Kreis RW, van der Meulen HG, *et al*. No higher risk of CRPS after external fixation of distal radial fractures: subgroup analysis under randomised vitamin C prophylaxis. Open Orthop J 2010;(4):71e75.
13. Jeudy J, Steiger V, Boyer P, *et al*. Treatment of complex fractures of the distal radius: a prospective randomised comparison of external fixation “versus” locked volar plating. Injury 2012;43(2):174e179.
14. Bolmers A, Luiten WE, Doornberg JN, *et al*. A comparison of the long-term outcome of partial articular (AO type B) and complete articular (AO type C) distal radius fractures. J Hand Surg Am 2013;38(4):753e759