



E-ISSN: 2395-1958  
P-ISSN: 2706-6630  
IJOS 2021; 7(2): 752-754  
© 2021 IJOS  
[www.orthopaper.com](http://www.orthopaper.com)  
Received: 16-02-2021  
Accepted: 18-03-2021

**Dr. Ankur Kumar**  
Dr. D. Y. Patil Medical College,  
Hospital & Research Centre,  
Sant Tukaram Nagar, Pimpri  
Colony, Pimpri-Chinchwad,  
Maharashtra, India

## A rare concurrence of giant cell tumor and Myasthenia gravis

**Dr. Ankur Kumar**

**DOI:** <https://doi.org/10.22271/ortho.2021.v7.i2j.2701>

### Abstract

Giant Cell tumors are rare, locally aggressive tumors, seen most commonly in long bones. These benign bone tumors are usually associated with disturbance of the bony architecture whereas, myasthenia gravis is an autoimmune disorder affecting the neuromuscular junction and manifests as a generalized muscle weakness that might involve the respiratory muscles and can lead to development of other autoimmune conditions and myasthenic crisis. Here we are reporting a rare concurrence of Giant cell tumor and myasthenia gravis in a 50 year old patient in which we used sandwich technique of reconstruction, without any perioperative complications, that resulted in good functional outcome.

**Keywords:** giant cell tumor, myasthenia gravis, sandwich technique, distal femur

### Introduction

Giant cell tumors of bone, also known as osteoclastomas. Giant cell tumor generally a benign tumor composed of mononuclear stromal cells and characteristic multinucleated giant cells that exhibit osteoclastic activity. It usually develops in long bones but can occur in unusual locations<sup>[1]</sup>.

GCT accounts for 5% of all primary bone tumors and 20% of benign skeletal tumors (5–7). There is an unusually high prevalence in southern India and China, where GCT represents 20% of all primary bone tumors<sup>[2, 3]</sup>. The Prognosis of ultimate tumor behavior is dependent on surgical staging (which requires careful radiographic analysis to detect cortical breakthrough and joint involvement) and type of treatment. The recurrence rate is relatively high with simple curettage but decreases with adjuvant treatment at the tumor site. Optimal therapy for the more aggressive lesions is wide resection, but compromise is frequently required when such a resection would sacrifice joint function because of the subarticular location of the giant cell tumor<sup>[4]</sup>.

Myasthenia gravis is an autoimmune disorder caused by autoantibodies against the nicotinic acetylcholine receptor on the postsynaptic membrane at the neuromuscular junction and characterized by weakness and fatigability of the voluntary muscles. It has a bimodal peak of incidence with first peak in the third decade and the second peak in the sixth decade<sup>[5]</sup>.

The presence of myasthenia gravis and giant cell tumor together in a patient brings about a challenging management that requires preoperative optimization of comorbid conditions and postoperative physiotherapy.

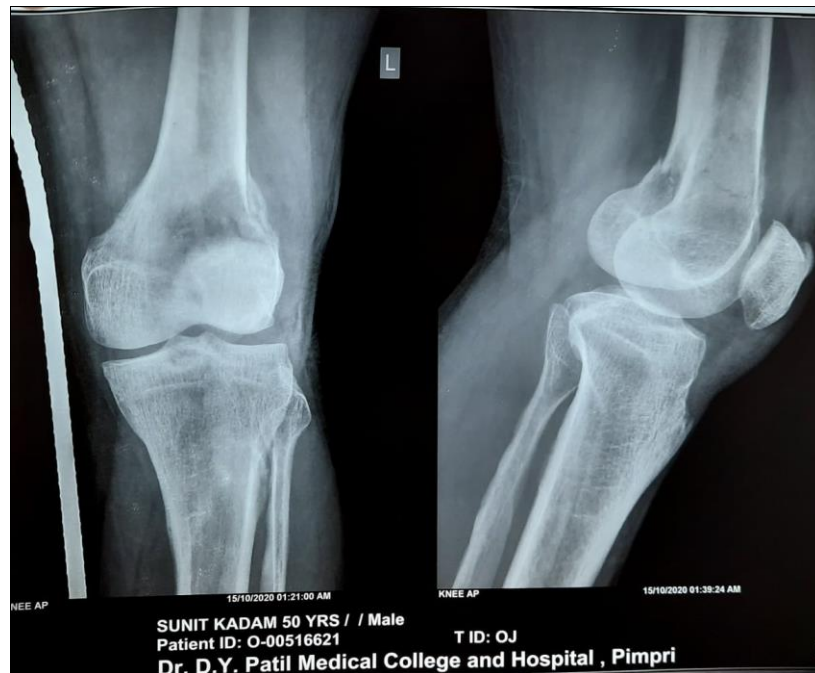
### Case Report

A 50 year male, who is a Chef by profession, a known case of hypertension since 2 years & myasthenia gravis since one year, was brought to the emergency department following an alleged history of fall from stairs three hours back. Following which he developed an intense swelling and tenderness over left knee. Subsequent to a primary survey he was declared hemodynamically stable. On examination, swelling and tenderness present over left knee, with range of motion restricted. Patient was on tablet Amlodipine 5 mg OD and tablet Neostigmine 15 mg BD with AChR antibody level 0.62 nmol/l. He also gave history of intermittent dull aching pain and local swelling in his left knee after prolonged exercise or standing since last 4 years.

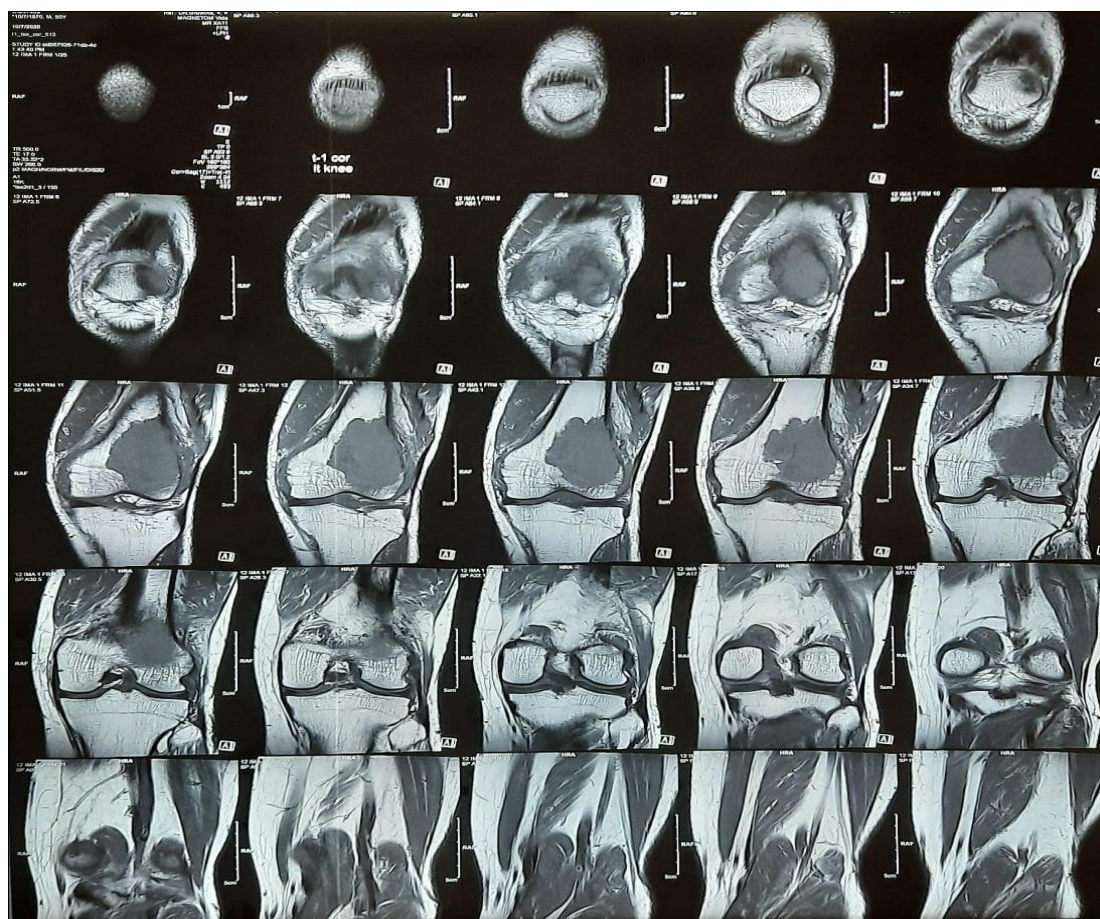
**Corresponding Author:**  
**Dr. Ankur Kumar**  
Dr. D. Y. Patil Medical College,  
Hospital & Research Centre,  
Sant Tukaram Nagar, Pimpri  
Colony, Pimpri-Chinchwad,  
Maharashtra, India

Radiography of his left knee showed an expansile, osteolytic, radiolucent lesion at the distal portion of femur without

sclerotic margin and without periosteal reaction.



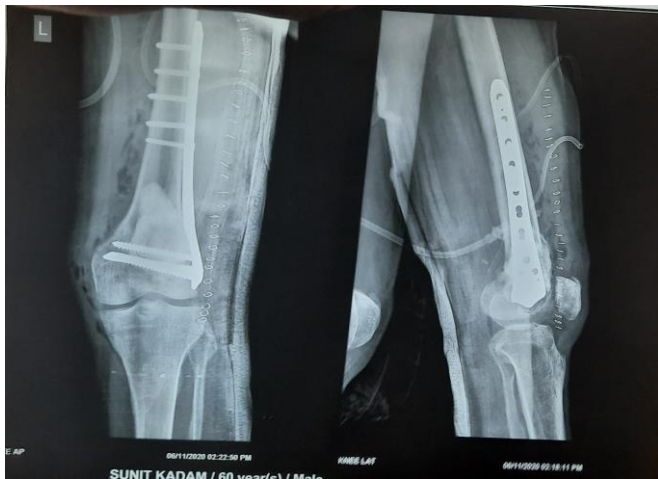**Fig 1:** Showed a well-defined lytic lesion, involving distal femoral diaphysis



**Fig 2:** showed a single, well defined

Under spinal-epidural anesthesia, incision taken and a large cortical window made to have good access the tumor. The cavity was then enlarged using a high power burr in all directions cautiously to prevent any contamination of the surrounding soft tissues. The cavity was cleaned with jet lavage of 5% phenol, and phenol soaked gauze was placed

inside the cavity for 2 minutes. Care was taken not to spill the phenol to the surrounding tissues. A layer of gel foam was laid and the remaining cavity was packed with cement. Cement was shaped to match the architecture of distal femur, further supported by distal femur locking plate.



**Fig 3:** Post-operative X-ray

Postoperatively, non-weight-bearing crutch walking was started and after 20 weeks weight bearing was allowed as tolerated. Intravenous zoledronate (4 mg) was given once monthly for 6 months, along with oral supplementation of vitamin D and calcium. Our patient showed significant improvement in his recovery by resuming his work in 6 weeks without any functional compromise.

### Discussion

The most common site for giant cell tumors (GCT) is knee, where the tumor characteristically extends right up to the subarticular bone plate. Extensive curettage with preservation of the joint should be done wherever possible. The alternatives for filling the void left after curettage are either bone graft or bone cement. Sandwich technique uses the advantages of both, taking care to prevent damage to articular cartilage [6]. It doesn't get any easier when we plan the same technique in a patient of myasthenia gravis, lot of odds comes into existence, right from the risks of having or developing other autoimmune diseases like Rheumatoid arthritis or SLE during the course of treatment, but also the post-operative complications like recurrence.

A study in 1975 by JA Aarli, showed that arthritis may develop during the course of MG. The clinical and serological data demonstrate a close relationship between the two disorders. In some patients, the articular symptoms indicate the development of RA. In other patients, the myasthenia may be a prelude to SLE. In still other patients, unspecified arthralgia occurs, where only the future clinical development may reveal the definite diagnosis [7].

Therefore, when we deal with two major concurrent conditions, decision making requires an extensive assessment of the surgical outcome

GCT deserves consideration in our first option until waxing and waning nature of MG is noticed. Male gender, distal femur GCT with restricted range of motion, MG stabilized on anticholinesterase medication & well-controlled hypertension are some potential predictors that assisted in decision making of using a sandwich technique, for a good surgical outcome.

### Conclusion

Knowing the close relationship of Myasthenia gravis with risk of developing arthritis and using sandwich technique for limb salvaging in GCT. It would be safe to say that benefit outweighs the risks in this case. A long term follow-up is required for any early diagnosis of complication and prompt adequate therapy can help to reduce events of recurrence and

repeated surgeries.

### Reference

1. Giant Cell Tumor of Bone: Review, Mimics, and New Developments in Treatment Corey J. Chakarun, MD, Deborah M. Forrester, MD, Christopher J. Gottsegen, MD, Dakshesh B. Patel, MD, Eric A. White, MD, George R. Matcuk, Jr, MD
2. Turcotte RE. Giant cell tumor of bone. *Orthop Clin North Am* 2006;37(1):35-51.
3. Arnold RT, van Holsbeeck MT, Mayer TG, Mott MP, Koch SR. Necrotic giant cell tumor of bone manifesting with pathologic fracture. *RadioGraphics* 2011;31(1):93-98.
4. Manaster BJ, Doyle AJ. Giant cell tumors of bone. *Radiol Clin North Am.* 1993;31(2):299-323. PMID: 8446751.
5. Thanvi BR, Lo TCN, Update on myasthenia gravis, *Postgraduate Medical Journal* 2004;80:690-700.
6. Kundu ZS, Gogna P, Singla R, Sangwan SS, Kamboj P, Goyal S. Joint salvage using sandwich technique for giant cell tumors around knee. *J Knee Surg* 2015;28(2):157-64. doi: 10.1055/s-0034-1373738. Epub 2014. PMID: 24752921.
7. Arthritis in myasthenia gravis JA AARLI, E.-J. MILDE, AND S. Thunold From the Departments of Neurology and Pathology, School of Medicine, University of Bergen, and the Rheumatic Disease Unit, The Deaconesses' Hospital, Bergen, Norway