

E-ISSN: 2395-1958
P-ISSN: 2706-6630
IJOS 2021; 7(2): 698-704

www.orthopaper.com
Received: 25-02-2021
Accepted: 27-03-2021

Dr. TR Sunil Kumar
MS Ortho, Assistant Professor of Orthopaedics, Sanjay Gandhi Institute of Trauma and Orthopaedics Bangalore, Karnataka, India

Dr. B Easwar
Junior Resident, MS Ortho, Sanjay Gandhi Institute of Trauma and Orthopaedics Bangalore, Karnataka, India

Dr. Ashwin S
Junior Resident, MS Ortho Sanjay Gandhi Institute of Trauma and Orthopaedics Bangalore, Karnataka, India

Corresponding Author:
Dr. TR Sunil Kumar
MS Ortho, Assistant Professor of Orthopaedics, Sanjay Gandhi Institute of Trauma and Orthopaedics Bangalore, Karnataka, India

A prospective study of functional outcome of intracapsular femoral neck fractures with delayed presentation in young adults

Dr. TR Sunil Kumar, Dr. B Easwar and Dr. Ashwin S

DOI: https://doi.org/10.22271/ortho.2021.v7.i2i.2694

Abstract
Objectives: To assess the functional and radiological outcome of intracapsular femoral neck fractures with delayed presentation in young adults treated with cannulated cancellous screws.
Methods: A prospective study included 21 patients with intracapsular neck of femur fractures who presented after 24 hours of injury but within 3 weeks of injury for which closed reduction and fixation was done with cannulated cancellous screws in Sanjay Gandhi Institute of trauma and orthopedics, Bangalore from May 2018 to December 2019**.** Patients were followed up at 6 weeks, 3 months, 6 months and 12 months. Clinical outcome was assessed using Modified Harris hip score and radiological assessment was done using x rays.
Results: In our study we analysed the following parameters especially age, fracture type according to Garden and Pauwel, time of presentation, timing of surgery. In our study we found that patients with Pauwels type 3 (23.81%) and Gardens type 4 (42.86%) had low hip scores compared to others. 85% patients were pain free, 80% had good mobility post surgery. Incidence of non union was 2 out of 21 cases. The Modified Harris Hip Score evaluated at maximum follow-up of our patients averaged 90.13 with the maximum score being 96 and the minimum score being 67.8. Overall, 10 patients (47.62%) achieved excellent result, 6 patients (28.57%) achieved good result, 3 patients (14.29%) achieved fair result and 2 patients (9.48%) achieved poor result. 76.19% of the patients achieved either excellent or good results. According to radiographic evaluation AP view xray of pelvis with hip in 15 degree internal rotation, radiological parameters such as fracture union, non union changes, avascular necrosis of head, arthritic changes in the joint were analysed. Fracture union was seen in 19 patients (90.48%) and non union in 2 patients (9.52%). AVN changes were seen in 3 patients (14.29%). Average time of union was less than 3 months in 8 patients (44.4%), 3 to 4 months in 5 patients (27.7%), 4to 5 months in 4 patients (22.2%) and in one patient (5.55%) union achieved at 6 months.
Conclusion: We conclude that canulated cancellous screw fixation is a viable option of treatment for fractures of intracapsular neck of femur in young adults with delayed presentation, showing excellent to good functional outcome and early radiological union with minimal complications.

Keywords: functional outcome, intracapsular femoral neck fractures, delayed presentation

Introduction

Fracture of the neck of femur is a challenging injury to manage. It is often a fracture of fragility due to osteoporosis in the elderly, though in the younger age group, it usually results from high-energy trauma sustained in a road crash [1, 2]. Anatomical reduction and stable internal fixation are essentials for achieving the goals of treatment in this young population allowing preservation of the femoral head while minimizing rates of non-union and osteonecrosis [5]. However, the optimal timing for surgical fixation of these fractures is still open to debate. It is usually advocated that fracture reduction and fixation should be performed as a surgical emergency in an attempt to restore the precarious blood supply to the femoral head and prevent complications such as non-union and avascular necrosis [1-4]. A delayed presentation of fracture of the femoral neck is one where there is a delay of 48 hours to 20 days between injury and diagnosis, whereas in a neglected fracture, this delay is in excess of 21 days [7]. The main complications of such injuries are a vascular necrosis (AVN) of the femoral head and non-union of the fracture with reported average incidences of 15% for AVN and 12% for non-union [6, 7].

In these young individuals, extreme force is required to produce fracture which explains the increased incidence of AVN & nonunion. Non-union and avascular necrosis predisposes to future degenerative arthritis of the hip joint involved [8, 9].

We conducted a study to evaluate the outcome of cannulated screw fixation for femoral neck fractures in young adults with delayed presentation in our institution i.e presenting after 24 hours of injury but before 3 weeks from the time of injury. The aim was to assess the functional and radiological outcome of these fractures with delayed presentation in young adults treated with cannulated cancellous screws. Special attention was given to the time lapse from injury to surgery in relation to union and occurrence of complications such as avascular necrosis and non-union, the fracture type based on Garden and Pauwel classification and the timing of surgery.

Materials and Methods

The study was conducted in Sanjay Gandhi Institute of Trauma and Orthopedics and the study period was May 2018 to December 2020. This study was conducted to analyse the functional and radiological outcome of femoral neck fractures fixed using closed reduction and internal fixations with cannulated cancellous screws in 21 young adults (between 18 to 60 years) showing delayed presentation.

Inclusion Criteria

1. Patients more than 18 years and less than 60 years with neck of femur fractures.
2. All types of femoral neck fractures (garden types 1-4 and pauwel's type 1-3) including posterior wall comminution.
3. Patient with no other associated fractures

Exclusion Criteria

1. Patients aged above 60 years
2. Patients with bilateral neck of femur fractures
3. Patients with arthritic changes of hip joint
4. Pathological fractures
5. Patients with other associated fractures around the hip.

Operative Procedures: Closed reduction using "Lead better" technique and percutaneous cannulated screw fixation of the femoral neck fractures were performed in all our patients under either general - or regional spinal or epidural anaesthesia. During the procedure, the patient was positioned supine on a traction table with the foot secured to the footplate. The fracture was then visualised with an image intensifier. Undisplaced fractures were fixed in-situ, while displaced fractures were reduced by closed manipulation by first gently flexing and externally rotating the hip joint with in line traction applied to the femur neck(Flynn's manouver), to achieve reduction followed by gradual extension, abduction, then internal rotation of the hip joint to "lock" the reduction. Three standard cannulated (6.5mm cancellous) screws were inserted for all our patients, following the "3 Point Principle. Hip joint capsulotomy was not performed in any of the cases.

Follow up Post operatively, the patients were advised to ambulate strictly with non-weight bearing crutches until there was radiological evidence of union. Post-operative hip radiographs were taken and these patients were then followed up till there was evidence of radiological union. Documented incidence of non-union and avascular necrosis were noted and analysed individually in relation to the following risk factors: Age of patient, elapsed time between injury and surgery, presence of posterior comminution, type of fracture and anatomical location of fractures.

Age of patient was taken as the age on day of admission to the hospital. Elapsed time was calculated from time of injury to starting time of surgery. Posterior comminution was detected either during surgery under image intensifier or post operatively in plain radiographs as it is sometimes not easy to detect on initial radiograph. Fractures were classified based on Garden's (4 types) and Pauwel's (3 types). Anatomical location of fracture was divided into subcapital, transcervical or base of neck.

A detailed history of patient regarding, age, sex, mode of injury, duration, associated injuries, past history, clinical examination and radiological examination were done. X-Ray pelvis with both hip-Antero-Posterior view in 15° internal rotation was also performed.

X-Ray of affected hip (lateral view) was performed to observe site of fracture, type of fracture (Anatomical, Pauwel's type), and pre- operative drawing, quality of bone, amount of neck absorption and degree of posterior comminution. MRI was done to assess the vascularity of femoral head.

All cases were followed up at monthly interval after surgery for 6 months and then at three monthly intervals for next 6 months, then 6 monthly interval and results were evaluated using Modified Harris Hip Scoring System (HHS). Grading for the Harris Hip Score was taken as Poor (<70), Fair (70-79), Good (80-89) and Excellent (>90)

Avascular necrosis of femoral head was identified based on radiological evidence and clinical features, using Ficat and Arlet classification.

Good outcome was defined radiologically as fracture union with no evidence of non-union or avascular necrosis. Statistical analysis was performed using Pearson Chi square test and Fischer's exact test. A p value of less than 0.05 was considered to be statistically significant.

Results: In our study period, there were 21 cases of neck of femur fracture who showed a delayed presentation. Out of this 15 were males (71.43%) and 6 were females (28.57%).

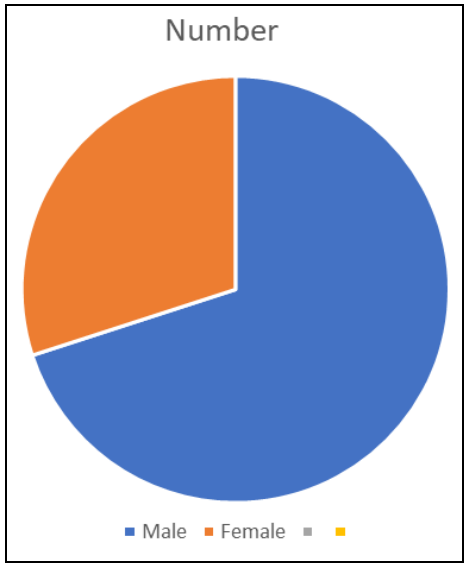

Chart 1: Sex distribution

Majority of the patients were in the age group of 30 to 46 years, with the mean age of 34.90 years (Age range- 18 to 60 years). 12 patients had sustained fracture of the right side (57.14%) and 9 patients had fracture of the left side (42.86%).

Radiographs taken at the time of admission showed 11 trans

cervical, 7 sub capital type and 3 basi cervical type of fractures. 9 patients had Garden's type 4 (42.86%), 8 patients had Garden's type 3 (38.09%), 3 patients had Garden's type 2 (14.29%) and 1 patient had Garden's type 1 fracture (4.76%).

The angle of inclination of the fracture line was Pauwels's type 1(<30 degree) in 7 patients (33.33%), Pauwel's type 2(30-50 degree) in 9 patients (42.86%) and Pauwel's type3in 5 patients (23.81%).

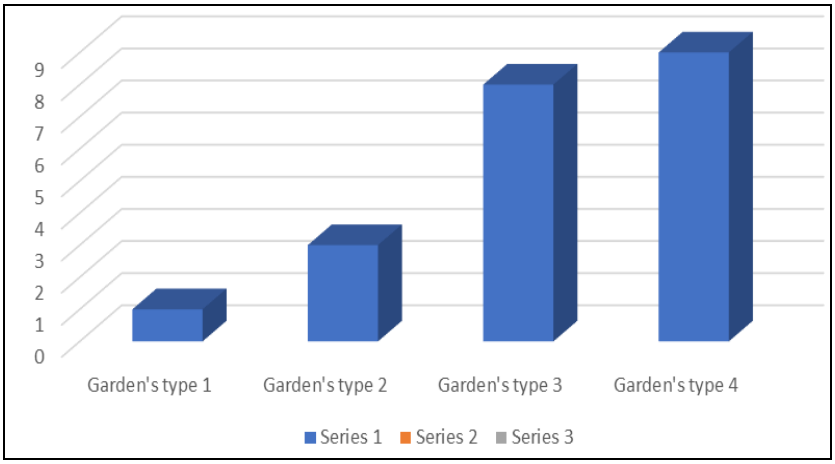

Chart 2: Garden's classification distribution

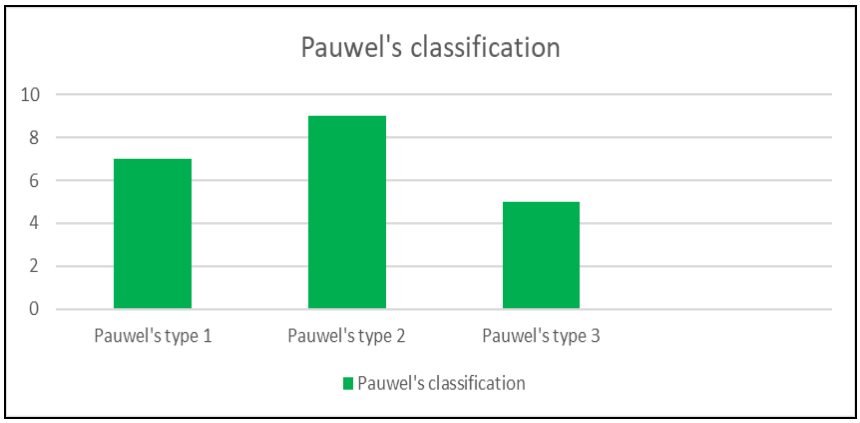

Chart 3: *Pauwel's classfication distribution*

While 12 patients presented between 24-72 hours of injury, 6 patients presented between 3 to days post injury and 3 patients presented to us between 1 to 3 weeks of injury.

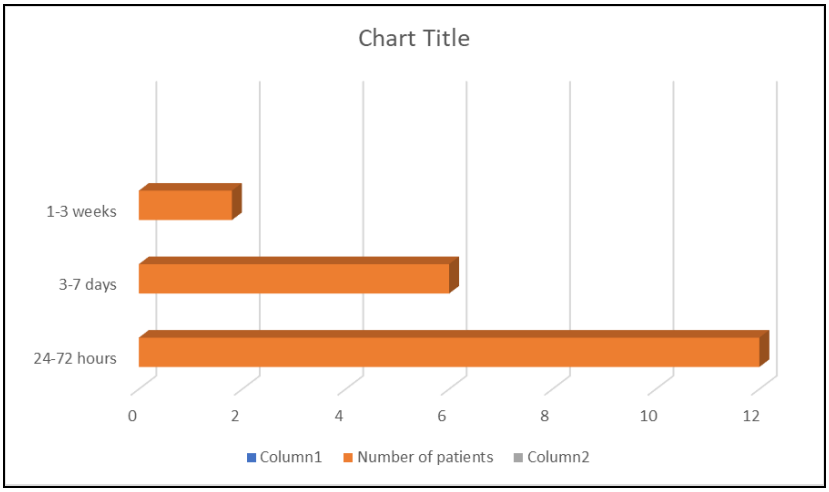

Chart 4: Time of presentation

Outcomes were analysed using Modified Harris hip scores. At the end of the 12 month follow up period, in our study out of 21 patients, 17 (80.95%) were pain free, 3 (14.29%) patients had mild pain, and 1(4.76%) patient had moderate pain. 2 (9.48%) patients had moderate limp, 2 (9.48%) had slight limp while 17 patients (80.95%) had no limp. 15 patients (71.43%) were found to be ambulating without the help of any support and the remaining 6 patients (28.57%) needed some support in the form of a cane or walker for a long walk. 16 (76.19%) of the study patients could walk an unlimited distance at any given point of time while 3 patients (14.29%) could walk no more than 1000 meters at a time and 2 patients

(9.48%) could only manage 500 meters at a time. On evaluation of the patients ability to climb stairs, it was found that 15 patients (71.43%) were able to climb stairs without the use of any support or railing while 3 patients (14.29%) were able to do so with the support of the railing, 2 patients (9.48%) not able to climb. As far as the ability to sit on chair for a long duration was concerned, it was found that 17 (80.95%) of the study patients were able to sit comfortably on a chair for upto one hour while 4 patients (18.96%) were not able to sit on a chair for more than half an hour at a stretch.

The Modified Harris Hip Score evaluated at maximum follow-up of our patients averaged 90.13 with the maximum score being 96 and the minimum score being 67.8. Overall, 10 patients (47.62%) achieved excellent result, 6 patients (28.57%) achieved good result, 3 patients (14.29%) achieved fair result and 2 patients (9.48%) achieved poor result. 76.19% of the patients achieved either excellent or good results.

Table 1. Functional outcome using Modified Harris Hip score

Grade	Modified Harris Hip Score	Number Of Patients	Percentage
Excellent	90-100	10	47.62
Good	80-89	6	28.57
Fair	70-79	3	14.29
Por	<70	2	9.48

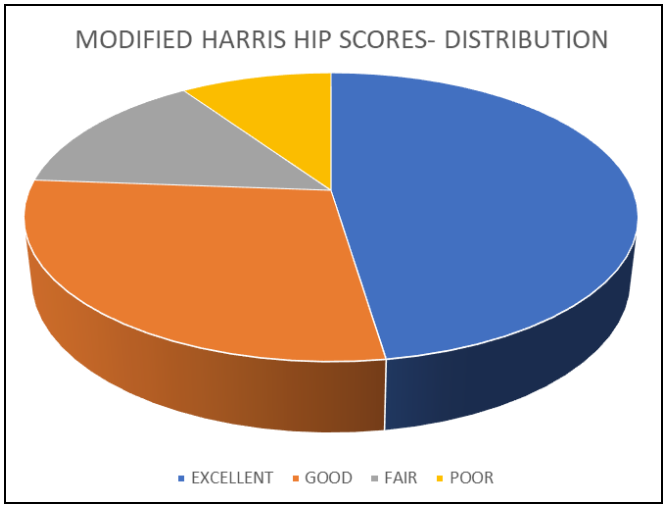

Chart 5: Modified Harris hip scores distribution

Radiological Analysis: On analyzing the anteroposterior view x ray of pelvis with hip in 15 degrees of internal rotation the radiological parameters such as fracture union, non-union changes, avascular necrosis in head, arthritic changes in the joint were analysed. Fracture union was seen in 19 patients and nonunion in 2 patients. The average time of union was less than 3 months in 8 patients (38.10%), 3 to 4 months in 5 patients (23.81%), 4 to 5 months in 4 patients (19.05%) and in 1 patient (4.76%) union was achieved at 5 ½ months.

The position of the screws and the fracture site alignment were assessed by comparing the final follow up x-ray with immediate post op x-ray to decide about the fixation failure using following criteria: (1) more than 10 mm displacement (2) progression to varus angulation (3) more than 5% change between the axis of the screws (4) more than 20 mm of posterior translation, and (5) femoral head perforation. Based on this criteria, we had 2 cases of fixation failure which later on resulted in non-union.

At the end of the follow up period, 3 cases showed avascular necrosis of the femoral head (14.29%)

Discussion

Fractures of femoral neck remain a challenge in the clinical practice of orthopaedic surgeons. It is still a subject of debates over the years with regards its management. Generally, the accepted mode of treatment is internal fixation either by open or closed reduction in younger patients and patients without degenerative changes in the hip joint. Total hip replacement is generally a preferred option for patients with pre-existing degenerative changes in the hip. The primary aim of internal fixation in these fractures is to achieve anatomical reduction in order to restore or preserve the precarious blood supply to the head of femur, more so in the younger age group and prevention of future complications such as avascular necrosis and non-union. Stable anatomical reduction can be achieved by means of three standard cannulated screws (6.5mm cancellous) inserted according to the "3 Point Principle".

Fracture of the neck of the femur is traditionally treated by an emergency operation. Swiontkowski *et al* [20], in a series of 27 patients belonging to a similar age group, achieved union of 100% when surgery was performed within eight hours of the injury. This high rate of union may have been influenced by the number (30%) of undisplaced Garden grade II fractures among their patients. However, 20% of the patients developed AVN. Zetterberg *et al* [21] and Bray [22] also suggested that the timing of surgery after injury was an important factor in influencing the outcome.

Most contemporary studies do not identify an association between time to surgery and development of AVN or nonunion. Haideukewych *et al* [23] retrospectively compared 73 patients between ages 15–50 treated for femoral neck fractures. Those patients treated within 24 hours of injury demonstrated AVN 23 % of the time, and 7 % developed nonunions. Those treated after 24 hours developed AVN 20 % of the time and 10 % developed nonunion. Upadhyay [24] evaluated 92 patients less than 50 years old with femoral neck fractures and overall rate of AVN of 16 % with no difference in treatment before or after 48 hours.

The overall incidence of avascular necrosis in our series was 14.29%, which is comparable with the majority of previous published data (ranging from 10% - 30%) [1-4]. Avascular necrosis of the head of femur leads to segmental collapse of the head which predispose to secondary hip joint degenerative changes, necessitating subsequent revision or joint replacement surgery.

Urgent reduction and stable fixation of femoral neck fracture less than six hours after injury has been shown to reduce the risk of avascular necrosis [10]. Jain reported that time to reduction of the fracture was found to be the only significant contributing factor, though others have shown no difference between early or later surgery [11]. However this is not statistically significant due to the small number of cases.

Majority of the blood supply to the femoral head comes from the medial and lateral femoral circumflex arteries with minimal contribution from the obturator vessels [12, 13]. In our study, we noticed that out of the 3 cases of avascular necrosis, 2 were seen in transcervical type and 1 was seen in

basicervical type of fracture. More importantly, all 10 cases of subcapital fractures in our study – did not develop subsequent avascular necrosis. The transcervical region and the basal region of the neck is the watershed area between the blood supply from the femoral head and the shaft of the femur, and therefore having a relatively poorer blood supply. Once the epiphysis is closed, there is no more intra-osseous anastomosis between branches of epiphyseal artery and metaphyseal artery, leaving a potential watershed zone within the subcapital region. Furthermore this segment is intracapsular and therefore has no periosteum [12, 13].

Strong relationship is reported in the literature between the risks of avascular necrosis in displaced intracapsular fractures compared to undisplaced femoral neck fractures [14-16]. Asnis & Wanek-Sgaglione [17] reported an incidence of avascular necrosis of almost 20% in undisplaced fractures (Garden II) in their study. We found no significant difference between displaced and undisplaced fracture with regard to future risk of avascular necrosis in our study. We postulate that the initial force sustained at the proximal femur during the causal injury is directly related to the fate of the head of femur in terms of future avascular necrosis. The vascularity of the head could have been disrupted from the initial trauma, therefore the adequacy of reduction did not influence the rate of avascular necrosis. Tooke & Favero KJ [23] and Protzman & Burkhalter [24] also echoed similar view in their reports.

The period defined in the literature for occurrence of bone union after osteosynthesis of femoral neck fractures is usually within 3 months post operation, and all complications related to mechanical and/or biological deficiencies, called with the collective term non -union, occur within 6 months, including failure of fixation and pseudoarthrosis. Therefore, we assumed a minimal follow-up period of 12 months as sufficient to demonstrate occurrence of bone union and other associated complications [25].

In our study, at the end of the follow up period, fracture union was seen in 19 patients (90.48%) and non union in 2 patients (9.52%). Average time of fracture union was less than 3 months in 8 patients (38.09%), 3 to 4 months in 6 patients (28.57%), 4 to 5 months in 4 patients (19.05%) and in one patient (4.76%) union achieved at 6 months.

In our study, we analysed the following parameters especially: age, fracture type according to Garden and Pauwel, time of presentation, timing of surgery with functional outcome of the patient.

In a study by Karl Stoffel *et al*., in addition to evaluation of clinical results by HHS, important parameters namely: age, gender, relief of pain (good, poor), mobility (good, poor) and putting on socks and shoes skills (easy, difficult), degree of fracture displacement, incidence of AVN were analysed. He concluded that among all 207 patients, the Harris hip score was 86.2 ± 18.9 (range 10–100), with no significant difference between genders. This score was significantly higher for patients with Garden III versus Garden IV fractures. Also Harris hip score was significantly lower, for patients with poor versus good relief of pain, as well as in cases with poor versus good mobility and for patients declaring difficult versus easy putting on socks and shoes skills [26].

In our study we found that. With regarding to time of presentation and functional outcome, 12 patients who presented between 24 hrs and 72 hrs of injury and operated earlier had good functional outcome with average Harris hip score of 92.07%. Our study shows that patients with Pauwels type 3 (23.81%), and garden type 4 (42.86%) had lower Harris hip score in comparison to other types.

Karl Stoffel *et al*., highlighted that 88.4% were pain free, 83.6% had good mobility, 80.7% of patient were able to put shoes and socks with ease. [26] In our study out of 21 patients, 80.95% were pain free, 76.19% had good mobility, 80.95% of patients were able to put socks and shoes with ease.

Incidence of non-union in operated patients in Orlin Filipov study was 6 out of 83 patients (7.2%) [27] 79 In our study the incidence of non union was 2 out of 21 cases (9.52%).

Fig 1: Pre op Xray -35y male

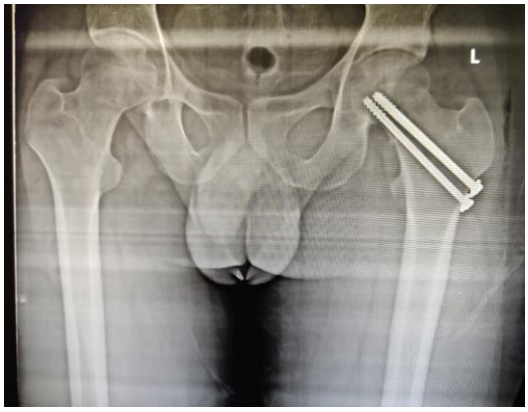

Fig 2: Immediate post op Xray

Fig 3: Intra operative fluoroscopy image (AP)

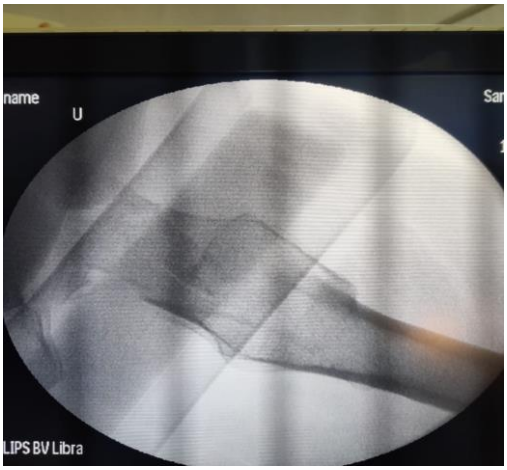

Fig 4: Intra operative Fluorosopy Image (lateral)

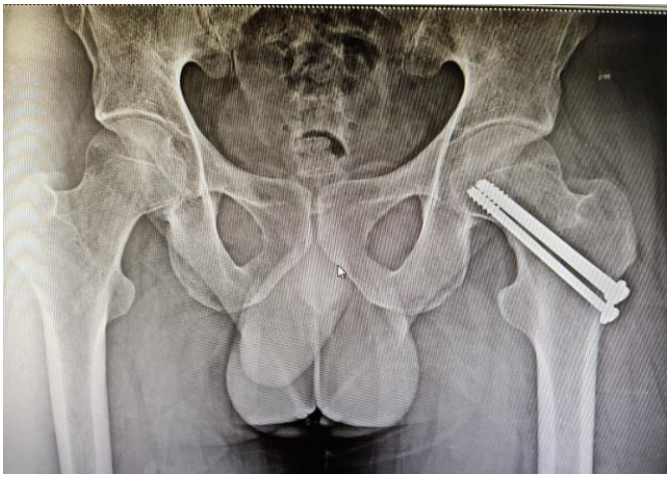

Fig 5: At 3 months follow up

Fig 6: At 1 year follow up

Fig 7-10: Clinical outcome at the end of 1 year post operatively

Conclusion

Fracture neck of femur in young individuals with a delayed presentation is a challenging orthopedic scenario. However functional and radiological outcomes were similar to the early fixation groups at an average of 12 months follow up. Longer and more complete functional and radiographic follow-up is required to evaluate the functional consequences and risk of avascular necrosis over time. However, the small sample size is a short coming of this study . Hence a large multicenteric prospective trial with long term follow up is warranted to establish the long term functional outcomes.

We conclude that canulated cancellous screw fixation is a viable option of treatment for fractures of intracapsular neck of femur in young adults with delayed presentation, showing excellent to good functional outcome and early radiological union with minimal complications.

References

1. Cserhati P, Kazar G, Manninger J. Non-operative or operative treatment for undisplaced femoral neck fractures: a comparative study of 122 non-operative and 125 operatively treated cases. Injury 1996;27:583-588. [PubMed] [Google Scholar]
2. Haidukewych GJ, Rothwell WS, Jacofsky DJ. Operative

treatment of femoral neck fractures in patients between the ages of fifteen and fifty years. J Bone Joint Surg Am 2004;86:1711-1716. [PubMed] [Google Scholar]
3. Rogmark C, Flensburg L, Fredin H. Undisplaced femoral neck fractures – no problems? A consecutive study of 224 patients treated with internal fixation. Injury 2009;40:274-276. [PubMed] [Google Scholar]
4. Angelini M, McKee MD, Waddell JP. Salvage of failed hip fracture fixation. J Orthop Trauma 2009;23:472-478.
5. Pauwels F. Gesammete Abhandungen zur funktionellen Anatomie des Bewegungs apparates. Berlin, Springer 1965
6. Wang SH, Yang JJ, Shen HC, Lin LC, Lee MS *et al*. Using a modified Pauwels method to predict the outcome of femoral neck fracture in relatively young patients. Injury 2015;46(10):1969-1974
7. ELzohairy MM, Eid A. Meta analysis of different methods used for joint preserving procedures in the management of delayed, neglected and non-united femoral neck fractures in young adults. Trauma 2016;18(4):245-249.
8. Bhandari M, Devereaux PJ, Swiontkowski MF. Internal fixation compared with arthroplasty for displaced fractures of the femoral neck. A meta-analysis. J Bone Joint Surg Am 2003;85:1673-1681. [PubMed] [Google Scholar]
9. Bosch U, Schreiber T, Krettek C. Reduction and fixation of displaced intracapsular fractures of the proximal femur. Clin Orthop Relat Res 2002;399:59-71.
10. Jain R, Koo M, Kreder HJ. Comparison of early & delayed fixation of subcapital hip fractures in patients sixty years of age or less. J Bone Joint Surg. 2002;84:1605-1612. [PubMed] [Google Scholar]
11. Manninger J, Kazar G, Fekete G. Significance of urgent (within 6 hrs) internal fixation in the management of fractures of the neck of the femur. Injury. 1989;2:101-105.
12. Trueta J, Harrison MHM. The normal vascular anatomy of the femoral head in adult man. Bone Joint Surg Br. 1953;35:442-461. [PubMed] [Google Scholar]
13. Sevitt S, Thompson G. The distribution and anastomoses of arteries supplying the head and neck of the femur. J Bone Joint Surg Br. 1965;47:560-573.
14. Barnes R, Brown JT, Garden RS, Nicoll EA. Subcapital fractures of the femur. A prospective review. J Bone Joint Surg Br. 1976;58:2-24. [PubMed] [Google Scholar]
15. Shih CH, Wang KC. Femoral neck fractures. 121 cases treated by Knowles pinning. Clin Orthop Relat Res 1991;271:195-200.
16. Nikolopoulos KE, Papadakis SA, Kateros KT. Long-term outcome of patients with avascular necrosis, after internal fixation of femoral neck fractures. Injury. 2003;34:525-528
17. Asnis SE, Wanek-Sgaglione L. Intracapsular fractures of the femoral neck: results of cannulated screw fixation. J Bone Joint Surg Am 1994;76:1793-1803.
18. Tooke MT, Favero KJ. Femoral neck fractures in skeletally mature patient, fifty years old or less. J Bone Joint Surg Am. 1985;67:1255-1260. [PubMed] [Google Scholar]
19. Protzman RR, Burkhalter WE. Femoral neck fractures in young adults. J Bone Joint Surg Am. 1976;58:689-695.
20. Swiontkowski MF, Winquist RA, Hansen Jr ST. Fractures of the femoral neck in patients between the ages of twelve and forty-nine years. J Bone Joint Surg Am. 1984;66:837-46
21. Zetterberg CH, Irstam L, Andersson GBJ. Femoral neck fractures in young adults. Acta Orthop Scand 1982;53:427-35
22. Bray TJ. Femoral neck fracture fixation. Clin Orthop 1997;339:20-31
23. Haidukewych GJ, Rothwell WS, Jacofsky DJ, Torchia ME, Berry DJ. Operative treatment of femoral neck fractures in patients between the ages of fifteen and fifty years. J Bone Joint Surg Am 2004;86:1711-6. This retrospective study is one of the more recent ones looking at the correlation of timing to surgery and outcomes of AVN and nonunion in young patients
24. Upadhyay A, Jain P, Mishra P *et al*. Delayed internal fixation of fractures of the neck of the femur in young adults. A prospective, randomised study comparing closed and open reduction. J Bone Joint Surg Br. 2004;86(7):1035-40
25. Filipov O. Biplane double-supported screw fixation (F-technique): a method of screw fixation at osteoporotic fractures of the femoral neck. Eur J Orthop Surg Traumatol 2011;21(7):539-543.
26. Femoral neck fracture osteosynthesis by the biplane double supported screw fixation method (BDSF) reduces the risk of fixation failure: clinical outcomes in 207 patients Orlin Filipov1 Karl Stoffel 2 Boyko Gueorguiev3 · Christoph Sommer4: Arch Orthop Trauma Surg DOI 10.1007/s00402-017-2689-8
27. Filipov O. The method of biplane double-supported screw fixation (BDSF) at femoral neck fractures-principle and clinical outcomes. J of IMAB 2013;19(1):423-428.