


**E-ISSN:** 2395-1958
**P-ISSN:** 2706-6630
IJOS 2021; 7(2): 705-711

www.orthopaper.com
Received: 28-02-2021
Accepted: 30-03-2021

**Dr. Ankit Dhaka**
Central Institute of Orthopaedics, VMMC and Safdarjung Hospital, New Delhi, India

**Dr. Laxmish R**
Senior Resident, Central Institute of Orthopaedics, VMMC and Safdarjung Hospital, New Delhi, India

**Dr. Davinder Singh**
Professor, Central Institute of Orthopaedics, VMMC and Safdarjung Hospital, New Delhi, India

**Corresponding Author:**
**Dr. Laxmish R**
Senior Resident, Central Institute of Orthopaedics, VMMC and Safdarjung Hospital, New Delhi, India

# Clinical and functional outcome of arthroscopic management of intra articular elbow disorders

**Dr. Ankit Dhaka, Dr. Laxmish R and Dr. Davinder Singh**

**DOI:** https://doi.org/10.22271/ortho.2021.v7.i2i.2695

**Abstract**
The elbow is a highly constrained synovial hinge joint that frequently becomes stiff after injury. Elbow stiffness is defined as flexion <120° and loss of extension >30°. Trauma is a common cause of stiffness in the elbow joint with rates ranging from 3% to 20. Elbow motion is required so that the hand can be properly positioned for activities of daily living. For this reason, joint contractures at the elbow can be poorly tolerated. Elbow arthroscopy is a valuable tool for both diagnostic and therapeutic purpose. Minimal invasiveness and effective rehabilitation after the surgery helps the patient achieve an early recovery and facilitates return to normal activities of daily living. This study was conducted to determine the clinical and functional outcome of arthroscopic management of Intra articular elbow disorders among 30 patients by Arthroscopic fibrolysis. From our study we can conclude that, elbow arthroscopy is an excellent surgical treatment for intra articular elbow disorder in selected patients resistant to conservative management.

**Keywords:** elbow stiffness, mayo score, visual analogue score

## Introduction
The elbow joint is a modified hinge joint, comprised of three articulations and contained within one synovial lining. The three articulations are the ulnotrochlear joint, the radiocapitellar joint, and the proximal radioulnar joint [1]. Elbow stability is provided by static and dynamic constraints. The static part is mainly provided by the congruency between the articulating surfaces at the elbow joint. The other static stabilizers are the anterior joint capsule, the medial and lateral collateral ligaments and the interosseous membrane. The dynamic part includes the muscles that cross the elbow joint [2]. The soft tissue boundary of the elbow joint is the articular capsule, which is weakest anteriorly and posteriorly but has well-defined lateral and medial ligamentous complexes. The functional arc of elbow motion during activities of daily living to be 100° for both flexion-extension (30° to 130°) and pronation-supination (50° in either direction). Limitation in range of motion (ROM) of the elbow leads to impaired arm function and can interfere with patient's daily life activities. The elbow is a highly constrained synovial hinge joint that frequently becomes stiff after injury. Elbow contracture is challenging to treat, and therefore prevention is of paramount importance.
Elbow stiffness results from abnormalities of bone, soft tissue, or a combination of both that may or may not follow a traumatic event. The etiology of elbow stiffness is the basis of its classification, diagnosis, prevention, and treatment. Although it is known that elbow trauma can result in joint contracture, the rate and progression of this contracture have not been well documented.
Traumatic causes of elbow stiffness include fractures, dislocations, soft tissue crush or burns, and head injury with a degree of stiffness that is typically directly proportional to the severity of the insult. Elective elbow surgery results in controlled trauma to the tissues and may also be complicated by postoperative stiffness. Atraumatic causes of elbow stiffness include rheumatoid arthritis, osteoarthritis, post-septic arthritis, multiple hemarthroses in hemophiliacs, and congenital contractures.
Elbow arthroscopy is a technically demanding procedure; however, as experience has been gained, arthroscopic release of the stiff elbow has become feasible. A sound knowledge of the neurovascular anatomy is mandatory in order to prevent the most severe complication,

a neurologic injury to the posterior interosseous or ulnar nerves.

Common elbow disorder which can be managed arthroscopically include: loose bodies, posterior impingement, osteochondritis dessicans, lateral epicondylitis, persistent synovitis, stiff elbow.

Elbow arthroscopy is usually used for diagnostic purposes, loose body extraction, arthrolysis and osteophyte resection. It is also frequently used in rheumatoid elbow when synovectomy is required. As degenerative arthritis is usually accompanied by osteophyte formation, loose bodies and capsular retraction, these patients are more frequently potential candidates to this kind of surgery. It is known to offer better visualization of the elbow joint, less post-operative pain, lower infection rates and decreased scarring than open surgery.

## Materials and Methods

A prospective interventional type of study design was carried out at a tertiary center at New Delhi, and was conducted over a period of one and half years which included 30 patients with complaint related to elbow joint.

### Inclusion criteria

- Post traumatic stiffness.
- Synovitis.
- Arthrofibrosis of elbow joint.
- Loose bodies.
- Fracture around elbow joint which can be managed arthroscopically.

### Exclusion criteria

- Bony ankylosis.
- Previous surgery that have altered normal elbow anatomy.
- Skin infection at site of incision.
- Stiffness due to primary osteoarthrosis, burns.

30 patients of fixed flexion deformity of elbow who met inclusion criteria were taken up for study and are subjected to elbow arthroscopy. Roentgenographic X-ray included x ray in anteroposterior and lateral view and magnetic resonance imaging of elbow is done of all patients.

An informed written consent, a detailed clinical history, careful examination of patients for instability of Elbow joint, range of motion, deformity, neurovascular status, and muscle charting and finding are noted in a predesigned proforma. Radiological assessment is done using anteroposterior and lateral view radiograph and magnetic resonance imaging was done and all finding were noted. Computed tomography of elbow was done whenever required.

Pre-operative investigation including haemoglobin, serum electrolyte, random blood sugar, blood urea, urine routine and microscopic examination and chest x ray were done as a part of pre anaesthetic evaluation. Prophylactic antibiotics was given 15 min prior to surgery.

### Instrumentation used

- Viewing monitor
- Powered instrument driver
- LED light source
- HD camera source
- Irrigation system
- No. 11 knife blade
- Blunt trocar and cannula
- 30° arthroscope-2.7 & 4 mm
- 16G I.V. cannula
- Wissinger rod
- Arthroscopic probe
- Motorized shaver and burr

### Procedure

All patients are operated in the lateral decubitus position on a standard operating room table under General Anaesthesia. A tourniquet is used to control bleeding and is placed as high as possible on the arm to avoid crowding the operative field. Before insufflating the joint, bony landmarks and the ulnar nerve is marked. After painting and draping elbow joint is distended though direct lateral portal with 20 ml of saline. Direct Lateral port was located in the lateral soft spot where effusion are visible, palpable and often aspirated. The portal was located in the centre of triangle formed by lateral epicondyle, radial head, and tip of olecranon. Intra-articular placement of the saline is confirmed by slight extension and supination of the arm that occurs with capsular inflation. Removing the syringe from the needle demonstrated fluid backflow from the needle, also confirming intra-articular fluid placement.

### Various portals of elbow include

1. Anterolateral port: Which are used include
   a) Distal antero lateral portal: 2-3 cm distal and 1 cm anterior to the lateral epicondyle.
   b) Mid anterolateral portal: Just proximal and 1 cm anterior to the palpable radiocapitellar Joint.

2. Anteromedial port is located 2cm distal and 2 cm anterior to the medial epicondyle and is used to visualize radioulnar, radiocapitellar articulation and annular ligament. Anterolateral capsule and gutter were examined for synovitis. Arthroscope was swept more proximally to observe the anticipated site of establishment of poster lateral port. The anterior compartment is examined using an anteromedial portal after a careful palpation of the ulnar nerve and intermuscular septum; a second anterolateral portal is created outside-in.
3. Posterolateral port is located 2-3 cm proximal to the olecranon tip and just lateral to the border of the triceps tendon along the supracondylar ridge. It is used for the visualization of olecranon fossa, olecranon tip and posterior trochlea used to debride posterior compartment.
4. Straight posterior port is placed 2-3 cm proximal to olecranon tip and approximately 2cm medial to the posterolateral portal.

Following saline distention of elbow joint, 18 gauze needle is inserted medially and posteriorly toward the center of elbow joint to confirm the mid anterolateral portal. Using an 11 number blade skin incision is made and soft tissue was dissected to area of joint capsule. Blunt trocar is used to enter joint. Trocar is used to capture the capsule just anterior and proximal to capitellum directed toward center of joint. The joint is palpated with trocar to confirm the intra articular placement of the trocar. Joint is carefully examined, radial head is inspected and movement is checked by pronating and supinating the hand. The concavity of radial head is examined articulating with the convex capitellum. Anterior fibrous tissue is fully debrided using a combination of full radius resector and electro cautery through anteromedial and anterolateral portals. Coronoid fossa is inspected for

impingement if found was relieved by resecting its tip and if osteophyte were found removed using burr. The posterior compartment was found full of synovitis debrided using direct posterior port and a posterolateral port was made under direct vision. Usually abundant synovitis is present posteriorly for which debridement is done to improve visualization and olecranon fossa is inspected for osteophyte and if present tip of olecranon was resected using motorized burr and impingement was checked by flexion and extension. Full radial resector was used and minimal mobilization was done to release the posterolateral and postero medial gutter. Once the procedure is complete thorough wash was given and portals were closed using nylon suture. After dressing elbow was mobilized under anesthesia to gain maximal range of motion.

All patients are placed in sling and isometric exercise is started immediately in post-operative period. Range of motion and muscle strengthening exercise are started at 1-3rd week. Patients are followed for 1st and 3rd month. Post-Operative Assessment is performed using Mayo elbow performance scale and pain is assessed using visual analogue scale. Follow-up done at 1st and 3rd month and are evaluated according to the rating scale of Mayo elbow performance scale and Visual Analogue scale. Patients are graded as excellent, good, fair or poor depending on the score obtained.

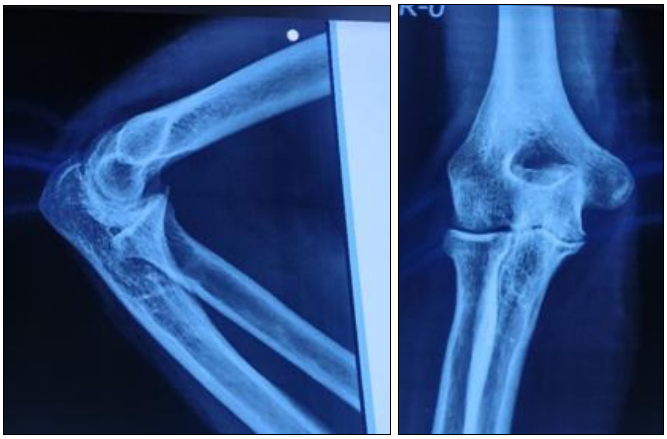

**Fig 1:** Radiograph showing arthritic elbow joint


**Fig 2:** MRI showing synovial hypertrophy


**Fig 3:** Pre-operation condition


**Fig 4:** Post-operation condition

**Statistical analysis**

Categorical variables were presented in number and percentage (%) and continuous variables were presented as mean ± SD and median. Normality of data was tested by Kolmogorov-Smirnov test. If the normality was rejected then non parametric test was used.

Statistical tests were applied as follows:

1. Quantitative variables were compared using Wilcoxon Test (as the data sets were not normally distributed) across follow up.
2. Qualitative variables were correlated using Chi-Square test.
3. A p value of <0.05 was considered statistically significant.
4. The data was entered in MS Excel spreadsheet and analysis was done using Statistical Package for Social Sciences (SPSS) version 21.0.

**Results**

In this study we gave our primary concern in patient selection and all surgeries were performed by same surgeon and with same instruments. The age of the patients included in our study ranges from 16-60 years with the mean age being 35.63 ± 12.39 years (mean ± SD). Maximum number of patients were in the age group of 21-40 years with the median age being 34 years. The male and female ratio was 2:1. Out of 30 patients, 18 patients had complaint over right elbow and 12 patients had over left elbow. Out of the 30 patients, 24 were right handed and 6 were left handed. 10 patients had degenerative origin of elbow stiffness while remaining 20 patients had traumatic cause of elbow stiffness**.** Mean duration of symptoms before patients were taken up for arthroscopic intervention was 7.87 ± 3.28 months (mean ± SD.). Most of the patients in the study had duration of symptoms 3-12 months with all of them undergoing Arthroscopic arthrolysis. The mean pre-op mayo pain score was 13.5 with the highest value being 30 and the lowest being 0. The score increased by 6.5 in 1 month to reach 20 and by 28 in 3 months to reach 41.5. The mean post-op 3 months pain score was 41.5. Total increase from pre-op period was 28 with the highest value being 45 and the lowest being 30. The post op mean mayo pain score at 3 month (41.5 ± 6.45) was significantly higher ($p$<0.0001) than pre op pain score (13.5 ± 7.21). The mean pre-op function score was 16.67 with the highest value being 25 and the lowest being 10. The score was increased by 7 at end of month to reach 23.67 and by 7.16 in 3 months to reach 23.83. The mean post op 3 month function score was 23.83. Total increase from pre op period was 7.16. The highest value being 25 and the lowest value being 20. The post op mean mayo function score at 3 month (28.83 ± 3.3) was significantly higher ($P$<0.0001) than the pre-op mean Mayo function score (16.67 ± 3.3). The mean pre-op motion score was 8.33 +- 4.79 with the highest value being 15 and the lowest being 5. The score increased by 9 in 1 month to reach 17.33 and by 11.67 in 3 months to reach 20. The mean post-op 3 months flexion score was 20. Total mean increase from pre-op period was 11.67 with the highest value being 5 and the lowest being 20. The mean post-op motion score at 3 months (20 ± 0) was significantly higher ($P$<0.0001) than the mean pre-op motion score (8.33 ± 4.79). The mean mayo pre-op stability score was 9.17 with the highest value being 10 and the lowest being 5. The score increased by 0.83 in 1 month to reach 10 and but no increase was there at 3 month follow-up. The mean post-op 3 months stability score was 10. Total mean increase from pre-op period was 0.83 with the highest value being 10 and the lowest being 5. The mean post op stability score at 3 month (10 ± 0) was not significantly higher (p = 0.025) than the mean pre op stability score (9.17 ± 1.9). The mean pre-op mayo elbow performance score was 48.67 with the highest value being 70 and the lowest being 40. The score increased by 22.33 in 1 month to reach 71 and by 2.39 in 46.66 months to reach 95.33. The mean post-op 3 months mayo performance score was 95.33. Total mean increase from pre-op period was 46.66 with the highest value being 100 and the lowest being 40. The post op patient mayo performance score at 3 month (95.33 ± 6.15) was significantly higher ($P$<0.0001) than the pre op patient mayo performance score (48.67 ± 6.94). The mean pre op flexion movement was 87.33 +- 12.3 with highest being 110 and the lowest being 70.The flexion movement was increased by 19 in 1 month to reach 106.33 and by 39.34 to reach 126.67. The mean post op 3month flexion movement score was 126.67. Total increase from pre op period was 39.34 with highest value being 140 and lowest value being 70**.** The mean post op flexion movement at 3 month (126.67 ± 10.2) was significantly higher ($P$<0.0001) than mean pre op flexion movement (87.33 ± 12.3). The mean pre op extension movement was -42.83 with highest being -35 and the lowest being -50. The extension movement was increased by 17.33 in 1 month to reach -25.5 and by 38.83 to reach -4. The mean post op 3month extension score was movement score was -4. Total

increase from pre op period was 38.83 with highest value being 0 and lowest value being -50. The mean post op extension movement at 3 month (-4 ± -3.57) was significantly higher ($P$<0.0001) that mean pre op extension movement. (-42.83 ± -4.68). The mean pre-op Visual Analog Score (VAS) was 9.1 with the highest value being 10 and the lowest being 8. The VAS score decreased by 3.73 in 1 month to reach 5.4 and by 7.43 in 3 months to reach 1.7. The mean post-op 3 months VAS score was 1.7. Total increase from pre-op period was 7.43 with the highest value being 10 and the lowest being 1. The mean post VAS score at 3 month (1.7 ± 0.75) was significantly higher ($P$<0.0001) that mean pre op VAS score. (9.13 ± 0.82).

**Flexion movement observation**

In our study out of 30 patients, preoperatively, 5 (16.67%) patients ad $70^0$ flexion, 8 (26.67%) had $80^0$, 11 (36.67%) had $90^0$ flexion, 2 (6.67%) had $100^0$ flexion, 4 (13.33%) had $110^0$. In post-operative at 3 month follow up 1 (3.33%) had $100^0$ flexion, 3 (10.00%) had $110^0$, 7 (23.33%) had $120^0$, 12 (40.00%) had $130^0$, 2 (6.67%) had $135^0$, 5 (16.67%) P value is <0.0001 and is statistically significant.

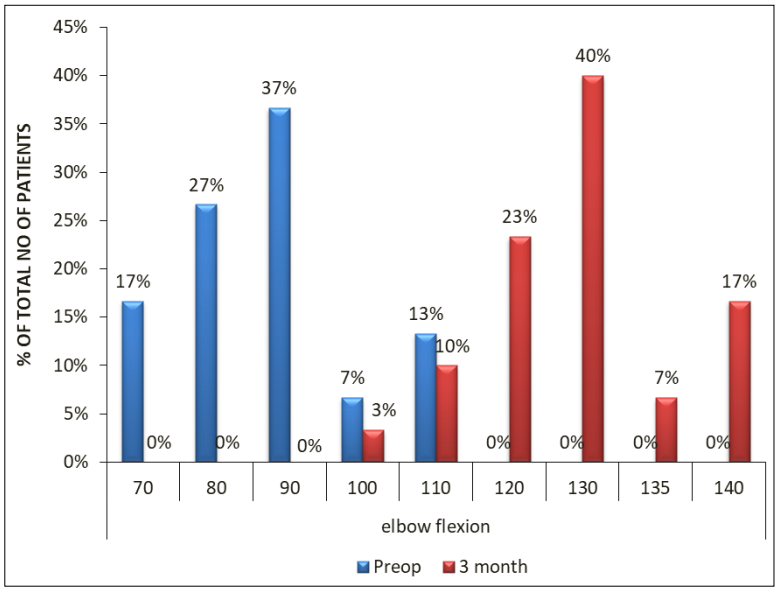


**Fig 5:** Elbow flexion * Group

**Extension movement observation**

In our study out of 30 patients, pre operatively 4 (13.33%) had $-50^0$ extension, 14 (46.67%) had $-45^0$, 7 (23.33%) had $-35^0$ extension. Post operatively 5 (16.67%) had $-10^0$ extension, 14 (46.67%) had $-5^0$, 11 (36.67%) had $0^0$ extension. P value is <0.0001 and is statistically significant.

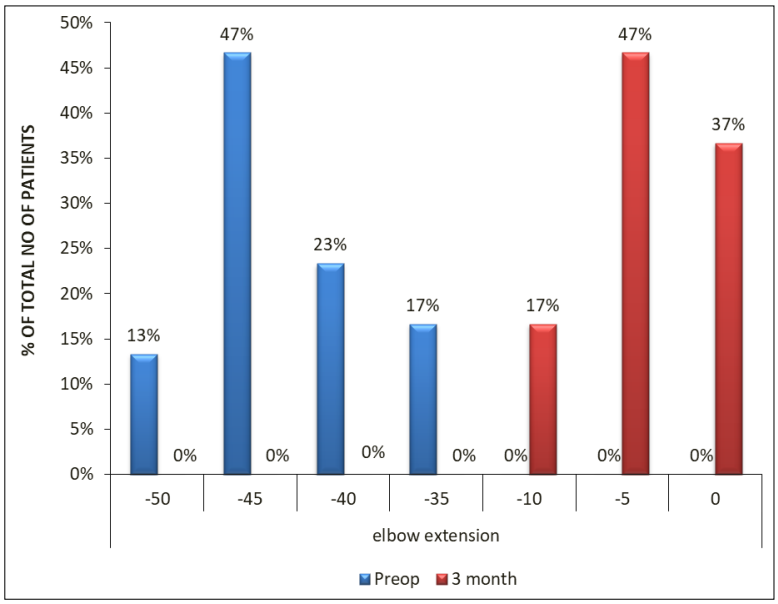


**Fig 6:** Elbow extension * Group

**Discussion**

Arthroscopy of elbow still not a very common procedure and need a lot of expertise and is a technically demanding procedure. Although elbow arthroscopy was a rare procedure but now because of an increasing number of athlete population being affected and more of people with degenerative diseases the incidence of elbow arthroscopy has increased considerably. Because elbow arthroscopy proved to be useful for several diagnostic and therapeutic purposes, indications and techniques for elbow arthroscopy in recent years have increased in number and complexity and are being performed by a growing number of surgeons. Since hardware

and surgical techniques have been improved, arthroscopic surgery became first line treatment modality in patients with elbow stiffness and those with failed conservative therapy.

Intra articular pathologies could be addressed accurately arthroscopically because arthroscopy providing improved joint visualization. Elbow stiffness is multifactorial in origin resulting from abnormalities of bone, soft tissue or a combination of both the may or may not follow traumatic event. The cause may be intrinsic or extrinsic or mixed.

The present study comprised of 30 patients with elbow stiffness, unimproved after 3 months of conservative treatment. In our study mean age were 35.63 at time of surgery which is comparable to studies conducted by Thomas. J. W 37 years, Nguyen D 42 years, Lukaswillinger, Sebastian Siebenlist 41 years. Maximum study population i.e. 26.67% were in two age group 31-40 and 41-50 years.

Out of 30 patients in study 10 (33.33%) were female and 20 (66.67%) were males. Males predominated in the study, with the overall male to female ratio being 2:1. It was similar to other studies in which males pre dominated more than females conducted by Xinghuowu [2015] 2.4:1, Nguyen D {2006} 1.75:1, Reduaan Elfedaali *et al.* {2013} 2.076:1.

However in one study done by Irma cefo MD {2011} [7] had female pre dominance with male to female ratio being 0.588:1. Since in most of studies there was male pre dominance thus we can infer that males are more affected because they are usually involved with more overhead and athletic activities.

Out of 30 patients 18 (60%) were right handed and 12 (40%) were left handed. This was comparable to other studies conducted by B.P.H. Lee {1997} [13] 45%, Reduan Elfeddali {2013} 67.5%, Xinghuo Wu {2015} 70%, Lukas Willinger {2017} 65%. Dominant elbow affection can be attributed to increased use of particular elbow for most day to day activities especially overhead and throwing activities. 93.34% of patients in our study had duration of symptoms ranging from 3-12 months.

Duration of symptoms ranged from 3-18 month. Mean duration of symptoms before operative intervention was performed was 7.87 ± 3.8 months. This is comparable to other studies done by G. Scott where duration of symptoms was 4-18 month, Irma Cefo 6-12 month. In our study 93.34% patients had duration of symptoms less than 12 month and remaining had duration of symptoms more than 12 month. In our study 24 (80%) had traumatic, 6(20%) had degenerative etiology.

In comparing two etiological groups the cohort with post traumatic etiology had lesser range of motion pre operatively and gained more range of motion as compared to patients with degenerative onset. Range of motion post op at 3 month did not show any difference between two groups of patients. This is comparable to study done by Lukas willinger, Sebastian Siebenlist, Phillips and Strasburger in which patients with traumatic etiologies gained more range of motion as compared to patients with degenerative etiologies.

The mean pre op flexion movement score was 87.33 ± 12.3 with highest being 110 and the lowest being 70.The mean flexion movement score was increased by 19 in 1 month to reach 106.33 and by 39.34 to reach 126.67 in 3 months. The mean post op 3month flexion movement score was 126.67.

Total increase from pre op period was 39.34 with highest value being 140 and lowest value being 70.

The mean pre op extension movement was -42.83 ± -4.68 with highest being -35 and the lowest being -50.The extension movement was increased by17.33 in 1 month to reach -25.5 and by 38.83 to reach -4. The mean post op 3 month extension score was movement score was -4. Total increase from pre op period was 38.83 with highest value being 0 and lowest value being -50.

However post operatively full extension and full flexion were achieved during manipulation under anaesthesia.

Above results are comparable to study conducted by Irma Cefo [2011] [7] in which mean flexion was $123^0$ which was increased to $133^0$ and extension was $24^0$ which was improved to $7^0$. All patients regarded procedure as helpful and were willing to undergo the same procedure again should the need arise.

The mean pre-op mayo performance score was 48.67 with the highest value being 70 and the lowest being 40. The score increased by 22.33 in 1 month to reach 71 and by 2.39 in 46.66 months to reach 95.33. The mean post-op 3 months mayo performance score was 95.33. Total mean increase from pre-op period was 46.66 with the highest value being 100 and the lowest being 40.

Above results are comparable to study conducted by Xinghuo Wu [2015] in which mayo elbow performance scale was 68.2 which was increased to 92.4 with mean improvement of 24.2, and also by Horiuchi. K in which mayo elbow performance score was 48.3 which was increased to 77.5 and also results were comparable to study done by Pederzini LA, Nicoletta F in which functional outcome of arthroscopy surgery in 243 patients with post traumatic and post degenerative elbow stiffness was evaluated. The post-operative improvement of the MEPI score was significant and showed a full recovery of working life and, sports and relationships for majority of patients.

No serious complications were noted. Only 8 patients had scar pain. And few patients had persistent limitation of range of motion. Good ROM could be performed intra operatively, but as time passed, the improved ROM was not maintained in some patients. The results were similar to study done by Xinghuo Wu in which patients ROM achieved intra operatively results were not maintained without effective exercise. Rest of patients did not have any significant complication.

The most important finding of our study was that arthroscopic arthrolysis is able to be an effective treatment option to restore elbow function in patients with post traumatic or degernative elbow stiffness. Both group showed significant improvement of ROM and provided good to excellent clinical outcome scores at follow up survey. Result of both groups was comparable and not different regarding ROM and MAYO Score. The above results were comparable to study done by Lukas willinger, Sebastian Siebenlist in which results were same regarding ROM and ESAS score in both traumatic and degernative causes of elbow stiffness.

Elbow arthroscopy is a tool that has been validated with symptomatic and functional improvement in both short term and long term, for patients with elbow stiffness. Apart from the lessened surgical morbidity, one of main advantage of the arthroscopic procedure compared to open procedure was ability to directly visualise elbow joint and lesser risk of heterotopic ossification.

In comparison to open procedures good outcomes have been reported with arthroscopic management of elbow stiffness because of lesser soft tissue trauma and small scar thus reducing the chance of contracture recurrence.

In study done by Gundlach and eygendaal monitored 21 patients and did comparison of arthroscopic and open technique showed a shorter rehabilitation after arthroscopic

intervention.

## Conclusion

After proper work up of 30 patients of stiff elbow out of which 26 were post traumatic and 4 were degenerative, elbow arthroscopy was carried out and the patients were followed up till 3 months to collect and analyse the data. On analysing the below mentioned points it can be concluded that elbow arthroscopy is an effective and safe method for treatment of selected patients with elbow stiffness.

- Those patients who had failed a course of conservative treatment were benefitted by the procedure.
- Almost all patients experienced rapid relief in pain with an accompanying improvement in function, pain and range of motion. Almost 83% patients reported that their symptoms had improved and that they were feeling better and satisfied.
- Duration of procedure was short and avoid long mutilating incision.
- Patients were able to return to activities of daily living within a few weeks.
- Number of days absent from work was less as patients returned to normal activities soon and were discharged a day after surgery.
- No significant complication was observed except for limitation of range of motion.
- Age, sex, dominant arm and side involved do not affect post-operative result but a larger study including more number of cases and a longer duration of follow up would be helpful in strengthening our conclusions.

We recommend the use of elbow arthroscopy in all patients with clinical and radiological findings of intra articular elbow disorder and not having bony ankylosis, who are resistant to a course of conservative treatment for quicker and effective pain relief and rehabilitation.

## References


1. Mitchell T, Keschner MD, Nader Paksima DO, MPH. The Stiff Elbow Bulletin of the NYU Hospital for Joint Diseases 2007;65(1):24-8.
2. de Haan J, Schep NWL, Eygendaal D, Kleinrensink GJ, Tuinebreijer WE, den Hartog D. Open Orthop J 2011;5:168-176.
3. Peter Evans J MD PhD, Sumon Nandi MD, Steven Maschke MD, Harry Hoyen A MD, Jeffrey Lawton N MD. J Hand Surg 2009;34A:769-778.
4. Morrey BF, Askew LJ, Chao EY. A biomechanical study of normal functional elbow motion J Bone Joint Surg Am 1981;63(6):872-7.
5. Curtis Myden MD, Kevin Hildebrand MD. FRCSC Elbow joint contracture after traumatic injury J Shoulder Elbow Surg 2011;20:39-44.
6. Willinger L, Siebenlist S, Lenich A, Liska F, Imhoff AB, Achtnich A. Arthroscopic arthrolysis provides good clinical outcome in post-traumatic and degenerative elbow stiffness. Knee Surg Sports Traumatol Arthrosc Off J ESSKA 2018;26(1):312-7.
7. Irma Cefo MD, Denise Eygendaal MD. Arthroscopic arthrolysis for posttraumatic elbow stiffness J Shoulder Elbow Surg 2011;20:434.
8. Frank Theodoor, Gabriel Rahusen1, Denise Eygendaal. Arthroscopic Surgery of the Elbow; Indications, Contra-Indications, Complications and Operative Technique Surgical Science 2011;2:219-223.
9. Deenesh Sahajpal MD, Tony Choi MD, Thomas Wright W MD. Arthroscopic Release of the Stiff Elbow J Hand Surg 2009;34A:540-544.
10. Thomas SCHUBERT, Jean-Emile DUBUC, Olivier BARBIER. A review of 24 cases of elbow arthroscopy using the DASH questionnaire Acta Orthop. Belg 2007;73:700-703.
11. Burman MS. “Arthroscopy or the Direct Visualization of Joints: An Experimental Cadaveric Study,” Journal of Bone and Joint Surgery 1931;13(4):669-695.
12. Singh H, Nam K, Moon Y. Arthroscopic Management of Stiff Elbow. J Orthopedics 2011;78:98.
13. Bruno RJ, Lee ML, Strauch RJ, Rosenwasser MP. Posttraumatic elbow stiffness: evaluation and management. J Am Acad Orthop Surg 2002;10:106-116.
14. Pederzini LA, Nicoletta F, Tosi M, Prandini M, Tripoli E, Cossio A. Elbow arthroscopy in stiff elbow. Knee Surg Sportsm Traumatol Arthrosc 2014;22:467-473.
15. Kodde IF, van Rijn J, van den Bekerom MP, Eygendaal D. Surgical treatment of post-traumatic elbow stiffness: a systematic review. J Shoulder Elbow Surg 2013;22:574-580.
16. Achtnich A, Forkel P, Metzlaff S, Petersen W. Arthroscopic arthrolysis of the elbow joint. Oper Orthop Traumatol 2013;25:205-214.
17. Khanchandani P. Elbow Arthroscopy: Review of the Literature and Case Reports. Case Reports in Orthopedics 2012.