



E-ISSN: 2395-1958
P-ISSN: 2706-6630
IJOS 2021; 7(2): 616-625
© 2021 IJOS
www.orthopaper.com
Received: 25-02-2021
Accepted: 29-03-2021

Dr. Janmejy Dalal
Senior Resident, Department of
Orthopaedics, Ruby Hall Clinic,
Pune, Maharashtra, India

Dr. Baldev Dudani
Consultant Orthopaedic Surgeon
& HOD Orthopaedics, Ruby
Hall Clinic Pune, Maharashtra,
India

Dr. Siddharth Jadhav
Senior Resident, Department of
Orthopaedics, Jehangir Hospital,
Pune, India

Dr. Nirav Shah
Resident, Department of
Orthopaedics, Ruby Hall Clinic,
Pune, India

Dr. Rahul Pujara
Resident, Department of
Orthopaedics, Ruby Hall Clinic,
Pune, India

Corresponding Author:
Dr. Janmejy Dalal
Senior Resident, Department of
Orthopaedics, Ruby Hall Clinic,
Pune, Maharashtra, India

A prospective comparative study of functional outcome in patients treated non-operatively and surgically (by plate osteosynthesis) for mid-shaft clavicle fractures in adults

Dr. Janmejy Dalal, Dr. Baldev Dudani, Dr. Siddharth Jadhav, Dr. Nirav Shah and Dr. Rahul Pujara

DOI: <https://doi.org/10.22271/ortho.2021.v7.i2h.2685>

Abstract

Clavicle fracture is a common traumatic injury around shoulder girdle due to their subcutaneous position. It is caused by either low-energy or high-energy impact. Fractures of the clavicle have been traditionally treated non-operatively. Although many methods of closed reduction have been described, it is recognized that reduction is practically impossible to maintain and a certain amount of deformity and disability is expected in adults.

30 patients with mid-shaft clavicle fracture were systematically randomized (alternate patient) into either operative treatment with plate fixation or non-operative treatment with clavicle brace and sling. All fractures were classified using Robinson's classification for clavicle fractures and only Type 2A2 and 2B1 were considered for the study. Patients were followed up at 3wks, 6wks, 3rd month & 6th month. Functional outcomes were assessed according to the Constant and Murley Scoring and radiologically.

Maximum number (90%) of patients had Robinson's Type 2B1 fracture. The mean duration of hospital stay for patients in Group A (operative) and Group B (non operative) was 3.67 ± 0.90 days and 1.73 ± 0.46 days respectively. In Group A, the mean duration of trauma to surgery was 3.13 ± 2.64 days. While the mean operative time was 104.87 ± 13.52 minutes. The duration of union was significantly lesser in Group A as compared to Group B according to Chi-Square test ($p < 0.05$)

The mean duration for time till Return to Functional ROM in Group B was 8.73 ± 4.33 weeks. There was no significant difference between the groups as per Chi-Square test ($p > 0.05$). Primary open reduction and internal fixation with pre-contoured clavicle plate for displaced, middle third clavicle fractures provide a more rigid fixation and allows early mobilization whereas conservative treatment require longer periods of immobilization till fracture union. Functional outcomes are better with surgical management of middle third clavicle fractures with pre-contoured locking compression plate. The successful use of locking compression plate for middle third fractures of clavicle requires careful assessment of fracture pattern, patient selection, meticulous operative technique, appropriate choice of fixation, judicious internal fixation, careful post-operative monitoring and aggressive early institution rehabilitation. So, there is need to individualize the treatment as per the need and functional demand of the patient to give the optimum outcome.

Keywords: Mid-shaft clavicle fractures, pre-contoured locking compression plate, clavicle brace, sling, Constant & Murley Score

Introduction

The clavicle or collarbone is a long bone that serves as a strut between the shoulder blade and the sternum or breastbone. Together with the shoulder blade it makes up the shoulder girdle. A clavicle fracture is a common traumatic injury around shoulder girdle due to their subcutaneous position.

Clavicle fracture is a common traumatic injury around shoulder girdle due to their subcutaneous position. It is caused by either low-energy or high-energy impact. Fracture of the clavicle accounts for approximately 5–10% of all fractures and up to 44% of injuries to the shoulder girdle. About 70–80% of these fractures are in the middle third of the bone and less often in the lateral third (12–15%) and medial third (5–8%) [1].

Incidence in males is usually highest in second and third decade which decreases thereafter as per age [2]. In females, it is usually bimodal, with peak incidence in young and elderly [3]. Allman [4] classified clavicle fractures into three groups based on their location along the bone. The middle-third fractures are most common and account for approximately 80–85% all clavicular fractures [5].

Fractures of the clavicle account for 2.5-5% of all fractures [3]. These fractures involve the middle third in 69-82% of the cases and are more common in children and young adults. Fractures of the clavicle have been traditionally treated nonoperatively. Moreover, open reduction and internal fixation (ORIF) of mid-clavicle fractures was considered the surest way to develop a nonunion. Although many methods of closed reduction have been described, it is recognized that reduction is practically impossible to maintain and a certain amount of deformity and disability is expected in adults [6].

Nonsurgical treatment was considered adequate to decrease pain and allow the fracture to unite. The radiographic union is expected by 12 weeks. In recent past few years, several publications have described about poor outcomes such as malunion and nonunion (15%) after conservative treatment of severely displaced clavicle fractures [7, 8, 9].

Clavicular plating remains the gold standard of operative treatment. Other types of internal fixation that have been used include intramedullary devices (titanium elastic nails), Rockwood pins, Kirschner wire, Rush nail and Kuntscher nails. However, most of these implants went into disrepute because of implant-related problems requiring removal of implants after fracture union [10, 11].

The proponents of early fixation of fresh clavicular fractures to prevent complications like malunion and non-union emphasize the value of accurate reduction and rigid fixation in affording quick pain relief and promoting early functional recovery [12].

In the younger age group, apart from isolated clavicle fractures poly-traumatic injuries are also very common, and clavicular mid-shaft fracture remains a frequent entity. In such situations, the choice of treatment remains a constant dilemma for achieving maximum pre-fracture functional status.

Recent studies in the adult literature have shown a higher prevalence of symptomatic malunion, non-union and poor functional outcome after non-operative treatment of comminuted mid shaft clavicle fractures.

Hence the present study was done to evaluate the functional outcome of fractures of the middle third of the clavicle treated with nonoperative management and fixation with plating at 6 months.

Materials and Methods

A prospective comparative study was conducted with 30 patients to evaluate the functional outcome of fractures of the middle third of the clavicle treated with non-operative management and fixation with plating. The patients were divided in the following two groups of 15 patients each:

Group A: 15 patients treated with operative management

Group B: 15 patients treated with non-operative management

Study Place: A Tertiary care Hospital in the department of Orthopedics, Ruby Hall Clinic, Pune.

Study design: A hospital based prospective observational study.

Study Duration: 12 months

Study area: The study was done at our tertiary care centre in the department of Orthopedics, Ruby Hall Clinic, Pune, Maharashtra, India on attending OPD/IPD.

Study population: Patients of the age 18-60 years having closed fracture of the clavicle who were admitted to Ruby Hall Clinic, Pune who fulfilled the inclusion criteria.

Sample size: 30 patients, randomized (alternate)

Sample Size was determined by using the effect sizes from previous study of Canadian Orthopaedic Trauma Society [13]. Total Sample Size of 30 patients was enrolled for this study with the help of following formula:

Where: n = Sample Size (per group).

$Z_{\alpha/2}$ = Standard normal variant at 5 % level of significance =

1.96 Z_{β} = cut off value for power $(1-\beta) = 0.84$

Δ/s = effect sizes in SD units = 0.71

s = expected pooled standard deviation = 16.8 weeks

Δ = mean difference of duration of union to be detected (minimum difference)

= 12 weeks

$n = (1.96 + 0.84)^2 / (12/16.8)^2$ $n = 15.36 = 15$

Thus, the sample size according to this formula is 15.36 @ 15 (minimum per group) and hence sample size of 30 patients were selected for the study.

Inclusion criteria

- Male and female patients aged 18-60 years
- Closed middle 1/3 clavicle fractures
- Fractures less than 1 week old
- Robinson's Type 2A2, type 2B1 fractures with/without butterfly fragment
- Patients who are medically fit for surgery.

Exclusion criteria

- Open fractures of the clavicle.
- Fracture in medial and lateral third of clavicle.
- Patients <18 yrs and >60yrs.
- Pathological fractures.
- Associated acromioclavicular joint dislocation
- Patients medically unfit for surgery.
- Associated head injury
- Established non-union from previous fracture
- Patients not willing for surgery.
- Comminuted fractures of the clavicle.
- Patients with neurovascular deficits.
- Any medical contraindication to surgery or general anaesthesia (heart diseases, renal failure or active chemotherapy)

Ethical Consideration

Informed consent was taken from the patients who were included in the study and approval was taken from the institutional ethical committee.

Methodology

Clavicle Brace with Broad arm sling used for conservative treatment and Pre- contoured locking clavicle plate used for surgical treatment.

Cases were followed at regular intervals. At the arrival of the patient with suspected clavicle fracture patients were resuscitated depending upon their general condition. Clavicle

Brace with simple sling or broad arm sling was given to stabilize fracture. The distal neurovascular status of the affected upper limb was examined and also the associated injuries along with fractured clavicle were noted.

Plain radiograph of clavicle with shoulder in antero-posterior view was taken to assess the site of fracture and the fracture type.

Investigations

- Routine blood examination
- Routine Urine examination
- HIV I & II, HbsAg, ECG.
- Echocardiography as when needed.
- X – Rays: Chest PA View
- Clavicle full length with shoulder AP view in sitting or standing position

Preoperative Preparation of Patient

- Patients were kept fasting for 6 hours before surgery.
- A written informed consent for surgery was taken.
- The neck, chest, axilla shoulders and arm were prepared.
- Tranquilizers were given as advised by the anaesthetist.
- A systemic antibiotics usually inj. Taxim 1gm intravenously were administered 30 minutes before surgery to all patients.
- All patients were operated under general anaesthesia.

Technique

Patient Positioning

The patient were placed in supine position. A bolster is placed between the shoulder blades to help facilitate reduction of the fracture during the case. The patient's involved upper extremity is prepped and draped in a sterile fashion.

Exposure

Approximately a six cm transverse (medial to lateral) incision is made over the palpable fracture of the clavicle, usually in the middle third. The medial fragment is usually proximal in relation to the distal fragment. Dissection is carried down to the fascia and the skin flaps are elevated. The cutaneous nerves are protected. The musculature is then sub-periosteally elevated off the bone fragments. It is important to keep soft tissue attachments to the butterfly fragments in an attempt to maintain vascularity. The fracture is reduced.

Plate Selection

The appropriately sized left or right precontoured locking clavicle plate is selected of the different length and curvature. The two middle slots may be placed over the fracture, ideally leaving two to three locking and/or non-locking holes.

Plate Placement

Once the plate's ideal positioning has been selected, it is provisionally stabilized to the clavicle with bone clamps. The locking/non-locking screws were placed either uni-cortical or bicortical.

Final Plate and Screw Position

An intraoperative radiograph is recommended to check the position of the screws and the final reduction of the fracture. If the surgeon feels the bone quality of the lateral fragment is poor, sutures may be passed from medial to lateral around the coracoid process and the plate to take stress off of the lateral fixation. The musculature is then re-approximated directly over the plate. The skin is then closed in layers with a

subcuticular stitch for the remaining skin layer.

Post-operative antibiotics were continued for 5 days. Analgesics and tranquilizers were given according to the needs of the patient. The operated upper limb was immobilized in broad arm sling. Check x-rays were taken to study the alignment of fracture fragments. The wound was inspected at 2nd or 3rd postoperative day. Suture removal was done on 12th postoperative day. Patients were discharged with the broad arm sling.

Rehabilitation of the affected arm was started at the end of 2 weeks. Gentle pendulum exercises to the shoulder were allowed. Follow-up at 4 to 6 weeks gentle active range of motion of the shoulder was allowed but abduction in limited to 80 degrees. At 6 to 8 weeks active range of motion in all planes were allowed. The functional outcome were assessed by Constant and Murley score.

Assessment was made at 3 wks, 6 wks, 3 months and 6 months.

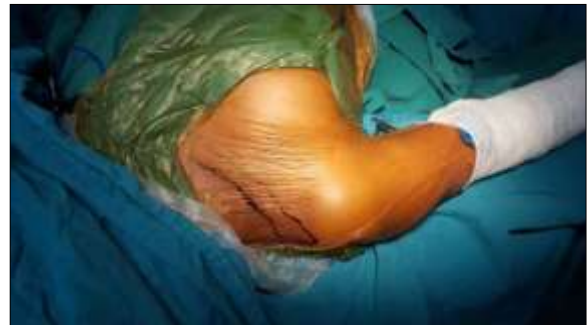

Fig 1: Marking – Pre Incision

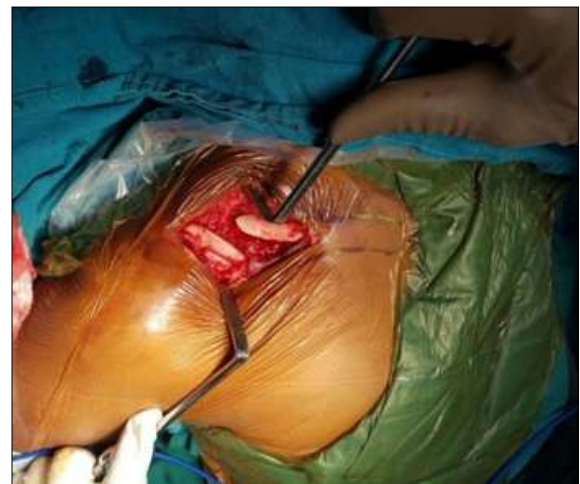

Fig 2: Incision & Exposure

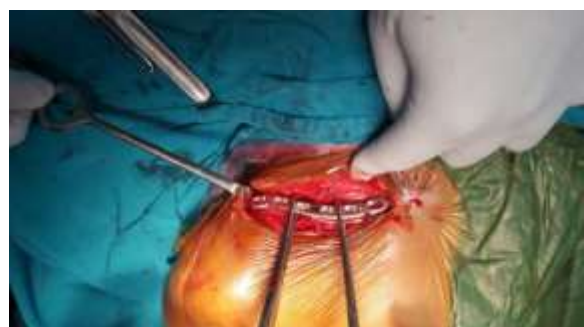

Fig 3: Reduction + Plate placement

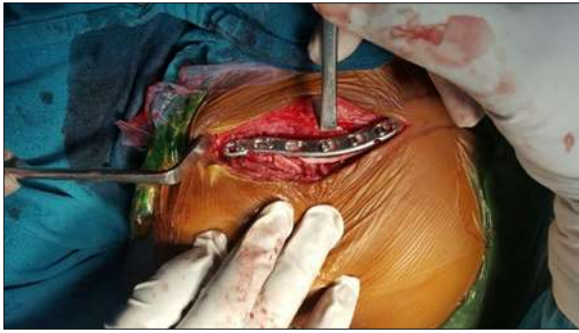

Fig 4: Screw placement

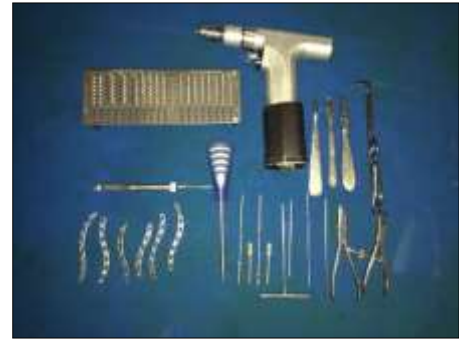
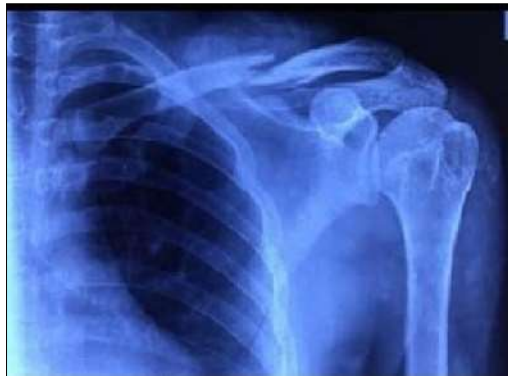
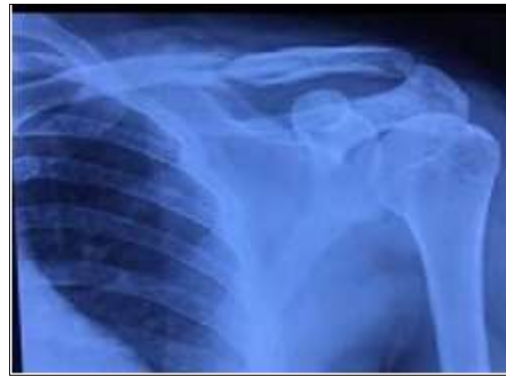Fig 5: Instrumentation & Implant

Follow Up Cases

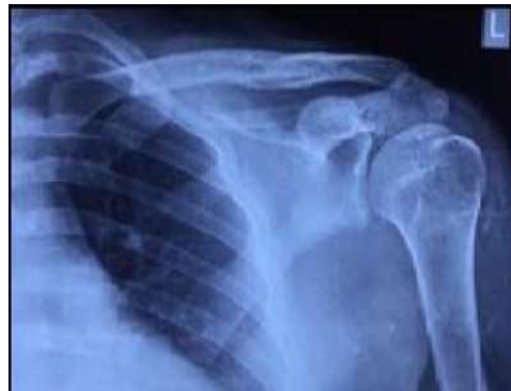Case 1 – Non-Operative



Pre-op



6 weeks



6 months

Fig 6: X-rays

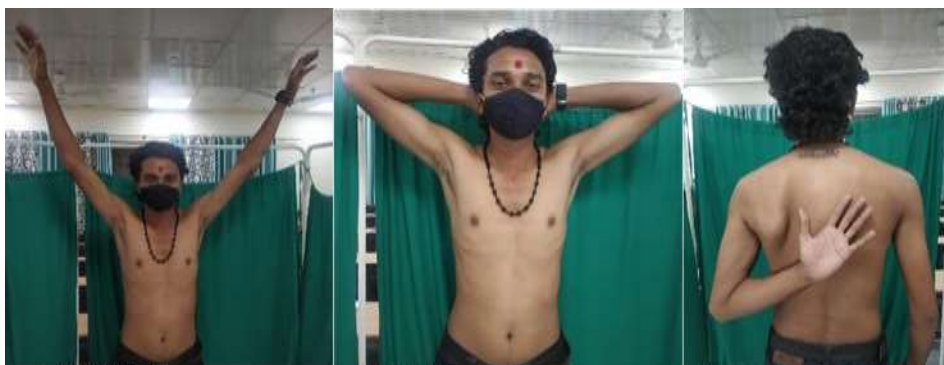

Fig 7: Functional Outcome & Score – 96 – Excellent

Plating – Case 1

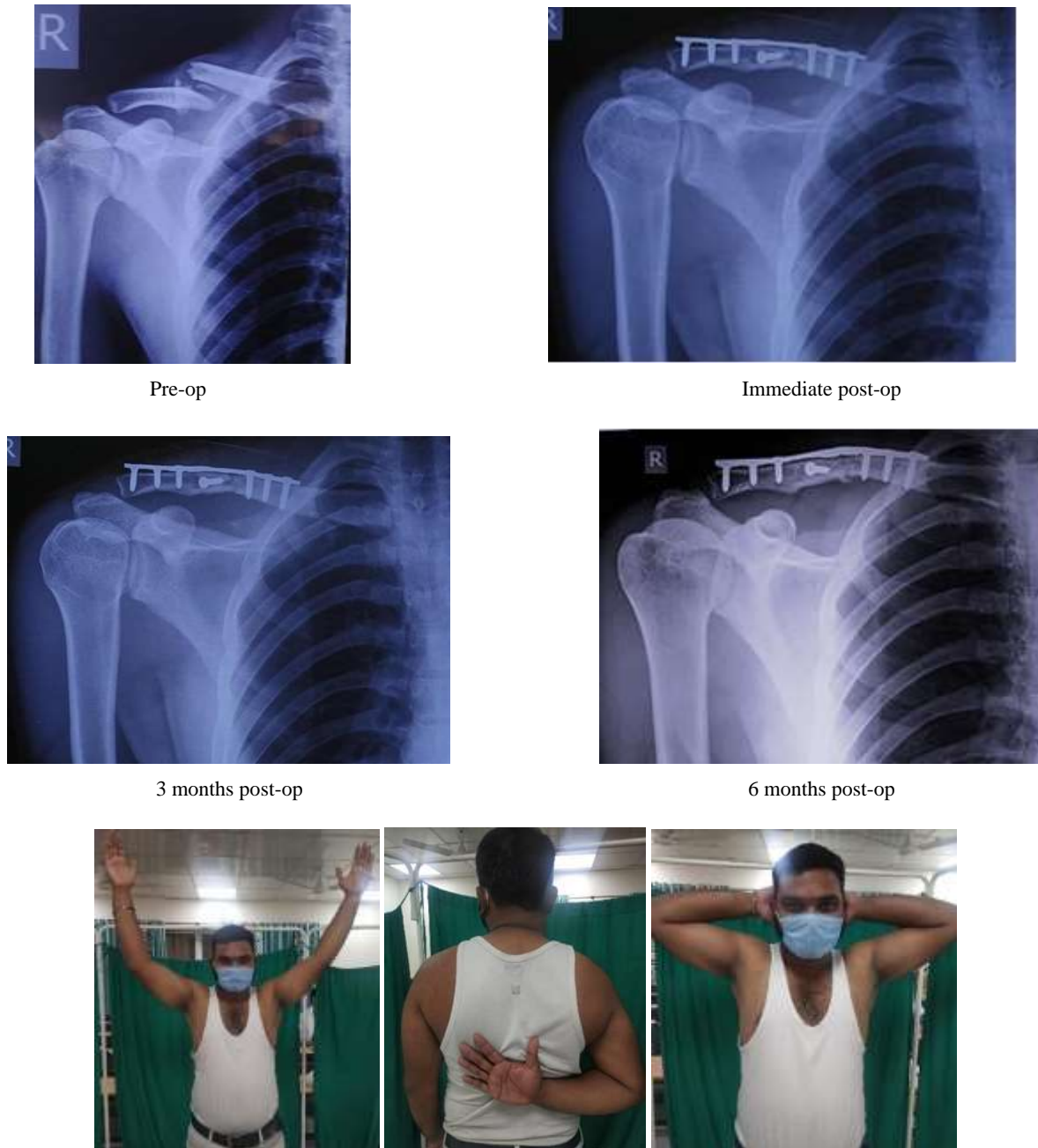


Fig 8: Functional outcome & Score – 94 – Excellent

Parameters used

Patients were evaluated both clinically and radiologically. Radiographs of the immediate post operative period were compared with that of latest follow-up. The union of fracture were assessed by callus formation and disappearance of fracture line.

Clinical evaluation was done by using

Constant-Murley score

Criteria	Maximum Score	Total score	Result
Pain	15	90-100	Excellent
Activities of daily living	20	80-89	Good
Range of motion	40	70-79	Fair
Strength	25	0-70	Poor
Total	100		

Results

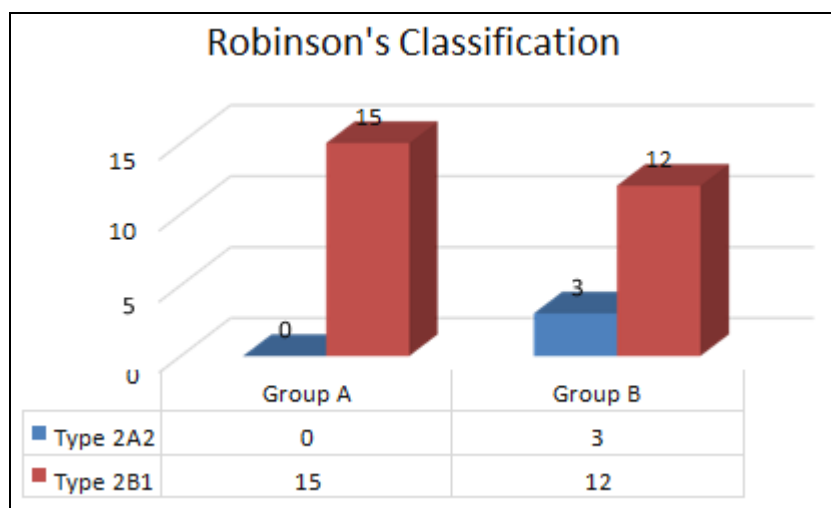
In the present study of 30 cases studied, the mean age of the

entire group of cases studied was 33.13 ± 9.82 years. Maximum patients were in the age group of 31-40 years (33.3%), immediately followed by 21-30 (26.7%). The incidence of mid-shaft clavicle fracture was found to be more in males with a sex ratio of 3:1. Road Traffic Accident was observed to be the main cause of fracture in both the groups (60% and 66.7% respectively) followed by fall from height (26.7% and 26.7% respectively) and fall while walking (13.3% and 6.7% respectively). There was a dominance of right side (73.3% and 66.7% respectively) as compared to left side (26.7% and 33.3% respectively) in both groups. Maximum number (90%) of patients had Robinson’s Type 2B1 fracture. The mean duration of hospital stay for patients in Group A (operative) and Group B (non operative) was 3.67 ± 0.90 days and 1.73 ± 0.46 days respectively. In Group A, the mean duration of trauma to surgery was 3.13 ± 2.64 days, while the mean operative time was 104.87 ± 13.52 minutes. In Group A, majority of the patients (86.7%) achieved

radiological union in <12 weeks while 2 (13.3%) patients achieved union in 12-24 weeks. The mean duration for radiological union in Group A was 8.53 ± 4.36 weeks. In Group B, majority of the patients (60%) achieved radiological union in <12 weeks while 6 (40) patients achieved union in 12-24 weeks. The mean duration for radiological union in Group B was 10.93 ± 5.46 weeks. The duration of union was significantly lesser in Group A as compared to Group B according to Chi-Square test ($p < 0.05$). In Group A, majority of the patients (73.3%) took <6 weeks to return to Functional Range of Motion (ROM) while 4 (26.7%) patients took >6 weeks to return to Functional ROM.

The mean duration for time till Return to Functional ROM in Group A was 5.07 ± 3.08 weeks. In Group B, majority of the patients (66.7%) took >6 weeks to return to Functional ROM while 5 (33.3%) patients took <6 weeks to return to Functional ROM. The mean duration for time till Return to Functional ROM in Group B was 8.73 ± 4.33 weeks. The patients in Group A achieved Return to Functional ROM significantly faster compared to Group B as per Student t-test ($p < 0.05$). 2 (13.3%) patients each in Group A had plate prominence and skin scar while 1 (2.9%) patient had restricted range of motion (ROM). 3 (20%) patients in Group B had malunion while 1 (6.7%) patient had delayed union. 2 (13.3%) patients had restricted ROM. There was no significant difference between the groups as per Chi-Square

test ($p > 0.05$). During 3 weeks follow-up period, 1 (6.7%) patient each in Group A and Group B had excellent score while 7 (46.7%) and 3 (20%) patients respectively had good score. Moderate score was observed in 6 (40%) and 4 (26.7%) patients of Group A and Group B respectively whereas poor score was observed in 1 (6.7%) and 7 (46.7%) patients respectively. There was no significant difference between the groups as per Chi-Square test ($p > 0.05$). During 6 weeks follow-up period, 11 (77.3%) and 6 (40%) patients in Group A and Group B respectively had excellent score while 3 (20%) and 6 (40%) patients respectively had good score. Moderate score was observed in 1 (6.7%) and 3 (20%) patients of Group A and Group B respectively. There was no significant difference between the groups as per Chi-Square test ($p > 0.05$). During 3 months follow-up period, 13 (86.7%) and 8 (53.3%) patients in Group A and Group B respectively had excellent score while 2 (13.3%) and 5 (33.3%) patients respectively had good score. Moderate score was observed in 2 (13.3%) patients of Group B. There was no significant difference between the groups as per Chi-Square test ($p > 0.05$). During 6 months follow-up period, all patients in Group A had excellent score. 13 (86.7%) and 2 (13.3%) patients in Group B had excellent and good score respectively. There was no significant difference between the groups as per Chi-Square test ($p > 0.05$).



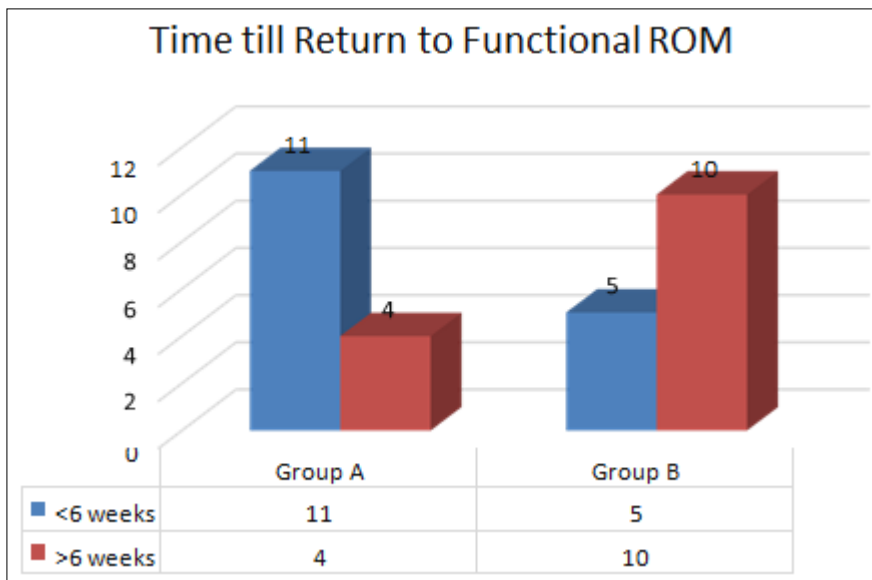
Graph 5: Distribution of patients according to Robinson's Classification

Table 8: Hospital Parameters of patients in Group A

Parameters	Group A	
	Mean	SD
Duration of Trauma to Surgery (days)	3.13	2.64
Operative Time (minutes)	104.87	13.52

Table 9: Distribution of patients according to Duration of Union

Duration of Union	Group A		Group B		p Value
	N	%	N	%	
<12 weeks	13	86.7%	9	60%	<0.05
12 - 24 weeks	2	13.3%	6	40%	
Total	15	100%	15	100%	
Mean \pm SD	8.53 ± 4.36		10.93 ± 5.46		



Graph 10: Distribution of patients according to Time till Return to Functional Range of Motion (ROM)

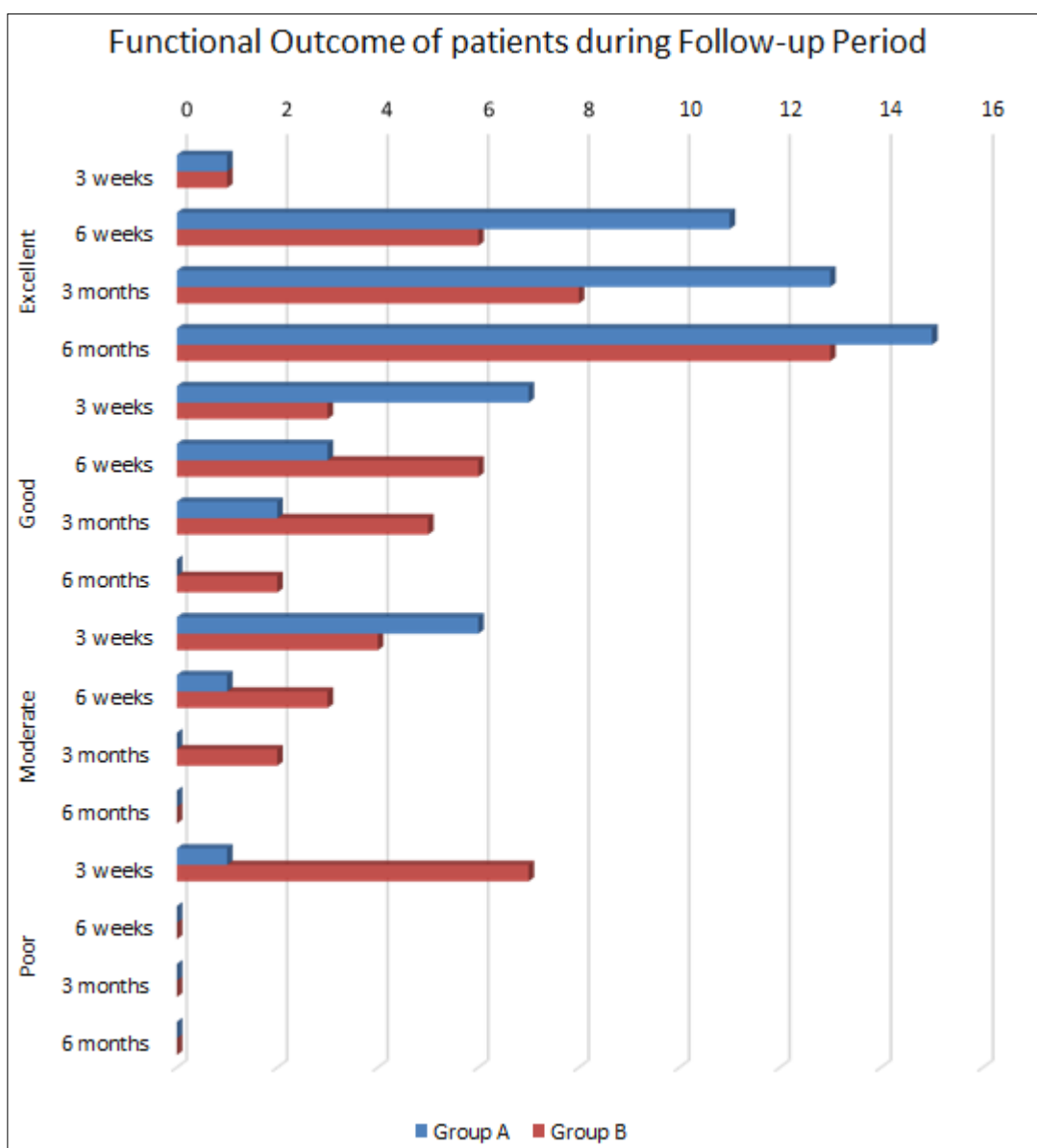


Table 12: Functional Outcome of patients during Follow-up Period

Discussion

A prospective comparative study was conducted with 30 patients to evaluate the functional outcome of displaced

fractures of the middle third of the clavicle treated with non-operative management and fixation with plating. The patients were divided in the following two groups of 15 patients each:

Group A: 15 patients treated with operative management

Group B: 15 patients treated with non-operative management
Traditionally these fractures have been treated conservatively. Neer in 1960 suggested that only 0.1% of fractures treated non-operatively, will fail to unite^[14]. More recently, however, it has been suggested mid shaft fractures with 20 mm initial shortening have a 15% non-union rate^[15]. Symptomatic mal-union of clavicle fractures can also occur in 31% to 50% of cases^[15, 16]. Reasons for dissatisfaction include weakness, pain, displacement, or a bump¹⁶. Other indications for clavicle fixation include open fractures, skin compromise, neurovascular damage, floating shoulder and symptomatic non-unions^[17].

In the present study, majority of the patients (33.3%) in Group A were in the age group of 31-40 years followed by 26.7% in the age group of 21-30 years, 20% in the age group of 41-50 years, 13.3% in the age group of 18-20 years and 6.7% in the age group of 51-60 years. The mean age of the patients was 33.13 ± 9.82 years. Majority of the patients (33.3%) in Group B were in the age group of 21-30 years followed by 26.7% in the age group of 31-40 years, 20% in the age group of 18-20 years, 13.3% in the age group of 41-50 years and 6.7% in the age group of 51-60 years. The mean age of the patients was 32.27 ± 12.42 years. There was no significant association between the groups as per Student t-test ($p > 0.05$).

In our study, majority of the patients in both groups were male. There were 80% and 73.3% male patients in Group A and Group B respectively whereas female patients constituted 20% and 26.7% of the study group respectively. There was no significant association between the groups as per Chi-Square test ($p > 0.05$). This is similar to the studies of Ethiraj P *et al.*^[18], Singh A *et al.*^[19] and Abu-zeid ME *et al.*^[20].

Ethiraj P *et al.*^[18] prospective study found middle third clavicle fracture commonly occurred between the age group of 19 to 30 years in 41 patients (68.3%). The youngest patient age was 19 years and oldest patient age was 55 years. The average patient age was 32 years.

Singh A *et al.*^[19] study assessing the outcomes of operative and non-operative management of middle 1/3rd clavicle fracture found out of 30 patients, 21 patients were male (70%) and 9 patients were female (30%). Majority of the patients i.e. 17 patients (56.67%) were in the age group of 21-40 years. The youngest patient was 19 years and oldest patient was 75 years. The average patient age was 37.10 years.

Abu-zeid ME *et al.*^[20] prospective study comparing results of conservative treatment and operative treatment with plate and screws in treatment of mid- shaft clavicular fractures found out of the 20 adult patients in two equal groups, the age in group A ranged from 22-55 years with a mean of 37.7 years and in group B it ranged from 21-41 years with a mean of 30.3 years with no statistically significant difference. Group A included 9 males (90%) and 1 female (10%), group B included 7 males (70%) and 3 females (30%) with no statistically significant difference.

It was observed in the present study that there was dominance of right side (73.3% and 66.7% respectively) as compared to left side (26.7% and 33.3% respectively) in both groups. There was no significant association between the groups as per Chi-Square test ($p > 0.05$). This is in concordance to the study of Abu-zeid ME *et al.*^[20].

Singh A *et al.*^[19] study found as per Robinson classification in type-2 middle third fracture type 2A1 (undisplaced) occurred in 13 patients (43.33%), type-2 B1 (displaced with simple or single butterfly fragment) occurred in 15 patients (50%) and type-2B2 (displaced with comminuted or

segmental) fracture occurred in 2 patients (6.67%).

Ethiraj P *et al.*^[18] prospective study observed Robinson Type-2B1 (Displaced with simple or butterfly fragment) were more common and there were 51 patients (85%). Type-2B2 (Displaced with comminution) occurred in 9 patients (15%).

Abu-zeid ME *et al.*^[20] prospective study found according to Robinson's classification in Group A included five patients with 2B1 (50%), and five patients with type 2B2 (50%). Group B had three patients with type 2B1 (30%), and seven patients with type 2B2 (70%).

In Group A, the mean duration of trauma to surgery was 3.13 ± 2.64 days while the mean operative time was 104.87 ± 13.52 minutes. This is consistent with the study of Ethiraj P *et al.*^[18].

Ethiraj P *et al.*^[18] prospective study found most of the patient were operated in two days from the time of injury i.e. 55 patients (91.7%). 5 patients (8.3%) were operated in the second week due to other co morbid conditions.

It was observed in the present study that in Group A, majority of the patients (86.7%) achieved radiological union in <12 weeks while 2 (13.3%) patients achieved union in 12-24 weeks. The mean duration for radiological union in Group A was 8.53 ± 4.36 weeks. In Group B, majority of the patients (60%) achieved radiological union in <12 weeks while 6 (40) patients achieved union in 12-24 weeks. The mean duration for radiological union in Group B was 10.93 ± 5.46 weeks. The duration of union was significantly lesser in Group A as compared to Group B according to Chi-Square test ($p < 0.05$). Similar observations were noted in the studies of Singh A *et al.*^[19], Ethiraj P *et al.*^[18], Abu-zeid ME *et al.*^[20], Kingsly P *et al.*^[21], Ejagwulu FS *et al.*^[22] and Onta PR *et al.*^[23].

Singh A *et al.*^[19] study observed fracture mostly united between 8-12 weeks in 24 patients (80%) and in 6 patients (20%) union occurred after 12 weeks. In 18 conservatively treated patients, 13 patients (72.22%) showed union between 8- 12 weeks and 5 patients (27.78%) showed union after 12 weeks. In 12 surgically treated patients, 11 patients (91.67%) showed union between 8-12 weeks and 1 patient (8.33%) showed union at 16 week due to implant failure. Average duration of union is longer in conservatively treated patients (12.33) weeks as compared to operative group i.e. (8.67) weeks. 24 patients (80%) showed radiological union between 8 to 12 weeks and 6 patients (20%) showed union after 12 weeks.

Ethiraj P *et al.*^[18] prospective study evaluating the functional outcome of surgically managed clavicle fractures with precontoured locking plate observed among 60 patients with middle third clavicle fracture treated with locking compression plate and screws, 56 fractures united at an average of 12 weeks. 3 patients had delayed union, 1 patient had plate breakage for which implant removal and replating was done.

Abu-zeid ME *et al.*^[20] prospective study observed patients in group A achieved union in 5.8 months; range 4 to 8 months. In group B union occurred in 5.3 months; range 4 to 12 months.

Kingsly P *et al.*^[21] prospectively and retrospectively study found mean time to union was 16.3 weeks in the reconstruction plate group compared with 13.4 weeks in the precontoured locking plate group.

Ejagwulu FS *et al.*^[22] prospective study assessing the incidence of clavicle injuries observed average X-ray healing duration was 16.2 and 14.6 weeks for those managed conservatively and surgically, respectively.

Onta PR *et al.*^[23] study evaluating the clinical and

radiological outcome, time for fracture union and complications in midshaft clavicle fracture observed mean time for clinical and radiological union was 8.77 (1.17) weeks and 17.03 (3.06) weeks. All patients had union of fracture with only one patient having superficial surgical site infection.

It was observed in our study that in Group A, majority of the patients (73.3%) took <6 weeks to return to Functional Range of Motion (ROM) while 4 (26.7%) patients took >6 weeks to return to Functional ROM. The mean duration for time till Return to Functional ROM in Group A was 5.07 ± 3.08 weeks. In Group B, majority of the patients (66.7%) took >6 weeks to return to Functional ROM while 5 (33.3%) patients took <6 weeks to return to Functional ROM. The mean duration for time till Return to Functional ROM in Group B was 8.73 ± 4.33 weeks. The patients in Group A achieved Return to Functional ROM significantly faster compared to Group B as per Student t-test ($p < 0.05$). Agarwal T *et al.*²⁴ noted similar observations in their study.

Agarwal T *et al.*²⁴ study assessing the result after fixation of displaced clavicle fractures with locking compression plate observed 17 cases took 4 to 5 week time for functional range of motion and 13 cases took 6 to 8 weeks time for full functional range of motion.

It was observed in the present study that during 3 weeks follow-up period, 1 (6.7%) patient each in Group A and Group B had excellent score while 7 (46.7%) and 3 (20%) patients respectively had good score. Moderate score was observed in 6 (40%) and 4 (26.7%) patients of Group A and Group B respectively whereas poor score was observed in 1 (6.7%) and 7 (46.7%) patients respectively. There was no significant difference between the groups as per Chi-Square test ($p > 0.05$). During 6 weeks follow-up period, 11 (77.3%) and 6 (40%) patients in Group A and Group B respectively had excellent score while 3 (20%) and 6 (40%) patients respectively had good score. Moderate score was observed in 1 (6.7%) and 3 (20%) patients of Group A and Group B respectively. There was no significant difference between the groups as per Chi-Square test ($p > 0.05$).

During 3 months follow-up period, 13 (86.7%) and 8 (53.3%) patients in Group A and Group B respectively had excellent score while 2 (13.3%) and 5 (33.3%) patients respectively had good score. Moderate score was observed in 2 (13.3%) patients of Group B. There was no significant difference between the groups as per Chi-Square test ($p > 0.05$). During 6 months follow-up period, all patients in Group A had excellent score. 13 (86.7%) and 2 (13.3%) patients in Group B had excellent and good score respectively. There was no significant difference between the groups as per Chi-Square test ($p > 0.05$). Similar observations were noted in the studies of Ethiraj P *et al.*¹⁸, Agarwal T *et al.*²⁴ and Abu-zeid ME *et al.*²⁰.

Ethiraj P *et al.*¹⁸ prospective study reported excellent results in 46 cases (76.7%), good in 10 cases (16.7%), fair in 3 cases (5%), poor in 1 case (1.6%). Excellent results were seen in most of the clavicle fractures who complete, painless shoulder range of movements by three months. One patient who had poor result is due to implant failure due to breakage of the implant. Patient had an ipsilateral proximal tibia fracture fixed with LCP and started weight bearing on the fractured upper limb less than two weeks after fixation.

Agarwal T *et al.*²⁴ study assessing the result after fixation of displaced clavicle fractures with locking compression plate found 4 cases had ≥ 14 weeks time for union and 26 cases had less than 14 weeks for union.

Abu-zeid ME *et al.*²⁰ prospective study observed patients in group A showed ability to return to pre-injury daily activities in 10.2 weeks with range 8 to 14 weeks. In group B patients returned to pre-injury daily activities in 11.8 weeks with range of 7 to 15 weeks and was statistically not significant.

Conclusion

Primary open reduction and internal fixation with pre-contoured clavicle plate for displaced, middle third clavicle fractures provide a more rigid fixation and allows early mobilization whereas conservative treatment require longer periods of immobilization till fracture union.

Simple, undisplaced fractures can be treated with conservative treatment which gives good results in terms of functional and anatomical aspects but when this method is used for displaced fractures it gives complications such as mal-union and non-union.

Functional outcomes are better with surgical management of middle third clavicle fractures with locking compression plate. The successful use of locking compression plate for middle third fractures of clavicle requires careful assessment of fracture pattern, patient selection, meticulous operative technique, appropriate choice of fixation, judicious internal fixation, careful post-operative monitoring and aggressive early institution rehabilitation.

The final functional result of treatment of middle third fractures not only depends on anatomical reduction but also depends on surrounding soft tissue injuries and mobilization. Patients who undergo operative fixation of displaced middle-third clavicle fractures have a lower incidence of nonunion and symptomatic malunion.

Six months after a midshaft clavicular fracture, nonoperative treatment resulted in higher malunion and nonunion rate but similar functional outcome and union time compared to operative management. So, there is need to individualize the treatment as per the need and functional demand of the patient to give the optimum outcome.

Surgical treatment can be considered in patients, who demand a fast recovery and good upper limb range of motion, whereas the remaining can be treated conservatively.

References

1. Craig EV, Basamania CJ, Rockwood CA *et al.* Fractures of the clavicle. editors. The Shoulder. 3rd ed. Saunders; Philadelphia 2004;455-519.
2. Robinson CM. Fractures of the clavicle in the adult. J Bone Joint Surg Br 1998;80(3):476-484.
3. Nordqvist A, Petersson C. The incidence of fractures of the clavicle. Clin Orthop Relat Res 1994;300:127-132.
4. Allman FL Jr. Fractures and ligamentous injuries of the clavicle and its articulation. J Bone Joint Surg Am 1967;49(4):774-784.
5. Stanley D, Trowbridge EA, Norris SH. The mechanism of clavicular fracture. A clinical and biochemical analysis. J Bone Joint Surg Br 1988;70B:461-464.
6. Ledger M, Leeks N, Ackland T *et al.* Short malunions of the clavicle: An anatomic and functional study. J Shoulder Elbow Surg 2005;14:349-54.
7. Postacchini F, Gumina S, De Santis P *et al.* Epidemiology of clavicle fractures. J Shoulder Elbow Surg 2002;11:452-6.
8. Greene WB. Essentials of Musculoskeletal Care. 2nd ed. Rosemont, Ill: American Academy of Orthopaedic Surgeons 2001.
9. Jupiter JB, Leffert RD. Non-union of the clavicle

- associated complications and surgical management. *J Bone Jt Surg (Am)* 1987;69:753-760.
10. Frigg A, Rillmann P, Perren T *et al.* Intramedullary nailing of clavicular midshaft fractures with the titanium elastic nail: problems and complications. *Am J Sports Med* 2009;37:352-359.
 11. Crenshaw AH. Fractures of the shoulder girdle arm and forearm. In: Crenshaw AH, editor. *Campbell's operative orthopaedics*. 8th ed. St. Louis: Mosby Year book 1992;989-1053.
 12. Poigenfurst J, Rappold G, Fischer W. Plating of fresh clavicular fractures. *Injury* 1992;23(4):237-241.
 13. Canadian Orthopaedic Trauma Society. Non operative treatment compared with plate fixation of displaced mid shaft clavicular fractures. A multi center, randomized clinical trial. *J Bone Joint Surg Am* 2007;89(1):1-11.
 14. Neer CS. Non-union of the clavicle. *JAMA* 1960;172:1006-1011.
 15. Hill JM, Mc Guire MH, Crosby LA. Closed treatment of displaced middle third fractures of the clavicle gives poor results. *J Bone Joint Surgery (Br)* 1997;79:537-540.
 16. McKee MD, Pedersen EM, Jones C *et al.* Deficits following non operative treatment of displaced mid shaft clavicular fractures. *J Bone Joint Surg Am* 2006;88:35-40.
 17. Jupiter JB, Ring D. Fractures of the clavicle. Chapter- 26, in: Iannotti JP and Williams GR. editors. *Disorders of the Shoulder diagnosis and Management*, Philadelphia: Lippincott Williams and Wilkins 1999,709-786.
 18. Ethiraj P, Prathap P, Arun HS *et al.* Functional outcome in surgical management of midshaft clavicle fractures fixed with precontoured plate in adults. *International Journal of Orthopaedics Sciences* 2016;2(4):458-462.
 19. Singh A, Jain G, Sharma S. Comparative study of Non-operative versus Operative treatment for middle 1/3rd clavicle fracture. *International Journal of Orthopaedics Sciences* 2018;4(1):108-114.
 20. Abu-zeid ME, Khairy HM, El-Adawy AM *et al.* Comparative Study Between Conservative Management and Plate Fixation For The Mid- Shaft Clavicle Fractures in Adults. *Zumj* 2020;27(2):239-247.
 21. Kingsly P, Sathish M, Muhammad Ismail ND. Comparative analysis of functional outcome of anatomical precontoured locking plate versus reconstruction plate in the management of displaced midshaft clavicular fractures. *Journal of Orthopaedic Surgery*.
 22. Ejagwulu FS, Lawal YZ, Maitama IM *et al.* Management of clavicle fractures and adjacent clavicular joint dislocations in a Tertiary Health Center, North West, Nigeria. *Niger J Basic Clin Sci* 2019;16:15-23.
 23. Onta P, Sapkota K, Wahegaonkar K, Ranjeet N, Thapa P, Thapa U. Treatment of midshaft clavicle fracture with anatomical contoured clavicular locking plate. *Asian Journal of Medical Sciences* 2018;10(1):92-96.
 24. Agarwal T, Bhugra H, Jadhav S *et al.* Operative treatment of mid-shaft clavicle fracture by locking plate. *Indian Journal of Orthopaedics Surgery* 2017;3(4):356-359.