E-ISSN: 2395-1958
P-ISSN: 2706-6630
IJOS 2021; 7(2): 293-296

www.orthopaper.com
Received: 16-02-2021
Accepted: 25-03-2021

Dr. Harish Kumar Jain
Senior Professor, Department of Orthopaedics, Jhalawar Medical College and SRG Hospital, Jhalawar, Rajasthan, India

Dr. Mukul Jain
Senior Resident, Department of Orthopaedics, Jhalawar Medical College and SRG Hospital, Jhalawar, Rajasthan, India

Dr. Raghuveer Ram Dhattarwal
Resident, Department of Orthopaedics, Jhalawar Medical College and SRG Hospital, Jhalawar, Rajasthan, India

Dr. Om Prakash Meena
Resident, Department of Orthopaedics, Jhalawar Medical College and SRG Hospital, Jhalawar, Rajasthan, India

Dr. Muniraj Meena
Resident, Department of Orthopaedics, Jhalawar Medical College and SRG Hospital, Jhalawar, Rajasthan, India

Corresponding Author:
Dr. Mukul Jain
Senior Resident, Department of Orthopaedics, Jhalawar Medical College and SRG Hospital, Jhalawar, Rajasthan, India

A study of supracondylar fracture of humerus in children treated with lateral pinning

Dr. Harish Kumar Jain, Dr. Mukul Jain, Dr. Raghuveer Ram Dhattarwal, Dr. Om Prakash Meena and Dr. Muniraj Meena

DOI: https://doi.org/10.22271/ortho.2021.v7.i2d.2645

Abstract
Introduction: Supracondylar fracture humerus is one of the commonest fractures suffered in children accounting 50 to 70% of fractures around elbow in children. Complications of malunion or growth deformities into cubitus varus or valgus necessitates the accurate reduction and union along with maintaining normal range of motion. Closed reduction and splintage in plasters fail to achieve these goals often, so percutaneous pinning with k wires from lateral condyle is assumed to help in managing these cases without aforesaid complications.
Aim: To assess the functional outcome, union and complications if any associated with lateral pinning using K wires in supracondylar fractures in children.
Materials and Methods: In prospective study design, total 30 cases of supracondylar fracture humerus in children treated at tertiary care teaching hospital in southern Rajasthan between January 2020 to October 2020 were included. The functional as well as radiological assessment and complications observation was done in regular follow up till fracture union.
Results: All the 30 cases achieved solid union between 4 to 6 weeks duration. The functional outcome was satisfactory in 90% cases (including excellent and good results) using Flynn's Criteria with 1 patient having fair range of motion and carrying angle while 2 patients had poor range of motion and cubitus varus developed.
Conclusion: We concluded that preservation of the optimal function of elbow after supracondylar fracture humerus in children is satisfactorily achieved after fixing with lateral pinning using K wires with a short learning curve and minimal complications of malunion, cubitus varus or valgus deformity, loss of range of motion which are more in conservative management using plasters and no risk of ulnar nerve damage as seen in using cross wire fixation.

Keywords: Supracondylar fracture Humerus in children, K wires, Flynn's Criteria, Gartland classification, CRIF, lateral pinning

Introduction

Supracondylar Fracture of humerus is one of the commonest fractures sustained by children [1-4]. Supracondylar Fracture of humerus is not only the commonest fracture around the elbow in children accounting for 50% to 70% of fractures in elbow region.[5,6] but also one of the most difficult fracture to treat because of rather frequently occurring complications like nerve injury, vascular injury, Volkmann's ischemic contracture, stiffness of elbow and malunion.

Although there is a general consensus regarding the treatment of undisplaced supracondylar fracture of humerus, treatment of partially displaced and completely displaced supracondylar fracture of humerus has been surrounded by considerable controversy.

Close reduction and percutaneous pinning promises to be the best method at present but close reduction is not always achievable because intense soft tissue swelling and intrinsically unstable nature of the supracondylar fracture of humerus. In these cases, open reduction becomes mandatory.

The goal in treating these fractures is to re-establish the anatomy of distal humerus perfectly with least complications and with enough stability to permit early painless, functional elbow motion.

Materials and Methods

The present study was prospective therapeutic study performed in tertiary care hospital and teaching centre in southern Rajasthan after ethical clearance from institutional ethical committee. The cases included were supracondylar fracture humerus in children admitted between January 2020 to October 2020 and treated with closed reduction and internal fixation using two or three K wires through lateral condyle after consent obtained to participate willingly in this study.

Inclusion Criteria

- Gartland type I, II and type III fractures.
- Supracondylar fractures with or without neurovascular complication except those who requires neurovascular repair.
- Children of both genders

Exclusion Criteria

- Supracondylar fracture with compartment syndrome needing fasciotomy.
- Supracondylar fracture needing vascular repair.
- Supracondylar fracture associated with distal radius/ulna, proximal humerus fracture.
- Patients unfit for surgery.
- Patients not willing to give consent.
- Fractures more than 3 days old.
- Patients with metabolic bone disorder or pathological fractures.

As soon as the patient was admitted, a detailed history was taken and a meticulous examination of the patient was done. The required information was recorded in the proforma prepared. The patients radiograph was taken in antero-posterior and lateral views. The diagnosis was established by clinical and radiological examination.

In this study, supracondylar fracture of humerus was classified according to Kocher classification and Gartland's classification.

Type I: Undisplaced Supracondylar fracture of humerus.

Type II: Displaced Supracondylar fracture with intact posterior cortex.

Type III: Displaced Supracondylar fracture with no cortical contact.

a. Postero- medial
b. Postero-lateral.

Temporary closed reduction was done on admission and above elbow posterior pop slab was applied in 90° of flexion at elbow. The limb was elevated to reduce swelling of the elbow.

All patients were taken for surgery as soon as possible after necessary pre-operative blood investigations and pre anaesthetic work- up.

All patients were started on prophylactic antibiotic therapy. Intravenous cephalosporins were used. It was administered according to body weight of the children, prior to induction of anesthesia and continued at 12 hourly interval post-operatively for 3 days.

Operative procedure done Under General Anaesthesia, patient was placed in supine position with affected upper limb beyond the free edge of the table. Then painting and draping of the part done, leaving the elbow, lower 1/3rd arm and forearm exposed.

Technique of closed Reduction

Longitudinal traction was given with elbow in extension and supination. At the same time an assistant gave counter traction on the proximal portion of the arm. Continuing traction and counter traction medial or lateral displacement was corrected by applying valgus or varus force respectively at fracture site. After that posterior displacement and angulation was corrected by flexing the elbow and simultaneously anteriorly directed force was applied from posterior aspect of distal fragment while posteriorly directed force was applied from anterior aspect of proximal fragment and.

If adequate reduction is obtained, the elbow should be capable of smooth & almost full flexion. Adequacy of reduction was confirmed under image intensifier with two perpendicular views (Fig1). On failure to obtain a satisfactory reduction after two or three manipulations, open reduction was considered.

Insertion of K-wires

Stainless steel Kirschner's wire of 2.00 mm diameter was used. After achieving good reduction, hyperflexion at elbow was maintained and k-wires were inserted from lateral condyle with the help of power drill under image intensifier.

Point of Entry

Lateral pin started at the centre of the lateral condyle.

Direction of pin

In AP view of elbow, both pins should make an angle of 40 degrees with humeral shaft and should be directed 10 degrees posteriorly [7].

Criteria for adequate fixation:

Both pins were aimed to engage opposite medial cortex. Once pins were placed, we confirmed the placement and direction of the pin with c-arm. After achieving adequate fixation, we examined the elbow for full movement by extending the elbow.

Post-operative management

Post-operatively, above elbow posterior pop splint was applied and operated limb was elevated on a drip stand and patient was encouraged to move fingers.

At 2nd post-operative day, dressing was checked and condition of pin sites were noted. Patients were discharged on 3rd or 4th post-operative day.

K-wires were removed at 3 weeks post-operatively after xray confirmation of satisfactory callus formation. Pop splint was discarded at the same time and patient was encouraged to do active elbow flexion, extension, supination and pronation exercises.

Patients were advised not to lift heavy weight, till 12 weeks post-operatively. Follow up was done on OPD basis at 3rd, 4th, 6th and 8th week post-operatively. The follow up was done by clinical and radiological evaluation. The functional results were graded based on Flynn *et al.* [8] (Table 1) grading and x-rays were obtained for radiological union assessment.

Table 1: Flynn *et al* [8] grading

Rating	Loss in carrying angle	Loss in elbow movements
Excellent	0-5°	0°-5°
Good	6°-10°	6°-10°
Fair	11°-15°	11°-15°
Poor	>15°	>15°

Results

In the study of 30 cases, 20 children (66.66%) were male and 10 (33.33%) were females. 20 children (66.66%) had an injury of right humerus and 10 (33.33%) had injury of left humerus.

In our study, 28 children (93.33) had extension type fracture, only 2 (6.66%) had flexion type of fracture. In 2 children (6.66%) pin tract infection occurred, in 2 children (6.66%) median nerve injury occurred and in 2 children (6.66%) cubitus varus deformity occurred.

In our study, loss of ROM in 22 (73.33%) cases was 0 - 5°, in 5 (16.66%) cases 6-10°, in 1 (3.33%) case 11-15° and in 2 (6.66%) cases 15-20° (Table 2).

Table 2: Results on basis of Restriction of range of movement

Result	Loss of movement (range)	No. of cases	Percentage
Excellent	0-5°	22	73.33%
Good	6°-10°	5	16.66%
Fair	11°-15°	1	3.33%
Poor	15°-20° or more	2	6.66%

In our study, loss of carrying angle was 0-5°in 23 (76.66%) cases, 5-10° in 4 (13.33%) cases, 10-15° in 1 (3.33%) case and >15° in 2 (6.66%) cases (Table 3).

Table 3: Results on basis of Loss of carrying angle

Result	Loss of carrying angle	No. of cases	Percentage
Excellent	0-5°	23	76.66%
Good	5°-10°	4	13.33%
Fair	10°-15°	1	3.33%
Poor	More than 15°	2	6.66%

Fig 1(a): Preoperative X-ray

Fig 1(b): Post-operative X-ray

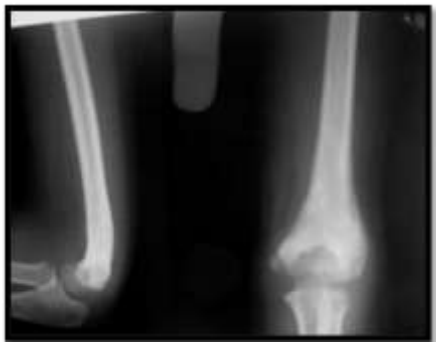

Fig 1(c): 6 month follow up X-ray

Discussion

Displaced supracondylar fracture of humerus in children when accompanied by marked swelling, presents a formidable challenge. Some displaced fractures are stable after reduction and may be managed satisfactorily after closed reduction by plaster slab immobilization. However, many of these fractures are unstable after reduction except in acutely flexed position. If considerable swelling is present this acutely flexed position may compromise circulation and predisposes to Volkmann's ischemic contractures. Immobilization in safer right angle position will frequently allow the fragment to slip producing varus deformity. Mac Laughlin called this "The Supracondylar fracture is a dilemma". Displaced supracondylar fractures are managed with various methods like closed reduction with plaster, traction, closed reduction and percutaneous pinning, open reduction and k- wire fixation, lateral divergent pins or crossed pins.

Management of displaced supracondylar fracture of humerus in children may present problems in management including limb threatening Volkmann's ischemia, neurovascular complications and deformity. It demands considerable skill and experience. Complications can occur due to injury itself or may follow treatment. It is essential to minimize additional trauma to already traumatized joint and periarticular tissues. Supracondylar fracture should be reduced accurately and stabilized.

Acceptance of poor reduction in a displaced position leads to imperfect results like limited movement of elbow joint like limited extension, varus & valgus deformities. So perfect anatomic reduction is key factor in management of displaced supracondylar fracture of humerus.

In this series, our aim was to avoidance of complications and achievement of excellent functional and cosmetic results, which should be goal in the treatment of all fractures.

Age Incidence

Age is the key factor in supracondylar fracture. This is almost exclusively fracture of immature skeleton often in first decade. This may explained by weak bony architecture and other anatomical factors. At the age of peak incidence for supracondylar fractures, the bone in the supracondylar area is undergoing remodeling with a decrease in both the anteroposterior and lateral diameter. It is less cylindrical than in the adult. The metaphysis of the child extends just distal to the two fossae which is site for this fracture. Our study is comparable with other studies reported in past literature.

Sex Wise Distribution

Male patients who had supracondylar fracture were almost 2/3rd of total number of patients. Males had more fractures than females because males were more active and prone to sustain this injury. Our result were comparable with other series and most of them have shown male predominance.

Side Distribution
In supracondylar fractures of humerus, the dominant side fracture is more commonly seen possibly because it is frequently used in protective reflex

Type of Fractures
Extension type of supracondylar humerus fractures were in the majority as compared to flexion type fractures. This is comparable with Pirone [2] and Jong series. Posteromedial displacement is more common due to secondary pull of the triceps, which originates medially and also biceps lie medial to the shaft which would increase contribution. Flexion type of fracture pattern is very less as mentioned above in results.

Vascular Injury
In our study, we did not find any vascular injury postoperatively.

Nerve Injuries
In our study, we found anterior interosseous nerve injuries in two patients postoperatively.

Myositis Ossificans
Neither we, nor other series reported myositis ossificans. This is mainly due to awareness of this fracture and easy availability of proper medical care and less incidence of massage and local treatment by quacks.

Pin tract Infection
Our study showed pin tract infection in 2 patients which was comparable with other study. We had less infection probably due to appropriate antibiotics and proper pin site care. (Table 4)

Table 4: Pin tract infection

Series	Percentage
Fowels J *et al.* [9]	7.70%
Hamid rm[3], Charles s [10]	7.20%
Our study	6.66%

Cubitus Varus and Valgus
We had two patients (6.66%) with cubitus varus deformity. This was due to medial column comminution which led to difficulty in getting perfect anatomical realignment of the pillars, thus leading to inadequate reduction.

Final result [Flynn. J.C. Criteria]
We had satisfactory (excellent and good) results in 27 cases (90%) of which is comparable with other studies. This is probably due to good anatomical alignment, stable fixation and early mobilization with monitoring and early physiotherapy. Three patients (10%) had unsatisfactory result as two cases had comminution of medial column and one case had undergone previous massage by osteopath which may be cause for stiffness and significant loss of motion.

Table 5: Comparing results with other series

Series	Satisfactory		Unsatisfactory	
	Excellent	Good	Fair	Poor
Bhan S *et al.* [11]	72%	3.20%	21.30%	4.50%
Laud N S *et al.* [12]	0%	94%	2%	4%
Pirone A *et al.* [2]	67%	11%	0%	22%
V Gurkan *et al.* [13]	71.20%	15.40%	5.40%	8%
Our study	73.33%	16.66%	3.33%	6.66%

Conclusion
The supracondylar fracture humerus in children needs accurate anatomical reduction and this can be achieved by close reduction and fixation with K wires mostly percutaneously from lateral condyle which stabilises the fracture fragments and also decompresses haematoma. Cross pinning technique from medial and lateral condyles is theoretically more stable construct biomechanically, but it adds to the risk of ulnar nerve injury. As these fractures unite in 3 to 4 weeks in children, immediate proper management of these fractures is essential to minimize or to avoid immediate and late complications.

References

1. David DA, Bruce IP. Supracondylar Fractures of humerus – a modified technique of closed pinning. CORR 1987;219:174-184.
2. Pirone AM, Graham HR, Krajbich JI. Management of displaced extension –type sypracondylar fractures of the humerus in children. JB JS 1988;70-A(5):641-650.
3. Hamid RM, Charles S. crossed pin fixation of displaces supracondylar humerus fracture in children. CORR 2000;376:56-61.
4. James RK, James HB. Rockwood Green' s fracture in children. 5th ed. Lippincot Williams & Wilkins, 2001.
5. John AH. Tachdjians pediatric orthopedic. 3rded, Saunders 2002.
6. Jeffery LN Malcom LE, Stanley MK, Paul AL Marianne D. Supracondylar fractures of humerus in children treated by closed reduction and percutaneous pinning. CORR 1983;177:203-209.
7. Gartland JJ. Management of supracondylar fracture of humerus in children. S urg. Gyneco. Obstet 1949;109:145-54.
8. Flynn JC, Mathew JC, Beoit RL. Blind pinning of supracondylar fracture of humerus in children. JBJS 1974;56 -A:263-71.
9. Fowles JV, Kassab MT. Displaced supracondylar fractures of the elbow in children. JBJS 1974;56-B:490-500.
10. Charles TM, William MS, Dennis RR, Eric JW, Alvin HC. The effect of surgical timing on the perioperative complications of treatment of supracondylar humerus fractures in children. JBJS 2001;83-A:323.
11. Bhan S. Technique of closed reduction and crossed percutaneous pinning of widely displaced supracondylar fractures of humerus in children. Orthopaedics Today 2003;4:214-8.
12. Laud NS, SHekar Kumta, Suryanarayana. Open reduction of displaced supracondylar fracture of the humerus in children result of 100 consecutive cases. Clinical ortho India 1988;2:41-55.
13. Gurkan V, Orhun H, Akca, Ercan T, Ozel S. Treatment of pediatric displaced supracondylar humerus fractures by fixation with two cross K-wires following reduction achieved after cutting the triceps muscle in a reverse V-shape. Acta orthop traumatol. Turc 2008;42:156-60.