



E-ISSN: 2395-1958
P-ISSN: 2706-6630
IJOS 2021; 7(2): 204-209
© 2021 IJOS
www.orthopaper.com
Received: 24-02-2021
Accepted: 27-03-2021

Dr. Kota Gandhi
Post Graduate, Department of
Orthopaedics, Kamineni
Institute of Medical Sciences,
Narketpally, Telangana, India

Dr. K Haranadh
Associate Professor, Department
of Orthopaedics, Kamineni
Institute of Medical Sciences,
Narketpally, Telangana, India

Osteosynthesis in midshaft humerus fractures with plating versus interlocking intramedullary nailing

Dr. Kota Gandhi and Dr. K Haranadh

DOI: <https://doi.org/10.22271/ortho.2021.v7.i2c.2634>

Abstract

The humerus shaft fractures are treated conservatively for a long time, but now the operative treatment is becoming more common. But the choice of operative intervention in humerus shaft fractures requiring surgical intervention is still a debate. The present study compares functional and radiological outcome of compression plating and intramedullary nailing in management of humerus midshaft fractures. This prospective comparative study over a period of three years in management of acute midshaft humerus fractures with compression plating and antegrade interlocking intramedullary nailing was done. In the period of study total 19 cases with midshaft humerus fractures were included after satisfying the inclusion and exclusion criteria. These patients are randomized and then 10 patients were treated with compression plating and 9 patients were treated with interlocking nailing. Postoperative assessment was done and functional scoring was done by Rodríguez-Merchán criteria and radiological outcome was assessed by serial radiographs. The minimum follow-up period was of 6 months and functional score at the end of 6 month follow up was considered. In this study excellent and good results were relatively higher in compression plating group with less number of complications. However sample size is small in this study. Further such studies are needed.

Keywords: Humerus shaft fractures, compression plating, interlocking intramedullary nailing

Introduction

Fractures of the humeral shaft account for roughly 3% of all fractures; most of them can be treated non-operatively. Traditionally humeral shaft fractures have been treated non-operatively with hanging cast or brace. Though conservative management is the main stay of treatment of humerus shaft fractures it has its demerits such as prolonged limb immobilization, the need for constant co-operation and repeated hospital visits. It also cannot be used in every case. And loss of reduction in the plaster cast invariably leads to malunion. Such fractures require operative line of treatment. The advantages of operative management are early mobilization. But, it also carries risk of technical errors and postoperative complications infections, nerve injuries etc. Early restoration of joint motion return to normal physiologic function and minimal morbidity are now regarded as the current goals of fracture treatment. The optimal method of humeral shaft fracture fixation remains a debate.

Two techniques frequently studied include intramedullary nailing and plate osteosynthesis. With each of them containing varied methods, implants, techniques along with their own set of complications. Plating provides satisfactory results but requires extensive dissection, with stripping of soft tissue, meticulous radial nerve protection and increased chance of infection. The plate may fail in osteoporotic bone. Closed interlocking intramedullary nailing involves minimal surgical intervention, biological fixation, no periosteal stripping, has rotational and torsional stability, anatomical reduction, early mobilization and preservation of hematoma. Complication, especially damage to the rotator cuff is one of the deterrents to intramedullary fixation. Recent studies showed preference to fixation of humeral fracture by plate osteosynthesis. The purpose of this randomized prospective study is to compare the outcomes of fixation of fracture mid shaft of humerus and analyze the results statistically.

Materials and Methods

A Prospective Comparative Study of management of acute mid shaft humerus fractures with

Corresponding Author:
Dr. K Haranadh
Associate Professor, Department
of Orthopaedics, Kamineni
Institute of Medical Sciences,
Narketpally, Telangana, India

compression plating and interlocking intramedullary nailing was conducted after taking prior consent from patients and after approval from the ethics committee at Department of Orthopaedics, Kamineni Institute of Medical Sciences, and Narketpally. The study was performed from October 2018 - September 2020.

19 patients presented to emergency with humerus mid shaft fracture were treated either with compression plating or intramedullary nailing during the period of study. Simple Randomization was done with alternatively placing the patient in the group as they presented starting with plating.

Inclusion criteria: 1. All humeral mid shaft fractures which require operative intervention and treated surgically with Plate Osteosynthesis or Interlocking Intramedullary Nailing. 2. Patients of age 18 years or more.

Exclusion criteria: 1. Patients aged less than 18 years 2. Fracture of upper and lower ends of humerus 3. Patients treated with other than plate osteosynthesis or interlocking intramedullary nailing 4. Patients with pre existing shoulder and elbow problems. 5. Patients with osteomyelitis and bone tumors 6. More than 3 weeks old fractures 7. Patients who were lost to follow up (minimum follow up of six months) or died before the fracture union.

All patients who met the inclusion and exclusion criteria were included in the study after taking informed consent. A thorough history taking and clinical examination was done.

The neurovascular status of the limb and status of radial nerve injury were documented. Radiographs of the arm with shoulder and elbow were taken in both anteroposterior view and lateral view. Additional radiographs were taken if other injuries are suspected. Preoperative evaluation was done. 10 patients were treated with Compression plating and 9 patients were treated with antegrade interlocking intramedullary nailing.

The patients were followed up at 1 month, 3 months and 6 months after surgery. At the time of every follow up patient was examined clinically to assess the wound, tenderness, range of motion of shoulder and elbow, fracture stability and clinical union. Radiographs were taken in anteroposterior and lateral views to assess radiological union. Clinical union is considered to be complete if the fracture site is stable and free from pain. The radiological union is considered to be confirmed if plain radiographs in AP and lateral views showed bone trabeculae or cortical continuity at fracture site on three surfaces on orthogonal radiographs. The time taken for the clinical and radiological union is documented. If there is no clinical or radiological union by 16 weeks, the fracture was categorized as delayed union and if there is no clinical union after 32 weeks it was considered a non union. The functional outcome was measured by using the Rodríguez-Merchán criteria at 6 months or at full recovery whichever is earlier.

Table 1: Rodriguez- Merchán Criteria

Rating	Elbow Range of Movement	Shoulder Range of Movement	Pain	Disability
Excellent	Extension 5° flexion 130°	Full range of movement	None	None
Good	Extension 15° flexion 120°	<10% loss of total range of movement	Occasional	Minimum
Fair	Extension 30° flexion 110°	10-30% loss of total range of movement	With activity	Moderate
Poor	Extension 40° flexion 90°	>30% loss of total range of movement	Variable	Severe

Results and Discussion

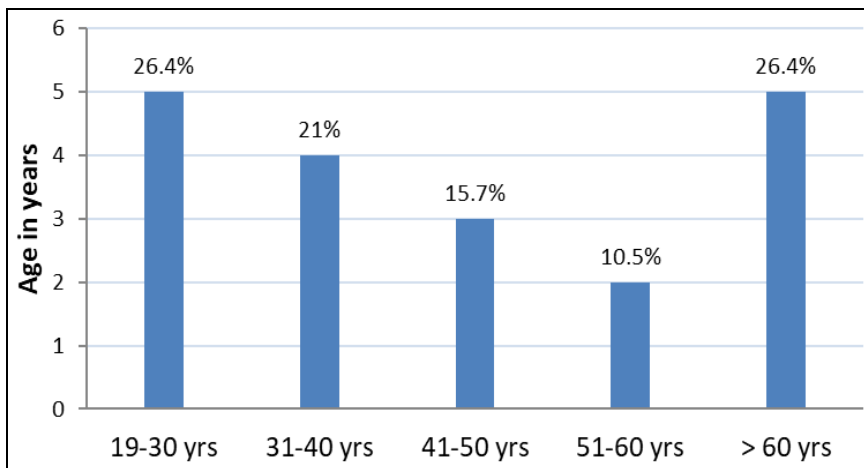
1. There were 19 fractures of midshaft humerus treated during the course of this study.
2. The 19 patients with the distribution being 10 in plating group and 9 in interlocking nailing group.
3. Majority of the patients were females. [11 patients, 58%]. Soumya Ghosh, *et al.* (2013) ^[10], in their study of 60 patients they found that males were prone to injury than females with ratio of 1.72:1. Salem Bajuifer, *et al.* (2018) ^[7], in their study of 100 patients males were 89 and females were 11.
4. The majority of the patients were in the age group of 19-30 years [5 patients, 26.4%] and in the age group of > 60 years [5 patients, 26.4%].

In the literature, majority of humerus mid shaft fractures were

common in the middle age group (30-50 years). In the present study the oldest patient was 75 years old and youngest patient was 23 years old. However the mean age was 45.78years. Nikunj Modi, *et al.* (2013) ^[11], in their study of 48 cases had an average age of presentation as 36.02 years. Salem Bajuifer, *et al.* (2018) ^[7], in their study of 100 patients, they found the mean age of presentation as 39.84 years.

Table 2: Patient Age Distribution (n=19)

S. No	Age In Years	No of Patients	Percentage
1	19-30	5	26.4
2	31-40	4	21.0
3	41-50	3	15.7
4	51-60	2	10.5
5	>60	5	26.4
		19	100



Graph 1: Age wise distribution in the study

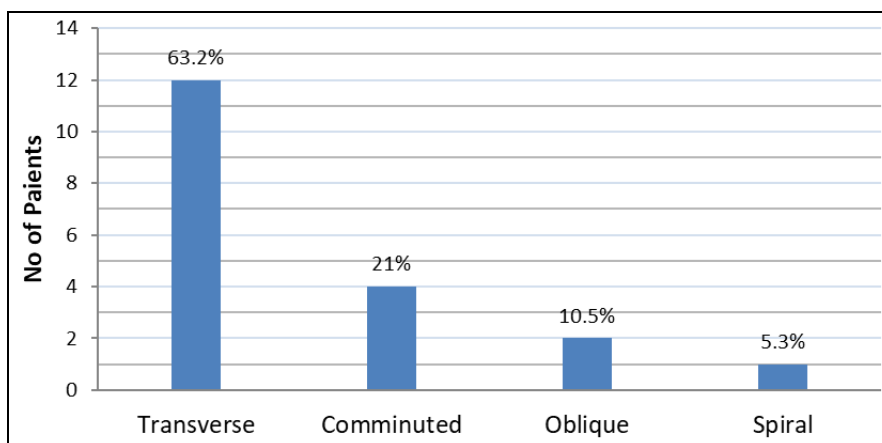
5. Vehicular RTA was the most common cause for injury [11patients, 5.8%]. In the literature, most other studies also observed that trauma due to vehicular Road traffic accidents is the most common cause of humerus mid shaft fractures.
6. Right side was more involved compared to left side [12, 63.2%]. In the literature, majority of fractures were seen on right side. Soumya Ghosh, *et al* (2013) [10], in their study of 60 patients 41 patients were affected on right side and 19 patients were affected on left side. Statistical data not available in other studies but according to Salem Bajuifer, *et al.* (2018) [7] most commonly affected side is the right side. Pratap Singh, *et al.* (2016) [5] stated that injury was more common on right arm because of conditioned protective reflex in using right upper limb more often in a bid to avoid trauma. As > 80% persons are right handed.
7. Most number of patients belongs to occupation of farming. [9 patients, 47.3%]
8. Most number of cases were operated 3 days after time of injury [10, 52.6%] with remaining cases operated within

- 3 days from time of injury [9,47.4%] In the literature, there is no statistical data available regarding the interval between surgery and injury.
9. Transverse type of fracture is most common. [12 patients, 63.2%]

In present study 63.2% of fractures are simple transverse type. Soumya Ghosh, *et al* (2013) [10] in their study of 60 patients noted 66.8% of them are simple transverse type of fractures. Other studies also mention about common occurrence of simple transverse type stating that direct mode of injury may be the reason for this type of fracture pattern.

Table 3: Type of Fracture (n=19)

S. No	Type of Fracture	No of Patients	Percentage%
1	Transverse	12	63.2
2	Comminuted	4	21
3	Oblique	2	10.5
4	Spiral	1	5.3
		19	100



Graph 2: Type of Fractures In The Study

10. Plating group had 9out of 10 patients (90%) with excellent and good results as compared to Interlocking nail group comprising 7 out of 9 patients (77.8%). This difference is clinically significant. However statistically not significant with p-value 0.091.

Soumya Ghosh *et al.* (2013) [10] found that 86.6% of patients of plating group had excellent and good outcome whereas only 80% of interlocking nailing group had excellent and

good outcome. They concluded that for patients requiring surgical treatment of mid shaft humeral fractures, locking plating and interlocking intramedullary nailing both provide statistically comparable results but a higher rate of excellent and good results was seen with locking plating group. Partap Singh *et al.* (2016) [5] concluded that compression plating is gold standard for fracture shaft humerus. While there is no significant difference in the radiological union in the patients treated with interlocking nail and compression

plate, but there is significant decrease in movements of shoulder joint; shoulder stiffness and persistent shoulder pain in patients treated with interlocking nail.

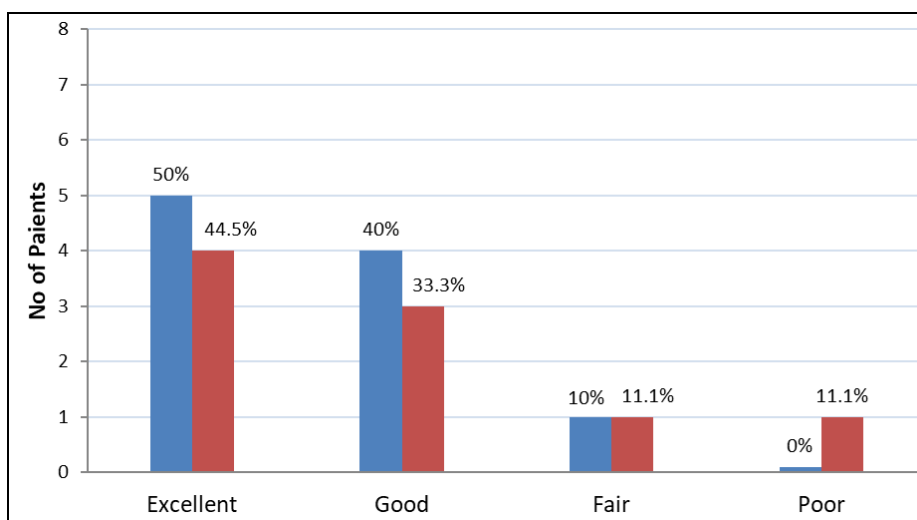
Salem Bajuifer *et al.* (2018) [7] found no significant difference between two procedures with 92% of patients in Plating group had excellent and good outcome while 96% patients of interlocking nail group had excellent and good outcome. They opined Interlocking nailing is technically demanding than

Plating with less blood loss and shorter operative time.

Golam Hashib (2016) [8] in his study of 29 cases observed that 92.3% of patients from plating group and 91% of patients from interlocking nailing group had excellent to good results. He found that though the patients of dynamic compression plating have a better shoulder function than the patients undergoing antegrade humeral interlocking.

Table 4: Type of Fracture

S. No	Result	Plating (n=10)	Percentage%	Interlocking Nailing(n=9)	Percentage%
1	Excellent	5	50	4	44.5
2	Good	4	40	3	33.3
3	Fair	1	10	1	11.1
4	Poor	-	-	1	11.1
		10	100	9	100



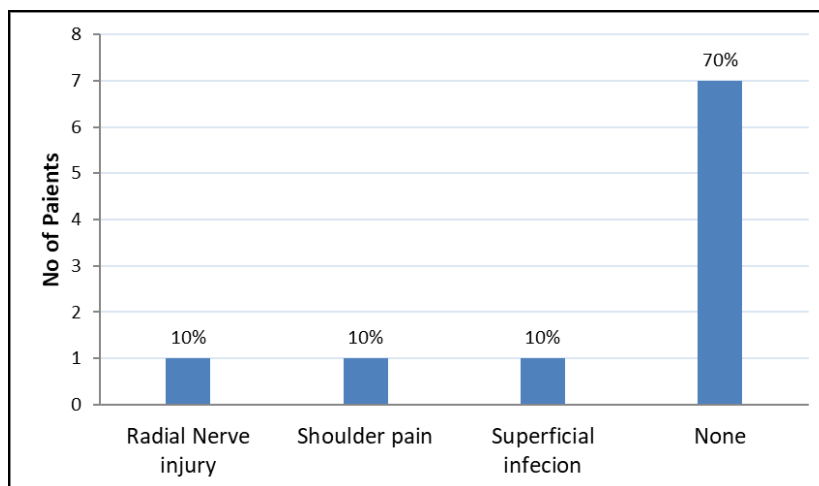
Graph 3: Final functional outcome by Rodriguez-Merchan Criteria

11. In the Plating group (n=10) 3 out of 10 patients had complications.

Radial nerve injury [1 patient, 10%], Shoulder pain [1 patient, 10%] and Superficial infection [1 patient, 10%] remaining 7 patients [70%] had no complications.

Table 5: Complications in plating group (N=10)

	Complication	NO OF Patients	Percentage%
1	Radial Nerve injury	1	10
2	Shoulder pain	1	10
3	Superficial infection	1	10
4	None	7	70
		10	100



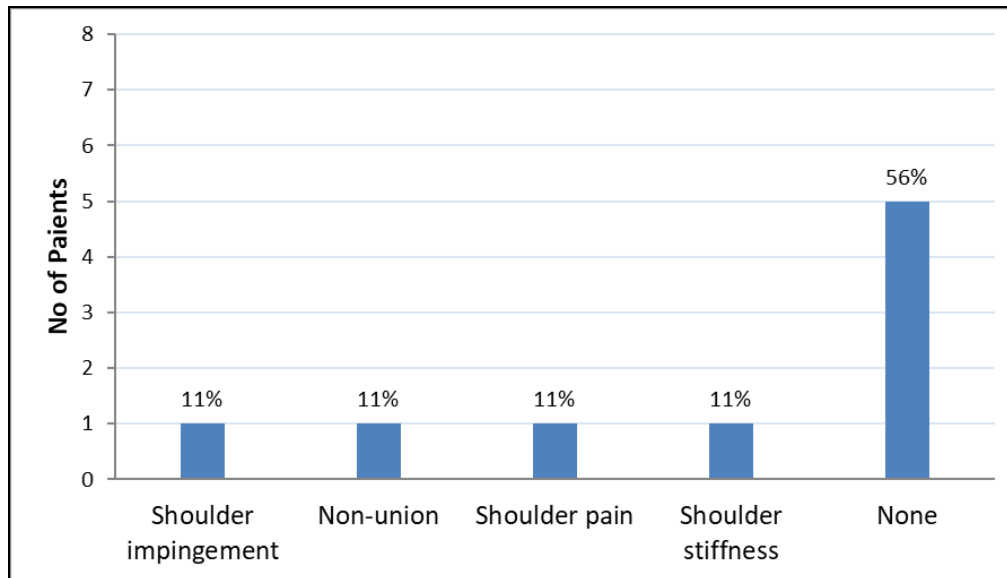
Graph 4: Complications In The Plating Group

12. In the Interlocking Nail group (n=9) 4 out of 9 patients had complications. Shoulder impingement [1 patient, 11%], Non-union [1 patient, 11%], Shoulder pain [1 patient, 11%]

and Shoulder stiffness [1 patient, 11%]. Remaining 5 patients [56%] had no complications.

Table 6: Complications in interlocking nailing group (n=9)

	Complication	No of Patients	Percentage%
1	Shoulder impingement	1	11
2	Non-union	1	11
3	Shoulder pain	1	11
4	Shoulder stiffness	1	11
5	None	5	56
		9	100

**Graph 5:** Complications in the plating group

13. Out of 19 fractures of midshaft humerus treated during the course of this study 3 patients [15.7%] in Plating group, 4 patients [21%] in Interlocking Nail group had complications. 12 patients [63.3%] overall had no complications.

Partap Singh *et al.* (2016) [5] stated that early complications are more in plating like superficial infection, radial nerve neuropraxia with late complications like shoulder pain delayed union and shoulder stiffness in nailing. There was significant decrease in abduction and rotation possible at shoulder joint at final follow up in nailing patients. They concluded that compression plating is gold standard for fracture shaft humerus. While there is no significant difference in the radiological union in the patients treated with interlocking nail and compression plate, but there is significant decrease in movements of shoulder joint; shoulder stiffness and persistent shoulder pain in patients treated with interlocking nail.

Jia-Guo Zhao (2015) [12] In their meta-analysis suggested that the differences between intramedullary nail and plate fixation were not significant in fracture union, radial nerve injury, and infection. But intramedullary nail significantly increased the risk of shoulder complications (shoulder impingement and restriction of shoulder movement) and reoperation. They concluded that plate fixation is superior to intramedullary nail

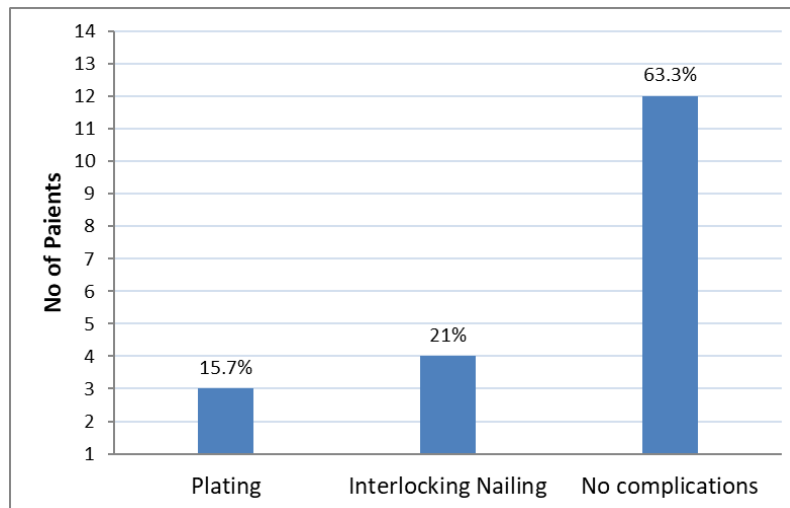
for the treatment of humeral shaft fractures.

He ShengWei (2017) [6] in their stated that the patients of both groups suffered from complications like radial nerve injury in the plating group, but none in the nailing group. Moreover, in the plating group, they found 2 case with incision infection, 2 joint pain, and 2 broken plate; in the nailing group, there was 2 case with disunion, and 2 joint pain.

Pansy NK *et al.* (2017) [9] in their study of 43 patients there were 2 (9.09%) cases in the nailing group and 1 (4.7%) case in the plating group had delayed union. There were 2 (9.5%) cases in plating group which had superficial infection. Post-operative radial nerve palsy was seen in 2 (9.5%) cases in the plating group both of which resolved completely within 3 months of the index surgery. There were 3 (13.6%) cases in the nailing group who had postoperative shoulder stiffness. 1 (4.54%) case however had persisted pain and decreased range of movements till the last follow-up.

Table 7: No of complications in each group (n=19)

S. No	Group	No of Patients	Percentage%
1	Plating	3	15.7
2	Interlocking Nailing	4	21
3	No complications	12	63.3
		19	100



Graph 6: No of complications in each group

Conclusion

Fractures of the mid shaft humerus are one of the common fractures affecting present generation and treatment modality has to be decided carefully. We are of the opinion that conservative treatment holds good for humerus midshaft fractures although operative treatment had advantages such as anatomical fixation and early mobilization. Both the modalities of operative treatment i.e. plate osteosynthesis and interlocking nailing are good as far as union of the fracture is concerned, but considering the functional outcome and rate of complications, we are of the opinion that plating offers better result than interlocking nailing with respect to pain and function of the shoulder joint. We therefore conclude that in cases where both plating and interlocking nailing can be done, we would prefer to use plating, as the results are better than interlocking nailing. The fallacies in our study are, the sample size is small and we have not taken retrograde interlocking nailing in to consideration.

References

- Mast JW, Spiegel PG. Fractures of the humerus shaft. *Clin Orthop* 1975;12:254-262.
- DeLong WG Jr, Born CT, Marcelli E, Shaikh KA, Iannacone WM, Schwab CW. Ender nail fixation in long bone fractures: experience in a level I trauma center. *J Trauma* 1989;29(5):571-576.
- Stern PJ, Mattingly DA, Pomeroy DL, Zenni EJ Jr, Kreig JK. Intramedullary fixation of humeral shaft fractures. *J Bone Joint Surg Am* 1984;66(5):639- 646.
- Sarimento A, Kinman PB, Galvin EG, Schmitt RH, Phillips JG. Functional bracing of fractures of the shaft of the humerus. *J Bone Joint Surg Am* 1977;59:596-601.
- Partap Singh, Vikas Gandhi, Deepak Bansal. Comparative study of compression plating vs. interlocking nail in fracture shaft of humerus. *International Journal of Contemporary Medical Research* 2016;3(11):3385-3388.
- He Sheng Wei, Qinruixian, Li Bin, Du Guangyu, Sun Chuanxiu, Sun Xuegang *et al.* Comparison study of the clinical effect and biomechanics between locking compression plate and interlocking intramedullary nail for humerus shaft fracture. *Biomed Res-India* 2017;28(14):6251-6255.
- Bajuifer S, Shaalan MH, Alamuodi A. Operative Management of Fracture Shaft Humerus by Plate Osteosynthesis and Locked Intramedullary Nail: A Comparative Study. *Orthop Muscular Syst* 2018;7(4):1000262.
- Hashib G. Management of humeral shaft fracture: a comparative study between interlocking nail and dynamic compression plate. *Int J Res Orthop* 2016;2(2):40-47.
- Pansey NK, Sharma GM, Naik LG, Badgire KS, Qureshi F, Jain V. Intramedullary nailing versus plating in shaft humerus fractures: a prospective randomized study. *Int J Res Orthop* 2017;3(3):578-582.
- Ghosh S, Halder TC, Chaudhuri A, Datta S, Dasgupta S, Mitra UK. Comparative study of operative treatment of mid shaft fracture of humerus by locking plate versus intramedullary interlocking nail. *Med J DY PatilUniv.* 2013;6:390-394.
- Modi N, Pundkar GN. Comparative study of functional outcome of Dynamic compression plating with Intramedullary Interlocking nailing in close fracture shaft of humerus in adults. *J Res Med Den Sci* 2015;3(4):298-302.
- Zhao JG, Wang J, Wang C, Kan SL. Intramedullary nail versus plate fixation for humeral shaft fractures: a systematic review of overlapping meta-analyses. *Medicine* 2015;94(11):e599.