

E-ISSN: 2395-1958
P-ISSN: 2706-6630
IJOS 2021; 7(2): 181-187

www.orthopaper.com
Received: 12-02-2021
Accepted: 16-03-2021

Dr. TC Premkumar
M.S. Ortho, D. Ortho, Associate Professor Department of Orthopaedics, Government Thoothukudi Medical College, Thoothukudi, Tamil Nadu, India

Dr. S Rajasekaran
M.S. Ortho, D. Ortho, Associate Professor Department of Orthopaedics, Government Thoothukudi Medical College, Thoothukudi, Tamil Nadu, India

Corresponding Author:
Dr. S Rajasekaran
M.S. Ortho, D. Ortho, Associate Professor Department of Orthopaedics, Government Thoothukudi Medical College, Thoothukudi, Tamil Nadu, India

A study on functional outcome of Talar fractures

Dr. TC Premkumar and Dr. S Rajasekaran

DOI: https://doi.org/10.22271/ortho.2021.v7.i2c.2629

Abstract
Background: Talar fractures are second in frequency among all tarsal bone fractures. Two percent of all lower extremity injuries and 5% to 7% of foot injuries involve fractures of the talus. The role of the talus in lower extremity function, the complexity of the anatomy, and the variability of fracture patterns often complicate treatment of talar fractures and often frustrate orthopaedic surgeon. The primary goal of treatment is to obtain stable, pain free subtalar and ankle joints and restoration of their maximum function.
Aim: To study about the functional outcome of talus fracture following internal fixation by using cannulated cancellous screws.
Materials and Methods: 20 patients [11males and 9 females] admitted in government thoothukudi medical college hospital thoothukudi with ankle injuries with talus fractues were included in this study. All the patients were treated with internal fixation with cannulated cancellous screw fixation. Patients were followed up and assessed for functional outcome with AOFAS scoring and Hawkins grading criteria.
Results: 20 patients with talar fractures admitted at Government Thoothukudi medical college hospital, Thoothukudi were included in the study. All the patients were treated with internal fixation with cannulated cancellous screws. The longest follow up period was 18 months and shortest follow up period was 6 months, mean follow up period was 12 months. Follow up analysis was made using AOFAS scoring and Hawkins grading criteria.
In our study, 65% of patients were less than 30 years of age. 70% of patients were male and there was no significant difference in the side affected (right-9, left-11). Most of the patients sustained injury by fall from height (55%). 55% of patients had fracture of neck of talus among others.
In this study, 40% of patients had excellent outcome, 30% patients had good outcome and 30% had fair outcome, while none had poor outcome.
In this study, only 1 patient developed screw prominence and wound infection, treated with IV antibiotics, and screw removal done. One patient developed avascular necrosis of the talus and one another developed subtalar arthritis, both of them were treated with subtalar arthrodesis.
Conclusion: In conclusion, treatment of fracture of talus with closed / open reduction and screw fixation facilitated early mobilization of the patients and helped achieving stable, pain free subtalar and ankle joints and preventing avascular necrosis of talus and subtalar and ankle joint arthritis.

Keywords: Fracture talus, internal fixation, cannulated cancellous screw fixation

Introduction
Background
Talar fractures are second in frequency among all tarsal fractures. Two percent of all lower extremity injuries and 5% to 7% of foot injuries involve fractures of the talus. The role of the talus in lower extremity function, the complexity of the anatomy, and the variability of fracture patterns often complicate treatment of talar fractures and often frustrate orthopaedic surgeon. The primary goal of treatment is to obtain stable, pain free subtalar and ankle joints and restoration of their maximum function.

Inclusion criteria
Simple and compound fracture of talar body and talar neck upto compound Gr II,
Patient age from 15 to 75 years and both sexes.

Exclusion criteria

- Comorbid conditions not permitting major surgical procedures
- Patients compound Gr III A, B, C Talar Fractures
- Delayed presentations
- Poor skin conditions.

Materials and methods

The prospective study was done in 20 patients with talar fractures treated with Internal fixation with cannulated cancellous screw fixation.in the department of government thoothukudi medical college thoothukudi between may 2020 and march 2021.

All the patients selected for study were examined according to protocol, associated injuries noted and clinical and lab investigations carried out in order to get fitness for surgery. Consent of the patient taken for surgery. Patients were followed till Union was achieved clinically as well as Radiologically Patients underwent a pre-operative evaluation including the following parameters: Hb, blood sugar, RFT, Xray - AP, LAT, and CT ankle with foot – Classification of fracture done.

First Aid; BK slab with adequate padding; Look for Compartment syndrome.

Time interval between injury and surgery: 0 to 14 days.

Anaesthesia: Spinal aneasthesia.

Surgical technique

In this study we have used anteromedial approach (10 cases), anteromedial and posterolateral combined (5), and anteromedial and anterolateral combined (5) approaches for internal fixation. Under C-arm guidance, locate the interdigitating fracture lines medially or laterally for a guide to reduction, even if a gap remains in the opposite cortex. Beginning just posterior to the articular surface of the head on the medial or lateral aspect of the neck, drill two or three small K wires through the neck and into the body to hold the reduction. Depending on the available space for fixation, a 4.0-mm, 4.5-mm, or 6.5-mm partially threaded cannulated screw can be used. In each case, care must be taken to countersink the screw head to provide a flat area for seating of the screw head.

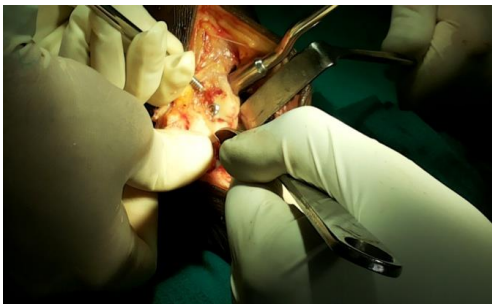

Implants and instruments:

- Cannulated cancellous screws 4mm
- Cannulated screw system
- K wire
- Osteotome

Osteotome and mallet

- Mallet

Post operative protocol

- 1st EOT - 48hrs
- 2nd & 3rd EOT -6th and 9th day

Suture Removal on 12th POD

- Below knee cast applied with ankle in neutral position continued for 6 to 8 weeks.
- Ankle mobilising exercises
- Clinical and radiological features were used to assess the progress of bony union at 4 weeks interval till union was sound.
- As soon as the wound healed, a below knee cast was applied and full weight bearing was not permitted.
- The cast was changed every 4 weeks and continued till union was confirmed with clinico-radiological assessment, upto a period of 3 months.
- Active physiotherapy for regaining ankle mobility were instituted till the range of movement was satisfactory.
- Follow up at 3, 6, 12 months.

Observation

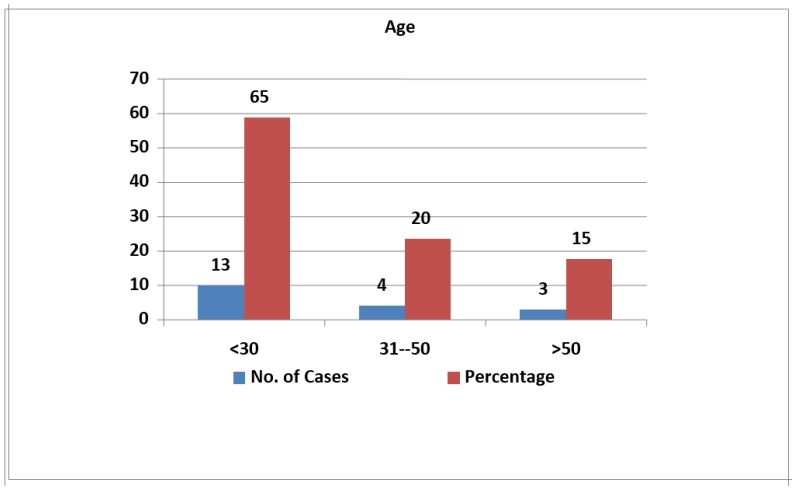

Age

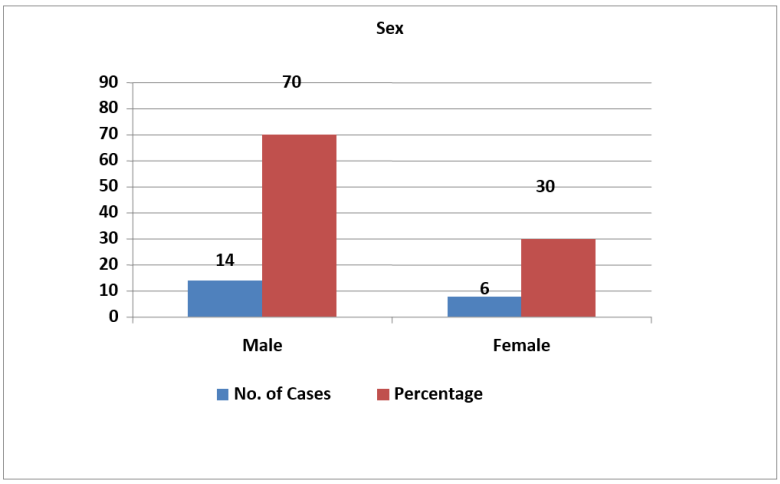

Sex

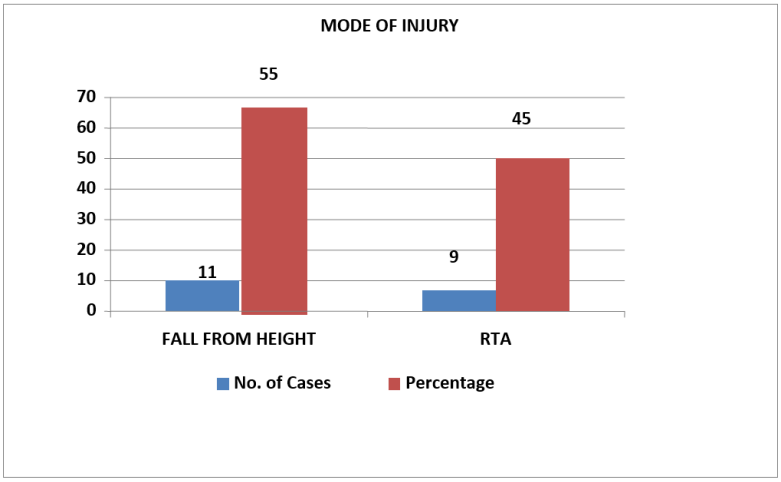

Mode of Injury

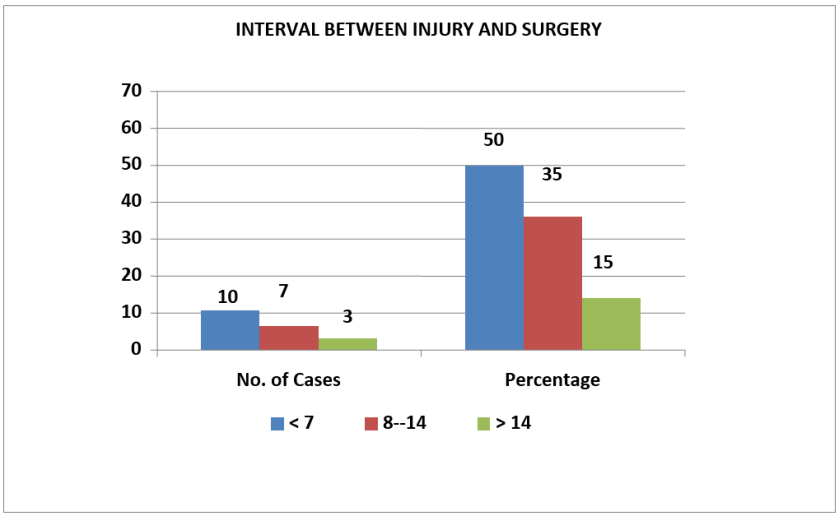

Interval between Injury and Surgery

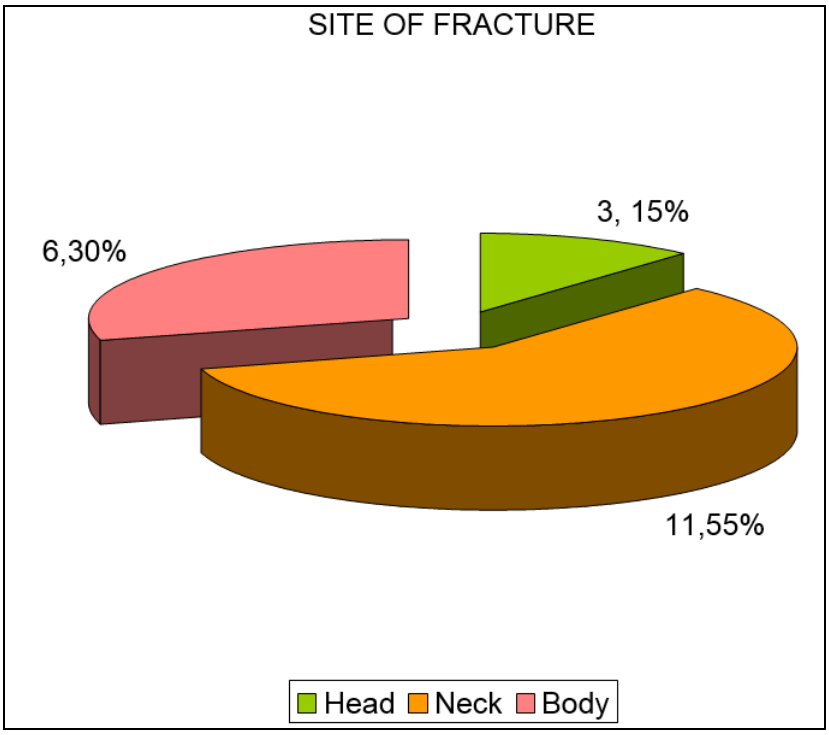

Site of Fracture

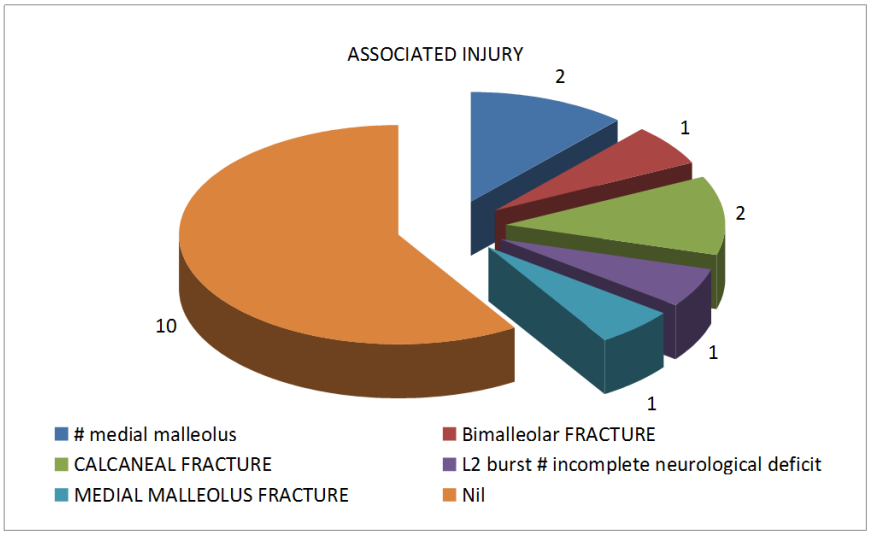

Associated Injury

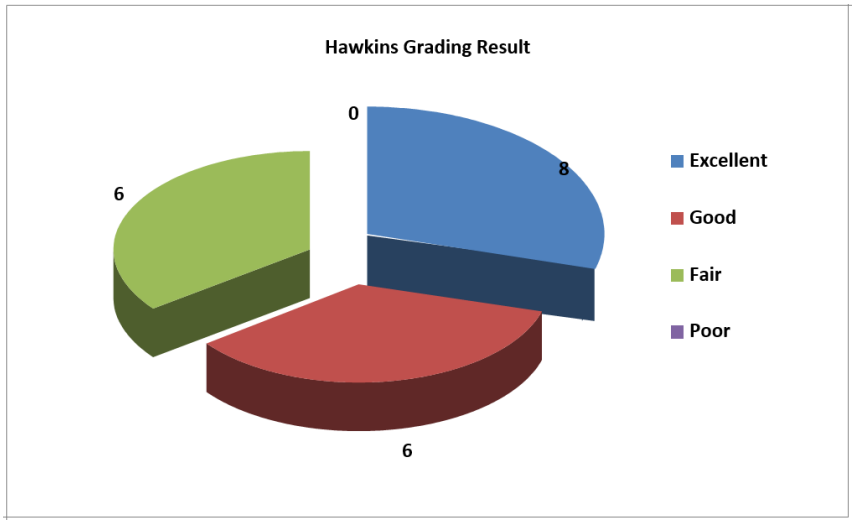

Hawkins Grading Result

Results

20 patients with talar fractures admitted at Government Thoothukudi medical college hospital, Thoothukudi were included in the study. All the patients were treated with internal fixation with cannulated cancellous screws. The longest follow up period was 18 months and shortest follow up period was 6 months, mean follow up period was 12 months. Follow up analysis was made using AOFAS scoring and Hawkins grading criteria.

In our study, 65% of patients were less than 30 years of age. 70% of patients were male and there was no significant difference in the side affected (right-9, left-11). Most of the patients sustained injury by fall from height (55%). 55% of patients had fracture of neck of talus among others.

In this study, 40% of patients had excellent outcome, 30% patients had good outcome and 30% had fair outcome, while none had poor outcome.

In this study, only 1 patient developed screw prominence and wound infection, treated with IV antibiotics, and screw removal done. One patient developed avascular necrosis of the talus and one another developed subtalar arthritis, both of them were treated with subtalar arthrodesis.

Fractures involving talus are rare in orthopaedic practice. The role of the talus in lower extremity function, the complexity of the anatomy, and the variability of fracture patterns often complicate treatment of talar fractures and often frustrate orthopaedic surgeon. The primary goal of treatment is to obtain stable, pain free subtalar and ankle joints and restoration of their maximum function.

Mean age group of our study (32.9%) is agreeable with most of the other studies, Canale and Kelley (30 years), Heppens *et al*. (38 years), Hcomfort (25 years), Kenwright and Taylor (35 years). Though the inclination is towards younger age, this study like others, showed a wide age range of patients (18 to 63).

The present study showed that the ratio of the male and female patients (14:6) is significantly more towards the former which is similar to most other studies, Hcomfort (16:5), Heppens *et al*. (15:5), Kenwright and Taylor (49:9). The high incidence in males in younger age, a period of active physical life can be attributed to more exposure to the injuries.

Most of the studies series (Lorentzen, Hcomfort, Heppens *et al*., Mindal *et al*.) recorded fall from height being the largest group in the patient population (39 to 58%) with talar injuries, followed by fall of heavy weight, RTA, twisting injuries, etc. in our study, fall from height was the most common mode of injury (55%).

In our study, there was more or less equal side distribution (Right-9 Left-11), which is comparable with that reported by Heppens *et al*. (right-11 left-10).

In our study, the incidence of fractures in various parts of talus was comparable with that of others.

Site	Our Study	Adelaar *et al.*	Coltart *et al.*
Head	15%	5-10%	2.6%
Neck	55%	50%	47%
Body	30%	15-20%	9.6%

In our study, associated injuries, medial malleolus (17.7%), bimalleolar (5.9%), calcaneal fractures (11.8%), is comparable with Canale and Kelly series(medial malleolus-14% calcaneum-9%).

Among the Hawkins classification of fracture neck of talus, type II (60%), was found to be more common, similar to other studies, kanale's (type II-42% typeIII-32%), Pantazopoulus (45% type II, 30% type III).

In our study, 29.4% of the injuries were compound and 70.6% were simple, comparable with that of Rudolf's (simple 63%) and Komalf *et al*. (simple 70%).

In our study, we encountered complication in one case screw prominence and mild infection. It was treated with screw removal and antibiotics. Similar complication had been encountered before as in Canale's series (7%).

Another complication encountered during our study was avascular necrosis of the talus, for which subtalar arthrodesis was performed. Avascular necrosis, in past studies had been common, following fracture dislocation of the talar neck, Coltart (25%), Hawkins (58%), Lorentzen (21%).

One patient in our study developed arthritis following open reduction and screw fixation. Subtalar arthrodesis was performed, followed by early mobilisation, limb elevation and use of proteolytic enzymes per orally. Coltart had reported 50% of subtalar arthrosis and 5% of ankle arthrosis in his study.

Inspite of such complications associated with these fractures, and their management using this technique, according to American orthopaedic foot and ankle society(AOFAS) score, we achieved a score of 91 or above for 12 cases. Hawkin's functional outcome grading was excellent (8 cases-40%), good (6 cases-30%), fair (6cases-30%) results and none of them had poor results.

Discussion

Fractures involving talus are rare in orthopaedic practice. The role of the talus in lower extremity function, the complexity of the anatomy, and the variability of fracture patterns often complicate treatment of talar fractures and often frustrate orthopaedic surgeon. The primary goal of treatment is to obtain stable, pain free subtalar and ankle joints and restoration of their maximum function.

Mean age group of our study (32.9%) is agreeable with most of the other studies, Canale and Kelley (30 years), Heppens *et al*. (38 years), Hcomfort (25 years), Kenwright and Taylor (35 years). Though the inclination is towards younger age, this study like others, showed a wide age range of patients (18 to 63).

The present study showed that the ratio of the male and female patients (14:6) is significantly more towards the former which is similar to most other studies, Hcomfort (16:5), Heppens *et al*. (15:5), Kenwright and Taylor (49:9). The high incidence in males in younger age, a period of active physical life can be attributed to more exposure to the injuries.

Most of the studies series (Lorentzen, Hcomfort, Heppens *et al*., Mindal *et al*.) recorded fall from height being the largest group in the patient population (39 to 58%) with talar injuries, followed by fall of heavy weight, RTA, twisting injuries, etc. in our study, fall from height was the most common mode of injury (55%).

In our study, there was more or less equal side distribution (Right-11, Left-9), which is comparable with that reported by Heppens *et al*. (right-11 left-10).

In our study, the incidence of fractures in various parts of talus was comparable with that of others.

Site	Our Study	Adelaar *et al.*	Coltart *et al.*
Head	15%	5-10%	2.6%
Neck	55%	50%	47%
Body	30%	15-20%	9.6%

In our study, associated injuries, medial malleolus (17.7%), bimalleolar (5.9%), calcaneal fractures (11.8%), is comparable with Canale and Kelly series (medial malleolus-14% calcaneum-9%).

Among the Hawkins classification of fracture neck of talus, type II (55%), was found to be more common, similar to other studies, kanale's (type II-42% typeIII-32%), Pantazopoulus (45% type II, 30% type III).

In our study, 29.4% of the injuries were compound and 70.6% were simple, comparable with that of Rudolf's (simple 63%) and Komalf *et al*. (simple 70%).

In our study, we encountered complication in one case, screw prominence and mild infection. It was treated with screw removal and antibiotics. Similar complication had been encountered before as in Canale's series (7%).

Another complication encountered during our study was avascular necrosis of the talus, for which subtalar arthrodesis was performed. Avascular necrosis, in past studies had been common, following fracture dislocation of the talar neck, Coltart (25%), Hawkins (58%), Lorentzen (21%).

One patient in our study developed arthritis following open reduction and screw fixation. Subtalar arthrodesis was performed, followed by early mobilisation, limb elevation and use of proteolytic enzymes per orally. Coltart had reported 50% of subtalar arthrosis and 5% of ankle arthrosis in his study.

Inspite of such complications associated with these fractures, and their management using this technique, according to American orthopaedic foot and ankle society (AOFAS) score, we achieved a score of 91 or above for 12 cases. Hawkin's functional outcome grading was: excellent (8 cases-40%), good (6 cases-30%), fair (6cases-30%) results and none of them had poor results.

Conclusions

Based on the results of the study following conclusions were made:

- For all cases of talar fractures with displacement, open reduction and screw fixation helped to achieve pain free, stable ankle and subtalar joints.
- Among all the approaches discussed above, combined anteromedial and antero lateral approach helped better visualization of talar neck and talar body for good fixation.
- The screw can be fixed either anterior to posterior direction or from posterior to anterior direction. But posterior to anterior directed screws are biomechanically stronger.

In conclusion, treatment of fracture of talus with open reduction and screw fixation facilitated early mobilization of the patients and helped achieving stable, pain free subtalar and ankle joints and preventing avascular necrosis of talus and subtalar and ankle joint arthritis.

References

1. Canale ST, Kelly FB Jr: Fractures of the neck of the talus. J Bone Joint.
2. Devalia KL, Ismaiel AH, Joseph G, Jersy MG. Fourteen years follow up of an unclassified talar body fracture with review of literature. Foot ankle surg 2006;12:85-88.
3. Elgafy H, Ebraheim NA, Tile M *et al*. Fractures of the talus: experience of two level 1 trauma centers. Foot Ankle Int 2000;21:1023-1029.
4. Fortin PT, Balazsy JE. Talus fractures: evaluation and treatment. J Am Acad Orthop Surg 2001;9:114-127.
5. Frawley PA, Hart JA, Young DA. Treatment outcome of major fractures of the talus. Foot Ankle Int 1995;16:339-345.
6. Haliburton RA, Sullivan CR, Kelly PJ, Peterson LF: The extra-osseous and intra-osseous blood supply of the talus. J Bone Joint Surg Am 1958;40:1115-1120.
7. Hawkins LG: Fractures of the neck of the talus. J Bone Joint Surg Am 1970;52:991-1002.
8. Higgins TF, Baumgaertner MR. Diagnosis and treatment of fractures of the talus: a comprehensive review of the literature. Foot Ankle Int 1999, 20:595-605. Surg Am 1978;60:143-156.
9. Inokuchi S, Ogawa K, Usami N. Classification of fractures of the talus: clear differentiation between neck and body fractures. Foot Ankle Int 1996;17:748-750.
10. Isefuku S, Hatori M. Talar fractures associated with ipsilateral femoral shaft fractures: report of three cases. Arch Orthop Trauma Surg 2005;125:142-144
11. Lindvall E, Haidukewych G, Di Pasquale T, Herscovici D Jr, Sanders R. Open reduction and stable fixation of isolated, displaced talar neck and body fractures. J Bone Joint Surg Am 2004;86:2229-2234
12. Mendonca AD, Maury AC, Makwana NK. Case report: A simultaneous fracture of the tibia and talar body. Foot and Ankle Surgery 2004;10:45-47.
13. Morgan G, Ramaswamy R, Frost B, Hariharan K. Talar body fractures: A case report of successful surgical

management and review of the literature. Injury Extra 2007;38:39-42
14. Rammelt S, Zwipp H. Talar neck and body fracturesInjury. Int J Care Injured 2009;40:120-135.
15. Schulze W, Richter J, Russe O, *et al*.: Surgical treatment of talus fractures: a retrospective study of 80 cases followed for 1-15 years. Acta Orthop Scand 2002;73:344-351.
16. Sneppen O, Christensen SB, Krogsoe O *et al*. Fracture of the body of the Talus. Acta Orthop Scand 1977;48:317-324.
17. Swanson TV, Bray TJ, Holmes GB Jr. Fractures of the talar neck. A mechanical study of fixation. J Bone Joint Surg Am 1992;74:544-551.
18. Tezval M, Dumont C, Sturmer KM. Prognostic reliability of the Hawkins sign in fractures of the talus. J Orthop Trauma 2007;21:538-543.
19. Thordarson DB: Talar body fractures. Orthop Clin North Am 2001;32:65-77.
20. Vallier HA, Nork SE, Benirschke SK, Sangeorzan BJ. Surgical treatment of talar body fractures. J Bone Joint Surg Am 2003;85:1716-1724.
21. Verettas DAJ, Ververidis A, Drosos GI, Chatzipapas CN, Kazakos KI. Talar body fracture combined with bimalleolar fracture. Arch Orthop Trauma Surg 2008;128:731-734