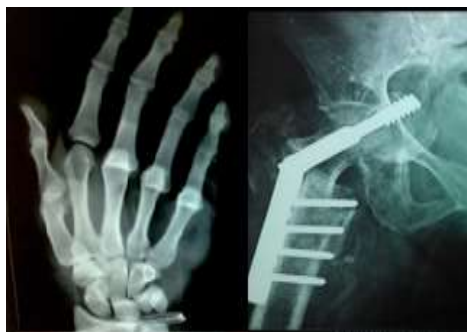



International Journal of Orthopaedics Sciences

E-ISSN: 2395-1958
P-ISSN: 2706-6630
IJOS 2021; 7(2): 43-52
© 2021 IJOS
www.orthopaper.com
Received: 19-02-2021
Accepted: 23-03-2021

Dr. Vijay Krishnan K
AJ Institute of Medical Sciences,
NH 66, Kuntikana, Mangalore,
Karnataka, India

Dr. Sudeep Shetty
AJ Institute of Medical Sciences,
NH 66, Kuntikana, Mangalore,
Karnataka, India

Dr. Bhaskar Bhandary
Associate Professor, AJ Institute
of Medical Sciences, NH 66,
Kuntikana, Mangalore,
Karnataka, India

Study of functional outcome following proximal humeral internal locking system plating for displaced proximal humeral fractures

Dr. Vijay Krishnan K, Dr. Sudeep Shetty and Dr. Bhaskar Bhandary

DOI: <https://doi.org/10.22271/ortho.2021.v7.i2a.2612>

Abstract

Proximal humerus fractures accounts for about 4 to 5% of all fractures. They are the third most common fractures in elderly population after hip and distal radius fractures. Regarding treatment of proximal humerus fractures, controversies still exists whether to do conservative or operative management. Various operative procedures are carried out, recent trend in internal fixation has moved on to locking plates. The present study is undertaken to evaluate the functional outcome and complication of proximal humerus fractures treated by philos locking plate. This is a prospective study involving adults (>18yrs) with proximal humerus fractures admitted to AJ Institute of medical sciences and research centre, Mangalore. In this study period 30 cases of fractures of proximal humerus were treated by open reduction and internal fixation with Philos locking plate were evaluated. In our series, majority of the patients were males with road traffic accident being the commonest mode of injury involving 2 part, 3 part and 4 part fractures of proximal humerus and fracture dislocations. The fractures united in all 30 patients. Among the 30 patients 2(6.7%) patients had an excellent outcome, 10(33.3%) patients had a good outcome, 13(43.3%) patients had a fair outcome, and 5(16.7%) patients had a poor outcome according to constant and murley scoring system. In conclusion Philos locking plate is an advantageous implant in proximal humeral fractures due to angular stability, particularly in comminuted fractures and in osteoporotic bones in elderly patients, thus allowing early mobilization.

Keywords: Proximal humerus fractures, philos locking plate, open reduction and internal fixation

Introduction

The field of orthopaedic surgery has been in the vanguard in creating new information, establishing new principles of treatment and solving both new and old problems of musculoskeletal system. Fractures of proximal humerus is still unsolved fractures in many ways. Disagreement exists regarding reliability of classification system. The indication for surgical management continue to be modified. Fixation technique are myriad and none is ideal for all cases Fractures of proximal humerus are not uncommon especially in older age group. They have been reported to account 4% of all fractures about 85% of these fractures are minimally displaced or undisplaced and are effectively treated symptomatically with immobilization followed by early motion. The remaining 15% of fractures are displaced unstable and may have disruption of the blood supply. The treatment of these fractures is therapeutic challenge. Displaced and unstable extra-articular fractures are most commonly treated by operative reduction and fixation using various technique Three and four part fractures (13-16% of proximal humerus fractures) have been a challenge to achieve stable fixation the treatment is more controversial for articular fractures which carry a high risk of the humeral head necrosis. In neer's classification, these are two part anatomical neck, three-part and four-part fracture and those with dislocation of head of humerus. A review of published result suggests that there is no universally accepted form of treatment. Conservative management may be associated with non union, malunion, and avascular necrosis resulting in painful dysfunction Proximal humeral fracture, whether caused by trauma (or) related to osteoporosis, requires carefully planned, individual treatment. Difficulties have been multifactorial, including osteoporotic bone, angular instability, implant impingement, loss of reduction and backing out of screws.

Corresponding Author:
Dr. Vijay Krishnan K
AJ Institute of Medical Sciences,
NH 66, Kuntikana, Mangalore,
Karnataka, India

The indication for fixing such a fracture depends on the fracture pattern, quality of bone and the age and activity of the patient the goal is to achieve near-anatomical reduction and stabilization so as to achieve early mobilization. The incidence of proximal fractures is 26% of all humerus fractures. They occur most commonly in the elderly. In younger patients, high-energy trauma is the cause and displacement is often more severe. A wide variety of treatment options have been described beginning with percutaneous fixation, non-absorbable rotator cuff-incorporating sutures and the use of tension band devices, intramedullary nails. Methods of open reduction and internal fixation with the more contemporary use of locking plates advocated recently. The role of hemiarthroplasty in the treatment of these fractures has also been advocated in both the acute setting and as a delayed procedure. Current therapeutic options for proximal humerus fractures are humerus nails, plates, tension band wiring, and percutaneous (or) minimally invasive technique such as pinning, intramedullary flexible nails, screw osteosynthesis and hemiarthroplasties. The choice of technique and devices depends on quality of bone, soft tissue, age and reliability of patients. However the goal of proximal humerus fracture fixation should be stable reduction allowing early motion of fracture. PHILOS plate provides rigid fixation and more angular stability this study is conducted to analyse fractures of the proximal humerus that were treated with the proximal humeral internal locking system (PHILOS) plate and document their clinical and functional outcome.

Materials and Methods

Source of the data

Adults (>18yrs) with proximal humerus fractures admitted to A J Institute of medical sciences and research centre, Mangalore

Method of collection of data

This is a clinical, prospective and observational study which includes patients with proximal humerus fractures admitted and examined according to protocol, associated injuries noted. Clinical and radiological evaluation done. Fractures classified Using Neer's classification. Routine investigation carried out to get fitness for surgery. Patients will undergo Open reduction internal fixation with philos locking plating for the sustained fracture under general anaesthesia. Post operative physiotherapy followed according to protocol, to evaluate the functional outcome. Patients will be followed up at 6 weeks, 12 weeks and at 6 months. A minimum of 30 cases will be studied without any sampling procedure.

Inclusion criteria

All skeletally mature patients presenting with displaced proximal humerus fractures according to NEER two, three and four part fracture. Patients with associated dislocation of the shoulder.

Exclusion criteria

Pathologic fractures from primary or metastatic tumours. Patients age less than 18 years. Open fractures. Poly trauma. Failure of conservative treatment. Four part fracture in elderly (>65 years). On admission of the patient a careful history was elicited from the patients and or attendants of injury and the severity of trauma. The patients were then assessed clinically to evaluate their general condition and the local injury. The general condition of the patient and the vital signs were recorded. Methodical examination was done to rule out

fractures at other sides. The local examination of injured shoulder was done for swelling, deformity, loss of function and altered attitude. Any nerve injury was also looked for and noted. Local neurologic deficit of axillary nerve was also assessed by looking for anaesthetic patch over lateral aspect of shoulder. Radiograph of proximal humerus i.e., antero-posterior view and axillary view were taken and fractures were classified according to Neer's classification. Next the limb was immobilized in U-slab and arm-pouch. The patient was taken for surgery after routine investigation and after obtaining physician fitness towards surgery. The investigations are as follows: Hb%, urine for sugar, FBS, blood urea, serum creatinine, HIV, HbsAg and ECG.

The consent for surgery was also taken from the patient and attendants after explaining the procedure and possible complications. Limb was shaved from shoulder to hand including axilla 1 day before the surgery. Injection Tetglobe and antibiotics were given 1 hour preoperatively.

Operative Techniques

General anesthesia was used in all patients.

Patient position and draping

Patients placed in supine position on operating table with wedge a sandbag under the spine and medial border of scapula to push the affected side forward while allowing the arm to fall backward. Drape the arm free, because it will have to be moved during the approach.

Surgical Approaches

Surgical approaches used is Deltopectoral approach. Deltopectoral approach: Incision starts just above the coracoid process, which is palpated in deepest point in the clavicular concavity distally towards acromioclavicular joint. An 8 to 10cm incision started from just above coracoid process advanced following the line of deltopectoral groove. The internervous plane is between the deltoid muscle which is supplied by axillary nerve and the pectoralis major muscle, which is supplied by the medial and lateral pectoral nerves. Retract pectoralis major medially and deltoid laterally, splitting the two muscle apart. The vein is retracted either medially or laterally. The short head of biceps and the coracobrachialis must be displaced medially before access can be gained to anterior aspect of shoulder joint. Beneath the tendons lie the transversely running fibers of subscapularis muscle. Apply external rotation to the arm to stretch the subscapularis, bringing the muscle belly into wound and making its superior and inferior borders easier to define. Pass a blunt instrument between the capsule and the subscapularis, then divide the subscapularis in from insertion onto to the lesser tuberosity of humerus. Incise the capsule longitudinally to enter the joint wherever the selected repair must be performed.

Procedure

All patients received a prophylactic dose of 4.5 gm of piperacillin-tazobactam intravenously preoperatively. The operation was done in supine position with small sand bag under shoulder, under general anesthesia. Through deltopectoral approach, the fracture was exposed and reduced with minimal soft tissue dissection. Briefly, the anatomical relationship between humeral head and greater tuberosity was reduced and fixed temporarily with K wires. In case of obvious rotation or displacement of the humeral head, a joystick technique was used. Then the shaft fragment was

reduced by abduction, traction and rotation of the arm. Reduction was checked under image intensifier. Definitive fixation with locking plate was done with plate positioned lateral to bicipital groove sparing tendon of long head of biceps and 1cm distal to greater tuberosity. The screws were chosen according to preoperative planning, and all the four head screws were supposed to be inserted to the head fragment. The inferior screws supporting the humeral head were considered critical. Proximal locking screws were inserted to hold the humeral head, which are multidirectional screws with the tips of the screws staying 5–10 mm away from the articular surface. All proximal locking screws were placed in a unicortical fashion through an external guide and confirmed to be within the humeral head with intraoperative fluoroscopy. AP (internal and external rotation) views and axillary views 90 degrees to each other were used to visualize screw placement. The distal shaft screws were placed bicortically. A minimum of three bicortical screws were used. Fluoroscopic images were taken to confirm satisfactory fracture reduction, plate positioning and proper length of screws in the humeral head. In case of severe comminution or instability, the rotator cuff, the greater tuberosity, and the lesser tuberosity were fastened to the plate using non-absorbable sutures. Range of motion of shoulder was checked on the table for impingement. Wound was closed under negative suction, which was removed after 48 hours.

Post operative management

All patients are immobilized in arm pouch with cuff and collar sling. Appropriate antibiotics and analgesics were used. Immediate post operative radiographs were taken to determine the bone alignment and maintenance of reduction. Sutures removed by 12th day Passive range of motion and

pendulum exercises are begun immediately depending on pain.

Follow up

All patients were followed up at 6weeks, 12 weeks and at 6 months.

Exercise regime post philos plating

I. POD 1 TO 3 Weeks

Post operatively arm pouch was applied for all patients for 3 weeks. Post op day 1 patients were started on pendulum exercises with arm pouch.

II. 3 Weeks TO 6 Weeks

At 3 weeks arm pouch was removed and started on active assisted external rotation to neutral and active assisted flexion.

III. After 6 Weeks

Patients were allowed full range of movements.

Functional results

Final results are assessed using the Constant and Murley scoring system.

Constant and murley scoring system

This scoring system consists of four variables that are used to assess the function of the shoulder. The right and left shoulders are assessed separately the subjective variables are pain and ADL (sleep, work, recreation / sport) which give a total of 35 points. The objective variables are range of motion and strength which give a total of 65 points. Altogether a total of 100 points.

Category	Score
Pain	(15 points)
None	15
Mild	10
Moderate	5
Severe	0
Activities of daily living	(20 points)
Activity level	
Full work	4
Full recreation / sport	4
Unaffected sleep	2
Positioning	
Up to waist	2
Up to xiphoid	4
Up to neck	6
Up to top of head	8
Above head	10
Range of motion	(40 points)
Forward elevation	
0° – 30°	0
31° – 60°	2
61° – 90°	4
91° – 120°	6
121° – 150°	8
151° – 180°	10
Lateral elevation	
0° – 30°	0
31° – 60°	2
61° – 90°	4
91° – 120°	6
121° – 150°	8
151° – 180°	10

External rotation	
Hand behind head with elbow held forward	2
Hand behind head with elbow held back	2
Hand on top of head with elbow held forward	2
Hand on top of head with elbow held back	2
Full elevation from on top of head	2
Internal rotation	
Dorsum of hand to lateral thigh area	0
Dorsum of hand to buttock	2
Dorsum of hand to lumbosacral junction	4
Dorsum of hand to waist (third lumbar vertebra)	6
Dorsum of hand to twelfth dorsal vertebra	8
Dorsum of hand to interscapular region (DV 7)	10
Strength	35

Difference between both the shoulders are calculated and it is graded accordingly

- <11 Excellent
- 11-20 Good
- 21-30 Fair
- >30 Poor

Instruments



Fig 1: Philos instruments-(1)5,6,7,8,10,12 hole philos plate, (2) locking and cortical screws, (3) depth gauge, (4) drill sleeve, (5) drill bit, (6) locking and non locking screw driver, (7) sleeve guide

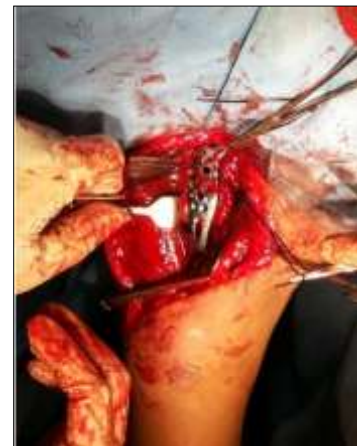
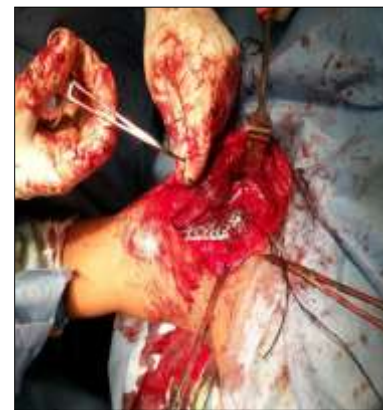
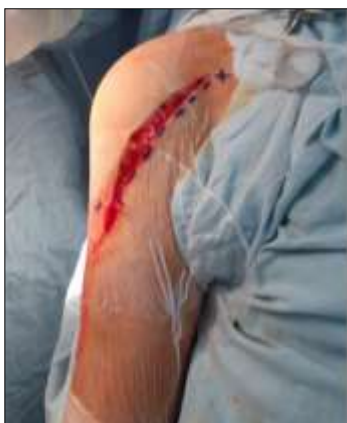Plate Positioning

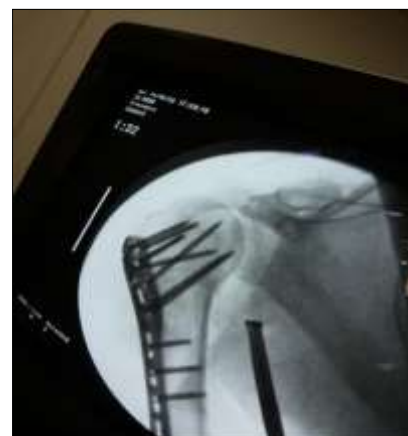

Fixation of plate and screws

Intra Operative Images



Draping and incision



Confirmation of reduction under c arm

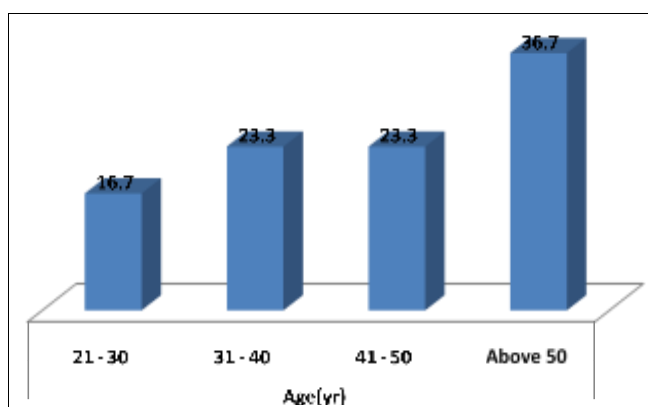
Results

Thirty patients with closed displaced proximal humerus fracture were treated by open reduction and internal fixation with PHILOS plate. The following observations were made from the data collected during this study.

Table 1: Age Distribution

Age in year	Frequency	Percent
21 – 30	5	16.7
31 – 40	7	23.3
41 – 50	7	23.3
Above 50	11	36.7
Total	30	100.0

Majority of the patients i.e. 11 (37%) were from age group of 51-62 years followed by 7 patients (23%) in 41-50 years followed by 7 patients (23%) in 31-40 years and 5 patients (17%) in 21-30 age group. The average age of patient was 43.7 years.



Graph 1: Age Distribution

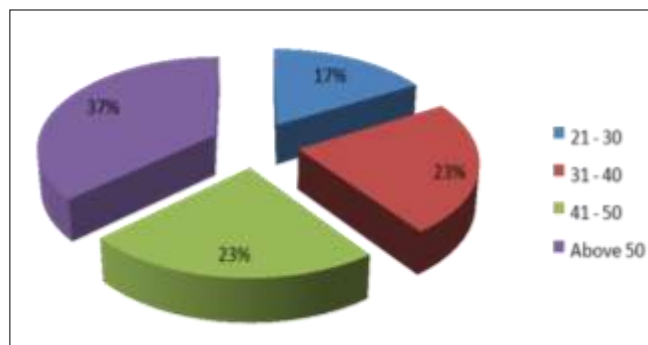
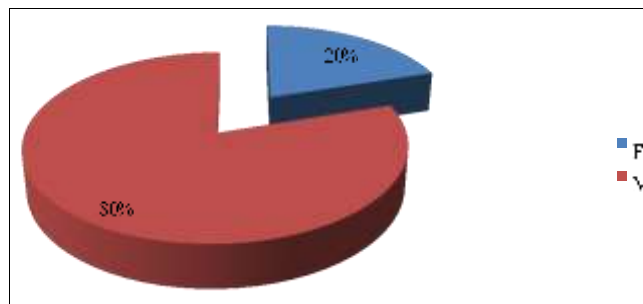


Table 2: Sex Distribution

Sex	Frequency	Percent
F	6	20.0
M	24	80.0
Total	30	100.0

Majority of the patients were males i.e. 80% and 20% were females. Male: Female sex ratio is 4:1

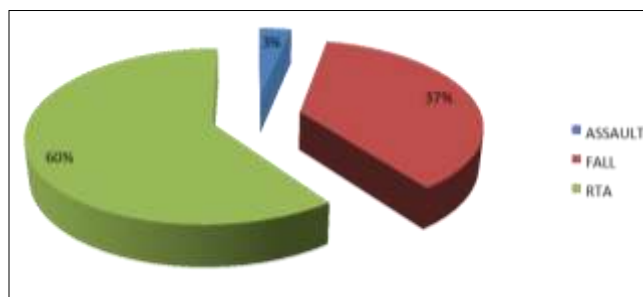


Graph 2: Sex Distribution

Table 3: Mode of Injury

Mode of injury	Frequency	Percent
Assault	1	3.3
Fall	11	36.7
RTA	18	60.0
Total	30	100.0

In majority 18(60%) of cases the mode of injury was RTA. These were high energy trauma directly or indirectly to shoulder. 11(37%) of the cases were due to fall and 1(3%) due to assault.

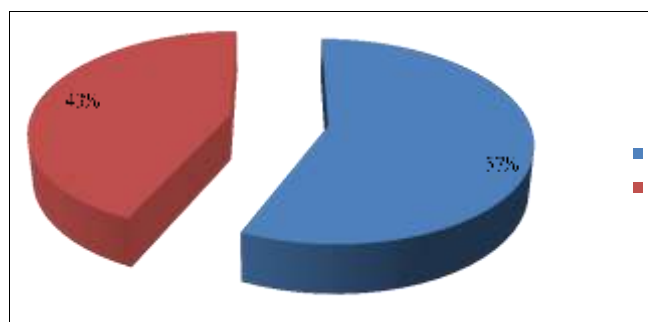


Graph 3: Mode of Injury

Table 4: Side Affected

	Frequency	Percent
L	17	56.7
R	13	43.3
Total	30	100.0

The fracture occurred right in 13 patients (43%) and left side in 17 patients (57%)

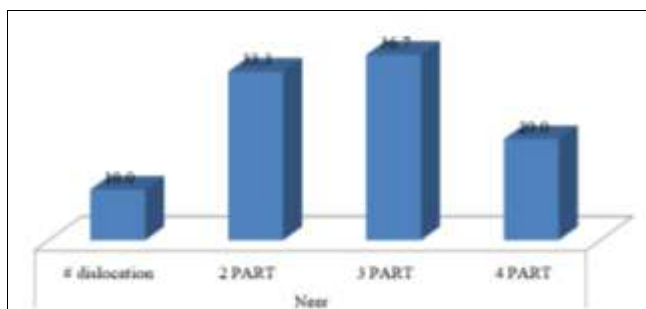


Graph 4: Side Affected

Table 5: Fracture Pattern

Fracture pattern	Frequency	Percent
# dislocation	3	10.0
2 PART	10	33.3
3 PART	11	36.7
4 PART	6	20.0
Total	30	100.0

In our study we had 10 cases (33%) with 2 part fracture surgical neck humerus and 11 (37%) cases with 3 part (greater tuberosity and surgical neck) fractures. 6(20%) case with 4 part (greater tuberosity, lesser tuberosity and surgical neck). 3(10%) cases with fracture dislocation.

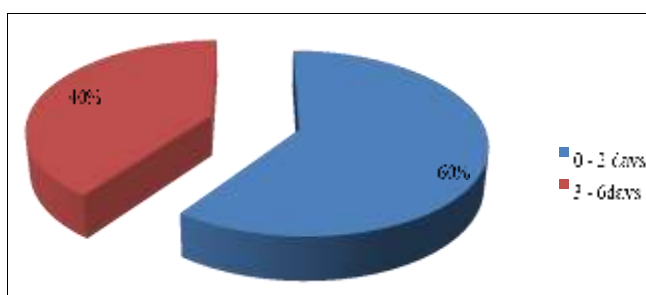


Graph 5: Fracture Pattern

Table 6: Timing of Surgery

Timing of surgery	Frequency	Percent
0 - 2 days	18	60.0
3 - 6days	12	40.0
Total	30	100.0

In 18 patients (60%), surgery was done within 2 days after admission. But in 12 patients (40%) surgery was delayed upto 6days due to underlying co-morbidities like uncontrolled diabetes mellitus, hypertension etc

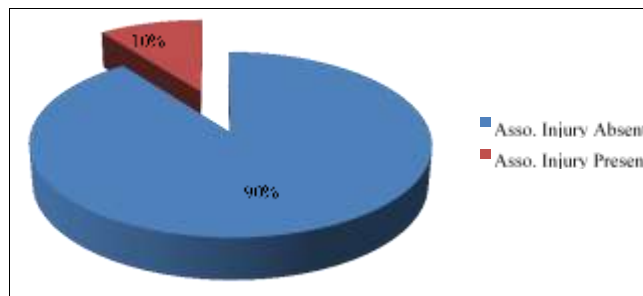


Graph 6: Timing of Surgery

Table 7: Associated Injuries

Associated injuries	Frequency	Percent
Absent	27	90.0
Present	3	10.0
Total	30	100.0

In 3 patients (3%) had associated injuries even though polytrauma cases were excluded in the study. 27 patients (90%) did not have any other injuries



Graph 7: Associated Injuries

Method of treatment

All patient underwent open reduction and internal fixation with philos plate.

Time of surgery

The average interval between admission and surgery was 2.06 days.

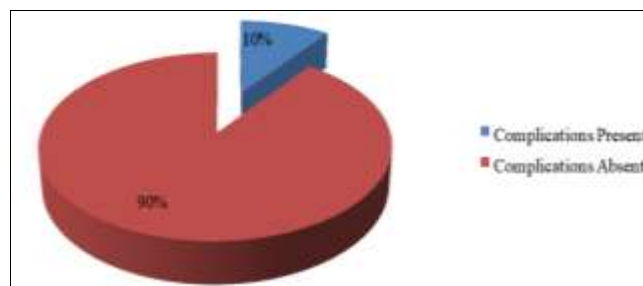
Stay in hospital

The average hospital stay in our study was 7 days

Table 8: Complications

	Frequency	Percent
Present	3	10.0
Absent	27	90.0
Total	30	100.0

There were 3 (10%) cases with varus malunion, but all patients had comparatively fair functional range of movements.



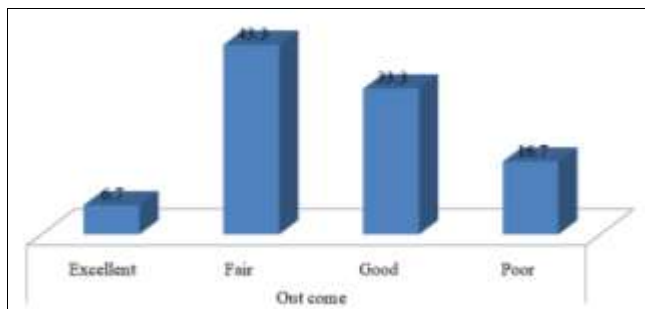
Graph 8: Complications

Functional Results: All fracture united by 8-12 weeks interval. The final results were evaluated by constant and murley scoring system

Table 9: Results according to constant and murley score

	Frequency	Percent
Excellent	2	6.7
Fair	13	43.3
Good	10	33.3
Poor	5	16.7
Total	30	100.0

In our study 2 (7%) case had excellent result, 10 (33%) had good result and 13(43%) had fair result. 5(17%) had poor result and there was no case of failure.



Graph 9: Results according to constant and murley score

Discussion

Displaced proximal humeral fractures are a challenge for orthopaedic surgeons. Undisplaced fractures can be treated conservatively. There are many options for the management of proximal humeral fracture which includes percutaneous pinning, intramedullary nailing and hemiarthroplasties. Even if the injury is thoroughly understood, the management of displaced proximal humeral fractures is often difficult.

Outcome depends on restoration of anatomical alignment. If fracture is treated conservatively, a functional deficit will certainly develop and may be associated with pain. The external support is difficult to apply in case of proximal humeral fracture.

Many studies have shown that the displaced fracture of the proximal humerus have a poor functional prognosis when left untreated because of severe displacement of fragments.

In some studies, the objective functional results of conservative treatment have been unsatisfactory. The fractures are defined by variety of classification systems. The difficulty in accurately classifying the fracture creates problems in reporting outcome and also none of the system gives clear prognosis and direction of treatment.

Fixation of proximal humeral fractures with plates and screws has been associated with complications such as pullout of screws in osteoporotic bone, subacromial impingement and avascular necrosis of the humeral head due to excessive periosteal stripping. Studies have reported a high incidence of fixation failure following use of T buttress plates in fixation of proximal humeral fractures.

Even the newer implants like Polaris nail, plan tan humerus fixator plate had higher failure rates in elderly patients with osteoporotic bone.

Overall, open reduction and internal fixation, although not in all institution, have yielded satisfactory results. The best results are obtained if the fracture is well reduced and planned rehabilitation program followed. It must be the goal to select fractures for open reduction and internal fixation which can be anatomically reduced. This is dependent on various factors such as type of fracture, the quality of the bone and the technique of reduction and fixation.

This study was conducted to assess the functional outcome following Neer two part, three part, four part and proximal humeral fracture dislocations treated by open reduction internal fixation by philos locking plate.

1. Age Incidence

In our study all patients between the age of 18 to 65 years were included. Mean age group of patients treated with PHILOS was 43.7years. Maximum age was 64 years and minimum age was 21 years.37% of the patients were above the age of 50years.

- Rizwan Shahid *et al.* study in 2008,the average age was 60 years

- Average age of incidence in David S. Thyagarajan’s study in 2009 was 58years. Neer original study of 300 patients, average age was 55.6 years

2. Sex Incidence

In the present study male: female ratio was 4:1.24(80%) patients were males in contrast to 6 (20%) females. This is in contrast to female preponderance as observed by various other authors. In our study 80%were males and 20% were females.

3. Side Involved

In the present study out of 30 cases, left humerus fractures were seen in 17 cases and right side were seen in 13 cases. That is 57 % of fractures were seen on the left humerus as compared to 43%, that were seen in the right humerus.

C. Gerber reported, in their series of 34 fractures 16 were on left side and 18 were on right side

4. Mode of Injury

Major cause of fracture in our study was road traffic accident in 18 cases (60%), in 11 cases (37%) the mode of injury was fall and 1 assault (3%). Herbert Resch *et al.* in their study of 27 patients with 3 part and four part fracture, 24 patients had history of high energy trauma.

5. Time of Surgery

The average interval between fracture and surgery was 2.06 days in our study. Average interval between fracture and surgery was 3.2 days in Gerber C. *et al.* study. 21 of 27 patients in Herbert Resch *et al.* study the operation was done within first 4 days.

6. Type of Fracture

In our present study we had considered displaced proximal humerus fractures– Neer’s 2 part, 3 part, 4part fractures and fracture dislocations We had 10(33%) cases of Neer’s 2 part fractures, 11(37%) cases of Neer’s 3 part fractures and 6(20%) cases of Neer’s 4 part fractures and 3(10%) fracture dislocations.

7. Complications

Among the 30 cases that were operated in our study, we had complications in 3(10%) cases. All three patients had varus malunion. There was no case of avascular necrosis of humeral head or impingement. Secondary displacement and malunion occurred at surgical neck. It usually involves anterior angulation and varus deformity, decreasing neck shaft angle <120°. In all the cases it was probably due to comminution which may go for impaction at the fracture site after reduction leading to varus malunion. The incidence of avascular necrosis ranges from 8% to 35% in different studies. We had no case of avascular necrosis. Comparatively we also had less chance of stiffness because of extensive and planned physiotherapy with stable fixation

Complications	Frequency	Percent
Present	3	10.0
Absent	27	90.0
Total	30	100.0

In Moonot *et al.* study in 2005,7 patients developed complications like non union and avascular necrosis of humeral head, malunion, impingement, broken distal screw and prominent proximal screw.

In Rizwan Shahid *et al.* study in 2008, there were 4

complications like non union and impingement In David Thyagarajan’s study in 2009, 3 patients had complications like stiffness.

Among the 30 patients 2(6.7%) patients had an excellent outcome, 10(33.3%) patients had a good outcome, 13(43.3%) patients had a fair outcome, and 5(16.7%) patients had a poor outcome.

8. Functional Outcome

It was assessed using Constant and Murley scoring system.

9. Correlation between fracture type and outcome

		Out come				Total
		Excellent	Fair	Good	Poor	
Neer	# dislocation	0	0	0	3	3
		.0%	.0%	.0%	100.0%	100.0%
		.0%	.0%	.0%	60.0%	10.0%
	2 Part	1	2	7	0	10
		10.0%	20.0%	70.0%	.0%	100.0%
		50.0%	15.4%	70.0%	.0%	33.3%
	3 Part	1	7	2	1	11
		9.1%	63.6%	18.2%	9.1%	100.0%
		50.0%	53.8%	20.0%	20.0%	36.7%
	4 Part	0	4	1	1	6
.0%		66.7%	16.7%	16.7%	100.0%	
.0%		30.8%	10.0%	20.0%	20.0%	
Total		2	13	10	5	30
		6.7%	43.3%	33.3%	16.7%	100.0%
		100.0%	100.0%	100.0%	100.0%	100.0%

All 3 patients with fracture dislocation had a poor outcome. Out of 10 patients with 2 part fracture, 1(10%) had an excellent outcome, 7(70%) had good, 2(20%) had fair outcome. 1(9.1%) patient with 3 part fracture had excellent outcome followed by 2(18.2%) with good outcome,7(63.6%)

with fair outcome and 1(9.1%) with poor outcome out of 11 patients. 1(16.7%) patient with 4 part fracture had good outcome followed by 4(66.7%) with fair outcome and 1(16.7%) had a poor outcome out of 6 fractures.

Type of fracture	Number of cases	Percentage	Average constant score	Inference	Complications
2 part	10	33.3	17.3	Good	1
3 part	11	36.7	23.7	Fair	2
4 part	6	20	27	Fair	Nil
Fracture dislocations	3	10	43	Poor	Nil
Total	30	100	27.7	Fair	3

As displayed, among the 30 patients in our study, 10 patients had Neer’s 2 part fracture with an average constant score of 17.3 which was good and only 1 complication. 11 patients had Neer’s 3 part fracture with an average constant score of 23.7, which was fair.6 patients had Neer’s 4 part fracture with an average constant score of 27, which was fair and 3 patients with fracture dislocations had an average constant score of 43 which was poor. This correlation indicated that, more

complex the fracture, the function outcome was affected, and simple fracture had better functional outcome. These findings are comparable to earlier studies done by P. Moonot *et al.* 2005, David S. Thyagarajan; 2009^[48], Rizwan Shahid *et al.*; ^[49] 2008, Jan-Magnus Björkenheim, 2004^[50].

10. Correlation between age and functional outcome

		Out come				Total
		Excellent	Fair	Good	Poor	
Age(yr)	21 - 30	2	0	3	0	5
		40.0%	.0%	60.0%	.0%	100.0%
		100.0%	.0%	30.0%	.0%	16.7%
	31 - 40	0	2	2	3	7
		.0%	28.6%	28.6%	42.9%	100.0%
		.0%	15.4%	20.0%	60.0%	23.3%
	41 - 50	0	4	2	1	7
		.0%	57.1%	28.6%	14.3%	100.0%
		.0%	30.8%	20.0%	20.0%	23.3%
	Above 50	0	7	3	1	11
		.0%	63.6%	27.3%	9.1%	100.0%
		.0%	53.8%	30.0%	20.0%	36.7%
Total		2	13	10	5	30
		6.7%	43.3%	33.3%	16.7%	100.0%
		100.0%	100.0%	100.0%	100.0%	100.0%

Out of 11 patients above 50years, 3(27.3%) had good outcome, 7(63.6%) had fair and 1(9.1%) had poor outcome. Out of 19 patients less than 50 years, 2(10.5%) had excellent

outcome, 7(36.8%) had good, 6(31.5%) had fair and 4(21%) had poor outcome.

Age	Number patients	of	Percentage	Average constant score	Inference
<50 years	19		63.3	24	Fair
>50 years	11		36.7	25	Fair
Total	30		100	24.5	Fair

As shown above, among 30 patients in our study, 19 patients were below 50 years and 11 patients above the age of 50 years. We observed that the average constant and murley score had increased as the average age of the patient in the study increased. These findings are comparable to earlier studies done by P. Moonot *et al.*; 2005, David S. Thyagarajan; 2009 [48], Rizwan Shahid *et al.*; 2008 [49], Jan-Magnus Björkenheim, 2004 [50].

11. Correlation with p Value

	Fishers exact test	
	p value	
Age(yr) * Out come	.044	sig HS
Sex * Out come	.805	
MOI * Out come	.406	
Timing of Sx * Out come	.768	
Side * Out come	.769	
Asso. Injury * Out come	.807	
Neer * Out come	.003	
Complications * Out come	.501	

Conclusion

The present study was done to evaluate functional outcome following surgical management of displaced proximal humerus fracture by philos locking plate.

In our study of 30 patients with displaced proximal humerus fractures treated with proximal humeral internal locking system plating, we conclude that the functional outcome is much better in patients with 2 part and 3 part fractures, and not good in complex fractures and fracture dislocations. The advantage of this fixation is it allows early postoperative mobilization of the affected shoulder and better functional outcome of the affected shoulder, as compared to conservative management, where patients affected shoulder is immobilized for long periods. Among the 30 patients on 3(10%) had complications, and all were varus malunion. Our study also concluded that older the patient the functional outcome of the affected shoulder was fair at the end of 6 months.

Proximal Humeral Internal Locking system (PHILOS); In this system, locking of the threaded heads of the screws in the plate itself provides for a construct with angular and axial stability, eliminating the possibility of screw toggling (windscreen wiper effect), or sliding of the screws in the plate holes.

Coupled with a divergent or convergent screw orientation, this makes for much improved resistance to pull out and failure of fixation. Also, whereas conventional plating systems depend on compression between the plate under surface and bone for stability, this is not the case for the PHILOS. This lessens the chance of stripping the thread in osteoporotic bone, as the plate/bone interface is not loaded along the screw axis. This also allows for a more biological fixation as the underlying periosteum and blood supply to the fractured regions are much less compressed.

To conclude, Philos locking plate is an advantageous implant in proximal humeral fractures due to angular stability, particularly in comminuted fractures and in osteoporotic bones in elderly patients, thus allowing early mobilization.

References

- Gerald R. Williams and Kirk L. Wong, Two-part and three part fractures-Management of proximal and distal humerus fracture. Orthop Clin North Am, January 2000;31(1):1-21.
- Lind T, Kroner Jensen J. The epidemiology of fractures of proximal humerus. Arch Orthop Trauma Surg 1989;108:285.
- Lous U, Bigiliani. Chapter 9 The shoulder, Vol-1 ed. Charles Rockwood, Frederick A. Fractures of proximal humerus. In Rockwood CA, Matsen. Philadelphia: W.B. Saunders 1990, 278-334.
- Scott Powell E, Robert Chandler W. Fractures of the proximal humerus. Chapter 11, In: Text book of Operative techniques in upper extremity sports injuries. Ed. Frank W. Jobe, Mosby 1995, 313-340.
- Zyto K. Non-operative treatment of comminuted fracture of proximal humerus in elderly patients. Injury 1998;29:349-52.
- Zyto K, Wallace WA, Frostick SP, Preston BJ. Outcome after hemiarthroplasty for three and four part fracture of the proximal humerus. J Shoulder Elbow Surg 1998;7:85-9.
- Wijman AJ, Roolker W, Patt TW *et al.*, open reduction and internal fixation of three and four part fractures of proximal humerus. Scientific Article November 01, 2002.
- Sarah Edwards L, Nicole Wilson A, Li-gun Zhang *et al.* Two part surgical neck fractures of proximal part of humerus: Biomechanical Evaluation of Two Fixation. The journal of bone and joint surgery 2006;88:2258-64.
- Gerber C, Worner CM, Vienne P. Internal fixation of complex fractures of the proximal humerus. J Bone Joint Surg (Br) 2004;86(60):P848-55.
- Neer CS. Displaced proximal humeral fracture: Part I: Classification and evaluation. J Bone Joint Surg (Am) 1970;52-A:1077-89.
- Neer CS. Displaced proximal humeral fractures. Part II. Treatment of three part and four part displacement. J Bone Joint Surg 1970;52A:1090-1103.
- Paavolainen P, Björkenheim JM, Slati P, Pauku P. Operative treatment of severe proximal humeral fractures. Acta Orthop Scand 1983;54:374-379.
- Siebler G, Kuner EH. Late results following the surgical treatment of proximal humerus fractures in adults. Unfall chirurgie 1985;11(3):119-127.
- Kristiansen B, Christensen SW. Plate fixation of proximal humeral fractures, Acta Orthop Scand 1986;57:320-323.
- Hawkins RT, Bell RH, *et al.*, The three-part of proximal part of humerus. J Bone Joint Surg 1986;68A:1410-1414.
- Mouradian WH., Displaced proximal humeral fractures. Seven years experience with a modified zickel supracondylar device. Clin Orthop 1986;212:209-218.
- Sharafeldin KN, Quinlan JF, Corrigan J *et al.*, Functional follow-up of locking plate fixation of fractures of the proximal humerus, Eur J Orthop Surg Traumatol 2008;18:87-92.
- Savie FH, Geissler WB, Vander Griend RA. Open reduction and internal fixation of three-part fractures of the proximal humerus. Orthopaedics 1989;12:65.

19. Moonot P, Ashwood N, Hamlet M., Early results for treatment of three- and fourpart fractures of the proximal humerus using the Philos plate system, *J Bone Joint Surg Br* 2007;89(9):1206-9.
20. Moda SK, Chadha NS, Sangwan SS, Khurana DK, Dahiya AS, Siwach RC. Open reduction and fixation of proximal humeral fractures and fracture dislocations. *J Bone Joint Surg* 1990;72-B:1050-1052.
21. Flatow EL, Cuomo F, Maday MG, Miller SR, MacIlveen SJ, Bigiliani LU. Open reduction and internal fixation of two part displaced fractures of greater tuberosity of proximal part of the humerus. *J Bone Joint Surg* 1991;73-A:1213-1218.
22. Cuomo F, Flatow EL, Maday MG, Miller SR, MacIlveen SJ, Bigiliani LU. Open reduction and internal fixation of two and three part displaced surgical neck fractures of proximal humerus. *J Bone Joint Surg* 1992;1:287-293.
23. Kenneth A. egol, Crispin C.ong, Michael walsh *et al.*, Early complication of proximal humerus fractures treated with locked plates, *Jorthop trauma* 2008;22:159-164.
24. Aksu N, Göğüş A, Kara AN, Işiklar ZU *et al.* Complication of proximal humerus fractures treated with locked plates, *Acta Orthop Traumatol Turc* 2010;44(2):97-104
25. Szyszkowitz R, Seggl W, Schleifer P, Cundy PJ. Proximal humeral fractures: management techniques and expected results. *Clin Orthop* 1993;293:13-25.
26. Robinson CM, Christie T. Two part proximal humeral fracture: A review of operative treatment using two techniques. *Injury* 1993;24(2):123-125.
27. Esser RD *et al.*, Open reduction and internal fixation of three and four part fractures of proximal humerus. *Clin Orthop* 1994;299:244-251.
28. Zyto K, Kronberg M, Brostorm LA. Shoulder function after displaced fractures of the proximal humerus. *J Bone Joint Surg* 1995;4:331-336.
29. Leonard M, Mokotedi L, Alao U *et al.*, The use of locking plates in proximal humeral fractures: Comparison of outcome by patient age and fracture pattern, *Int J shoulder surgery* 2009;3(4):85-9.
30. Felix Brunner, Christoph Sommer, Christian Bahrs *et al.* Open Reduction and Internal Fixation of Proximal Humerus Fractures Using a Proximal Humeral Locked Plate: A Prospective Multicenter Analysis, *J Orthop Trauma* 2009;23:163-172.
31. Koval KJ, Blair B, Takie R, Kummer FT, Zuckerman D. Surgical nerve fractures of proximal humerus; A laboratory evaluation of ten fixation techniques. *J Trauma* 1996;40(S):778-783.
32. Herbert Resh *et al.*, Percutaneous fixation of three and four part fractures of proximal humerus. *J Bone Joint Surg (Br)* 1997;79-B:295-300.
33. Lin J, Hou SM, Hing YS. Locked nailing for displaced surgical neck fractures of the humerus. *J Trauma* 1998;45(6):1051-1057. Campbell's operative orthopaedics Vol 3, 12th edition, page 2838.
34. Hessmann M, Gehling H, Gotzenl. Plate fixation of proximal humerus fracture with indirect reduction; surgical technique and results using the shoulder score. *Injury* 1999;30:453-462.
35. Stanley Hoppen field Operative exposure 4th edition page 4-15,
36. Hintermann B, Trouillier HH, Schufer D. Rigid internal fixation of fractures of the proximal humerus in older patients. *J Bone Joint Surg (Br)* 2000;82(8):1107-1112.
37. Ruch DS, Glisson RR, Marr AW, Russel GB. Fixation of three part proximal humeral fracture: A biomechanical evaluation. *J Orthop Trauma* 2000;14(1):36-40.
38. Ramchander Siwach, Roop Singh, Rajesh Kumar, Rohilla *et al.* Internal fixation of proximal humerus fracture by locking proximal humerus plate in elderly osteoporotic, *J Orthopaed Traumatol* 2008;9:149-153.
39. Hong-fei Shi, Jin Xiong, Yi-xin Chen *et al.* Management of proximal humeral fractures in elderly patients with uni- or polyaxial locking osteosynthesis system, *Arch Orthop Trauma Surg* 2011;131:541-547.
40. Nisan Nisan, Tahir OGUT *et al.* Fixation of proximal humeral fractures with modified tension band technique. *J of Arthroplasty and Arthroscopic Surgery* 2002, 13(3).
41. Hodgson SA, Mawson ST, Stanley JD. Rehabilitation after two part fractures of the neck of the humerus. *J Bone Joint Surg (Br)* 2003;85(30):419-22.
42. Christopher M Jobe. Gross anatomy of the shoulder. Chapter-2, In: *The Shoulder*, Vol. 1, ed. Charles A. Rcockwood Jr, Frederick A. Matsein III, Philadelphia: W.B. Saunders Company 1990, 34-97.
43. Rothmann TB, Mainab I. The microvascular pattern of rotator cuff. *J Bone Joint Surg* 1970;52B:540-553.
44. Gerber C *et al.* The arterial vascularization of the humeral head. *J Bone Joint Surg* 1990;72A:1486-1493.
45. Evan L. Flatow. Fracture of the proxiaml humerus. Chapter-25, In: *Text book of Rockwood and Green's fractures in adults*. Vol.1, New York: Lippincott Willimas & Wilkins 2001, 997-1035.
46. Zuckerman JD *et al.* Axillary artery injury as complication of proximal humerus fractures. *Clin Orthop* 1984;189:234.
47. Andrew H. Crenshaw Jr. Surgical techniques and approaches. Chapter-1, In: *Campbell's operative orthopaedics*, 10th Edn., Vol.1, ed. S. Terry Canale, Kay Daugherty, Linda Jones, London: Mosby Year Book Publication 2003, 3-122.
48. David S Thyagarajan, Samarth J Haridas, Denise Jones, Colin Dent, Richard Evans, Rhys Williams. Functional outcome following proximal humeral interlocking system plating for displaced proximal humeral fractures. *Int J Shoulder Surg* 2009;3(3):57-62.
49. Rizwan Shahid, Abid Mushthaq, Julian Northover, Mohammad MAQSOOD. Outcome of proximal humerus fractures treated by PHILOS plate internal fixation Experience of a District General Hospital. *Acta Orthop. Belg* 2008;74:602-608.
50. Jan-Magnus Björkenheim, Jarkko Pajarinen, Vesa Savolainen. Internal fixation of proximal humeral fractures with a locking compression plate. *Acta Orthop Sc and* 2004;75(6):741-745.
51. Alexandra Kirkley, Sharon Griffin, CSS, Katie Dainty C. Scoring Systems for the Functional Assessment of the Shoulder. *J of Arthroscopic and Related Surgery*, Vol 19, No 10 (December), 2003, 1109-1120.
52. Kristiansen B, Christiansen SW. Plate fixation of proximal humeral fractures. *Acta Orthop Sc and* 1986;57:320-3.
53. Constant CR, Murley AHG. A clinical method of functional assessment of the shoulder. *ClinOrthop* 1987;214:160-164
54. Geiger EV, Maier M, Kelm A, Wutzler S, Seebach C, Marzi I. Functional outcome and complications following PHILOS plate fixation in proximal humeral fractures. *Acta Orthop Traumatol Turc* 2010;44(1):1-6. Doi: 10.3944/AOTT.2010.2270.