



E-ISSN: 2395-1958
P-ISSN: 2706-6630
IJOS 2021; 7(1): 930-933
© 2021 IJOS
www.orthopaper.com
Received: 25-11-2020
Accepted: 27-12-2020

Dr. Shashank G
Senior Resident, Department of Orthopedics, Bangalore Medical College and Research Institute, Bangalore, Karnataka, India

Dr. Haricharan L
Senior Resident, Department of Orthopedics, Bangalore Medical College and Research Institute, Bangalore, Karnataka, India

Dr. Rajendra J
Assistant Professor, Department of Orthopedics, Akash Institute of Medical Sciences, Bangalore, Karnataka, India

Dr. Sathish Babu DG
Assistant Professor, Department of Orthopedics, Bangalore Medical College and Research Institute, Bangalore, Karnataka, India

Corresponding Author:
Dr. Haricharan L
Senior Resident, Department of Orthopedics, Bangalore Medical College and Research Institute, Bangalore, Karnataka, India

A prospective study to evaluate tibial plateau fractures union and complications treated by locking compression plate in a tertiary care centre, South India

Dr. Shashank G, Dr. Haricharan L, Dr. Rajendra J and Dr. Sathish Babu DG

DOI: <https://doi.org/10.22271/ortho.2021.v7.i1n.2591>

Abstract

Background: Knee joint is the major weight bearing joints in the lower extremity. Proximal tibial fractures are commonest intra-articular fractures. As more and more concepts about biological fixation become clearer the innovation of plates progressed and lead to the development of less invasive stabilizing system. Research to combine these two methods has led to the development of the anatomically contoured locking compression plate. This new system is technically mature as it offers numerous fixation possibilities and has proven to worth in complex fracture situations and in osteoporotic bones.

Objectives: To evaluate union and complications following three column locking compression plate reconstruction for treating tibial plateau fractures in a tertiary care centre in South India.

Methods: This study was a prospective study done on 34 consenting cases of proximal tibial fractures admitted to the Department of Orthopaedics, and underwent surgical treatment for tibial plateau fractures at M S Ramaiah Hospitals, Bengaluru. The patients were chosen based on the inclusion and exclusion criteria. Results were evaluated by fracture union on X ray and descriptive statistics were used to analyze the data.

Results: In the present males were, 97%, most patients belonged to the category 40-50 years (14 patients, 41.18%). The mean age was 39 years. vehicular accident (27 patients, 79%). right sided injury (24 patients, 69.38%), type of Schatzker's fracture type VI (29 patients, 85.2%), followed by Type IV 4 patients 11.76%, the 34 cases in the study most patients were fixed by LCP plates. on evaluation of the final outcome of the fracture most patients had excellent results (24, 70.58%) and only one case had poor result because of delayed and non-union.

Conclusion: Three-column fixation is a new fixation concept in treating complex tibial plateau fractures, which is especially useful for multiplanar fractures involving the posterior column. The combination of posterior and anterior-lateral approaches is a safe and effective way to have direct reduction and satisfactory fixation for such difficult tibial plateau fractures.

Keywords: tibial plateau fracture, multi-plate reconstruction, clinical outcome, complications

Introduction

The knee joint is one of the major weight bearing joint in the lower extremity. Proximal tibial fractures are one among the commonest intra-articular fractures. Usually, these injuries fall into two broad categories: a) high energy fractures b) low energy fractures. Fractures of the proximal tibia are the results of high-energy injuries because of the lack of soft tissue coverage in this region, it is usually vulnerable, so commonly open fractures are encountered. In those cases, the treatment of damaged soft tissues is of primary concern ^[1].

The most of the tibial plateau fractures are secondary to high-speed velocity accidents and the fall from height ^[2]. These fractures resulted from direct axial compression, commonly with a valgus or varus moment and indirect shear forces ^[3].

The main aim of surgical treatment of proximal tibia fracture is to restore congruent articular surfaces of the tibial condyles maintaining the mechanical axis and restoring ligamentous stability to achieve functional painless and good range of motion in the knee joint ^[4].

The many clinical studies found that bone beneath a rigid conventional plate is thin and atrophic. These are prone for secondary displacement because of insufficient buttressing and secondary fractures after removal of plate. Also, fracture site take longer period to osteosynthesis due to interruption of vascular supply to bone due to soft tissue and periosteal stripping. So, a new concept of biological fixation using the plates was developed, otherwise called minimally invasive percutaneous plate osteosynthesis (MIPPO). This was difficult since conventional plates needs to be accurately contoured to achieve good fixation. Also, osteoporosis posed the same problem of poor fixation with conventional plates this led to the development of the internal fixators [5].

Conservative treatment is reserved for very simple undisplaced fractures that represent a small minority of the overall tibial plateau fracture or for very low demand patients with severe co-morbidities. For the young patients with such an injury operative treatment will be good, usually which aims for anatomical reduction, stable fixation, and early movement. These operative indications and goals are currently expanding further in patients even over 55 years with good results, despite the presence of osteoporosis or osteopenia, coexisting medical problems, or of degenerative joint disease. Currently, the gold standard method of treatment is open reduction and internal fixation with plates and screws. Modern locking plating systems provides increased angular stability, less chance of implant failure, new and improved designs which matches periarticular bone surface, as well as compatible with the minimal invasive techniques are nowadays the mainstay of clinical practice [2].

More concepts of biological fixation becoming clearer, the innovation of plates progressed drastically and led to the development of less invasive stabilizing system. Many researches to combine these two methods has led to the development of the anatomically contoured locking compression plate [6].

“Three-column fracture” is defined as at least one independent articular fragment in each column.⁷ Fixation of Three-column fracture needs a sophisticated approach. Also, a multi-plate reconstruction is a safe and valid method for treating severe bicondylar tibial plateau fractures. In view of this we decided to evaluate union and complications following three column locking compression plate reconstruction for treating tibial plateau fractures in a tertiary care centre in South India.

Material and Methods

This prospective study was conducted at Department of Orthopaedics, M S Ramaiah Hospitals, Bengaluru during the study period of 18 months extending from November 2016 to June 2018. The study population was cases with proximal tibial fractures admitted to the Department of Orthopaedics, and underwent surgical treatment for tibial plateau fractures.

The participants who were given consent to participate in this study were included and after considering inclusion and exclusion criteria.

Inclusion criteria

1. Patients more than 18 years of age.
2. Patients of tibial plateau fractures requiring surgical intervention.
3. Radiological diagnosis of tibial plateau fractures based on Schatzker classification type 4,5,6 [8].

Exclusion criteria

1. Open fractures of tibial plateau fractures.
2. Fractures associated with knee dislocation.
3. Patients with ipsilateral femur, tibia and foot fractures
4. Schatzker type 1, 2, 3 [8].

Sample Size: From literature review by Dasaraiah *et al.* study has observed that over 83.4% had acceptable results in tibial plateau fractures [9]. In present study accepting similar result with 15% relative precision and 95% confidence level, the study requires a minimum of 34 subjects. With an average incidence rate of proximal tibial fractures 1.75% [0.5 – 3%] at 95% confidence interval.

$$\text{Calculated using the formula } n = \frac{4pq}{d^2}$$

where p-prevalence, q-100-p and d- percentage pf allowable error of P.

Hence 34 cases of proximal tibial fractures were included in the study.

The study was started after taking approval from Institutional Ethics Committee. The patients were informed about the study in all respects and informed consent was obtained from each patient and data was collected from the patients who gave informed consent.

Three-Column Concept for the classification and treatment of complex tibial plateau fractures [8]:

A combined preoperative assessment of fracture morphology and injury mechanism is utilized to determine surgical approach, implant placement and fixation sequence Standard radiographic and computed tomography imaging are used to systematically assess and classify fracture patterns as follows:

- 1) identify column(s) injured and locate associated articular depression or comminution,
- 2) determine injury mechanism including varus/valgus and flexion/extension forces, and
- 3) determine surgical approach(es) as well as the location and function of applied fixation

Operative Procedure

Positioning: The patient positioned on the operating table patient was placed either on fracture table or without fracture table to surgeons convenience if patient is not placed on fracture table then knee is flexed to 20 degrees with bolster below knee and incisions will be made accordingly.

After this minimally invasive percutaneous plate osteosynthesis of tibial fractures and Operative procedure by open reduction and internal fixation of tibial fractures by locking compression plate were done [8].

After the surgery, standard post-operative management were followed and check X-ray taken third post-operative day. Quadriceps exercises and ankle mobilization started within 48 hours of surgery and knee bending and toe touch walking with a walker on second or third postoperative day if the fixation allowed. Dressing done on 2nd, 5th and 8th post-operative day. Sutures removed on 12th post-operative day. Full weight bearing was permitted only after clinico-radiological evidence of union.

Follow up done at 6 weeks, 3 months and 6 months after surgery.

Data were entered in Microsoft Excel and descriptive statistics were analysed using EpiData Analysis V2.2.2.182 in the form of frequencies and proportions.

Results

A total of 34 cases with Tibial Plateau Fractures were assessed, among them 33 (97%) and 1 (3%) were males and females respectively. The mean age of the participants was 39.87±11.6 years and most patients belonged to the category 40-50 years (14 patients, 41.18%).

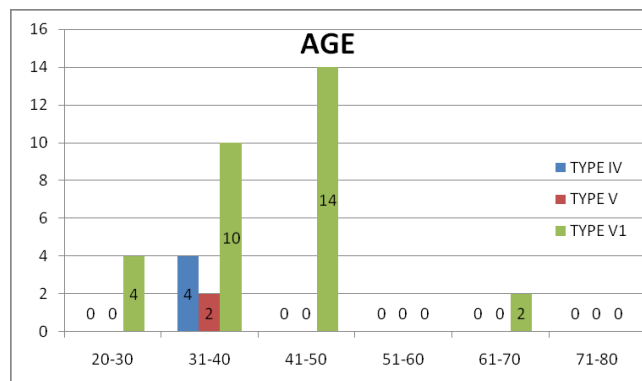


Fig 1: Age distribution of the study population

The commonest mode of injury was motor vehicle accidents (79.4%), around 21 (62%) of them had injury to the left leg. About 28 (82.3%) of the people had Type VI fracture and the method of reduction and fixation used was LCP plates for all the patients (Table 1).

Table 1: Shows the characteristics of injury and fracture among the study group.

Characteristics of Injury and Fracture	Frequency (n=34)	Percentage
Mode of Injury		
• Motor Vehicle Accidents (RTA)	27	79.4
• Fall from height	7	21.6
Side Affected		
• Right	10	38.2
• Left	21	61.8
Type Of Schatzker's Fracture		
• Type IV	4	11.8
• Type V	2	05.9
• Type VI	28	82.3
Method of Reduction and Fixation		
• LCP Plates	34	100

These 34 cases undergone surgical management using Locking Compression Plate. The mean duration of surgery was 92.7± 18 minutes. The pre and post-operative of range of motion is shown in Table 2. In the present study on evaluation of the range of motion following surgery, most patients had a good range of motion the mean was of 440 better as compared to pre-operative period.

Table 2: The Range of Motion.

Range of Motion (N=34)	Mean	Standard Deviation
Pre-operative	59.14	16.52
Post-operative	103.14	20.69

Table 3: Postoperative complications among the study group.

Complications	Frequency (n=34)	Percentage
Knee stiffness	2	05.89
None	32	94.21

In our study, we encountered only knee stiffness among two patients post operatively. (Table 3).

The mean duration of hospital stay was 14 days and mean time to full weight bearing was 16.97±1.9 weeks.

Table 4: Duration taken for fracture union among the study group.

Fracture union in weeks	Frequency (n=34)	Percentage
• 14 Weeks	5	14.7
• 16 Weeks	14	41.2
• 17 Weeks	2	05.9
• 18 Weeks	11	32.3
• 20 Weeks	2	05.9

All patients were followed at 6 weeks, 12 weeks, 6 months. At each follow up radiograph of the operated limb was taken and assessed for fracture union and implant failure and screw cut out.

In the present study on evaluation of the duration taken for the fracture union most patients had fracture union in 16 weeks (14 patients, 41.2%), The mean duration for fracture healing was 16.51 weeks. (Table 4).

In our study, on evaluation of the final outcome of the fracture most patients had excellent results (24, 70.58%) and only one case had poor result because of delayed and non-union. (Table 5).

Table 5: Final outcome of the study group.

Results	Frequency (n=34)	Percentage
• Excellent	24	70.58
• Good	4	11.76
• Fair	5	14.72
• Poor	1	02.94

Discussion

Proximal tibial fractures treated with LCP can be manipulated under anaesthesia in the event of plate bending due to re-injury. Because LCP provide angular stability and technique of MIPPO retains the fracture biology, manipulation under anaesthesia may be justified in these cases.

The main purpose of the study is to evaluate outcome of the surgery. Hence all the patients included in the study are of the operative group. We have not included any conservatively managed group. Our study shows the effectiveness of the operative treatment as the articular surface was restored anatomically and fixed with suitable implant for early mobilization.

In a study by Tang Xin *et al.* study on evaluation of the age distribution, the mean age was 45 years which is similar to our study and gender distribution is also similar to our study [10].

In the present study on evaluation of the range of motion following surgery, most patients had a good range of motion of 130 degree (6 patients, 23.08%). In a study by Prasad *et al.* most patients had 120° and above knee flexion which is a finding similar to our study [11].

In the present study on evaluation of the duration taken for the fracture union most patients (10 patients) had fracture union in 18 weeks (38.46%). The mean duration for fracture healing was 16.61 weeks. In a study by Prasad *et al.* 83 all patients had had union in 8-22 weeks (average 14 weeks) [11].

In the present study on evaluation of the final outcome of the fracture most patients had excellent results and it was similar to studies conducted by Tang Xin *et al.* Prasad *et al.*

Conclusions

From this study, we can conclude that, displaced tibial plateau fractures are best managed operatively. Optimal knee function is achieved by accurate anatomical reduction and secure fixation followed by early mobilisation to attain functional arc of motion. Three-column fixation is a new fixation concept in treating complex tibial plateau fractures, which is especially useful for multiplanar fractures involving the posterior column. The combination of posterior and anterior-lateral approaches is a safe and effective way to have direct reduction and satisfactory fixation for such difficult tibial plateau fractures.

Acknowledgements

We are highly thankful to Staff of Department of Orthopaedics, for their support in this work. We immensely thank the patients for their valuable time and cooperation in completing this study.

Declarations

Funding: None

Conflict of interest: None declared

Ethical approval: Ethical approval taken from Institutional Ethics Committee, M S Ramaiah Hospitals, Bengaluru, Bangalore.

References

1. Kim JW, Oh CW, Jung WJ, Kim JS. Minimally invasive plate osteosynthesis for open fractures of the proximal tibia. *Clin Orthop Surg* 2012;4(4):313–20.
2. Schulak DJ, Gunn DR. Fractures of tibial plateaus. A review of the literature. *Clin Orthop Relat Res. United States* 1975;(109):166-77.
3. Koval KJ, Helfet DL. Tibial Plateau Fractures: Evaluation and Treatment. *J Am Acad Orthop Surg. United States* 1995;3(2):86–94.
4. Wagner M. General principles for the clinical use of the LCP. *Injury. Netherlands* 2003;34(2):B31-42.
5. Sommer C, Gautier E, Müller M, Helfet DL, Wagner M. First clinical results of the Locking Compression Plate (LCP). *Injury. Netherlands*; 2003;34(2):B43-54.
6. Stoffel K, Dieter U, Stachowiak G, Gächter A, Kuster MS. Biomechanical testing of the LCP--how can stability in locked internal fixators be controlled? *Injury. Netherlands* 2003;34(2):B11-9.
7. Zhu Y, Yang G, Luo CF, Smith WR, Hu CF, Gao H *et al.* Computed tomography-based Three-Column Classification in tibial plateau fractures: introduction of its utility and assessment of its reproducibility. *J Trauma Acute Care Surg. United States* 2012;73(3):731-7.
8. Campbell WC, Canale ST, Beaty JH. *Campbell's operative orthopaedics*. 11th ed. Campbell WC, Canale ST, Beaty JH, editors. Philadelphia: Elsevier 2008;3:3239-3308.
9. Dasaraiah C, Rao AS, Kuma AT. Study of Surgical Management of Tibial Plateau Fractures – Functional and Radiological Evaluation. *IOSR J Dent Med Sci* 2016;15(1):18-27.
10. Tang X, Liu L, Tu CQ, Yang TF, Wang GL, Fang Y *et al.* Timing of internal fixation and effect on Schatzker IV-VI tibial plateau fractures. *Chinese J Traumatol = Zhonghua chuang shang za zhi. China* 2012;15(2):81-5.
11. Prasad GT, Kumar TS, Kumar RK, Murthy GK, Sundaram N. Functional outcome of Schatzker type V and VI tibial plateau fractures treated with dual plates.