



E-ISSN: 2395-1958
P-ISSN: 2706-6630
IJOS 2021; 7(1): 536-539
© 2021 IJOS
www.orthopaper.com
Received: 09-11-2020
Accepted: 21-12-2020

Dr. O Ravinathan
Assistant Professor, Department
of Orthopedics, Government
Medical College, Pudukkottai,
Tamil Nadu, India

R Vasantharaman
Professor, Department of
Orthopedics, Government
Medical College, Pudukkottai,
Tamil Nadu, India

Corresponding Author:
R Vasantharaman
Professor, Department of
Orthopedics, Government
Medical College, Pudukkottai,
Tamil Nadu, India

Analysis of functional outcome of complex tibial plateau fractures (Schatzker Type 5 and Type 6) treated with hybrid external fixators

Dr. O Ravinathan and R Vasantharaman

DOI: <https://doi.org/10.22271/ortho.2021.v7.i1i.2537>

Abstract

Introduction: Tibial fractures type V and VI are complex injuries usually treated with ORIF (Open Reduction and Internal Fixation) which have increased risk of wound complications. The hybrid external fixer helps to mitigate these complications by permitting early mobilization and bearing of weight, minimal soft tissue damage, and stable fixation.

Aim: To analyze the functional outcome of hybrid external fixator-treated tibial plateau fractures (Schatzker type 5 and 6).

Methods: The study included 30 patients who had tibial plateau fractures of Schatzker Type V and type VI. Patients offered informed consent and a 2 years follow-up following surgery was done. We have applied K'wire or minimal open reduction with cancellous screw and universal external fixator. The analyses were performed with Neer's Rating System for Knee.

Results: Out of 30 patients, 26 patients were males, and 4 patients were females. Mean age was 42.34 years. Based on outcomes, 40% of the study population had an excellent and good effect, 17% had fair outcome, 3% had a poor outcome. Based on the type of fracture, 12 patients had Schatzker type V, 18 patients had Schatzker type VI, 10 patients had closed fracture, 20 patients had a compound fracture. Based on mode of injury, 85% had a road traffic accident, 10% had assaulted, 5% had fall injury. Based on complication, 23% had pin tract infection, 17% had knee stiffness, 3% had malunion, 3% had shortening, and 10% had wound infection.

Conclusion: In this report, we have concluded that a promising alternative therapy for high-energy plateau fractures is a hybrid external fixator. Without high complication rates, it permits a safe fixation of fracture fragments, early joint recovery and the treatment of related soft tissue injuries.

Keywords: Schatzker type 5 and 6, compound fracture, hybrid external fixator

Introduction

Complex and high-impact tibial plateau fractures is a challenge to the orthopaedic surgeon and the use of open reduction and internal fixation techniques are associated with increased risk of wound complications. This led to the development of alternate methods of fixation like Ilizarov ring fixation, external fixation with limited internal fixation and hybrid external fixation. It is controversial and difficult to optimally treat tibial plateau fractures type V and VI by Schatzker. Surgical treatment of high energy tibial plateau fractures continues to be a concern because of problems such as wound complications, infection, knee stiffness and joint incongruity and a treatment protocol is yet to be developed and confirmed^[1, 2, 3]. High energy tibial fractures generally have a significant socio-economic effect on the younger age group due to late recovery period and the resultant need for early complete replacement of the knee in some complicated cases^[4].

Tibial plateau fractures are classified into six types by Schatzker: Pure cleavage (Type I), Cleavage combined with depression (Type II), Pure central depression (Type III), Fracture of medial condyle (Type IV), Bicondylar fractures (Type V), and Plateau fracture with dissociation of metaphysis and diaphysis (Type VI). Different treatment modalities (traction, external attachment spanning the knee, to complete knee arthroplasty) for tibial plateau fractures have been used for more than 3 decades.

Traction and closed reduction following the pop application will not recover the joint surface and contribute to joint surface failure and knee stiffness. Open reduction and fixation with plating, although the articular surface decreases well, the already-damaged soft tissue does not support it and contributes to wound necrosis and complications. Dual plated ORIF was an attractive form of treatment for these forms of injuries [5].

There have been many attempts to identify the fractures of tibial plateaus. Hohl and Luck in the year 1956 [6,7] in an early attempt to identify tibial plateau fractures, recognized some of the critical themes of several condyles split structures, subchondral and articular incongruity and comminution involvement. In 1979, Schatzker *et al.* published their classification system [8], based on AP radiographs of a total of 94 patients, most of whom received non-surgical treatment with tibial plateau fractures.

Since the early 1990s, catastrophic complications such as joint rigidity, malunion or loss of skin may occur to minimize the incidence of amputation and even death [9]. Soft tissue envelope typically covers a hybrid, external fixator for high-energy tibial plateau fractures. It also offers access to soft tissue cover during the treatment of fractures. When applied to this cancelled screws and K-wires for joint surface reduction, it provides additional stability and prevents early knee steadiness [10, 11]. Minimal interventions and hybrid external attachment will result in a fair result, compared to open internal reduction fixing by plating or other methods, with fewer complications.

Aim

To analyze the functional outcome of hybrid external fixator-treated tibial plateau fractures (Schatzker type 5 and 6).

Materials and Methods

In this prospective study, conducted during the time period from 2016 to 2018 in Government medical college, Pudukkottai and Team Speciality Hospital, Pudukkottai, 30 patients with tibial plateau fractures Schatzker type V and VI treated with hybrid fixation. We have applied K'wire or minimal open reduction with cancellous screw fixation and universal external fixator. The study began after gaining informed consent from the patients. The conditions for inclusion include age over 20 years and fractures of the closed tibial plateau fractures (Schatzker type 5 and type 6) (grade I to grade III B). Criteria of exclusion include age less than 20 years, patients with co-morbid conditions, shut-off shallow board fractures (Schatzker 1-4), compound grade IIIc shallow board fracture, and related fractures, such as floating knee, pilon fracture.

The pre-operative data like mode of injury, demographic information and fracture classification were collected and traced from the medical records. The fractures were treated with closed reduction or with minimal open reduction with K'wire or cancellous screw fixation and external fixator, hybrid fixation. The patients were allowed to walk with walker's support with touch toe after the symptoms subsided in the post-operative period. Partial weight bearing walking with the help of walker was started after 2 weeks and at 8 weeks after surgery full-weight bearing walking with walker support was allowed. Radiographic analysis showed fracture reunion after 8 weeks. The Fixator was removed, and PTB cast was added to allow the patient to bear full weight. The PTB cast was removed after 4 weeks. The patients were advised to begin walking with a walker and to discard the

walker gradually.

Results

Out of the 30 patients who participated in the study, 26 patients were males, and 4 patients were females. The mean age was 42.34 years. 12 patients(40%) showed excellent outcomes, 12 patients showed good results (40%), 5 patients had (17%) fair outcomes, and 1 patient (3%) had a poor effect. (Fig.1)

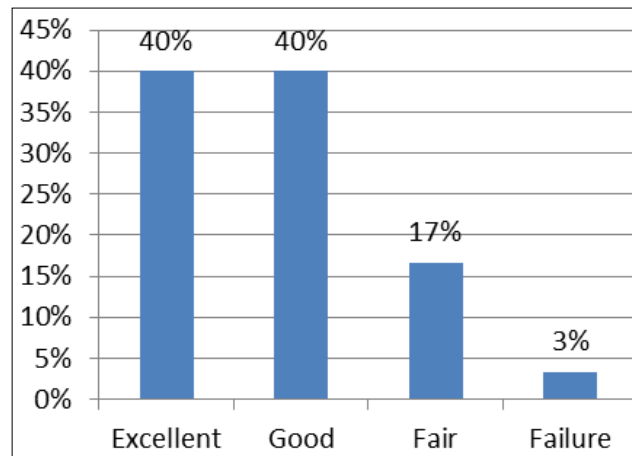


Fig 1: Outcomes

Based on the type of fracture 12 patients had Schatzker type V, 18 patients had Schatzker type VI, and their average NEER rating score was 18.25 and 13.98 respectively.(Table.1)

Table 1: Results according to Schatzker type

S. No	Schatzkers type	No. of cases	Average Neer rating score
1	TYPE 5	12	18.25
2	TYPE 6	18	13.98

Based on the type of fracture 10 patients had closed fracture, 20 patients had a compound fracture, and their average NEER rating score was 18.28 and 14.71, respectively.(Table.2)

Table 2: Type of fracture

S. No	Type of fracture	No. Of cases	Average Neer rating score
1	Closed Fracture	10	18.28
2	Compound Fracture	20	14.71

Road traffic accident was the predominant cause for tibial fractures (85%), followed by physical assaults (10%). Fall injury accounted for 5% of the fracture cases. (Fig.2)

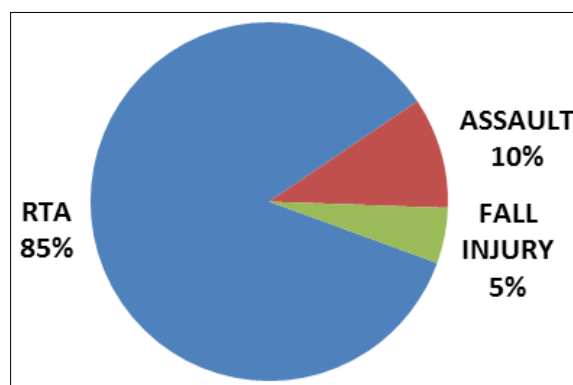


Fig 2: Mode of injury

Based on complication, 23% had pin tract infection, 17% had knee stiffness, 3% had malunion, 3% had shortening, and 10% had wound infection. (Fig.3)

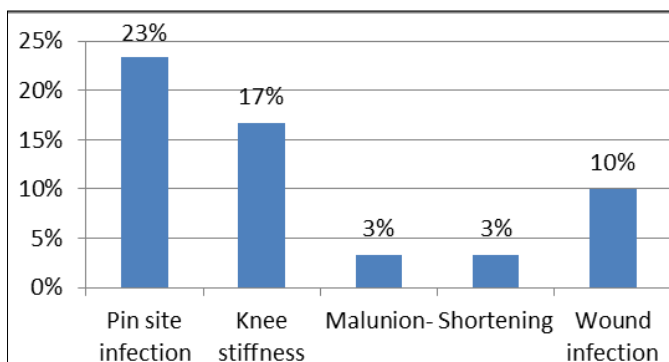


Fig 3: Complications

Discussion

A healthy soft tissue envelope is critical for fracture healing and tibial type 5 and type 6 fractures are almost always associated with a compromised soft-tissue. Surgery also traumatizes the envelope of soft tissue and if not done right, serves as a second effect on soft tissue. The risk of complications of the type V and type VI fractures is increased by high-energy trauma and softened tissue insult. An optimum decision is therefore most important in managing a complex fracture of bicondylar tibial plateau [12]. In a recent study, the treatment of tibial plateau fractures with an external fixator resulted in fewer complications and early mobilization than with an internally fixed solution. However, previous studies showed that hybrid external fixator is also a source of pin tract infection and can lead to knee joint septic's arthritis [13].

Due to its easy use, the use of hybrid fixator for tibial condyle fractures has increased in the recent years, particularly for compound fractures. The procedure is also associated with lower blood loss compared with ORIF for plating. Preserving the hematoma in fracture site helps in good health and early union prospects. Avoiding skin necrosis is also inevitable as that could be an issue in the proximal tibia and could offer space for covering skin/flaps in cases of skin loss/bone exposed compound fractures [8].

High energy fractures associated with a soft tissue that is often at risk, are the tibial plateau fractures, particularly SVI and S-V fractures [14] and healing time ranges from 6 weeks to 10 weeks. The fracture healing has been significantly influenced by fracture nature, the form of fracture (closed/open) and the presence of infection. Early recovery and reduced complications resulted in anatomical and relatively stable fixation reduction [15, 16].

Previous studies show the importance of stable knee fractures as one of the most significant predictors for potential knee function following treatment of tibial plateau fractures [17]. In the last two decades, the advancement of equipment and techniques of external fixation has led many surgeons to apply the concepts of biological osteosynthesis and minimally invasive procedure for the treatment of comminuted tibia. The results are significant to the development of tibial plateau as an essential indicator of future knees [18, 19]. The effect of hybrid fixation is the capacity for axial compression and lateral dynamization has given external fixators new opportunities for complete treatment [20].

When comparing external with internal fixation, Mahadana *et al.* concluded that hybrid external fixation has theoretical

advantages as far as soft tissue safety is concerned; however, the gain of external fastening was modest as far as reduction accuracy was concerned [21]. In its high energy Schatzker V and VI series of tibial plateau fractures treated with circular external fixators Catagni *et al.* recorded good and excellent results for 30 patients (50.85%) and 27 (45.766%) respectively [22]. Chin *et al.* showed 38.9% good and excellent and 61.1% fair and bad results for its type V and VI fractures series [23].

In our study too, 40% of the patients showed excellent results and 40% showed good outcomes following treatment with hybrid external fixator which are similar to the results of other studies. Only a 3% failure rate was observed in this study which is insignificant. The most important wound complication associated with the procedure was pin tract infection (23%) followed by knee stiffness (17%). Wound infection was observed in 10% of the cases. This minimally invasive approach can be utilized wherever possible, that prevents soft tissue damage, thereby avoiding wound healing issues. Early aggressive rehabilitation can help to regain the full range of movements. Further studies to ensure optimal functional recovery and patient satisfaction are needed.

Conclusion

In this report, we have concluded that a promising alternative therapy for high-energy plateau fractures is a hybrid external fixator. Without high complication rates, it permits a safe fixation of fractured fragments, early joint recovery and the treatment of related soft tissue injuries.

References

1. Young MJ, Barrack RL. Complications of internal fixation of tibial plateau fractures. *Orthop Rev.* 1994;23:149–54.
2. Mallik AR, Covall DJ, Whitelaw GP. Internal versus external fixation of bicondylar tibial plateau fractures. *Orthop Rev* 1992;21:1433–6.
3. Mckee MD, Pirani SP, Stephen DJ. The Canadian Orthopedic Trauma Society, Open reduction and internal fixation compared with circular fixator application for bicondylar tibial plateau fractures. Results of a multicenter, prospective, randomized clinical trial. *J Bone Joint Surg Am* 2006;88:2613-23
4. Weiner LS, Kelley M, Yang E, Steuer J, Watnick N, Evans M, *et al.* The use of combination internal fixation and hybrid external fixation in severe proximal tibia fractures. *J Orthop Trauma* 1995;9:244-50.
5. Ebraheim NA, Sabry FF, Haman SP. Open reduction and internal fixation of 117 tibial plateau fractures. *Orthopaedics* 2004;27(12):1281-7
6. Palmer I. Fractures of the upper end of the tibia. *J Bone Joint Surg Br.* 1951;33:160–166.
7. Hohl M. Tibial condylar fractures. *J Bone Joint Surg Am* 1967;49:1455–1467.
8. Schatzker J, Mc Broom R, Bruce D. The tibial plateau fracture: the Toronto experience: 1968–1975. *Clin Orthop Relat Res* 1979;138:94–104.
9. Bianchi-Maiocchi A, Aronson J. *Operative Principles of Ilizarov.* Baltimore: Williams & Wilkins 1991.
10. Watson JT. High-energy fractures of the tibial plateau. *Orthop Clin North Am* 1994;25:723-52.
11. Thakur AJ. *Elements of Fracture Fixation.* 1st ed. Ch. 8. Philadelphia, PA: W.B. Saunders, 1997. p147-76.
12. Kumar A, Whittle AP. Treatment of complex (Schatzker Type VI) fractures of the tibial plateau with circular wire

- external fixation: retrospective case review. *J Orthop Trauma* 2000;14:339-44.
13. Hutson JJ, Jr, Zych GA. Infections in periarticular fractures of the lower extremity treated with tensioned wire hybrid fixators. *J Orthop Trauma* 1998;12:214-8.
 14. Rommens PM, Broos PL. The significance of soft tissue trauma for fracture healing. A prospective study on 70 tibial shaft fractures following primary treatment with the Monofixateur. *Unfallchirurg* 1992; 95(3):133-41.
 15. Madhor A Karunakar, Micheal J bose. Rockwood and Greens "Fracture in adults". 5th edition, chapter 2001, 231-245.
 16. Mark Farrar, Lang yans, Micheal salen. The Sheffield Hybrid Fixator- a clinical and biomechanical review. *INJURY* 2001;32:8-13.
 17. Marsh JL, Buckwalter J, Gelberman R, *et al.* Articular fractures: does an anatomic reduction really change the result? *J Bone Joint Surg Am* 2002;84A:1259-1271.
 18. Stamer DT, Schenk R, Staggers B, Aurori K, Aurori B, Behrens FF. Bicondylartibial plateau fractures treated with a hybrid ring external fixator: a preliminary study. *JOrthop Trauma* 1994;8:455-461.
 19. Young MJ, Barrack RL. Complications of internal fixation of tibial plateau fractures. *Orthop Rev* 1994;23:149-54
 20. Keoch P, Kelly C, Cashman WF, McGuinness AJ, O Rourke SK. Percutaneous screw fixation of tibial plateau fractures. *Injury* 1992;23:387-389.
 21. Mahadeva D, Costa ML, Gafrey A. Open reduction and internal fixation versus hybrid fixation for bicondylar/severe tibial plateau fractures: a systematic review of the literature. *Arch Orthop Trauma Surg* 2008;128:1169-75.
 22. Catagni MA, Ottaviani G, Maggioni M. Treatment strategies for complex fractures of the tibial plateau with external circular fixation and limited internal fixation. *J Trauma* 2007;63:1043-1053.
 23. Chin TYP, Bardana D, Bailey M, Williamson OD, Miller R, Edwards ER, *et al.* Functional outcome of tibial plateau fractures treated with the fine-wire fixator. *Injury* 2005;36:1467-1475.