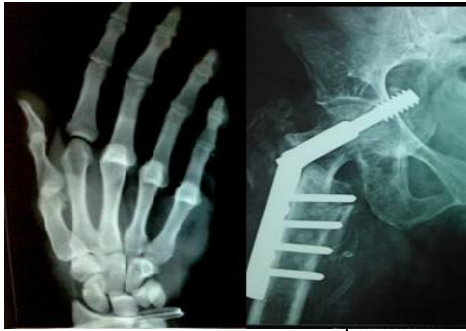

International Journal of Orthopaedics Sciences

E-ISSN: 2395-1958
P-ISSN: 2706-6630
IJOS 2021; 7(1): 478-482
© 2021 IJOS
www.orthopaper.com
Received: 12-11-2020
Accepted: 18-12-2020

Dr. Swapnil Nalge
Assistant Professor, Government
Medical College, Surat, Gujarat,
India

Dr. Hiren Shah
MS Orthopaedic, Government
Medical College, Surat, Gujarat,
India

Dr. Nrutik Patel
Postgraduate, MS Orthopaedic,
Government Medical College,
Surat, Gujarat, India

Dr. Aditya Tripathi
Postgraduate, MS Orthopaedic,
Government Medical College,
Surat, Gujarat, India

Cadaveric coracoid dimensions in Indian populations for its implications in shoulder instability

Dr. Swapnil Nalge, Dr. Hiren Shah, Dr. Nrutik Patel and Dr. Aditya Tripathi

DOI: <https://doi.org/10.22271/ortho.2021.v7.i1h.2529>

Abstract

Objective: Anterior shoulder instability with glenoid bone loss is a common clinical entity, particularly among young athletic patient population. Nonoperative management and arthroscopic treatment of glenohumeral instability have been associated with high rates of recurrence. Significant bone loss is commonly managed with the bony augmentation mainly Latarjet procedure. However, the bony anatomy of the coracoid in coracoid transfer has not yet been defined in Indian populations. The aims of this study were to describe the coracoid anatomy and average bone dimension of coracoid available for transfer in Indian populations.

Methods: We dissected 20 fresh frozen shoulders, exposing the coracoid process and then measured the bony dimensions of the coracoid.

Results: The mean coracoid length was 26.03mm (SD, 1.98mm), mean coracoid width was 16.16mm (SD, 1.53mm), mean coracoid height was 9.66mm (SD, 0.82mm).

The mean subscapularis vertical dimension at the level of coracoid graft insertion (sling mechanism) was 35.35mm (SD, 4.51mm), mean vertical dimension at subscapularis footprint was 24.82 (SD, 3.28mm) and mean anteroposterior dimension at footprint was 15.98mm (SD, 1.31mm). The mean Coracoacromial ligament length was 2.46mm (SD, 0.24mm)

Conclusion: The coracoid dimensionally available for transfer in Indian population are slight less than American populations. Thus facing difficulty in inserting two screws for Latarjet procedure by standard Gillie Walch technique.

Keywords: Cadaver, coracoid dimensions, latarjet procedure, shoulder instability

Introduction

Chronic anterior shoulder instability with glenoid bone loss can be a very demanding clinical problem. Literatures suggest that “significant” degree of bone loss means greater than 25% the width of the glenoid [1-5]. Restoration of glenohumeral stability in the setting of significant anteroinferior bone loss (often described as the “inverted-pear” glenoid) requires a bone grafting procedure [6]. Failure to recognise or to treat bony instability is the primary cause of unsuccessful arthroscopic shoulder reconstructions, and it has been well demonstrated in the literature that attempting to treat a bony problem with a soft-tissue solution will result in recurrent instability [2, 3, 5].

Bone graft can be taken from either coracoid or contoured structural bone graft including autologous tricortical iliac crest bone graft, as well as femoral head, distal tibia and iliac crest allograft [7, 8, 9].

Latarjet [6] first described his eponymous coracoid transfer for the development of increased edge loading. The coracoid and attached conjoint tendon are transferred to the scapular neck to restore the bony surface area and articular arc of the anteroinferior glenoid. The pectoralis minor is detached from the medial aspect of the coracoid, and the bone osteotomise at the knee of the coracoid, just anterior to the coracoclavicular ligaments. The conjoint tendon remains attached, vascularizing the graft as well as further stabilizing the shoulder through a sling effect. The undersurface of the coracoid is fixed with its long axis in a superior-to-inferior orientation against the anterior glenoid neck. The coracoid graft is fixed flush with the glenoid. Placement of the graft in a proud position must be avoided to prevent the development of

Corresponding Author:
Dr. Nrutik Patel
Postgraduate, MS Orthopaedic,
Government Medical College,
Surat, Gujarat, India

increased contact pressures, and placement in a recessed position must be avoided to prevent development of increased edge loading¹⁰.

Our objective with this study was to evaluate the anatomic coracoid measurements.

The purpose of the cadaveric study was

1. To measure the length of the coracoid graft distal to the coracoclavicular ligament that may be available for harvesting during the Latarjet procedure.
2. To measure and analyse the width of the undersurface and the medial surface of the coracoid.

Materials and Methods

This anatomic cadaveric study was approved by Ethical Committee, Government Medical College, Surat, India.

The study used 20 fresh frozen shoulders from 20 cadavers who were an average age of 76.5 years (range, 71-82 years) in the Anatomy cadaveric laboratory of Government Medical College, Surat, Gujarat, India. The skin, subcutaneous tissue,

deltoid, and overlying soft tissue were removed, exposing the coracoid, lateral clavicle, and acromion. The footprints of each ligament and tendon attaching to the coracoid were preserved. The footprint insertion areas were clearly marked circumferentially with a pen while the ligament/tendon footprint was intact; the Coracoacromial ligament and subscapularis tendon measurement was taken. Subscapularis tendon was removed from its insertion and then dimensions were taken at footprint. We did the osteotomy of the coracoid at the anterior border of coracoclavicular ligament ('knee' of the coracoid). Osteotomized coracoid dimensions were noted in our study. Measurements were independently recorded by 2 of the authors, blinded to each others' measurements, using a digital caliper accurate to 0.1 mm. The average of the 2 measurements are reported.

The following bony dimensions of the coracoid were measured: (1) distance from the coracoid tip (hereafter termed 'tip') to the coracoid base (length) (2) coracoid width, and (3) coracoid height. Coracoid length was measured as a straight line from the knee to the tip of the coracoid.

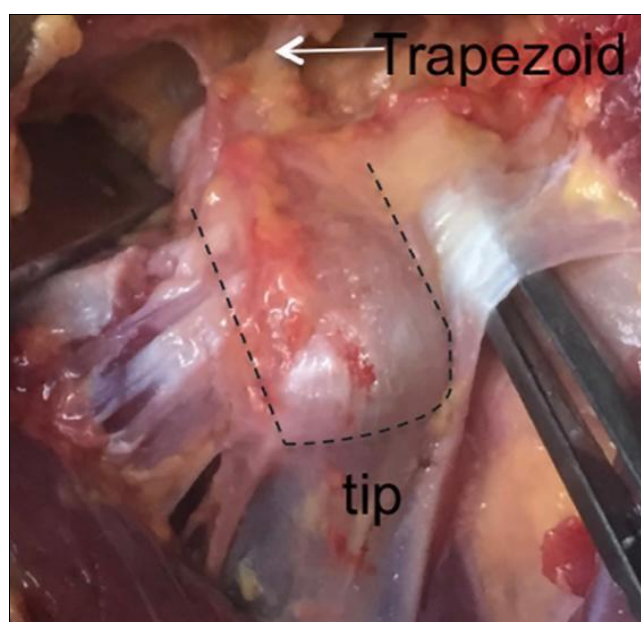


Fig 1: Cadaveric dissection of the coracoid with preserved trapezoid ligament and conjoint tendon

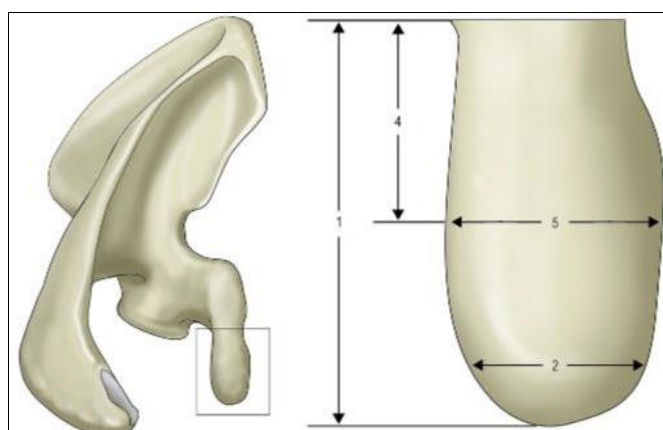


Fig 2: View of the superior aspect of the coracoid. The numbers correlate to 1, coracoid length (distance from tip to base); 2, coracoid tip width; 4, distance from the coracoid tip or base to the coracoid midpoint; 5, midpoint width.

The following soft tissue footprints on the coracoid were studied: Coracoacromial ligament length and subscapularis muscle length at midpart and at insertional footprint site.

The distance from the coracoid tip to the anterior CC

ligaments was measured. This bony area anterior to the CC ligaments is often described as the 'knee' or 'elbow' of the coracoid. The dimensions and location of the trapezoid CC ligament were measured rather than the conoid CC ligament

because the trapezoid footprint is more anterior on the coracoid. Given that the length of coracoid available for transfer is the bone span from the coracoid tip to the most anterior CC ligament footprint, the trapezoid is the more clinically relevant CC ligament in osteotomy and transfer of the coracoid.

Demographic information about each specimen, including age and ethnicity, was retrieved directly from Anatomy cadaveric lab of Government Medical College, Surat Gujarat, India.

Result

Table 1: Individual dimensions of coracoid and soft tissue included in study

Sr. No	Sex	Side	Coracoid			Coracoacromial ligament	Subscapularis tendon		
			Length (mm)	Width (mm)	Height (mm)	Length (cm)	Vertical height (mm)	Vertical height at footprint (mm)	AP dimension at footprint (mm)
1.	Male	Right	26.23	14.59	8.97	2.5	29.70	24.77	16.56
2.	Female	Left	27.60	17.69	9.81	2.7	44.17	28.31	15.88
3.	Male	Right	23.51	17.52	8.29	2.6	42.43	30.91	20.06
4.	Female	Right	23.90	16.34	10.60	2.3	33.24	28.42	16.91
5.	Male	Left	26.12	15.61	10.83	2.4	31.34	25.44	15.32
6.	Male	Left	26.81	15.33	10.18	2.8	37.96	24.28	16.32
7.	Female	Left	27.30	14.10	8.84	2.3	30.81	21.02	13.61
8.	Male	Left	23.07	15.07	8.40	2.6	29.21	19.37	15.22
9.	Female	Left	23.40	18.00	9.63	1.7	36.67	20.63	14.03
10.	Male	Right	29.21	15.16	10.07	2.4	37.16	22.30	14.61
11.	Male	Left	24.04	15.17	9.98	2.7	38.02	24.18	15.09
12.	Male	Right	28.71	19.78	9.84	2.6	42.00	26.20	16.10
13.	Male	Right	26.74	16.18	10.24	2.4	34.40	26.10	16.39
14.	Female	Left	24.10	16.75	9.10	2.2	30.20	19.63	16.25
15.	Female	Right	23.80	19.10	9.84	2.3	36.77	20.97	15.10
16.	Male	Left	26.40	14.12	8.10	2.6	28.10	24.97	16.83
17.	Female	Right	24.91	16.10	10.96	2.3	33.79	28.41	16.00
18.	Male	Right	27.88	16.34	10.71	2.4	38.99	29.30	17.31
19.	Male	Right	29.01	15.30	9.71	2.7	34.17	24.11	16.07
20.	Female	Left	27.87	14.98	9.10	2.8	37.96	27.10	15.96

Table 2: Result of coracoid and soft tissue dimensions included in study

Structure	Dimensions	Mean	SD	Range	
				Min	Max
1. Coracoid	Length(mm)	26.03	1.98	23.07	29.21
	Breadth(mm)	16.16	1.53	14.10	19.78
	Height(mm)	9.66	0.82	8.10	10.96
2. Subscapularis tendon	Vertical dimension(mm)	35.35	4.51	28.10	44.17
	Vertical dimension at footprint(mm)	24.82	3.28	18.37	30.91
	Anteroposterior dimension at footprint(mm)	15.98	1.31	13.61	20.06
3. Coracoacromial ligament	Length(cm)	2.46	0.24	1.7	2.8

The anatomic dimensions of coracoid and soft tissue are reported in table 1.

The mean coracoid length was 26.03mm (SD, 1.98mm), mean coracoid width was 16.16mm (SD, 1.53mm), mean coracoid height was 9.66mm (SD, 0.82mm).

The mean subscapularis vertical dimension at the level of coracoid graft insertion (sling mechanism) was 35.35mm (SD, 4.51mm), mean vertical dimension at subscapularis footprint was 24.82 (SD, 3.28mm) and mean anteroposterior dimension at footprint was 15.98mm (SD, 1.31mm).

The mean Coracoacromial ligament length was 2.46mm (SD, 0.24mm).

Discussion

In the case of chronic shoulder instability with significant bone loss, coracoid transfer procedure have resulted superior than any other soft tissue procedures in view of lower dislocation rate and other complications [16, 17, 18, 19, 11]. Latarjet procedure reduced humeral head translation by around 354% at 30 degree of abduction and by 374% at 60 degree of abduction [11]. Burkhart *et al.* [12] noticed in their study about reduction of dislocation rate from 67% to 5% in patient with

shoulder instability with significant bone loss. Multiple studies have reported excellent results with Latarjet procedure, with success rates upto 99% [13, 2, 14, 15].

The coracoid graft offer a finite amount of bone, and in some cases with significant bone loss, Iliac crest bone graft or other structural bone graft may be needed to restore sufficient stability and glenoid contour. Many authors advocate the use of allograft or autograft [20-28].

Autologous Iliac crest bone graft provides limitless amount of graft that is non-immunogenic and contourable and also provides osteoinductive and osteoconductive properties [29, 10]. However, iliac crest graft harvesting associated with more complication including transient or permanent lateral femoral cutaneous nerve palsy, infection, hematoma, donor site pain, abdominal hernia and fracture of iliac wing. Thus, Iliac crest bone harvesting must be weighed against potential risks and complication not associated with coracoid transfer.

The aim of our study was to define the average amount of coracoid bone available for the transfer in Indian populations for shoulder instability procedure. We also defined the coracoacromial ligament length and subscapularis dimensions. The mean coracoid length for graft transfer was 26.03mm,

with mean width and mean height was 16.16mm and 9.66mm, respectively. The mean Coracoacromial ligament length was 2.58mm.

Dolan *et al.* [30] (USA) reported that the average maximum length of the coracoid available for transfer was 28.5mm.

The coracoid available for transfer in Indian population are slight less than American populations.

Coracoacromial ligament has a varied and broad insertion onto the coracoid. We noticed that in 2 cadavers, Coracoacromial ligament's footprint much more close to Coracoclavicular ligament. Therefore one must take care when releasing Coracoacromial ligament during coracoid transfer.

Conclusion

The purpose of this study was to assess the average coracoid dimensions available for transfer in shoulder instability procedure. This anatomical descriptions of the coracoid bony and soft tissue insertion give idea about coracoid graft and their implementation in glenoid bone loss surgery.

The subscapularis tendon dimensions also give idea for intraoperative manipulation and coracoid transfer. Thus congruent arc technique would be an better option to accommodate two screws to fix coracoid to anterior aspect of glenoid.

Disclaimer

The authors and any research organisations with which they are affiliated have not received any financial payments or other benefits from any commercial entity related to the subject of this article. No financial biases exist for these authors.

References

1. Bollier MJ, Arciero R. Management of glenoid and humeral bone loss. *Sports Med Arthrosc* 2010;18:140-8. doi:10.1097/JSA.0b013e3181e88ef9
2. Burkhart SS, DeBeer JF, Barth JRH, Criswell T, Roberts C, Richards DP. Results of modified Latarjet reconstruction in patients with anteroinferior instability and significant bone loss. *Arthroscopy* 2007;23:1033-41. doi:10.1016/j.arthro.2007.08.009
3. Bushnell BD, Creighton RA, Herring MM. Bony instability of the shoulder. *Arthroscopy* 2008;24:1061-73. doi:10.1016/j.arthro.2008.05.015
4. Itoi E, Lee SB, Berglund LJ, Berge LL, An KN. The effect of a glenoid defect on anteroinferior stability of the shoulder after Bankart repair: a cadaveric study. *J Bone Joint Surg Am* 2000;82:35-46.
5. Piasecki DP, Verma NN, Romeo AA, Levine WN, Bach BR, Provencher MT. Glenoid bone deficiency in recurrent anterior shoulder instability: diagnosis and management. *J Am Acad Orthop Surg* 2009;17:482-93.
6. Latarjet M. Treatment of recurrent dislocation of the shoulder [in French]. *Lyon Clin* 1954;49:994-7.
7. Hutchinson JW, Neumann L, Wallace WA. Bone buttress operation for recurrent anterior shoulder dislocation in epilepsy. *J Bone Joint Surg Br* 1995;77:928-32.
8. Provencher MT, Bhatia S, Ghodadra NS, Grumet RC, Bach BR Jr, Dewing CD, *et al.* Recurrent shoulder instability: current concepts for evaluation and management of glenoid bone loss. *J Bone Joint Surg Am* 2010;92(2):133-51. doi:10.2106/JBJS.J.00906
9. Provencher MT, Ghodadra N, LeClere L, Solomon DJ, Romeo AJ. Anatomic osteochondral glenoid reconstruction for recurrent gleno- humeral instability with glenoid bone deficiency using a distal tibia allograft. *Arthroscopy* 2009;25:446-52. doi:10.1016/j.arthro.2008.10.017
10. Ghodadra N, Gupta A, Romeo AA, Bach BR Jr, Verma N, Shewman E, *et al.* Normalization of glenohumeral articular contact pressures after Latarjet or iliac crest bone-grafting. *J Bone Joint Surg Am* 2010;92:1478-89. doi:10.2106/JBJS.I.00220
11. Wellmann M, Petersen W, Zantop T, Herbolt M, Kobbe P, Raschke MJ, *et al.* Open shoulder repair of osseous glenoid defects: biomechanical effectiveness of the Latarjet procedure versus a contour structural bone graft. *Am J Sports Med* 2009;37:87-94. Doi:10.1177/036354650832671412.
12. Burkhart SS, De Beer JF, Barth JR, Cresswell T, Roberts C, Richards DP. Results of modified Latarjet reconstruction in patients with anteroinferior instability and significant bone loss. *Arthroscopy* 2007;23:1033-41. doi:10.1016/j.arthro.2007.08.009
13. Allain J, Goutallier D, Glorion C. Long-term results of the Latarjet procedure for the treatment of anterior instability of the shoulder. *J Bone Joint Surg Am* 1998;80:841-52.
14. Hovelius L, Korner L, Lundberg B, Akermark C, Herberts P, Wredmark T, *et al.* The coracoid transfer for recurrent dislocation of the shoulder. Technical aspects of the Bristow-Latarjet procedure. *J Bone Joint Surg Am* 1983;65:926-34.
15. Young DC, Rockwood CA Jr. Complications of a failed Bristow procedure and their management. *J Bone Joint Surg Am* 1991;73:969-81.
16. Burkhart SS, De Beer JF. Traumatic glenohumeral bone defects and their relationship to failure of arthroscopic Bankart repairs: significance of the inverted-pear glenoid and the humeral engaging Hill-Sachs lesion. *Arthroscopy* 2000;16:677-94. doi:10.1053/jars.2000.17715
17. Millett P, Clavert P, Warner J. Open operative treatment for anterior shoulder instability: when and why? *J Bone Joint Surg Am* 2005;87: 419-32. doi:10.2106/JBJS.D.01921
18. Piasecki DP, Verma NN, Romeo AA, Levine WN, Bach BR, Provencher MT. Glenoid bone deficiency in recurrent anterior shoulder instability: diagnosis and management. *J Am Acad Orthop Surg* 2009;17:482-93.
19. Tauber M, Resch H, Forstner R, Raffl M, Schauer J. Reasons for failure after surgical repair of anterior shoulder instability. *J Shoulder Elbow Surg* 2004;13:279-85. doi:10.1016/j.jse.2004.01.008
20. Auffarth A, Schauer J, Matis N, Kofler B, Hitzl W, Resch H. The J-bone graft for anatomical glenoid reconstruction in recurrent post- traumatic anterior shoulder dislocation. *Am J Sports Med* 2008;36:638-47. doi:10.1177/03635466507309672
21. Bodey WN, Denham RA. A free bone block operation for recurrent anterior dislocation of the shoulder joint. *Injury* 1983;15:184-8.
22. Brox JI, Finnanger AM, Merckoll E, Lereim P. Satisfactory long-term results after Eden-Hybbinette-Alvik operation for recurrent anterior dislocation of the shoulder: 6-20 years 'follow-up of 52 patients. *Acta Orthop Scand* 2003;74:180-5.
23. Haaker RG, Eickhoff U, Klammer HL. Intraarticular autogenous bone grafting in recurrent shoulder dislocations. *Mil Med* 1993;158:164-9.

24. Hindmarsh J, Lindberg A. Eden-Hybbinette's operation for recurrent dislocation of the humero-scapular joint. *Acta Orthop Scand* 1967;38:459-78.
25. Hutchinson JW, Neumann L, Wallace WA. Bone buttress operation for recurrent anterior shoulder dislocation in epilepsy. *J Bone Joint Surg Br* 1995;77:928-32.
26. Khazzam M, Kane SM, Smith MJ. Open shoulder stabilization procedure using bone block technique for treatment of chronic glenohumeral instability associated with bony glenoid deficiency. *Am J Orthop (Belle Mead NJ)* 2009;38:329-35.
27. Rahme H, Wikblad L, Nowak J, Larsson S. Long-term clinical and radiologic results after Eden-Hybbinette operation for anterior instability of the shoulder. *J Shoulder Elbow Surg* 2003;12:15-9. Doi:10.1067/mse.2002.128138
28. Scheibel M, Nikulka C, Dick A, Schroeder RJ, Popp AG, Hass NP. Autogenous bone grafting for chronic anteroinferior glenoid defects via a complete subscapularis tenotomy approach. *Arch Orthop Trauma Surg* 2008;128:1317-25. doi:10.1007/s00402-007-0560-z
29. Arrington ED, Smith WJ, Chambers HG, Bucknell AL, Davino NA. Complications of iliac crest bone graft harvesting. *Clin Orthop Relat Res* 1996;300:9.
30. Dolan CM, Hariri S, Hart ND, McAdams TR. An anatomic study of the coracoid process as it relates to bone transfer procedures. *J Shoulder Elbow Surg* 2011;20:497-501.
[Http://dx.doi.org/10.1016/j.jse.2010.08.015](http://dx.doi.org/10.1016/j.jse.2010.08.015)