E-ISSN: 2395-1958
P-ISSN: 2706-6630
IJOS 2021; 7(1): 408-411

www.orthopaper.com
Received: 10-11-2020
Accepted: 17-12-2020

Dr. Rohan Navalkar
Shree Sathya Sai Medical College and Research Institute, Ammapettai, Tamil Nadu, India

Dr. F Abdul Khader
Shree Sathya Sai Medical College and Research Institute, Ammapettai, Tamil Nadu, India

Dr. S Raghul Raj
Shree Sathya Sai Medical College and Research Institute, Ammapettai, Tamil Nadu, India

Corresponding Author:
Dr. F Abdul Khader
Shree Sathya Sai Medical College and Research Institute, Ammapettai, Tamil Nadu, India

A brief review on proximal fibular osteotomy for treating medial compartment osteoarthritis of knee

Dr. Rohan Navalkar, Dr. F Abdul Khader and Dr. S Raghul Raj

DOI: https://doi.org/10.22271/ortho.2021.v7.i1g.2519

Abstract
It was seen that Proximal fibular osteotomy (PFO) is a very simple to perform and a very low-cost surgery when compared to knee arthroplasty and high-tibial osteotomy and was seen to be useful in treating low socio-economic populations that cannot afford expensive surgical treatment methods. The literature available currently consists of mainly of case series and finds PFO useful in symptomatic improvement of medial compartment osteoarthritis. However, there is a lack of consensus regarding the functional outcome of this surgery and also the exact mechanism that is in action. This study was hence conducted to analyse all the evidence on proximal fibular osteotomy which is available, to know its benefits and the mechanisms in action. The theories like non-uniform settlement, slippage phenomenon, the too-many cortices theory, dynamic fibular distalization theory, the concept of competition of muscles, ground reaction vector readjustment theory are various mechanisms have been proposed previously. We have discussed these mechanisms and proposed directives for future research. However, to be sure of the benefits of this procedure when compared to other established treatment modalities, large trials and long-term follow-up studies are required.

Keywords: Osteoarthritis, medial compartment osteoarthritis, proximal fibular osteotomy, upper partial fibulectomy

Introduction
Osteoarthritis (OA) most commonly affects the knee joint. It occurs predominantly in the medial compartment of knee. A prevalence of 12% has been reported in elderly patients above the age of 60 years with symptomatic OA knee [1] and a 44% of lifetime risk was reported for symptomatic knee OA [2]. 10, 000 patients in Sweden were studied and the radiological revalence of OA (≥ grade 2 Kellgren-Lawrence (KL)) was found to be 25.4%. Symptomatic OA was found to be 15.4% while frequent knee pain was reported in 25.1% of these subjects [3] 26.5% of male and 35.6% of females, in 2197 weight-bearing radiographs of the knee, in rural Japan were found to be having symptomatic OA knee and on radiographic examination were found to have grade 2 OA or more with some amount of varus deformity [4]. Barrett *et al*. reported an incidence of 63% in terms of varus deformity which is common in primary OA knee [5].

Uni-compartmental knee arthroplasty (UKA), total knee arthroplasty (TKA) and high-tibial osteotomy (HTO) are a few surgical modalities that are being used for treating medial compartment OA knee. Proximal fibular osteotomy (PFO) or upper partial fibulectomy is a simple and a novel procedure which is equally effective, easily reproducible, short recovery time, giving good functional result and which improves the quality of life of patients of OA knee. This review article attempts to discuss the existing literature available on this procedure with respect to above mentioned aspects along with its origin, biomechanics of OA knee and indications.

Methodology of the review
A web search for the keyword "proximal fibular osteotomy" and "upper partial fibulectomy" was done in established journal libraries. Out of the endless results, the articles and studies relevant to PFO and present study were identified and shortlisted. These included 10 studies from PubMed, 1 from Cochrane, 10 articles from Embrase, 8 each from Ovid medline and

Scopus. Articles published in the past 10 years and in English language were chosen. Articles and studies which were duplicates and the articles not traceable in the archives were excluded. The references for these articles were again checked for relevance. Different mechanism that cause varus deformities in OA were reviewed along with different mechanisms for functional improvement in PFO were studied.

Biomechanics of varus deformity in OA knee

In OA of knee joint, there is a medial shift of the mechanical axis as well as the degenerative compression of medial tibial plateau. This leads to reduction of the valgus angle of the normal knee. There are evidence of the varus deformity initiates during the early stages of the disease which later gets defined with tibial plateau compression contributing significantly [6].

The trabeculae of the proximal tibia bear more axial load as compared to the cortex which is at the outer border. Being cancellous in nature, risk of resorption and collapse are present in this part. Fibula on the other hand being cortical in nature is not affected much. Females are more affected then males due to a faster rate of resorption in trabecular bone and thus have a greater risk of varus deformity than men [7, 8]. HVID after his study on the strength and axial loading patterns in tibia, noted that the medial compartment is affected more than the lateral compartment of knee in OA [9]. Fibula only bares 16% of the total weight in lower limb, out of which maximum loading occurs at the ankle joint when compared to the knee joint [10]. This informs us that the fibula which is supporting the lateral compartment of the knee joint is less affected in OA of knee joint.

Wear and tear of knee joint in osteoarthritis

In a normal knee joint (i.e. intact ACL with normal joint alignment), medial compartment OA knee affects the anteromedial aspect most commonly [11, 12]. This wear at the knee joint is due to the loading of the articular surface of proximal tibia [9].

In OA of knee joint, the area affected by the wear is greater in the medial compartment and involves the posterior aspect as well. This is noted to be more in patients with deficient ACL [11].

Origin of PFO

Yazdi *et al*. [13] in 2014 did a study on cadaveric knee and was the first to suggest that use of PFO from releasing the pressure over the medial compartment in OA knee. He concluded that PFO paired with periarticular knee osteotomy gives better outcome in the knee joint.

A year later Yang *et al*., concluded their study on PFO which was a retrospective case study model in Hebei, China [14].

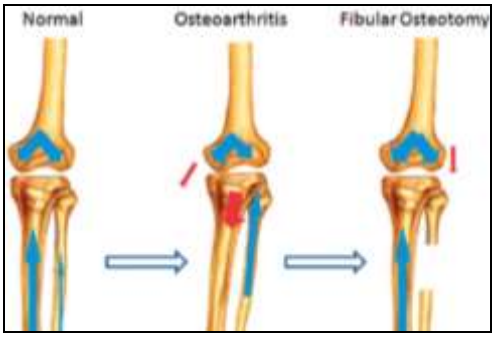

Fig 1: Distribution of load over the normal knee joint compared with the load sharing in OA of knee and Post PFO

Different concepts behind PFO

"Non-uniform settlement" concept suggests that the medial compartment settles more as compared to the lateral compartment due to the extra support of fibula on the lateral side of the tibia. This in turn increased the medial joint pressure of the knee and causes the pain. It is suggested to be the cause for varus deformity in OA knee. Loading of the knee joint aggravates the settlement [14, 15].

Dong *et al*., found a significant relationship between the KL grading of OA knee and the settlement value of knee. Studies also showed an improvement in varus deformity after PFO which was casuse by the settlement of lateral compartment of the knee joint post-operatively [14-18].

"too-many-cortices theory" suggests that the medial compartment is supported by a single cortex while on the other hand the lateral compartment is supported by two cortices of tibia and fibula. Thus a OA knee with intact fibula will most likely go into varus deformity [19].

"Competition of muscles" is a concept introduced by Huang *et al*., which suggests that after PFO the activity of peroneus muscle decreases and that of biceps femoris increases. This causes the immediate pain relief post-operatively in patients and improves their HKA angle [20].

The cause of varus deformity and its progression was suggested to be due to the sliding of femur more to the medial compartment due to the non-uniform settlement of knee joint. This was seen radiologically and was called as 'tibiofemoral subluxation' or "slippage phenomenon" [21, 22].

"Dynamic fibular distalization" theory was proposed by Qin *et al*., in their prospective type of study. He suggested that the muscles attached to the proximal end of fibula pull the head of fibula distally and the force is transferred to the femoral condyle. Hence there is lateral joint narrowing which in turn opens up the medial joint space [20].

"Ground reaction vector readjustment" theory was suggested by Xie *et al*. [23], in the year 2018. They said that the lateral malleolus will move proximally and the calcaneus will go into valgus due to the calcaneofibular ligament. However, Guo *et al*. [24] did not approved the theory as there was limited evidence of lateral malleolus migrating proximally. They suggested that after PFO the ankle valgus will be improved in patients.

Proposed procedures for PFO

As the approaches for PFO are not defined, various authors have used approaches which they found to be suitable.

Huang *et al*., removed 1 cm of proximal fibula which was 7-8 cm distal to the head of fibula. They approached through the extensor digitorum longus and peroneus longus/brevis muscles [20]. Few have approached through the plane between peroneus and soleus muscles and osteotomized 2 cm segment of fibula 6-10 cm distal to its head [15, 25].

While performing PFO, fibula approached through posterior to coronal plane was found to be safest in case of preventing the peroneal nerve injury [26]. Osteotomy in distal part of fibula was avoided to keep the stability of the ankle joint intact [26, 27].

Outcome after PFO

Huang *et al*., in their study noted the changes in the gait of the patients after PFO and also noted an decrease in the knee varus angle by 5° [16]. Radiographic evidence taken after 1 year showed improved valgus of the knee joint and medial joint space [16, 28].

Wang *et al*., studied 46 patients for 1 year and recorded the

time taken for surgery which was 32±9 minutes, pain scale by VAS and American knee society score. Their study concluded that there was a significant improvement in all the parameters and few patients showed improvement in the knee joint alignment as well [17].

Lie *et al*., studied 84 patients with respect to Kellgren-Lawrence grading, CP angle, HKA angle, settlement value of knee and joint space of knee. They concluded that the KSS clinical score and joint space affected the clinical outcome of PFO while the functional outcome was affected by the knee settlement value, VAS, HKA angle and Age. They also suggested that HKA angle and knee settlement value can be used as a parameter for patient selection [25].

Utomo *et al*., studied 15 patients with KL grade IV of OA knee. The functional outcome was recorded using oxford knee score, SF-12 questionnaire, QOL index, ADL score and KOOS. They observed an improvement in all the parameter but lacked in testing the significance of their study [29].

Yang *et al*., studied 110 patients under the parameters of FTA, KSS, VAS and joint space. They noted a significant improvement in KSS, VAS and joint space. Also noted a decrease in the FTA and lateral joint space and recorded very less complications among their patients [14].

Zou *et al*., performs a comparative study which was prospective in nature among patients with medial compartment OA knee undergoing PFO vs HTO. They recorded a significant decrease in the time taken to perform the surgery, post-operative time for recovery, post-operative time taken to weight bear, VAS and FTA in the PFO group. They also noted few complications associated with PFO when compared to HTO [30].

Prognosis after PFO

Liu *et al*. [30] made a study of the various factors that can affect the functional outcome of PFO. They concluded that the knee joint with normal alignment gave a better joint function post-operatively. Some patients showed partial correction in the degree of varus deformity they had pre-operatively. They also suggested that the patients with high knee joint settlement value gave a better outcome after PFO. They recorded a significant improvement in the Knee Society score and HKA angle post-operatively.

Proposed complications during PFO

Peroneal nerve injury is the most common injury to occur in the operative site for proximal fibular osteotomy. Yang *et al*. in his report recorded about 1.8% patients suffered common peroneal nerve injury while 1.8% suffered superficial peroneal nerve injury and 14.5% patient reported weakness in power. All patients recovered within 1 month to 10 months [14].

Ogdemubia *et al*., in their study compared risk of peroneal nerve injury in PFO with that of High tibial osteotomy. They concluded that the maximum risk of injury to the nerve is at the proximal 8.2cms of fibula [26]. The area for effective PFO lies in the proximal 6cm to 10cm of fibula and osteotomy below 10cms will result in failure of surgery as the medial compartment pressure will not be adequately reduced.

Risk of peroneal nerve injury decreases if the surgery was performed in posterior approach to the coronal plane of leg [26]. In some patients, extensor hallucis longus muscle was affected due to its proximally originating nerve supply 9cm below the head of fibula [26, 27, 29]. Injury to peroneal nerve is high risk due to the fact that is in close contact with the periosteum and can be directly be injured during retraction or manipulation [31, 32].

Future research in PFO

A need for blinded and double blinded studies on PFO are still required before we can decide the exact benefits of the surgery. The use of PFO in routine practice is still needs to be established. The review of available literature still keeps some question unanswered which needs to be addressed in the studies done in future.

1. Can PFO be used in post-traumatic OA of the knee joint?
2. What degree of varus deformity is acceptable for performing a successful PFO?
3. How long will PFO keep the patient pain free?
4. PFO in unstable knee joint vs PFO in stable knee joint.
5. Can PFO be combined with other surgical procedure like arthroscopy or PRP injection and give better outcome?

Conclusion

Even though the current data is limited to short term case studies and further research is required to be done before recommending PFO for regular clinical practice in orthopaedics. It can be concluded that proximal fibular osteotomy is a safe surgery that can be done with minimum operative requirement and setup. It is an effective surgery in reducing pain for OA knee patients. For patients with early OA knee it is a good alternate surgery for reducing symptoms. For patients who cannot afford surgeries like TKA and Uni-condylar arthroplasty, PFO is a cheap alternative and suitable in low-socioeconomic population.

References

1. Dillon CF, Rasch EK, Gu Q, Hirsch R. Prevalence of knee osteoarthritis in the United States: arthritis data from the Third National Health and Nutrition Examination Survey 1991-94. J Rheumatol 2006;33(11):2271-9.
2. Murphy L, Schwartz TA, Helmick CG, Renner JB, Tudor G, Koch G *et al*. Lifetime risk of symptomatic knee osteoarthritis. Arthritis Rheum 2008;59(9):1207-13.
3. Turkiewicz A, Gerhardsson De Verdier M, Engström G, Nilsson PM, Mellström C, Lohmander LS *et al*. Prevalence of knee pain and knee OA in southern Sweden and the proportion that seeks medical care. Rheumatol. Oxf. Engl 2015;54(5):827-35.
4. Hanada M, Hoshino H, Koyama H, Matsuyama Y. Relationship between severity of knee osteoarthritis and radiography findings of lower limbs: A cross-sectional study from the TOEI survey. J Orthop 2017;14(4):484-8.
5. Barrett JP, Rashkoff E, Sirna EC, Wilson A. Correlation of roentgenographic patterns and clinical manifestations of symptomatic idiopathic osteoarthritis of the knee. Clin Orthop 1990;253:179-83.
6. Matsumoto T, Hashimura M, Takayama K, Ishida K, Kawakami Y, Matsuzaki T *et al*. A radiographic analysis of alignment of the lower extremities-initiation and progression of varus-type knee osteoarthritis. Osteoarthritis Cartilage 2015;23(2):217-23.
7. Ding M, Odgaard A, Linde F, Hvid I. Age-related variations in the microstructure of human tibial cancellous bone. J Orthop Res Off Publ Orthop Res Soc 2002;20(3):615–21.
8. Chen H, Washimi Y, Kubo K, Onozuka M. Gender-related changes in three-dimensional microstructure of trabecular bone at the human proximal tibia with aging. Histol Histopathol 2011;26(5):563-70.
9. Hvid I. Mechanical strength of trabecular bone at the knee. Dan Med Bull 1988;35(4):345-65.
10. Goh JC, Mech AM, Lee EH, Ang EJ, Bayon P, Pho RW.

Biomechanical study on the load-bearing characteristics of the fibula and the effects of fibular resection. Clin Orthop 1992;279:223-8.
11. Mullaji AB, Marawar SV, Luthra M. Tibial articular cartilage wear in varus osteoarthritic knees: correlation with anterior cruciate ligament integrity and severity of deformity. J Arthroplasty 2008;23(1):128-35.
12. Raju PK, Kini SG, Verma A. Wear patterns of tibiofemoral articulation in osteoarthritic knees: analysis and review of literature. Arch Orthop Trauma Surg 2012;132(9):1267-71.
13. Yazdi H, Mallakzadeh M, Mohtajeb M, Farshidfar SS, Baghery A, Givehchian B. The effect of partial fibulectomy on contact pressure of the knee: a cadaveric study. Eur J Orthop Surg Traumatol 2014;24(7):1285-9.
14. Yang ZY, Chen W, Li CX, Wang J, Shao DC, Hou ZY *et al*. Medial Compartment Decompression by Fibular Osteotomy to Treat Medial Compartment Knee Osteoarthritis: A Pilot Study. Orthopedics 2015;38(12):e1110-4.
15. Dong T, Chen W, Zhang F, Yin B, Tian Y, Zhang Y. Radiographic measures of settlement phenomenon in patients with medial compartment knee osteoarthritis. Clin Rheumatol 2016;35(6):1573-8.
16. Huang W, Lin Z, Zeng X, Ma L, Chen L, Xia H *et al*. Kinematic Characteristics of an Osteotomy of the Proximal Aspect of the Fibula During Walking: A Case Report. JBJS Case Connect 2017;7(3):e43.
17. Wang X, Wei L, Lv Z, Zhao B, Duan Z, Wu W *et al*. Proximal fibular osteotomy: a new surgery for pain relief and improvement of joint function in patients with knee osteoarthritis. J Int Med Res 2017;45(1):282-9.
18. Sharma L. The Role of Knee Alignment in Disease Progression and Functional Decline in Knee Osteoarthritis. JAMA 2001;286(2):188.
19. Prakash L. PFO-Proximal Fibular Osteotomy in medial compartment arthritis of the knee with varus deformity. EC Orthop 2019;10(5):315-21.
20. Ze Yu, Huang YN, Xu B, Shen B, Kraus VB, Pei F. Evidence and mechanism by which upper partial fibulectomy improves knee biomechanics and decreases knee pain of osteoarthritis: A Pilot and Biomechanical Study. J Orthop Res 2018;36(8):2099-108.
21. Shanmugasundaram S, Kambhampati SBS, Saseendar S. Proximal fibular osteotomy in the treatment of medial osteoarthritis of the knee-A narrative review of literature. Knee Surg. Relat. Res 2019;31(1):16.
22. Saseendar S, Shanmugasundaram S, Kambhampati S. Reply to A Critical Review of Proximal Fibular Osteotomy for Knee Osteoarthritis. Arch Bone Jt. Surg. [Internet] 2019. Available from: https://doi.org/10.22038/abjs.2019.44398.2215
23. Xie W, Zhang Y, Qin X, Song L, Chen Q. Ground reaction vector re-adjustment-the secret of success in treatment of medial compartment knee osteoarthritis by novel high fibular osteotomy. J Orthop 2018;15(1):143-5.
24. Guo J, Zhang L, Qin D, Chen W, Dong W, Hou Z *et al*. Changes in ankle joint alignment after proximal fibular osteotomy. Tsuchiya H, editor. Plos One 2019;14(3):e021-4002.
25. Liu B, Chen W, Zhang Q, Yan X, Zhang F, Dong T *et al*. Proximal fibular osteotomy to treat medial compartment knee osteoarthritis: Preoperational factors for short-term prognosis. Isales CM, editor. Plos One 2018;13(5):e0197-980.
26. Ogbemudia A, Umebese PFA, Bafor A, Igbinovia E, Ogbemudia P. The level of fibula osteotomy and incidence of peroneal nerve palsy in proximal tibial osteotomy. J Surg Tech Case Rep 2010;2(1):17.
27. Wootton JR, Ashworth MJ, MacLaren CA. Neurological complications of high tibial osteotomy-the fibular osteotomy as a causative factor: a clinical and anatomical study. Ann R Coll. Surg. Engl 1995;77(1):31-4.
28. Qin D, Chen W, Wang J, Lv H, Ma W, Dong T *et al*. Mechanism and influencing factors of proximal fibular osteotomy for treatment of medial compartment knee osteoarthritis: A prospective study. J Int. Med Res 2018;46(8):3114-23.
29. Utomo DN, Mahyudin F, Wijaya AM, Widhiyanto L. Proximal fibula osteotomy as an alternative to TKA and HTO in late-stage varus type of knee osteoarthritis. J Orthop 2018;15(3):858-61.
30. Zou G, Lan W, Zeng Y, Xie J, Chen S, Qiu Y. Early clinical effect of proximal fibular osteotomy on knee osteoarthritis. Biomed Res 2017;28(21):4.
31. Kirgis A, Albrecht S. Palsy of the deep peroneal nerve after proximal tibial osteotomy. An anatomical study. J Bone Joint Surg. Am 1992;74(8):1180-5.
32. Georgoulis AD, Makris CA, Papageorgiou CD, Moebius UG, Xenakis T, Soucacos PN. Nerve and vessel injuries during high tibial osteotomy combined with distal fibular osteotomy: a clinically relevant anatomic study. Knee Surg. Sports Traumatol Arthrosc 1999;7(1):15-9.